

CASE REPORT

Long-term persistent fetomaternal hemorrhage

Takeshi Umazume¹, Mamoru Morikawa¹, Takahiro Yamada¹, Kazutoshi Cho¹, Nobuo Masauzi² & Hisanori Minakami¹

¹Department of Perinatal Medicine, Hokkaido University Hospital, Sapporo, Japan

²Department of Medical Laboratory Science, Faculty of Health Sciences, Hokkaido University, Sapporo, Japan

Correspondence

Takahiro Yamada, Department of Obstetrics, Hokkaido University Graduate School of Medicine, N14 W6, Kita-ku, Sapporo 060-8638, Japan. Tel: +81 11 706 5941; Fax: +81 11 706 7711; E-mail: taka0197@med.hokudai.ac.jp

Funding Information

This study was supported by Grants-in-Aid for Scientific Research from the Ministry of Education, Science, Sports, and Culture of Japan (no. 25462546 and 26462468).

Received: 8 May 2015; Revised: 9 June 2015; Accepted: 29 July 2015

Clinical Case Reports 2015; 3(11): 916–919

doi: 10.1002/ccr3.345

Key Clinical Message

It is not clear that how long the affected fetuses can tolerate fetomaternal hemorrhage (FMH). Incidental serial measurements of the fetal peak systolic velocity of the middle cerebral artery and the retrospective analysis of stocked blood available incidentally indicated that our patient had suffered from FMH for at least 2 weeks prior to delivery.

Keywords

Alpha fetoprotein, blood flow velocity, fetomaternal hemorrhage, HELLP syndrome, middle cerebral artery/ultrasonography.

Introduction

Fetal blood can enter the maternal circulation and a diagnosis of clinical fetomaternal hemorrhage (FMH) is made when fetal blood loss reaches a significant level leading to clinical symptoms due to fetal anemia, such as an abnormal fetal heart rate (FHR) patterns, decreased fetal movement, and/or fetal hydrops. FMH with clinical problems is estimated to occur in 1 of 3000–10,000 births [1–4], and affected infants may die, survive with disability, or exhibit normal development [1–4]. FMH accounts for approximately 2.0% of Japanese infants with cerebral palsy caused by antenatal and/or intrapartum hypoxic conditions [5].

Measurement of fetal middle cerebral artery peak systolic velocity (MCA-PSV) is a useful noninvasive test for detection of fetal anemia due to not only Rh alloimmunization [6] but also FMH [7–11]. However, as the MCA-PSV is measured in women with suspected fetal anemia and/or nonreassuring fetal status (NRFS), neither the time of significant FMH occurrence nor natural history of FMH is well understood. It is also unclear how

long affected fetuses can tolerate clinical FMH. We recently encountered a case of FMH that was diagnosed immediately after birth, but was documented later to have lasted for at least 2 weeks prior to delivery.

Case Presentation

The Hokkaido University Hospital Institutional Review Board approved this study and the patient provided signed informed consent.

A 43-year-old nulliparous woman with body weight of 63 kg was admitted to our hospital at gestational week (GW) 31^{–0/7} due to persistent nausea, proteinuria as evidenced by spot urine protein-to-creatinine ratio (mg/mg) of 0.45, and edema (weight gain of 2.2 kg in 2 weeks) in the presence of normal blood pressure of 136/81 mmHg. Minimal pericardial effusion without skin edema, pleural effusion, or ascites was present in the fetus. Elevation of the aspartate transaminase (AST)/alanine transaminase (ALT) from 29/15 IU/L at GW 28^{–6/7} to 58/45 IU/L with mild thrombocytopenia ($132 \times 10^9/L$), and fetal peak systolic velocity of middle cerebral artery

(MCA-PSV) of 73.6 cm/sec (1.76 multiples of the median [MoM] according to the report by Mari [6]) on the day of admission (at GW 31^{-0/7}), and NRFS (Fig. 1) at GW 31^{-1/7} required early delivery on the day after admission. A male infant was born by cesarean section, weighing 1746 g with 1- and 5-min Apgar scores of 6 and 8, respectively, and arterial cord blood pH, PaCO₂, PaO₂, and base deficits of 6.97, 64.5 mmHg, 22.6 mmHg, and 15.2 mEq/L, respectively. As the neonate was very pale and had a cord blood hemoglobin (Hb) concentration of 3.6 g/dL, 50 mL of red blood cells (RBC) and 20 mL of fresh frozen plasma (FFP) were transfused 2 h after birth. The neonate did not develop respiratory syndrome, did not require tracheal intubation, and exhibited unremarkable findings on brain magnetic resonance imaging (MRI) 46 days after birth. Both the mother and infant had otherwise uneventful clinical courses and left hospital on postpartum day 10 and 53 days after birth, respectively.

The medical chart recorded a gradual and consistent increase in MCA-PSV in this fetus: 31.0 cm/sec (1.07 MoM) at GW 23^{-6/7}, 48.7 cm/sec (1.46 MoM) at GW 26^{-6/7}, and 59.5 cm/sec (1.63 MoM) at GW 28^{-6/7}. Nonspecific complaints of the mother were also recorded, including heartburn at GW 26^{-6/7}, and heartburn and generalized itch without skin eruption at GW 28^{-6/7}.

Investigations of FMH occurrence and diagnosis

Investigations were performed to determine the time of FMH occurrence. As the mother had participated in a prospective study unrelated to the present episode, two blood samples obtained at GW 28^{-6/7} and at GW 31^{-0/7} were stocked and available for retrospective analyses. After

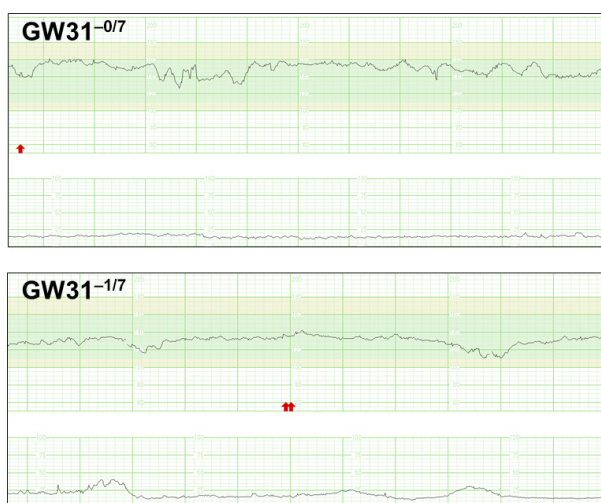


Figure 1. Fetal heart rate tracings. Late decelerations were seen on FHR tracing in this patient at GW 31^{-1/7}.

receiving permission from the patient, flow cytometric assessment of FMH and determination of α -fetoprotein (AFP) were performed using these blood samples as well as blood obtained postpartum. This case already exhibited a high level of HbF fraction, 5.5% at GW 28^{-6/7} (16 days prior to delivery) and 3.2% on the day of admission, and decreased levels of 0.6% on postpartum day 28 (Fig. 2). The AFP level was already markedly elevated to 14,704 ng/mL (67 MoM according to the report of Ishijima [12]) at GW 28^{-6/7}, 23,000 ng/mL (82 MoM) on the day of admission, and 23,702 ng/mL (85 MoM) on postpartum day 0.

At our hospital, ultrasound (including Doppler ultrasound) studies were performed after obtaining inclusive informed consent from all pregnant women at the beginning of pregnancy. Measurement of fetal MCA-PSV in otherwise healthy women used to be performed at the attending physician's discretion in our hospital. However, many physicians measured MCA-PSV in otherwise healthy women at our hospital; in a review of medical charts of 256 women who gave birth to singleton infants without clinical FMH at term (GW 37–40) in 2014 at our hospital, there were 100 women in whom fetal MCA-PSV was measured around GW 30 (between GW 28^{-0/7} and GW 31^{-6/7}). The 100 measurements of MCA-PSV MoM performed by seven physicians were distributed normally (Fig. 3), ranging from 0.60 to 1.95 MoM. The 25th, 50th, 75th, 90th, 95th, and 98th percentile MoM values were 0.85, 1.02, 1.12, 1.28, 1.44, and 1.52, respectively. The 95th percentile MoM of 1.44 was consistent with the results obtained in another study population without diagnosis of FMH by Kurmanavicius *et al.* [13] in which 95th percentile MCA-PSV of 56.1 cm/sec for GW 30 corresponded to 1.40 MoM according to Mari *et al.* [6]. Thus, the prevalence rate of MCA-PSV MoM ≥ 1.5 was estimated as approximately 1 in 50 fetuses without clinical FMH when tested around GW 30.

Discussion

Retrospective analysis of the maternal blood for HbF fraction and AFP concentration demonstrated unequivocally that this patient already suffered from FMH 16 days prior to delivery (at GW 28^{-6/7}). In addition, a consistent increase in fetal MCA-PSV, beginning with 1.46 MoM on GW 26^{-6/7}, suggested that this patient may have suffered from FMH for more than 3 weeks.

Fetal MCA-PSV measurement with Doppler ultrasound is noninvasive and useful for detection of fetal anemia, having a very high sensitivity of 100% with a cutoff of 1.5 MoM [6]. However, this test with a cutoff of 1.5 MoM has a low positive predictive value among the general population of pregnant women—an approxi-

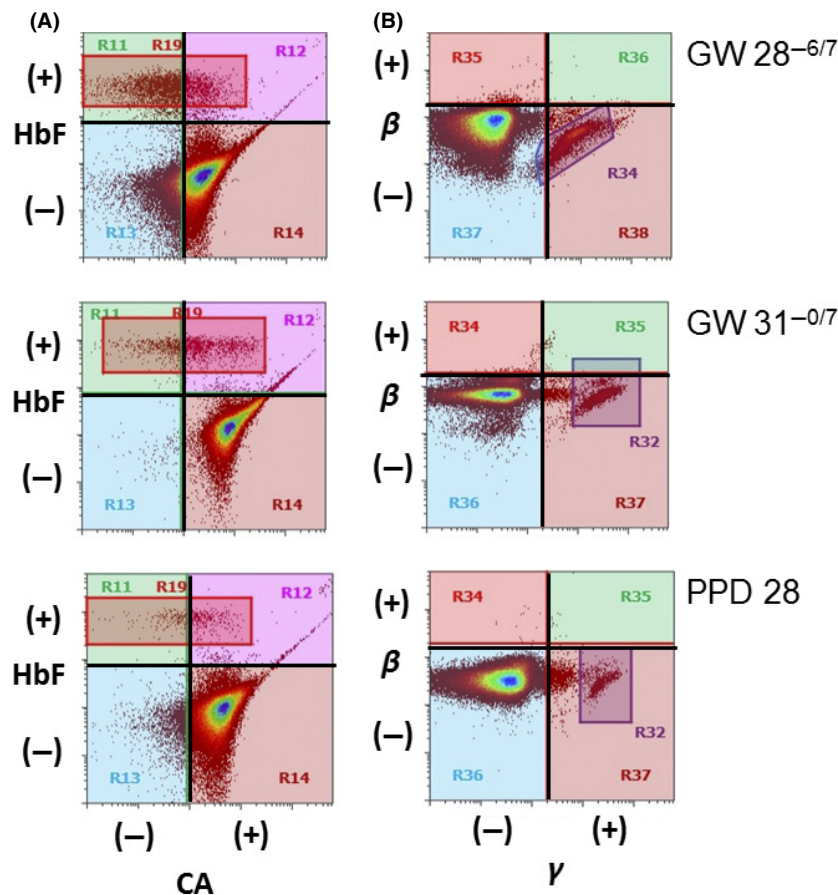


Figure 2. Flow cytometric study for assessment of FMH. Flow cytometric analysis was performed using a Fetal Cell Count™ Kit (IQ Products BV, Groningen, The Netherlands) (A) and monoclonal antibodies against Hb β -chain and Hb γ -chain using hemoglobin β (37-8):PerCP-Cy5.5 and hemoglobin γ (51-7):sc-21756 (Santa Cruz Biotechnology, Inc., Santa Cruz, CA) (B), respectively. Fetal RBC contains fetal Hb (HbF) with γ -chain (γ) and reduced expression of carbonic anhydrase (CA), while F cells composing adult RBCs contain HbF with a high expression of CA. Adult Hb has β -chain (β), but not γ -chain. PPD, postpartum day. Fraction sizes were 5.5% for rectangle area in A and 5.6% for parallelogram area in B on GW 28^{-6/7}, 3.2% and 2.5% for rectangle areas in A and B, respectively, on GW31^{-0/7}, and 0.6% and 0.7% for rectangle areas in A and B, respectively, on PPD 28.

mately 2.0% of women exhibit MCA-MSV MoM ≥ 1.5 in the absence of clinical FMH, as reported by Kurmanavicius *et al.* [13] and demonstrated in this study. As clinical FMH occurs in 2 of 10,000 births based on the literature [1–4], only 2 of 200 women with a positive MCA-PSV test result would have clinical FMH, yielding a positive predictive value of 1.0% (2/200) in the general pregnant population. This may explain why the measurement of MCA-PSV has not been used as a routine test in Japan as well as most other countries.

Our clinical path inevitably did not include measurement of fetal MCA-PSV for otherwise healthy women. Therefore, we did not have a predefined clinical path for cases that were incidentally found to have MCA-PSV MoM ≥ 1.5 . The present review of 100 MCA-PSV measurements around GW 30 suggested that the prevalence rate of MCA-PSV

MoM ≥ 1.5 was not high (approximately 2%). Therefore, the following treatments were recently introduced into our clinical path for cases with incidental MCA-PSV MoM ≥ 1.5 : continuous FHR tracing for 30 min and determination of maternal AFP and HbF fraction levels.

Clinical FMH is rare [1–4], with only a few FMH cases with in utero transfusion reported to date [7, 8, 14]. Cases with in utero transfusion were limited to those with hydrops fetalis [7, 8, 14], and the effects of in utero transfusion on outcome have not yet been established. However, early suspicion of FMH, early confirmation of cord blood Hb concentration in pale neonates, and early blood transfusion may be effective for avoiding neurological sequelae in such anemic neonates [4]. The infant described here is being followed up carefully with respect to neurological development.

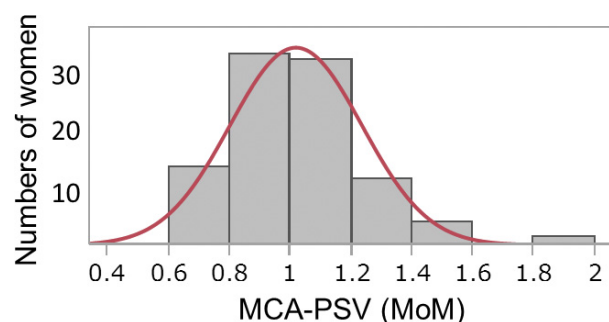


Figure 3. Distribution of MCA-PSV values transformed to MoM among 100 consecutive women. One hundred women underwent fetal MCA-PSV measurement between GW 28^{–6/7} and GW 31^{–6/7} and gave birth to term singleton infants without clinical FMH.

The mother complained of nonspecific symptoms, including heartburn at GW 26^{–6/7}, heartburn and generalized itch without skin eruption at GW 28^{–6/7}, and persistent nausea on the day of admission. Rise of AST/ALT concomitant with a decreased platelet count on the day of admission suggested impending HELLP syndrome. It is unclear at present whether these symptoms were associated with the occurrence of FMH and whether the impending HELLP syndrome was associated with FMH, although a case with onset of HELLP syndrome soon after massive FMH caused by blunt abdominal trauma was reported previously [15].

In conclusion, this case indicated the existence of persistent FMH. However, a policy of screening with MCA-PSV for detection of occult FMH targeting the general pregnant population was considered to be too labor intensive and not cost effective.

Acknowledgments

This study was supported by Grants-in-Aid for Scientific Research from the Ministry of Education, Science, Sports, and Culture of Japan (no. 25462546 and 26462468).

Conflict of Interest

None declared.

References

- DeAlmeida, V., and J. M. Bowman. 1994. Massive fetomaternal hemorrhage: manitoba experience. *Obstet. Gynecol.* 83:323–328.
- Stroustrup, A., and L. Trasande. 2012. Demographics, clinical characteristics and outcomes of neonates diagnosed with fetomaternal haemorrhage. *Arch. Dis. Child. Fetal Neonatal Ed.* 97:405–410.
- Kecskes, Z. 2003. Large fetomaternal hemorrhage: clinical presentation and outcome. *J. Matern. Fetal. Neonatal. Med.* 13:128–132.
- Kadooka, M., H. Kato, A. Kato, S. Ibara, H. Minakami, and Y. Maruyama. 2014. Effect of neonatal hemoglobin concentration on long-term outcome of infants affected by fetomaternal hemorrhage. *Early Hum. Dev.* 90:431–434.
- Yamada, T., T. Yamada, M. Morikawa, and H. Minakami. 2012. Clinical features of abruptio placentae as a prominent cause of cerebral palsy. *Early Hum. Dev.* 88:861–864.
- Mari, G., R. L. Deter, R. L. Carpenter, et al. 2000. Noninvasive diagnosis by Doppler ultrasonography of fetal anemia due to maternal red-cell alloimmunization. Collaborative Group for Doppler Assessment of the Blood Velocity in Anemic Fetuses. *N. Engl. J. Med.* 342:9–14.
- Friszer, S., A. Cortey, F. Pierre, and B. Carbonne. 2010. Using middle cerebral artery peak systolic velocity to time in utero transfusions in fetomaternal hemorrhage. *Obstet. Gynecol.* 115:1036–1038.
- Baschat, A. A., C. R. Harman, L. S. Alger, and C. P. Weiner. 1998. Fetal coronary and cerebral blood flow in acute fetomaternal hemorrhage. *Ultrasound Obstet. Gynecol.* 12:128–131.
- Malcus, P., L. J. Björklund, M. Lilja, P. Teleman, and R. Laurini. 2006. Massive feto-maternal hemorrhage: diagnosis by cardiotocography, Doppler ultrasonography and ST waveform analysis of fetal electrocardiography. *Fetal Diagn. Ther.* 21:8–12.
- Wong, G., and D. Levine. 2005. Increased systolic peak velocity in fetal middle cerebral artery blood flow shown by Doppler sonography in acute fetomaternal hemorrhage. *J. Ultrasound Med.* 24:243–246.
- Moise, K. J. Jr.. The usefulness of middle cerebral artery Doppler assessment in the treatment of the fetus at risk for anemia. *Am. J. Obstet. Gynecol.* 2008; 198: 161.e1–161.e4.
- Ishijima, K. 1992. Changes in levels of obstetrical and gynecological disease-related tumor markers during gestation, puerperium and menstrual cycle, and their significances. *St. Marianna Med. J.* 20:733–745.
- Kurmanavicius, J., A. Streicher, E. M. Wright, et al. 2001. Reference values of fetal peak systolic blood flow velocity in the middle cerebral artery at 19–40 weeks of gestation. *Ultrasound Obstet. Gynecol.* 17:50–53.
- Votino, C., V. Mirlesse, L. Gourand, F. Parnet-Mathieu, B. Bessières, and F. Daffos. 2008. Successful treatment of a severe second trimester fetomaternal hemorrhage by repeated fetal intravascular transfusions. *Fetal Diagn. Ther.* 24:503–505.
- Faber, V. J., F. J. Klumper, S. Scherjon, and W. J. van Wijngaarden. 2011. Severe pre-eclampsia and HELLP syndrome after massive fetomaternal hemorrhage following blunt abdominal trauma. *Pregnancy Hypertens* 1:197–199.