

Perfusion ^{123}I IMP-SPECT shows reversible abnormalities in GABA_B receptor antibody associated encephalitis with normal MRI

Kouichi Ohta¹, Morinobu Seki², Josep Dalmau³ & Yukito Shinohara¹

¹Department of Neurology, Tachikawa Hospital, Tokyo, Japan

²Department of Neurology, Keio University School of Medicine, Tokyo, Japan

³Department of Neurology, University of Pennsylvania School of Medicine, Philadelphia, Pennsylvania

Keywords

autoimmune, limbic encephalitis, GABA, SPECT, cerebral perfusion, cerebral cortex

Correspondence

Kouichi Ohta, M.D., Ph.D., Director,
Department of Neurology, Tachikawa Hospital,
4-2-22 Nishikicho, Tachikawa, Tokyo,
190-8531, Japan. Tel: +81-42-523-3131; Fax:
+81-42-522-5784; E mail:
k.ohta@tachikawa-hosp.gr.jp.

Received: 29 March 2011; Revised: 14 July
2011; Accepted: 27 July 2011

Brain and Behavior 2011; 1(2): 70–72

doi: 10.1002/brb3.14

Conflict of Interest

A patent application for the use of GABA_B receptor as a diagnostic test has been filed by Dr. Dalmau. The rest of the authors have no conflicts of interest.

Abstract

A new subtype of autoimmune encephalitis associated with antibodies against GABA_B receptor was recently identified. Although immune-mediated functional abnormalities are suggested for the pathogenesis, functional brain imaging such as perfusion SPECT has not been documented. A 62-year-old woman with anti-GABA_B receptor associated encephalitis underwent ^{123}I -IMP SPECT in the beginning and after methylprednisolone pulse therapy. Three-dimensional stereotactic surface projection analysis was used to evaluate the cortical distribution of perfusion abnormality. The patient presented with clinical features of subacute limbic encephalitis. Antibodies to GABA_B receptor were identified in her serum and cerebrospinal fluid (CSF), but no tumor was detected. Despite normal magnetic resonance imaging (MRI) findings, the first SPECT revealed hypoperfusion of the frontal, parietal and medial temporal lobes, as well as thalamus, and cerebellum. These areas are known to contain high levels of GABA_B receptors. In contrast, the SPECT revealed hyperperfusion in the motor strip and left temporal lobe, which are areas related to some of the patient's symptoms, including seizures, orolingual dyskinesia, and Wernicke aphasia. After treatment with pulses of methylprednisolone, the neuropsychiatric symptoms resolved and the SPECT findings showed substantial improvement in most of these regions. In conclusion, the findings suggest that immunotherapy improved the cortical dysfunction mediated by GABA_B receptor antibodies.

A 62-year-old woman, who has been briefly described including the laboratory data as case 11 of the previous case series (Lancaster et al. 2010), without preceding illness noticed difficulty in speech. On day 6, she presented with a generalized convulsive seizure. Brain MRI revealed no abnormalities. On day 12, she had another seizure. During the following days she developed memory deficit, disorientation, psychosis, and fever of 37–38°C. She eventually became delirious, and was admitted to our hospital on day 24. Functions of the cranial nerves, motor and sensory systems were normal. Cerebellar ataxia and meningeal signs were not evident. Brain MRI did not reveal focal lesions or abnormal gadolinium enhancement. Lumbar puncture yielded normal pressure, 80 mmH₂O; total protein, 22 mg/dL; and glucose, 79 mg/dL accompanied by increased mononuclear

cell count, 20/ μL . PCR of CSF was negative for herpes simplex virus, cytomegalovirus, varicella zoster virus, and Epstein-Barr virus. Electroencephalography (EEG) revealed diffuse slow waves. CT of the chest, abdomen, and pelvis revealed no tumors.

Laboratory blood tests revealed increase in the leukocyte count (11,070/ μL) and C-reactive protein (CRP, 5.11 mg/dL). Tumor markers were within normal limits. Viral titers did not increase between paired sera 2 weeks apart.

Antibodies to GABA_B receptor (R) were identified in serum and CSF (Lancaster et al. 2010). The titers of the antibodies were 40 in the serum and 40 in the CSF, defined as the reciprocal of the maximal dilution that gave positive immunostaining. Autoantibodies to NMDAR, AMPAR, VGKC, Ma2, HuD, and CRMP5 were not detected. Other tests including

antinuclear antibodies, rheumatoid factor, and autoantibodies to DNA, SS-A, SS-B, PR3-ANCA, MPO-ANCA, glutamic acid decarboxylase, thyroid peroxidase, thyroglobulin, thyroid stimulating hormone R, Ri, Hu, and Yo were negative.

Methylprednisolone pulse therapy at 1 g/day for 5 days and phenytoin were administered i.v. starting on day 25. On days 25 and 30, she had two generalized seizures, after which she did not develop further seizures. As her consciousness recovered over a period of 1 week after treatment, and EEG revealed restored α waves, she developed Wernicke aphasia and orolingual dyskinesia manifesting as chewing and tongue twisting; these unique symptoms of our patient are not observed among other 14 patients with anti-GABA_BR antibody encephalitis (Lancaster et al. 2010). Methylprednisolone pulse therapy for 3 days was repeated on days 32 and 42 followed by oral prednisolone 50 mg/day. The CSF cell count and CRP levels normalized, following which she became afebrile and regained normal mental as well as neurologic functions by day 50. She was discharged with prednisolone 30 mg/day on day 62.

Assessment of brain perfusion using interictal ¹²³I-IMP SPECT was performed on the fourth day (day 28) of the first course of methylprednisolone pulse therapy and after

the three courses of methylprednisolone pulse therapy (day 46) (Fig. 1). Three-dimensional stereotactic surface projection analysis was used to evaluate the cortical distribution of perfusion (Minoshima et al. 1995). Normalized brain activity of our patient was compared with that of normal controls using the pixel-by-pixel Z-score [(control mean value – patient value)/control SD], which enabled quantitative assessment of the hypoperfused area. SPECT on day 28, while our patient was suffering from neurologic manifestations, showed increased uptake in the superior temporal, middle temporal, and precentral as well as postcentral gyri of the left hemisphere. It also revealed decreased uptake at the anterior outer surface of the frontal lobe, thalamus, and cerebellum on both sides, but more marked on the right side. Decreased uptake was also observed in the inferior parietal lobule, supramarginal, and parahippocampal gyri of the right hemisphere as well as the left rectal gyrus. SPECT on day 46, following corticosteroid therapy and neurologic recovery, revealed normal uptake in all regions, except the bilateral cuneus (increased uptake) and the anterior outer surface of bilateral frontal lobes and bilateral thalamus (decreased uptake).

The patient's antibody demonstrated extensive reactivity with neuropil of the thalamus, hippocampus, cerebellum,

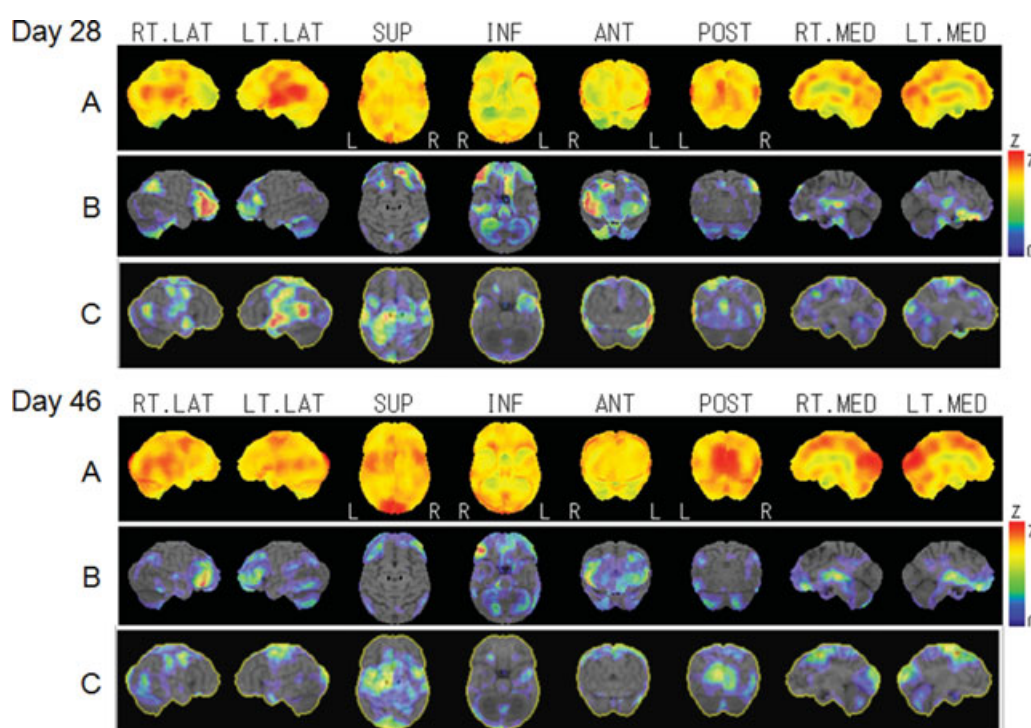


Figure 1. Three-dimensional stereotactic surface projection views of perfusion ¹²³I-IMP-SPECT on day 28 and after methylprednisolone pulse therapy on day 46. Row (A) Qualitative surface views. Row (B) and (C) Pixel-by-pixel Z-score views of functional reduction (B) and increase (C) in our patient in comparison with normal controls. RT.LAT = Right lateral; LT.LAT = left lateral; SUP = superior; INF = inferior; ANT = anterior; POST = posterior; RT.MED = right medial; LT.MED = left medial.

and cerebral cortex of rat brain (Lancaster *et al.* 2010). This localization is consistent with the SPECT findings, such as decreased uptake in the thalamus, parahippocampus, cerebellum, and cortex of the frontal and parietal lobes seen in our patient. A possible mechanism of regional cerebral hypoperfusion is neuronal hypofunction induced by inhibition of GABA_BR by the patient's antibody. This hypothesis is supported by an observation that, in patients with systemic lupus erythematosus with cognitive dysfunction, the decrease in GABA_BR density measured by ¹²³I-Iomazenil SPECT was linked to the decrease in perfusion measured by ^{99m}Tc-ECD SPECT in the cerebral cortex where MRI was normal (Mathieu *et al.* 2010). In a patient with adult-onset Rasmussen's encephalitis, interictal ^{99m}Tc-HMPAO SPECT demonstrated an extensive area of cortical hypoperfusion even in the clinically uninvolved contralateral cerebral hemisphere. The cerebral hemisphere appeared normal on MRI, indicating that SPECT can detect subclinical pathologic process (Leach *et al.* 1999). In addition, the hypoperfused cortical regions were more extensive in our patient when correlated with her neurological findings. Because the hypoperfused regions showed good agreement with the anti-GABA_BR antibody-binding regions (Lancaster *et al.* 2010), anti-GABA_BR antibody may cause local hypoperfusion that may not be accompanied by neurological symptoms. In contrast, the motor area and left temporal lobe, where SPECT revealed increased uptake in our patient, may be implicated in convulsive seizures, orolingual dyskinesia, and Wernicke aphasia. Positron emission tomography (PET) with flumazenil, a specific antagonist of the benzodiazepine binding site of GABA_AR, demonstrated that hypofunction of the inhibitory GABA system in the cerebral cortex is accompanied by

neurologic manifestations and local hyperperfusion in a patient with acute aseptic encephalitis (Iseki *et al.* 2009). A similar state could be evoked by anti-GABA_BR antibody in our patient. Anyway, precise mechanisms of alterations in cerebral perfusion induced by the anti-GABA_BR antibody remain to be elucidated by the further researches.

References

- Iseki, K., A. Ikeda, T. Kihara, Y. Kawamoto, T. Mezaki, T. Hanakawa, K. Hashikawa, H. Fukuyama, and H. Shibasaki. 2009. Impairment of the cortical GABAergic inhibitory system in catatonic stupor: a case report with neuroimaging. *Epileptic Disord* 11:126–131.
- Lancaster, E., M. Lai, X. Peng, E. Hughes, R. Constantinescu, J. Raizer, D. Friedman, M. B. Skeen, W. Grisold, A. Kimura, *et al.* 2010. Antibodies to the GABA_B receptor in limbic encephalitis with seizures: case series and characterisation of the antigen. *Lancet Neurol* 9:67–76.
- Leach, J. P., D. W. Chadwick, J. B. Miles, and I. K. Hart. 1999. Improvement in adult-onset Rasmussen's encephalitis with long-term immunomodulatory therapy. *Neurology* 52:738–742.
- Mathieu, A., A. Vacca, A. Serra, A. Cauli, M. Piga, G. Porru, F. Marrosu, G. Sanna, and M. Piga. 2010. Defective cerebral gamma-aminobutyric acid-A receptor density in patients with systemic lupus erythematosus and central nervous system involvement. An observational study. *Lupus* 19:918–926.
- Minoshima, S., K. A. Frey, R. A. Koeppe, N. L. Foster, D. E. Kuhl, S. Minoshima, K. A. Frey, and R. A. Koeppe. 1995. A diagnostic approach in Alzheimer's disease using three-dimensional stereotactic surface projections of fluorine-18-FDG PET. *J. Nucl. Med.* 36:1238–1248.