

Renal histopathological alterations induced by nanosilver toxicity: the size effect

Mansour Almansour¹, Qais Jarrar^{2,3}, Abdelkader Battah³, Fatima Obeidat³, Khairat Battah³, Bashir Jarrar⁴ ✉

¹Nanotoxicology Center, Deanship of Scientific Research, King Saud University, Riyadh 11451, Saudi Arabia

²Pharmacology and Toxicology Department, School of Medicine, Putra University, Serdang 43400, Malaysia

³Pathology and Forensic Medicine Department, School of Medicine, Jordan University, Amman 11942, Jordan

⁴Biology Department, College of Science, Jerash University, Jerash 2615, Jordan

✉ E-mail: bashirjarrar@yahoo.com

Published in Micro & Nano Letters; Received on 18th July 2016; Revised on 26th August 2016; Accepted on 13th September 2016

Nanosilver is widely used in medicine, industry, and other applications where it poses a high potential risk for human health, even though little information is available on its toxicity to vital organs. This study was conducted to determine the histopathological changes induced in renal tissues by various sizes of silver nanoparticles (SNPs). Male BALB/C mice were exposed to various sizes of SNPs for 5 weeks. Renal tissue samples from all members of all experimental groups were subjected to histological processing and histopathological examination. SNPs caused glomerular and tubular alterations in the form of tubular degeneration, necrosis, eosinophilia, glomerular shrinkage, and Bowman's capsule thickening. Moreover, SNPs induced interstitial intertubular regeneration, mononuclear inflammatory cell infiltration, proteinaceous casting, and fibrocyte proliferation. These results indicated that smaller particles (10 and 20 nm) were more toxic than the larger ones (40, 60, and 100 nm). In addition, the cortex was more affected than the medulla, and the proximal tubules were more affected than the distal ones. The results of the current investigation reveal that SNPs induce histomorphological alterations in renal tissues, with size being a key factor in the toxicity of these particles.

1. Introduction: Silver nanoparticles (SNPs) are widely used in industry, nanomedicine, consumer products, and some household appliances due to their unique properties [1]. These particles are used in surgical instruments, vascular and urinary catheters, contraceptive devices, medical masks, bone cement, dental resin composite, cosmetics, shampoos, and laundry detergents [2]. Moreover, nanosilver is used to coat refrigerators, air conditioners, washing machines, and other appliances [1]. In addition, SNPs are used in many products currently on the market including medical shoes, sport shirts, toys, baby pacifiers, humidifiers, and food storage containers [3]. Finally, SNPs are used in biological and chemical sensors, in bioengineering, and in some water filters in order to clean infected water [4].

Silver nanomaterials have unique properties including optical and spectral ones due to luminescence electron effect [5]. These nanomaterials can be synthesised by variety of conventional and unconventional techniques such as laser ablation, chemical reduction, microwave processing, gamma irradiation, photochemical techniques, and biological methods [6].

SNPs have unusual physiochemical properties related to their size, shape, large surface area, and chemical composition [7]. These particles can pass through the blood–brain barrier, cell membranes, endothelial membranes, and the placenta, and they can reach target sites and specific cells in vital organs [8]. Small SNPs persist longer in circulation and pass into neighbouring tissues from the vasculature more slowly than larger ones; they can also avoid being recognised and eliminated by the immune system [9]. Moreover, SNPs can penetrate vascular capillaries, giving them the potential to induce oxidative stress and to interact with tissues, cells, and macromolecules.

Some toxicological studies have concluded that induced SNP effects may result from the interaction of their charged ions and functional groups with tissue components and cell macromolecules, producing hydrogen peroxide and depletion of dissolved oxygen and protons [10]. Moreover, *in vitro* toxicological investigation reported that SNPs could produce reactive oxidative species (ROS) that could damage plasma membranes and cell organelles

with the possibility of cytoskeletal disruption and mitochondrial damage [11].

SNPs are becoming prevalent in the human ambient environment due to the widespread use of these nanoparticles (NPs) in many sectors, especially industry and nanomedicine. This poses potential risks to the environment and to human health. These concerns must be assessed so that fully informed decisions can be made regarding any risks or toxicological issues.

High blood flow to the kidneys makes the renal tissues susceptible to high exposure and accumulation of SNPs [12]. Tubular basophilia was observed in the kidneys of F_{344} rats following exposure to SNPs (56 nm) for 3 months [13]. Other research revealed significant inflammatory cell infiltration in the cortex of the kidneys of mice subjected orally to 1 mg/kg of SNPs (42 nm) over a period of 4 weeks [14]. Little is known about the toxicity of various sizes of SNPs in the renal tissues. The aim of this study was to determine any abnormalities in the renal tissues that might result from accumulation of different sizes of these NPs.

2. Materials and methods: BALB/C male mice with an average weight of 25 g were used throughout the current investigation. Mice were divided into one control group and five treatment groups of seven mice each. Animals were housed under standard environmental conditions ($24 \pm 1^\circ\text{C}$ and light–dark cycle of 12 h each). Food and tap water were available *ad libitum* for all groups throughout the duration of the experiment.

SNPs of various sizes (10, 20, 40, 60, and 100 nm; Sigma-Aldrich, USA) were utilised at a concentration of 0.02 mg/ml in aqueous citrate buffer. NP size was confirmed by scanning electron microscope (College of Science, King Saud University). The ultraviolet and visible absorption spectrum of the SNPs was determined (Shimadzu 1650), together with the stacking geometry of citrate molecules and the sizes of the used NPs, as seen in Fig. 1.

Following a 1-week period of stabilisation, all members of all groups were intraperitoneally injected daily with a single dose (1 mg/kg body weight) of SNPs (10, 20, 40, 60, or 100 nm) or control solution (citrate buffer with no SNPs) for 35 days.

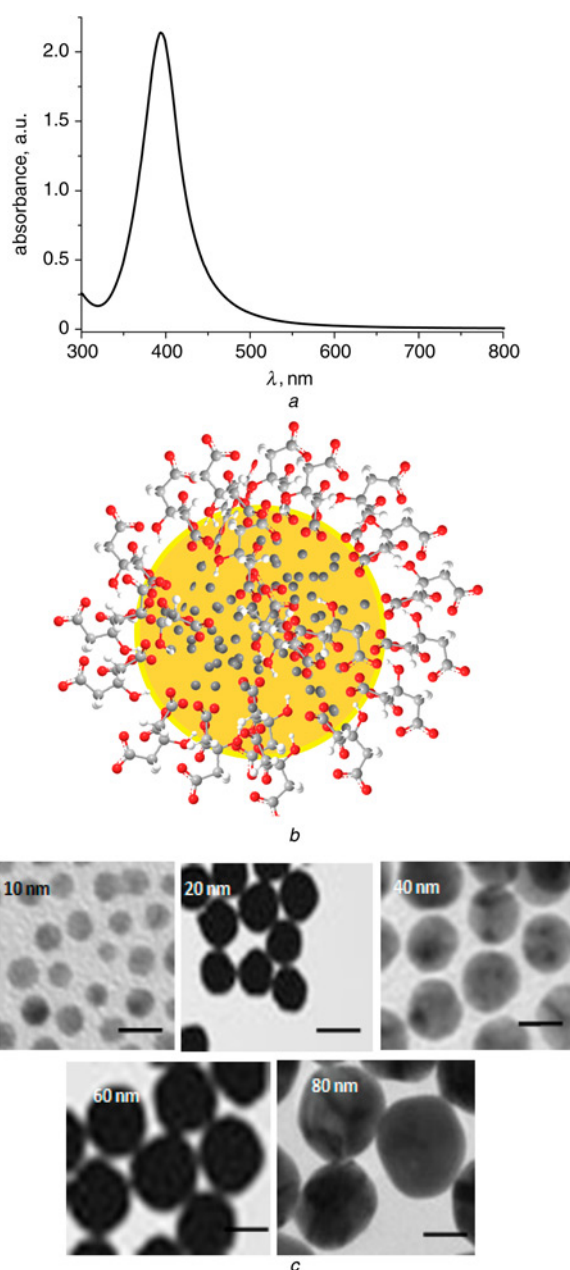


Fig. 1 Features of SNPs used in this Letter

a Plot diagram showing ultraviolet-visible spectrum of the SNPs. Note the maximum absorption peak (~ 400 nm), which corresponds with the normal absorption spectrum of SNPs

b Geometry of citrate molecule stacking on the SNP surface

c Scanning electron micrographs demonstrating spherical morphology and sizes of used SNPs. Scale = 20 nm

All experiments were conducted according to protocols approved by the Bioethical Committee of the University of Jordan. Furthermore, the experimental mice and laboratory procedures were conducted according to international animal care standards.

Biopsies from the left kidney of each mouse, including the cortex and medulla, were excised rapidly and processed for fixation with buffered formalin (10%), dehydrated with ethanol, cleared with chloroform, and impregnated with paraffin wax before being embedded and blocked. Kidney paraffin sections ($4\text{--}5\ \mu\text{m}$) from all experimental mice were used for haematoxylin and eosin (H&E) staining and other special histological treatments according to Jarrar and Taib [15].

Additional small pieces from the left kidney from each mouse were excised rapidly, cut into small cubes 1 mm in length, and

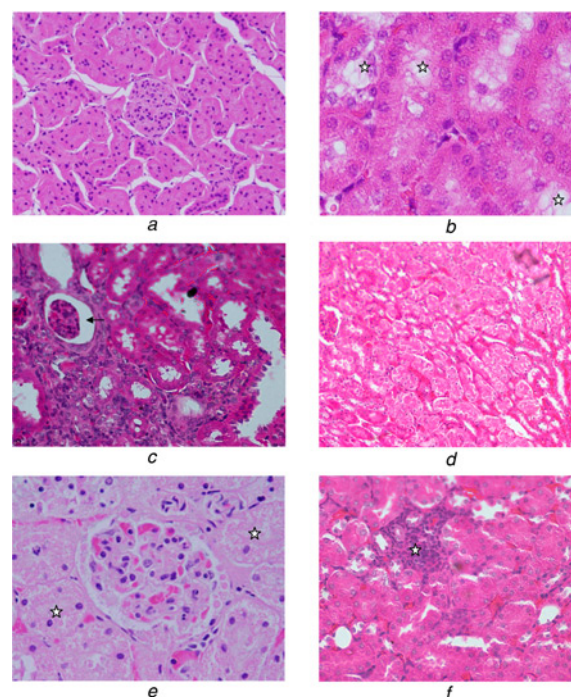


Fig. 2 Light micrograph of the kidney of mouse

a Light micrograph of the kidney of a control mouse demonstrating normal glomeruli and renal tubules. H&E, $400\times$

b Light micrograph of the kidney of a mouse subjected to SNPs (10 nm) for 35 days, demonstrating hydropic degeneration (stars). H&E, $750\times$

c Light micrograph of the kidney of a mouse subjected to SNPs (10 nm) for 35 days, demonstrating glomerular atrophy (arrow). H&E, $400\times$

d Light micrograph of the kidney of a mouse subjected to SNPs (10 nm) for 35 days, demonstrating intertubular regeneration. H&E, $270\times$

e Light micrograph of the kidney cortex of a mouse subjected to SNPs (20 nm) for 35 days, demonstrating tubular necrosis (stars). H&E, $640\times$

f Light micrograph of the kidney cortex of a mouse subjected to SNPs (60 nm) for 35 days, demonstrating mononuclear inflammatory cell infiltration (star). H&E, $400\times$

fixed in phosphate buffered glutaraldehyde (2.5%, pH 7.4, at 4°C) for 24 h. Specimens were then post-fixed in 2% osmium tetroxide (OsO_4) and dissolved in cacodylate buffer for 90 min at $22\text{--}25^\circ\text{C}$. Tissue blocks were dehydrated at 4°C through a gradual ascending concentration of acetone and blocked in Epon-Araldite resin mixture [16]. Semi-thin sections ($500\text{--}1000$ nm thick) were obtained using a glass knife on a Leica EM UC6 ultramicrotome and stained with toluidine blue (1%).

The histological processing of all renal samples was carried out in the toxicological unit at King Saud University. Histological sections and semi-thin sections of the kidneys of all control and SNP-treated mice were examined using an Olympus light microscope. Digital photography was conducted using an Olympus optical microscope with a digital camera.

3. Results: No mortalities or signs of toxicity were detected in any experimental mice. Moreover, no macroscopic anomalies were seen in terms of the morphology or behaviour of mice subjected to treatment with SNPs.

Kidneys of the control mice revealed normal glomeruli together with normal proximal and distal renal tubules. Moreover, the collecting tubules and loops of Henle also demonstrated normal characteristics (Fig. 2*a*).

In contrast, kidneys of mice subjected to treatment with 10 nm SNPs for 35 days demonstrated histological alterations. This included mild hydropic tubular degeneration in the renal tubules, with proximal convoluted tubules demonstrating more degenerative vacuolisation than distal tubules (Fig. 2*b*).

Table 1 Comparative renal histological alterations induced by different sizes of SNPs after 35 days of exposure

Group	Glomerular alterations		Tubular alterations		Intertubular alterations	
control group	absent	–	absent	–	absent	–
10 nm SNPs group	Bowman's capsule thickening	++	tubular degeneration	++	intertubular regeneration	++
	glomerular shrinkage	++	tubular eosinophilia	++		
20 nm SNPs group	Bowman's capsule thickening	++	tubular degeneration	++	intertubular inflammatory cell infiltration	±
	glomerular shrinkage	++	tubular necrosis	++	fibrocyte proliferation	+
			tubular eosinophilia	+		
			proteinaceous casting	+		
40 nm SNPs group	glomerular tuft congestion	++	absent	–	intertubular congestion	++
60 nm SNPs group	little alteration	±	little alteration	±	inflammatory cell infiltration	+
100 nm SNPs group	absent	–	absent	–	absent	–

–, no alteration; ±, occasional (slight); +, moderate; ++, prominent

In addition, mice treated with 10 nm SNPs exhibited occasional Bowman's capsule thickening. In comparison with the kidneys of control mice, considerable glomerular atrophy was visible in renal tissues of mice exposed to 10 nm SNPs, with a shrunken tuft occupying a small portion of Bowman's space (Fig. 2c).

The distal renal tubule of mice subjected to 10 nm SNPs exhibited intertubular regeneration, with an increase in cell turnover in the renal tubular epithelium resulting from the process of renal tissue repair (Fig. 2d). Finally, some renal tubules in these mice exhibited renal tubular eosinophilia.

Similar to the features observed in the mice treated with 10 nm SNPs, mice subjected to 20 nm SNPs for 35 days demonstrated degenerative renal tubules. In addition, the renal tubules showed vacuolation together with tubular necrosis, characterised by narrowing or lack of brush border of the proximal convoluted tubules (Fig. 2e). Some of the vacuolated degenerative tubules demonstrated tubular eosinophilia, while occasional hyaline casts were visible in the distal renal tubules of this group. In addition, occasional scattered infiltration of inflammatory cells was also detected. Moreover, the renal intertubular tissue in this group demonstrated foci of fibrocyte proliferation. Mice of this group also demonstrated glomerular shrinkage with prominent Bowman's capsule thickening.

Mice treated with 40 nm SNPs demonstrated renal intertubular congestion and congested glomerular tuft with little or no alterations in the renal tubules and interstitial tissues. The renal tissues of mice treated with 60 nm SNPs showed little tubular, glomerular, or interstitial alterations. Furthermore, focal and disperse mononuclear inflammatory cell infiltration was more prominent in the renal tissues of this group of mice than in those exposed to smaller NPs (Fig. 2f). Finally, little histological alterations, if any, were seen in the renal tissues of mice subjected to 100 nm SNPs for 35 days.

Semi-quantitative comparison of the above histological changes resulting from treatment with SNPs of varying sizes is shown in Table 1.

4. Discussion: Nanosilver materials have special thermal, electrical, and optical properties, prompting their use in a wide range of applications such as antimicrobial coatings and drug delivery. These properties make SNPs promising and potent components in many industrial, medical, and pharmaceutical items [17]. The number of industrial and commercial products containing SNPs jumped from 30 in 2006 to 1300 in 2014, arousing concerns about their effects on human health and the environment [18].

The kidney performs a wide range of vital functions, primarily involving the removal of wastes and excess water from the body. Our findings demonstrated that sub-chronic treatment with SNPs can cause significant renal morphological changes. These include glomerular, tubular, and interstitial renal alterations induced by

SNPs. Together, such changes may suggest abnormal renal function in mice subjected to nanosilver materials. Some of these histological changes are consistent with previous biochemical studies demonstrating increases in uric acid, creatinine, and urea levels as a result of exposure to SNPs [19]. This indicates that the filtration function of the kidney may be affected by exposure to these fine particles.

Our histopathological data indicated that exposure to SNPs induced more abnormality in the cortex than in the medulla. This may result from an uneven distribution of nanomaterials in the renal tissues, as there is greater blood flow through the cortex than through the medulla. Additionally, our results demonstrated that SNPs induced more injury in the proximal tubules than in the distal ones. This may result from more reabsorption and accumulation of particles in the epithelial lining of the proximal convoluted tubules in comparison to those of the distal tubules.

The glomerular injury induced by SNPs was manifested in shrinkage of some glomerular tufts and glomerular basement membrane thickening that may indicate renal dysfunction. The occurrence of proteinaceous materials in the affected renal tubule lumina may indicate glomerulonephritis. The hydropic degeneration of the renal tubules induced by SNPs may result from hydration changes in the renal tissues. This indicates that SNP exposure could cause renal injury via a reduction in ion pump transport in the lining of the renal tubules, leading to proximal renal tubule degeneration. Moreover, the appearance of regenerated tubules in the kidneys of mice subjected to small SNPs (10 and 20 nm) may indicate tubulotoxic injury.

The resulting inflammatory cell infiltration in renal tissues following SNP exposure suggests that these fine particles may interact with the interstitial tissues of the kidney. This indicates that SNPs may also induce oxidative stress in renal tissues leading to ROS generation and causing an immune response as well as immune-mediated inflammatory injury [20].

Our findings demonstrated that the renal tissues of mice injected with 10 or 20 nm SNPs were more affected than those of mice subjected to treatment with larger particles. These results are in agreement with those of previous studies. Nanosilver materials of different sizes exhibit diverse kinetics, and size is thought to be a key factor in the toxicity of these NPs [21]. The high surface area-to-volume ratio of small NPs enables them to circulate in the renal tissues for a longer period than larger particles. In addition, smaller NPs may potentially exhibit more toxicity due to their dissolution rate, reactive surface area, and bioavailability [22]. Previous nanotoxicological studies reported that the greater relative surface area of the smaller nanoparticles enables them to release more silver ions than the larger particles, inducing more oxidative stress on tissue components [23]. Moreover, the oxidative stress induced by the smaller NPs produces more free radicals, reducing the oxygen content of the tissue and thereby leading to intracellular ROS generation [23]. Previous reports indicated that reactive oxygen species can interact with cellular macromolecules,

causing fragmentation of DNA, dysfunction of proteins, and peroxidation of lipids and leading to ultrastructural pathological changes [24]. Furthermore, SNP toxicity may be related to the neutralisation of the released silver ions by binding with ultrastructural cellular components [10, 14].

Reduced particle size also induces changes in structural and electronic properties of the particle, creating reactive groups on their surfaces. This enables small particles to interact with tissues and to generate more free radicals via Fenton-type reactions, inducing more damage to cellular organelles. Furthermore, small particles can also adsorb some cellular proteins on their surface, causing NP-protein coronas. This may lead to a plasmonic effect where these particles convert electromagnetic radiation into local heat, which may further injure tissues [25].

5. Conclusion: We conclude from these findings that exposure to SNPs may produce histopathological changes in the structure and function of the kidney, with probable impact on the inflammatory and immune system. In addition, our results suggest a key role of particle size in the induced toxicity, where small SNPs induce a more toxic effect than larger ones. Furthermore, differently sized SNPs may demonstrate different toxicokinetics. More work is needed to elucidate the toxicity of SNPs implication on humans and the environment.

6. Acknowledgment: This research was funded by the Scientific Research Deanship at King Saud University (IRG14-06).

7 References

- [1] Luoma S.N.: 'Silver nanoparticles and the environment: old problems or new challenges?', Project on Emerging Nanotechnology. Woodrow Wilson International Center for Scholars, The PEW Charitable Trust. Publication PEN 15, 2008
- [2] Jain J., Arora S., Rajwade J., *ET AL.*: 'Silver nanoparticles in therapeutics: development of an antimicrobial gel formulation for topical use', *Mol. Pharm.*, 2009, **6**, pp. 1388–1401
- [3] Hanson J.: 'Nano silver legal petition: 300 nano silver products' (International Center for Technology Assessment, Washington DC, 2011)
- [4] Ahamed M., Alsalihi M.S., Siddiqui M.K.: 'Silver nanoparticle applications and human health', *Clin. Chim. Acta*, 2010, **411**, (23-24), pp. 1841–1848
- [5] Jiang Z., Yuan W., Pan H.: 'Luminescence effect of silver nanoparticle in water phase', *Spectrochim. Acta A*, 2005, **61**, (11-12), pp. 2488–2494
- [6] Iravani S., Korbekandi H., Mirmohammadi S.V., *ET AL.*: 'Synthesis of silver nanoparticles: chemical, physical and biological methods', *Res. Pharm. Sci.*, 2014, **9**, (6), pp. 385–406
- [7] De Lima R., Seabra A.B., Durán N.: 'Silver nanoparticles: a brief review of cytotoxicity and genotoxicity of chemically and biogenically synthesized nanoparticles', *J. Appl. Toxicol.*, 2012, **32**, (11), pp. 867–879
- [8] Rosenkranz P.W.: 'The ecotoxicology of nanoparticles in *Daphnia magna*', Presented for PhD, Edinburgh Napier University, Edinburgh, 2010
- [9] Yu M.K., Park J., Jon S.: 'Targeting strategies for multifunctional nanoparticles in cancer imaging and therapy', *Theranostics*, 2012, **2**, (1), pp. 3–44
- [10] Ma R.C., Levard C., Marinakos S.M., *ET AL.*: 'Size-controlled dissolution of organic-coated silver nanoparticles', *Environ. Sci. Technol.*, 2012, **46**, pp. 752–759
- [11] Schrand A.M., Bradich-Stolle L.K., Schlager J.J., *ET AL.*: 'Can silver nanoparticles be useful as potential biological labels?', *Nanotechnology*, 2008, **19**, pp. 1–13
- [12] Austin C.A., Umbreit T.H., Brown K.M., *ET AL.*: 'Distribution of silver nanoparticles in pregnant mice and developing embryos', *Nanotoxicology*, 2011, **6**, pp. 912–922
- [13] Kim Y.S., Song M.Y., Park J.D., *ET AL.*: 'Subchronic oral toxicity of silver nanoparticles', *Part. Fibre Toxicol.*, 2010, **7**, pp. 20–20
- [14] Park E.J., Bae E., Yi J., *ET AL.*: 'Repeated-dose toxicity and inflammatory responses in mice by oral administration of silver nanoparticles', *Environ. Toxicol. Pharmacol.*, 2010, **30**, (2), pp. 162–168
- [15] Jarrar B.M., Taib N.: 'Histocytotechnology' (King Saud University Press, Riyadh, 2008, 3th edn.)
- [16] Hayat M.A.: 'Principles and techniques of electron microscopy, biological applications' (Cambridge University Press, Cambridge, UK, 2000, 4th edn.)
- [17] Kalantzi O.I., Biskos G.: 'Methods for assessing basic particle properties and cytotoxicity of engineered nanoparticles', *Toxics*, 2014, **2**, pp. 79–91
- [18] Pineda L., Chwalibog A., Sawosz E., *ET AL.*: 'Effect of silver nanoparticles on growth performance, metabolism and microbial profile of broiler chickens', *Arch. Animal Nutr.*, 2012, **66**, (5), pp. 416–429
- [19] Jarrar Q., Battah A., Obeidat F., *ET AL.*: 'Biochemical changes induced by the toxicity of variable sizes of silver nanoparticles', *Br. J. Pharmacol. Res.*, 2014, **4**, (24), pp. 2670–2678
- [20] Johar D., Roth J.C., Bay G.H., *ET AL.*: 'Inflammatory response, reactive oxygen species, programmed (necrotic-like and apoptotic) cell death and cancer', *Rocz. Akad. Med. Białymst.*, 2004, **49**, pp. 31–39
- [21] Seki J., Sonoke S., Saheki A., *ET AL.*: 'A nanometer lipid emulsion, lipid nano-sphere (LNS), as a parenteral drug carrier for passive drug targeting', *Int. J. Pharm.*, 2004, **273**, pp. 75–83
- [22] Nel A.E., Meadler L., Velegol D., *ET AL.*: 'Understanding biophysicochemical interactions at the nano-bio interface', *Nat. Mater.*, 2009, **8**, pp. 543–557
- [23] Liu J., Hurt R.H.: 'Ion release kinetics and particle persistence in aqueous non-silver colloids', *Environ. Sci. Technol.*, 2010, **44**, pp. 2169–2175
- [24] Pryor W.A., Stone K.: 'Oxidants in cigarette smoke. Radicals, hydrogen peroxide, peroxyxynitrate, and peroxyxynitrite', *Ann. New York Acad. Sci.*, 1993, **686**, pp. 12–28
- [25] Duran N., Silveira C.P., Duran M., *ET AL.*: 'Silver nanoparticle protein corona and toxicity: a mini-review', *J. Nanobiotechnol.*, 2015, **13**, p. 55