

## Case Report

# Candidal emphysematous pyelonephritis: A case report on rare and challenging clinical entity

Bibechan Thapa  and Narayan Bhusal

KIST Medical College and Teaching Hospital, Lalitpur, Nepal

### Abbreviations & Acronyms

CT = computerized tomography  
DOA = day of admission  
Inj. = injection  
KUB = kidney ureter bladder  
MRI = magnetic resonance imaging  
USG = ultrasonography  
UTI = urinary tract infection

**Correspondence:** Bibechan Thapa M.B.B.S., Kirtipur-6, Kathmandu Nepal. Email: bibechanthapa@gmail.com

**How to cite this article:** Thapa B, Bhusal N. Candidal emphysematous pyelonephritis: A case report on rare and challenging clinical entity. *IJU Case Rep.* 2021; 4: 259–262.

This is an open access article under the terms of the Creative Commons Attribution-NonCommercial-NoDerivs License, which permits use and distribution in any medium, provided the original work is properly cited, the use is non-commercial and no modifications or adaptations are made.

Received 23 December 2020; accepted 16 April 2021.  
Online publication 9 May 2021

**Introduction:** Emphysematous pyelonephritis is a rare, severe acute necrotizing infection characterized by the presence of gas within the renal parenchyma, collecting system, and perirenal tissue. It is an aggressive disease with high morbidity and mortality. Patients have female preponderance and commonly have uncontrolled diabetes. It is caused most commonly by *Escherichia coli* and very rarely by *Candida* species. Unlike others, candidal emphysematous pyelonephritis has an indistinctive presentation and diagnosed late, thus delaying prompt treatment.

**Case presentation:** A 35-year-old Type 2 diabetic woman developed pyelonephritis. Computerized tomography revealed the gas in the renal parenchyma, establishing the diagnosis. Cultures isolated *Candida albicans* as a causative organism. The patient was treated successfully with nephrectomy as initial medical therapy and percutaneous nephrostomy failed.

**Conclusion:** Rare causative agent should be suspected if clinical presentation is indistinctive and conservative management fails. Nephrectomy is still preferred in such patients.

**Key words:** *Candida albicans*, candidal emphysematous pyelonephritis, diabetes, nephrectomy, percutaneous nephrostomy.

## Keynote message

Candidal EPN can have an indistinctive presentation, resulting in delayed treatment. Rare microorganisms like *Candida* should be suspected if the patient does not respond to initial antibiotics. Nephrectomy is still preferred if the initial medical management and percutaneous nephrostomy fail.

## Introduction

EPN is an acute severe necrotizing infection of the renal parenchyma and its surrounding tissues that results in the presence of gas in the renal parenchyma, collecting system, or perinephric tissue.<sup>1</sup> It was first described by Kelly and MacCullem,<sup>2</sup> whereas Schultz and Klorfein introduced the term emphysematous pyelonephritis.<sup>3</sup> It is an aggressive disease accounting of about 90% mortality and higher morbidity rates.<sup>4</sup> Women outnumbered men (41:7), and 96% patients had diabetes.<sup>5</sup>

The most common causative pathogen is *Escherichia coli* (70%); other less common include *Proteus mirabilis*, *Klebsiella pneumoniae*, and more rarely *Candida albicans*. Management of EPN is highly debatable between conservative medical management and surgical approach.<sup>1,6</sup> Candidal EPN, though very rare, has been reported.<sup>7–9</sup>

## Case presentation

A 35-year-old diabetic female, noncompliant to medications, had a surgical removal of renal stone (right) 8 years back presented to the emergency room with diffuse abdominal pain, lower back pain, and generalized body ache for last 7 days. There was no history of fever,

dysuria, hematuria, or pneumaturia. She was afebrile with stable vitals. The abdomen and renal angle were non-tender.

She was admitted for a high blood sugar level (Table 1) and was managed with intravenous fluids and insulin. On the fourth DOA, she developed fever (38.9°C) with chills and rigor and right flank pain with renal angle tenderness. Urine showed pyuria, but two urine cultures failed to grow any organism. She has normal renal function throughout. The patient was managed with Inj. levofloxacin and Inj. amikacin for UTI. X-ray KUB was unremarkable, whereas the USG showed moderate hydronephrosis of the right kidney with internal echoes and collection in right renal fossa adjacent to the right kidney measuring 8.4 × 4.9 cm. CT KUB showed the right moderate hydronephrosis with small streaks of air in the right renal parenchyma (Fig. 1) and collection posterior to the right kidney with foci of air extending to the right psoas muscle (Fig. 2). There was no evidence of renal/ureteric calculi, thus confirming diagnosis of EPN.

MRI revealed a large well-circumscribed multiloculated collection with a fluid level in the right lumbar region with the involvement of right psoas muscle. USG-guided percutaneous nephrostomy was performed with 14-Fr pigtail catheter on the 7th DOA, and pus was sent for culture. Conservative treatment was continued in order to preserve the kidney. Urine and pus (pigtail drain) cultures isolated *C. albicans* as a causative organism on 9th DOA. Hence, fluconazole therapy was instituted.

Despite nephrostomy and antibiotics, the patient deteriorated clinically into septic shock (Table 1). Right-sided subcapsular nephrectomy with the evacuation of the perinephric abscess (approx. 1500 mL) was performed on 15th DOA.

Pus culture from the operative specimen also isolated of *C. albicans*. Histopathology of the specimen was consistent with acute pyelonephritis.

Subsequently, she was discharged with insulin and linagliptin–metformin therapy. Patient was followed up for 2 years. She had good glycemic control and normal renal function.

## Discussion

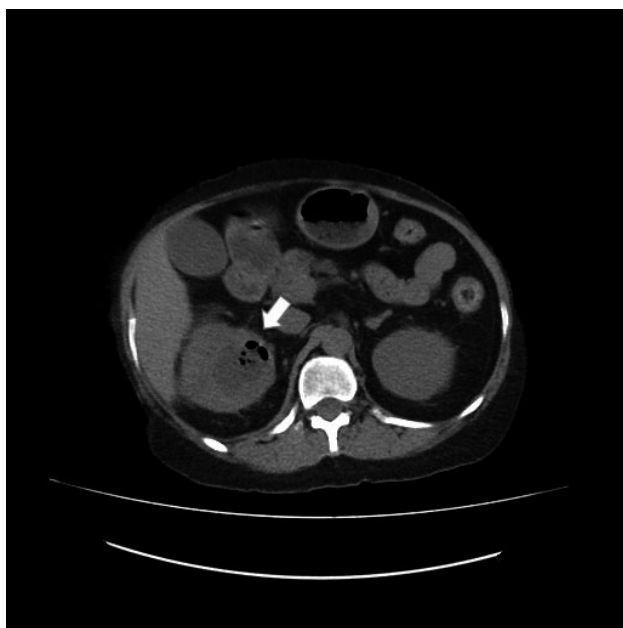
EPN caused by *C. albicans* is rare, and few cases have been reported with the outcome of successful treatment as well as mortality.<sup>7–9</sup>

A case of a 39-year-old diabetic female with hyperglycemia and urine culture isolating *Candida* species was reported by MA Hussein et al.<sup>8</sup> The patient was initially managed with aggressive conservative therapy, but urgent nephrectomy was performed as patient deteriorated. The patient showed remarkable improvement. MD Kamaliah et al.<sup>9</sup> also reported a case of a diabetic patient with extensive unilateral emphysematous pyelonephritis caused by *C. albicans*. The patient underwent nephrectomy as she deteriorates despite parenteral broad-spectrum antibiotics and antifungal management. Following nephrectomy, she made a good clinical recovery. On contrary, Bayrak et al.<sup>7</sup> reported EPN in a 46-year-old diabetic patient whose urine culture isolated *C. albicans*, but despite appropriate antifungal treatment and extensive debridement, patient died due to septic complications.

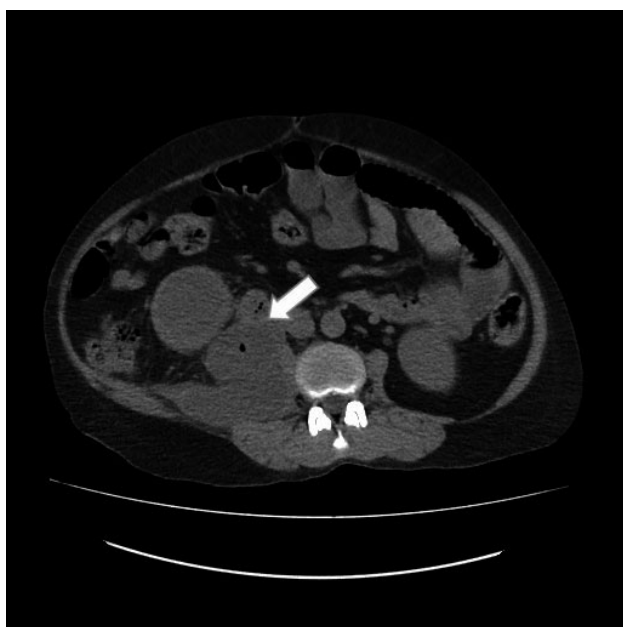Diabetic patients are more prone to UTI due to immunocompromised state. Some diabetic people develop EPN,

**Table 1** Laboratory investigations

Laboratory parameters (normal range for adult female)	At admission	At nephrostomy (7th day of admission)	Preoperative (14th day of admission)
<b>Blood counts</b>			
Hemoglobin (12–15) g/dL	12 g/dL	10.9 g/dL	7.5 g/dL
Total leucocyte count (4000–11 000)/cumm	8900/cumm	10 000/cumm	12 200/cumm
Neutrophil (45–75)%	73%	81%	87%
Lymphocyte (20–45)%	24%	18%	13%
Eosinophils (0–6)%	3%	01%	0
Platelets (150 000–450 000)/cumm	383 000/cumm	457 000/cumm	399 000/cumm
ESR (<1 mm/h)	55 mm/h	68 mm/h	
<b>Blood sugar profile</b>			
Fasting blood sugar (<100 mg/dL)	170 mg/dL	318 mg/dL (random <200 mg/dL)	
Postprandial blood sugar (<140 mg/dL)	520 mg/dL		
HbA1C (<6.3%)	13.9%		
<b>Urine routine and microscopy</b>			
White blood cells (<2–5 cells)/HPF (high power field)	Plenty	Plenty	
Red blood cells (nil)	Nil	Nil	
Sugar (nil)	Trace	Nil	
Acetone (negative)	Negative	Negative	
<b>Renal function test</b>			
Urea (10–40) mg/dL	28 mg/dL	18 mg/dL	18 mg/dL
Creatinine (0.3–1.2) mg/dL	0.7 mg/dL	0.6 mg/dL	0.7 mg/dL
Sodium (135–146) mmol/L	135 mmol/L	137 mmol/L	138 mmol/L
Potassium (3.5–5.2) mmol/L	3.9 mmol/L	4 mmol/L	4.4 mmol/L



**Fig. 1** Right moderate hydronephrosis with small streaks of air in right renal parenchyma.



**Fig. 2** The collection is posterior to the right kidney with foci of air extending to the right psoas muscle.

whereas others simply develop conventional UTI. Huang and Tseng<sup>5</sup> postulated four factors that are involved in the pathogenesis of EPN which includes gas-forming bacteria, high tissue glucose level, impaired tissue perfusion, and defective immune response. Our patient had uncontrolled diabetes as she was uncomplicated with diabetic medications which predisposed her to develop EPN.

Our patient initially presented with diffuse abdominal and lower back pain however fever, and renal angle tenderness

were absent. On 4th DOA, the patient developed fever, right flank pain, and renal angle tenderness. Similar findings were reported by Sharma P et al.<sup>6</sup> As ours was candidal EPN, it had an indistinctive presentation.

EPN is diagnosed radiologically, with CT being the most definitive modality. Abdominal X-ray and USG can also be used for diagnosis. A plain radiograph of the abdomen will show a crescent-shaped radiolucent shadow, but it was inconclusive in our patient. On USG, enlarged kidneys with parenchymal destruction and echogenic gas locules will be seen within the renal parenchyma, while the casting of dirty shadows will be seen in the perirenal area.<sup>10</sup> CT images are most useful to show the presence of gas and define its extent and position within the renal parenchyma. CT scan also facilitates monitoring of the response to treatment.<sup>6</sup>

Huang and Tseng<sup>5</sup> used CT scan to classify patients with EPN that signified prognostic value and also helped in selecting a management protocol. Patients belonging to Class III or IV, who had less than two risk factors (i.e., thrombocytopenia, acute renal function impairment, and disturbance of consciousness and shock) had an 85% survival rate after being managed with percutaneous procedures and adequate medical therapies, whereas those who had two or more risk factors had 92% failure rate with the same therapy. Our patient falls in Class IIIB (i.e., extension of gas into the pararenal space) but had no risk factor. Our patient was initially managed with medical therapies and percutaneous nephrostomy, but it failed, and she underwent nephrectomy.

## Conclusion

Candidal EPN can have an indistinctive presentation, resulting in delayed administration of treatment. Rare microorganisms like *Candida* should be suspected if the patient does not respond to initial antibiotics. Treatment modalities should be changed accordingly to culture reports and clinical judgments. Nephrectomy is still preferred if the initial medical management and percutaneous drainage fail.

## Acknowledgment

The authors are grateful to Dr. Narayan Bhusal for his thoughtful insight and guidance.

## Conflict of interest

The authors declare no conflict of interest.

## References

- 1 Ubee S, McGlynn L, Fordham M. Emphysematous pyelonephritis. *BJU Int.* 2010; **107**: 1474–8.
- 2 Kelly HA. Pneumaturia. *J. Am. Med. Assoc.* 1898; **XXXI**: 375.
- 3 Schultz E, Klorfein E. Emphysematous pyelonephritis. *J. Urol.* 1962; **87**: 762–6.
- 4 Tsitouridis I, Michaelides M, Sidiropoulos D, Arvanity M. Renal emphysema in diabetic patients: CT evaluation. *Diagn. Intervent. Radiol.* 2009; **16**: 221–6.
- 5 Huang J, Tseng C. Emphysematous pyelonephritis. *Arch. Intern. Med.* 2000; **160**: 797–805.

- 6 Sharma P, Sharma R, Vijay M, Tiwari P, Goel A, Kundu A. Emphysematous pyelonephritis: our experience with conservative management in 14 cases. *Urol. Ann.* 2013; **5**: 157.
- 7 Bayrak O, Seckiner I, Bulut E, Erturhan S. Emphysematous pyelonephritis caused by *Candida* species: first case in the English literature. *Türk Üroloji Dergisi/Turk. J. Urol.* 2012; **38**: 244–5.
- 8 Mohamed A, Mohamud H. Emphysematous pyelonephritis caused by *Candida* species: A case report and outcome of 1 year follow-up. *Urol. Case Rep.* 2020; **30**: 101113.
- 9 Kamaliah M, Bhajan M, Abu Dzarr G. Case report emphysematous pyelonephritis caused by *Candida* infection. ResearchGate. 2005. [Cited 2 Mar 2020.] Available from URL: [https://www.researchgate.net/publication/7637116\\_Emphysematous\\_pyelonephritis\\_caused\\_by\\_Candida\\_infection](https://www.researchgate.net/publication/7637116_Emphysematous_pyelonephritis_caused_by_Candida_infection)
- 10 Chou Y, Tiu C, Chen T, Chen K, Chang T. Emphysematous pyelonephritis in a polycystic kidney. Demonstration by ultrasound and computed tomography. *J. Ultrasound Med.* 1990; **9**: 355–7.