

## Case Report

# Improvement of urinary symptoms after bladder biopsy: A case of pathologically proven allergy-related cystitis during administration of nivolumab

Shugo Yajima,  Yasukazu Nakanishi, Shunya Matsumoto, Kenji Tanabe, Masato Sugano and Hitoshi Masuda

National Cancer Center Hospital East, Kashiwa, Chiba, Japan

### Abbreviations & Acronyms

CT = computed tomography  
CTCAE = Common Terminology Criteria for Adverse Events  
EGF = epidermal growth factor  
HB-EGF = heparin-binding EGF-like growth factor  
HPF = high-power field  
IO = immuno-oncology  
irAE = immune-related adverse event  
PD-1 = programmed cell death protein 1  
WBC = white blood cells

**Correspondence:** Yasukazu Nakanishi M.D., Ph.D., National Cancer Center Hospital East, 6-5-1 Kashiwanoha, Kashiwa-shi, Chiba 277-8577, Japan. Email: yanakani@east.ncc.go.jp

**How to cite this article:** Yajima S, Nakanishi Y, Matsumoto S, Tanabe K, Sugano M, Masuda H. Improvement of urinary symptoms after bladder biopsy: A case of pathologically proven allergy-related cystitis during administration of nivolumab. *IJU Case Rep.* 2021; 4: 213–215.

This is an open access article under the terms of the Creative Commons Attribution-NonCommercial-NoDerivs License, which permits use and distribution in any medium, provided the original work is properly cited, the use is non-commercial and no modifications or adaptations are made.

Received 21 January 2021;  
accepted 10 March 2021.  
Online publication 23 March 2021

**Introduction:** We present a case of cystitis, which was considered to be an immune-related adverse event associated with nivolumab administration.

**Case presentation:** A 47-year-old man suffered from sudden onset urinary symptoms after 18 cycles of nivolumab treatment for stage IV pulmonary adenocarcinoma. Urine culture and urine cytology were both negative. The symptoms were inferred to be related to nivolumab administration, and a bladder biopsy under spinal anesthesia was performed. The histopathological examination showed the evidence of allergic-related cystitis. We planned to administer corticosteroids, but the urinary symptoms disappeared after the bladder biopsy. Nivolumab treatment was continued without recurrent bladder symptoms.

**Conclusion:** We reported a case of cystitis after treatment with nivolumab, which served as a reminder to consider the possibility of immune-related adverse events as a potential cause for any symptoms that develop during treatment with immuno-oncology drugs.

**Key words:** adverse drug event, cystitis, lung neoplasms, nivolumab, urinary bladder.

## Keynote message

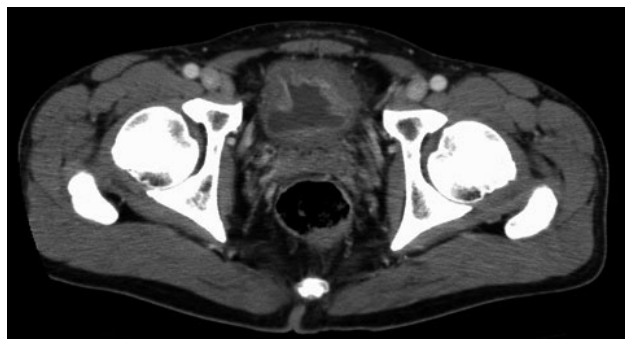
Recent reports have demonstrated that nivolumab, an anti-PD-1 antibody, might affect the urinary tract as irAEs. We presented a case of cystitis due to nivolumab, which was confirmed histopathologically. In this report, it was inferred that bladder distention positively affected the alleviation of urinary symptoms of the patient.

## Introduction

Nivolumab, a PD-1 blocking antibody, is increasingly being used as a drug therapy for various tumors. Nivolumab is known to induce various irAEs, which differ from the adverse events associated with conventional chemotherapy. Common irAEs of nivolumab were reported to be fatigue (34.2%), rash (25.9%), and diarrhea (19.2%).<sup>1</sup> Besides, recent reports have demonstrated that nivolumab might cause irAEs associated with the urinary tract.<sup>2,3</sup> Here, we report a case of cystitis as an irAE associated with nivolumab administration. In this report, the urinary symptoms disappeared after the performance of a bladder biopsy under spinal anesthesia.

## Case presentation

A 47-year-old Japanese male was referred to us complaining of sudden-onset pollakiuria and micturition pain after undergoing 18 cycles of treatment with nivolumab for stage IV pulmonary adenocarcinoma. Urinalysis results were normal before treatment with nivolumab; however, at the time of referral to us, significant pyuria with increased WBCs  $\geq 100$ /HPF were observed. A small quantity of bacteria was present in the urine sediment, but the urine culture



**Fig. 1** CT scan of the abdomen showed diffuse thickening of the bladder wall.

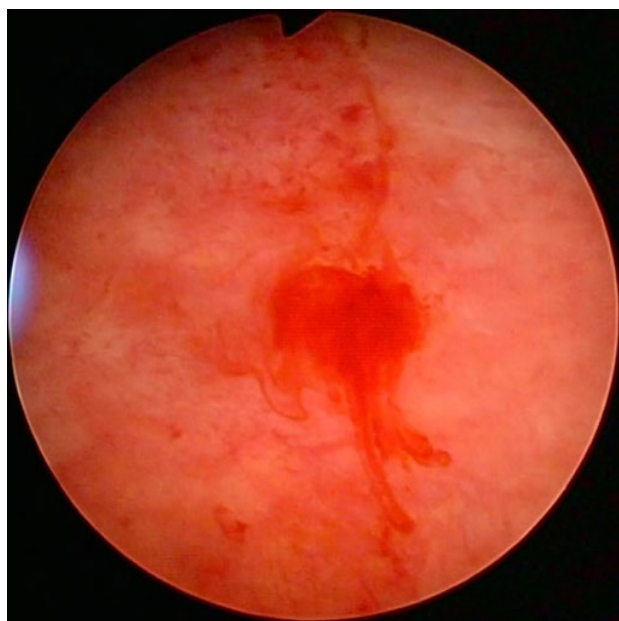
result was not significant ( $<1000$  colony-forming units/mL). A urine cytology test was negative, and blood screening revealed no abnormal findings.

Antibiotics were administered for 14 days, and pyuria alleviated (10–19 WBC/HPF), with no effect on the patient's symptoms. The subsequent administration of anticholinergic agents and nonsteroidal anti-inflammatory drugs following antibiotics treatment slightly improved the symptoms of pollakiuria and micturition pain, but had no major effect. These urinary symptoms were so severe that instrumental activities of daily living were restricted. Cystoscopy showed the erosion and diffuse redness of the bladder mucosa.

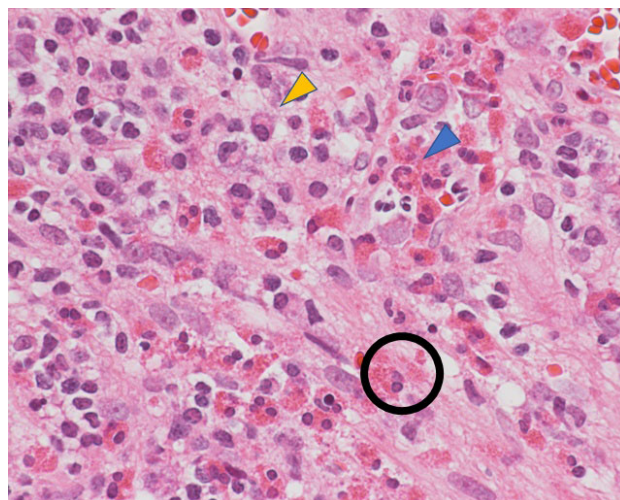
We performed a CT scan of the abdomen and found no abnormal findings in the urinary tract, except for the thickening of the bladder wall (Fig. 1). These symptoms were inferred to be related to nivolumab treatment.

A bladder biopsy under spinal anesthesia was performed. Intraoperative findings showed hemorrhages from the bladder wall after expansion of the bladder. (Fig. 2).

The histopathological examination showed evidence of allergy-related cystitis, including slightly strong inflammatory



**Fig. 2** Cystoscopic finding at bladder biopsy under spinal anesthesia. Hemorrhages were seen from the bladder wall after expansion of the bladder.



**Fig. 3** Histopathological findings. Slightly strong inflammatory cell infiltration mainly composed of eosinophils (blue arrow) and plasma cells (yellow arrow) were observed, and some eosinophils showed degranulation (black round). There was no evidence of malignancy.

cell infiltration that primarily comprised eosinophils and plasma cells, and some eosinophils showed evidence of degranulation (Fig. 3). There was no evidence of malignancy.

He was diagnosed with allergy-related cystitis (CTCAE Grade 2), and we considered the administration of corticosteroids. But the symptoms of pollakiuria and micturition pain disappeared after biopsy; thus, we did not administer corticosteroids. Pyuria gradually alleviated and finally disappeared 3 months after bladder biopsy.

The administration of nivolumab was continued, without recurrent bladder symptoms, until discontinuation after the 37th course due to the request of the patient. During treatment with nivolumab, the routine imaging surveillance of the patient showed no progression of the disease.

## Discussion

Advances in IO have changed the standard of treatment for many types of cancer, and drug development is being rewritten; there are a wide variety of IO drugs that target different steps in the antitumor immune response.

Nivolumab, which blocks the PD-1 receptor, is increasingly being used as drug therapy for various tumors. Nivolumab is known to induce various irAEs throughout the body, and recent reports have demonstrated that nivolumab might affect also the urinary tract as irAEs, although the specific incidence remains unknown.<sup>2,3</sup>

For the treatment of CTCAE Grade 2 or higher irAEs, the administration of IO drugs should be postponed or withdrawn in conjunction with symptomatic treatment. In addition, steroid administration is recommended for CTCAE Grade 2 irAEs lasting longer than 1 week.<sup>4</sup>

In this report, the urinary symptoms of the patient were considered to be irAEs of CTCAE Grade 2 because the instrumental activities of daily living of the patient were restricted. We considered the administration of corticosteroids; however, the symptoms of pollakiuria and micturition

pain disappeared following the performance of a bladder biopsy under spinal anesthesia, making corticosteroid treatment unnecessary. In this case, nivolumab side effects were thought to trigger an autoimmune reaction, resulting in cystitis symptoms. The role played by autoimmune processes in bladder pathophysiology is not yet completely elucidated, although studies have been conducted using various approaches.<sup>5</sup> The underlying cause of urinary symptom alleviation following bladder biopsy, in this case, remains unknown. We suggest the possibility that intraoperative bladder expansion may have had a positive effect on the alleviation of urinary symptoms in this patient.

The mechanism of hydrodistention has been reported to be possibly related to HB-EGF.<sup>6</sup> HB-EGF is a member of the EGF family which plays critical roles in tissue repair and regeneration throughout the body, including in the bladder.<sup>7</sup> In this case, hydrodistention was not performed intentionally during the biopsy under spinal anesthesia; however, the urinary symptoms might have improved due to a mechanism similar to hydrodistention.

This inference has to be seen in light of some limitations. First, we have not measured any urinary biomarkers such as HB-EGF, by enzyme-linked immunosorbent assay before and after the performance of bladder biopsy; thus, we cannot quantitatively support this inference. Second, the degree of bladder distention may not have achieved an effective level because we did not intend to perform hydrodistention but were instead performing a biopsy.

We reported a case of cystitis following treatment with an anti-PD-1 antibody, nivolumab. This case reminds us of the need to consider the possibility of irAEs for any symptoms that develop during the treatment period of IO drugs. Besides, environmental changes that occurred in the bladder

during the bladder biopsy might have had positive impacts on the alleviation of urinary symptoms in this patient.

## Disclosure

All human subjects provided written informed consent with guarantees of confidentiality.

## Conflict of interest

The authors declare no conflict of interest.

## References

- 1 Larkin J, Chiarion-Sileni V, Gonzalez R *et al.* Combined nivolumab and ipilimumab or monotherapy in untreated melanoma. *N. Engl. J. Med.* 2015; **373**: 23–34.
- 2 Shimatani K, Yoshimoto T, Doi Y, Sonoda T, Yamamoto S, Kanematsu A. Two cases of nonbacterial cystitis associated with nivolumab, the anti-programmed-death-receptor-1 inhibitor. *Urol. Case Rep.* 2018; **17**: 97–9.
- 3 Ozaki K, Takahashi H, Murakami Y, Kiyoku H, Kanayama H. A case of cystitis after administration of nivolumab. *Int. Cancer Conf. J.* 2017; **6**: 164–6.
- 4 Kähler KC, Hassel JC, Heinzerling L *et al.* Management of side effects of immune checkpoint blockade by anti-CTLA-4 and anti-PD-1 antibodies in metastatic melanoma. *J. Dtsch. Dermatol. Ges.* 2016; **14**: 662–81.
- 5 Sugino Y, Nishikawa N, Yoshimura K *et al.* BALB/c-Fcgr2b<sup>-/-</sup>-Pdcd1<sup>-/-</sup> mouse expressing anti-urothelial antibody is a novel model of autoimmune cystitis. *Sci. Rep.* 2012; **2**: 317.
- 6 Kim J, Keay SK, Freeman MR. Heparin-binding epidermal growth factor-like growth factor functionally antagonizes interstitial cystitis antiproliferative factor via mitogen-activated protein kinase pathway activation. *BJU Int.* 2009; **103**: 541–6.
- 7 Dao DT, Anez-Bustillos L, Adam RM, Puder M, Bielenberg DR. Heparin-binding epidermal growth factor-like growth factor as a critical mediator of tissue repair and regeneration. *Am. J. Pathol.* 2018; **188**: 2446–56.