

## CASE REPORT

WILEY

Reproductive Medicine and Biology

# Case of heterotopic cervical pregnancy and total placenta accreta after artificial cycle frozen-thawed embryo transfer

Kazuki Saito<sup>1,2</sup>  | Maki Fukami<sup>1</sup> | Mami Miyado<sup>1</sup> | Ichiro Ono<sup>3</sup> | Keijiro Sumori<sup>3</sup>

<sup>1</sup>Department of Molecular Endocrinology, National Research Institute for Child Health and Development, Tokyo, Japan

<sup>2</sup>Department of Comprehensive Reproductive Medicine, Graduate School, Tokyo Medical and Dental University, Tokyo, Japan

<sup>3</sup>Department of Obstetrics and Gynecology, Ome Municipal General Hospital, Tokyo, Japan

## Correspondence

Kazuki Saito, Department of Molecular Endocrinology, National Research Institute for Child Health and Development, Tokyo, Japan.  
Email: saito-kz@ncchd.go.jp

## Abstract

**Case:** A 39-year-old woman presented with a genital hemorrhage at 5 weeks of gestation after an artificial cycle double frozen-thawed embryo transfer. She was diagnosed with a cervical heterotopic pregnancy. Although hormone supplementation was discontinued to terminate the pregnancy at 5 weeks of gestation, the intrauterine and cervical gestational sacs continued to develop.

**Outcome:** The cervical gestational sac was surgically removed and the intrauterine pregnancy continued uneventfully, except for vasa previa. At 36 weeks of gestation, the patient underwent a cesarean section and gave birth to a healthy female infant. At the delivery, massive bleeding occurred and a hysterectomy was performed due to total placenta accreta.

**Conclusion:** This case provides a novel example of a near-term delivery after a cervical heterotopic pregnancy and emphasizes the need for intensive care, even after the successful management of a cervical pregnancy. Most importantly, the present case implies a possible link between hormonal withdrawal and abnormal placentation.

## KEYWORDS

artificial cycle, cervical heterotopic pregnancy, frozen-thawed embryo transfer, placenta accreta, progesterone

## 1 | INTRODUCTION

Circulating progesterone is thought to be essential for the maintenance of uterine quiescence during pregnancy,<sup>1</sup> as well as for decidualization of the endometrium.<sup>2</sup> In the early phase of pregnancy, progesterone is produced predominantly in the corpus luteum.<sup>1</sup> Accordingly, surgical excision of the corpus luteum at 4–6 weeks of gestation has resulted in miscarriage for all of the eight women reported to have undergone this treatment.<sup>1</sup> In general, endogenous progesterone production in the corpus luteum is markedly suppressed during the hormonally induced endometrial preparation ("artificial cycle") for frozen-thawed embryo transfer (FET).<sup>3</sup> Therefore, progesterone supplementation during early pregnancy is recommended for women who conceive by artificial cycle FET.<sup>4</sup>

Cervical heterotopic pregnancy is a rare condition that is defined by the presence of gestational sacs both in the uterus and the cervical canal.<sup>5</sup> This condition occurs primarily as a result of assisted reproductive technologies. To date, cervical heterotopic pregnancies have resulted in a viable delivery of the intrauterine pregnancy in ~30 individuals.<sup>5</sup> However, cervical heterotopic pregnancy frequently leads to genital bleeding and also has been associated with the risk of placental abnormalities.<sup>5</sup> Although the complete evacuation of a cervical pregnancy is recommended for a better pregnancy outcome,<sup>6</sup> the clinical course and possible complications after the evacuation are not fully understood. Herein is reported a unique case of a cervical heterotopic pregnancy that was conceived after artificial cycle FET. The patient successfully gave birth to a full-term infant without receiving any hormone supplementation therapy after 5 weeks of gestation.

This is an open access article under the terms of the Creative Commons Attribution-NonCommercial License, which permits use, distribution and reproduction in any medium, provided the original work is properly cited and is not used for commercial purposes.

© 2017 The Authors. Reproductive Medicine and Biology published by John Wiley & Sons Australia, Ltd on behalf of Japan Society for Reproductive Medicine.

## 2 | CASE REPORT

A 39-year-old woman (gravida 6, para 3-0-3-3) underwent a standard protocol of artificial cycle FET and had been transferred two in vitro fertilization-derived embryos at a fertility clinic. Detailed information about the transferred embryos was not available for this case. The patient had episodes of spontaneous and artificial abortions and a salpingectomy for an ectopic pregnancy, but had no history of a cesarean section. She became pregnant by FET and was treated with progesterone agents, an estrogen patch, and aspirin.

At 5-2/7 weeks of gestation, she presented to our hospital with hemorrhagic shock due to persistent genital bleeding. A transvaginal ultrasonography detected an intrauterine gestational sac of age-appropriate size and a squashed cystic lesion in the cervix. A blood examination indicated a hemoglobin level of 4.8 g/dL. Blood coagulum from the genitalia contained decidual tissues. Her genital bleeding was successfully controlled by manual compression of the external cervical os and the blood pressure and heart rate were stabilized after transfusing four units of red cell concentrates. She was diagnosed with a cervical heterotopic pregnancy. All the medications that had been prescribed at the fertility clinic were withdrawn, with the intention to terminate the pregnancy. However, despite the discontinuation of progesterone supplementation, the gestational sacs in the cervix and uterus continued to develop and formed yolk sacs (Figs 1a and 1b).

At 8 weeks of gestation, the patient expressed her desire to maintain the intrauterine pregnancy, despite being fully informed of the risk of hemorrhage and other complications. As there was growth discordancy in the two pregnancies and the fetal heartbeat was not observed in the gestational sac in the cervical canal,<sup>7</sup> the gestational sac was manually removed with forceps under ultrasound guidance, instead of local potassium chloride injection. The cervical bleeding was

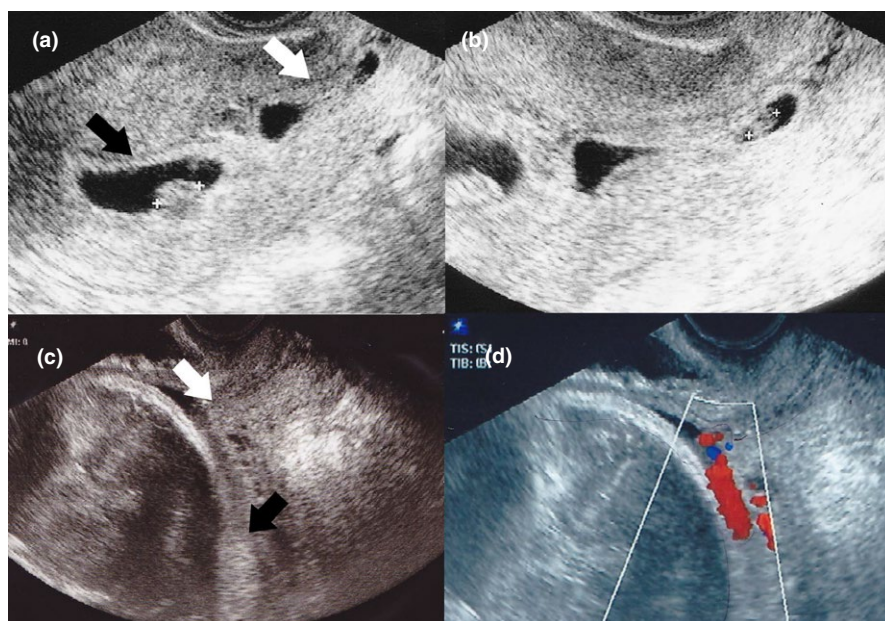
controlled by astriction. Histological analyses of the removed specimen confirmed the presence of fetal tissues.

The subsequent course of the pregnancy was uneventful until delivery, except for a vasa previa that was detected at 28 weeks of gestation (Figs 1c and 1d). In order to avoid the rupture of the vasa previa, a cesarean section was performed at 36 weeks of gestation, which resulted in the birth of a healthy female infant. However, at the delivery, massive bleeding occurred from the region around the internal cervical os. A total hysterectomy was performed because the placenta was not able to be manually separated from the uterus. A histological examination of the uterus indicated a total placenta accreta; placental villi had invaded the myometrium (Figs 2a and 2b). There was no histological abnormality in the cervix or in the region around the internal os.

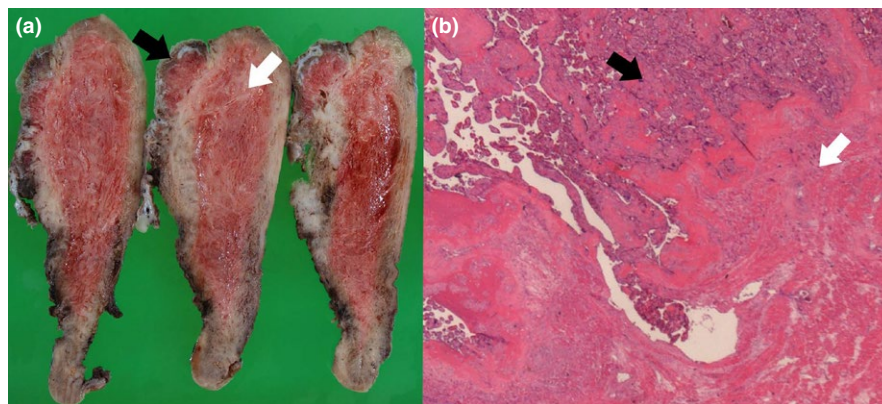
## 3 | DISCUSSION

The present case followed a unique clinical course. The patient developed a cervical heterotopic pregnancy after artificial cycle FET. Although progesterone supplementation was withdrawn at 5 weeks of gestation, the cervical and intrauterine gestational sacs continued to grow. Accordingly, the cervical gestational sac was surgically removed at 8 weeks of gestation and the intrauterine pregnancy resulted in the birth of a healthy infant. This case provides a further example of a live birth after a cervical heterotopic pregnancy. In this regard, a study reported that 14 out of 39 cases (36%) of cervical heterotopic pregnancies resulted in the birth of a full-term infant.<sup>5</sup> Careful clinical management might improve the reproductive prognosis of this condition.

The case in this report indicates that the withdrawal of hormonal support might not be sufficient to abort heterotopic pregnancies after artificial cycle FET in some cases. In this patient, the



**FIGURE 1** Ultrasonographic findings of the patient. (a) and (b) Transvaginal ultrasonography at 7-0/7 weeks of gestation. The gestational sacs in the uterus (black arrow) and cervical canal (white arrow) are shown. The plus signs indicate the fetus. The crown-to-rump lengths were 10.6 mm in the intrauterine pregnancy and 5.6 mm in the cervical pregnancy. (c) and (d) Transvaginal ultrasonography at 31-2/7 weeks of gestation. A lower edge of the placenta (black arrow) was 41 mm apart from the internal os of the uterus (white arrow). The presence of a blood flow that connected the internal os and the lower edge of the placenta was observed. No sign of placenta accreta was observed before the cesarean section



**FIGURE 2** Macroscopic and histological findings of the uterus. (a) Placental tissues (black arrow) invaded the uterine myometrium (white arrow). (b) The trophoblastic villi (black arrow) invaded the myometrium (white arrow)

presence of two placentas might have resulted in excessive progesterone production, compared to women with a single placenta. Another possible explanation for the hormonal compensation is that an estradiol patch might not have been enough to suppress spontaneous follicular growth and ovulation in this patient. In other words, it cannot be denied that unintended follicular growth was overlooked and the follicle ovulated in a timely fashion for FET in this case because patients are monitored a few times before FET during an artificial cycle. However, because the blood progesterone levels were not monitored in this case, these notions remain speculative. Some specific factors also can prevent the occurrence of miscarriage. In the present case, the abnormal trophoblastic invasion might have played a protective role for the fetus against uterine contraction and subsequent abortion. Although this patient had no history of a cesarean section, which is known as the major risk factor for placenta accreta,<sup>8</sup> she had multiple episodes of abortions and a salpingectomy for an ectopic pregnancy. These events might have induced the placenta accreta because it is known that low-oxygen environments in the local tissues, which are caused by abnormal vascularization after surgery, lead to excessive trophoblast invasion.<sup>8</sup> Likewise, the discontinuation of estrogen and progesterone supplementation at 5 weeks of gestation might have exerted negative effects in the patient, as low serum levels of estradiol have been linked to the risk of placenta accreta,<sup>9</sup> while progesterone is indispensable for decidualization and placentation.<sup>2</sup> Furthermore, a heterotopic cervical pregnancy might be associated with the risk of placental abnormalities or residual trophoblastic tissue, causing bleeding,<sup>5</sup> which also could be applicable to the current case. To date, placenta accreta of the intrauterine pregnancy has not been reported in association with heterotopic cervical pregnancy.<sup>6</sup> However, there should be an awareness of the possible link between placenta accreta and cervical heterotopic pregnancy because reliable ultrasound and radiological markers for placenta accreta have not been established.<sup>8</sup> Although complete cervical evacuation has been suggested as an effective treatment for cervical heterotopic pregnancy,<sup>6</sup> the current case emphasizes the need of intensive care for a heterotopic pregnancy, even after successful cervical evacuation.

In conclusion, this case provides an additional example of a near-full-term delivery after a cervical heterotopic pregnancy and indicates

that the withdrawal of hormonal support might not be sufficient to abort heterotopic pregnancies after artificial cycle FET in some cases. A possible link between hormonal withdrawal and abnormal placentation needs to be clarified in a future study.

## DISCLOSURES

**Conflict of interest:** The authors declare no conflict of interest. **Human and Animal Rights:** This study was approved by the Institutional Review Board of Ome Municipal General Hospital, Tokyo, Japan. All the procedures were followed in accordance with the ethical standards of the responsible committees on human experimentation (institutional and national) and with the Helsinki Declaration of 1964 and its later amendments. Informed consent was obtained from all the patients to be included in the study. This article does not contain any study with animal participants that were performed by any of the authors.

## ORCID

Kazuki Saito  <http://orcid.org/0000-0002-0597-9479>

## REFERENCES

1. Csapo AI, Pulkkinen MU, Kaihola HL. The relationship between the timing of lutectomy and the incidence of complete abortion. *Am J Obstet Gynecol.* 1974;118:985-989.
2. Norwitz ER, Schust DJ, Fisher SJ. Implantation and the survival of early pregnancy. *N Eng J Med.* 2001;345:1400-1408.
3. Groenewoud ER, Cantineau AEP, Kollen BJ, Macklon NS, Cohlen BJ. What is the optimal means of preparing the endometrium in frozen-thawed embryo transfer cycles? A systematic review and meta-analysis. *Hum Reprod Update.* 2013;19:458-470.
4. Alsbjerg B, Polyzos NP, Elbaek HO, Povlsen BB, Andersen CY, Humaidan P. Increasing vaginal progesterone gel supplementation after frozen-thawed embryo transfer significantly increases the delivery rate. *Reprod Biomed Online.* 2013;26:133-137.
5. Moragianni VA, Hamar BD, McArdle C, Ryley DA. Management of a cervical heterotopic pregnancy presenting with first-trimester bleeding: case report and review of the literature. *Fertil Steril.* 2012;98:89-94.
6. Kim JW, Park HM, Lee WS, Yoon TK. What is the best treatment of heterotopic cervical pregnancies for a successful pregnancy outcome? *Clin Exp Reprod Med.* 2012;39:187-192.

7. Papaioannou GI, Syngelaki A, Poon LC, Ross JA, Nicolaides KH. Normal range of embryonic length, embryonic heart rate, gestational sac diameter and yolk sac diameter at 6-10 weeks. *Fetal Diagn Ther.* 2010;28: 207-219.
8. Jauniaux E, Jurkovic D. Placenta accreta: pathogenesis of a 20th century iatrogenic uterine disease. *Placenta.* 2012;33:244-251.
9. Kaser DJ, Melamed A, Bormann CL, et al. Cryopreserved embryo transfer is an independent risk factor for placenta accreta. *Fertil Steril.* 2015;103:1176-1184.

**How to cite this article:** Saito K, Fukami M, Miyado M, Ono I, Sumori K. Case of heterotopic cervical pregnancy and total placenta accreta after artificial cycle frozen-thawed embryo transfer. *Reprod Med Biol.* 2018;17:89-92. <https://doi.org/10.1002/rmb2.12064>