


Low energy chronic traumatic spondylolisthesis of the axis

Conor J. Dunn¹  · Samuel Mease¹ · Kimona Issa¹ · Kumar Sinha¹ · Arash Emami¹

Received: 1 November 2016 / Accepted: 26 June 2017 / Published online: 21 July 2017
© Springer-Verlag GmbH Germany 2017

Abstract



Objective The aim of this study is to present a unique case of a patient who presented to our Emergency Department with evidence of a chronic traumatic spondylolisthesis of the axis with severe displacement treated with anterior cervical discectomy and fusion (ACDF) of C2–C3 as well as and posterior cervical fusion (PCF) of C1–C3.

Methods One patient with an untreated traumatic spondylolisthesis of the axis with Levine type II injury pattern and 1.2 cm of anterior subluxation underwent ACDF C2–C3 and PCF C1–C3.

Results The patient recovered well, radiographs demonstrated reduction of the anterior subluxation, and the patient reported a neck disability index (NDI) score of 20 at

6-month follow-up with full neurologic function intact. The patient was then lost to follow-up.

Conclusion In this report, we present an alcoholic patient with a history of many falls who presented with a Levine type II traumatic spondylolisthesis of the axis with signs of chronicity seen on magnetic resonance imaging (MRI). We were able to partially reduce the anterior displacement with traction, but needed both anterior and posterior cervical approaches to achieve adequate reduction and stabilization of the injury.

Keywords Cervical fracture · Traumatic spondylolisthesis of the axis · ACDF · Hangman's fracture

Case presentation

A 47-year-old man with a past medical history of alcohol abuse, mandibular osteomyelitis status post plate fixation and chronic pancreatitis presented to the emergency department via ambulance with a chief complaint of neck pain. Of note, he was heavily intoxicated and ambulating upon arrival. Per the patient's family, he had fallen several times from standing height on the previous evening while intoxicated, but both the patient and family deny any other trauma. Additionally, he complained of paresthesia of his hands bilaterally but denied any other sensory deficits, motor weakness, or change in bowel or bladder function. On physical examination he was minimally tender to palpation about his cervical spine, had 5/5 strength in all muscle groups of the upper and lower extremity and was neurovascularly intact distally.

✉ Conor J. Dunn
Emamiresearch@gmail.com

¹ Seton Hall University School of Health and Medical School Sciences, 400 South Orange Ave, South Orange, NJ 07079, USA

Diagnostic imaging

Traumatic spondylolisthesis of the axis (Hangman's fracture)

Traumatic spondylolisthesis of the axis is a serious injury with potentially devastating neurologic sequelae. This fracture is the second most common fracture of the axis to the odontoid fracture and accounts for 5% of all cervical spine injuries [1, 2]. A hyperextension or hyperflexion injury can cause this fracture morphology while the distraction versus compression component is hypothesized to have greatest effect on neurologic injury (Figs. 1, 2).

Classification systems, including the most widely used Levine and Edwards, attempt to assess stability of the fracture to determine treatment protocol [3]. Unfortunately, to the authors' knowledge, there is no classification system that decisively standardizes treatment with consistent and reliable results in patients with this injury. This variability in management and lack of uniform indications makes counseling the patient on their outcomes difficult for the surgeon.

In 2006, Li et al. conducted a systematic review on the management of Hangman's fracture and included 32 papers for analysis. The review included authors who argued for different treatment options and indications for management. The review was only able to include the healing rate as a measure of final outcome with no patient reported outcome score such as the neck disability index (NDI) or other questionnaire. In general, the literature is

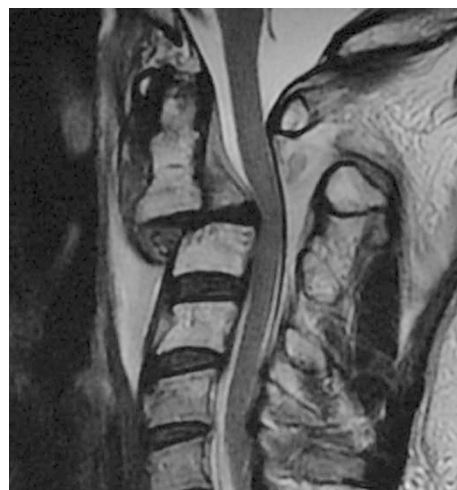
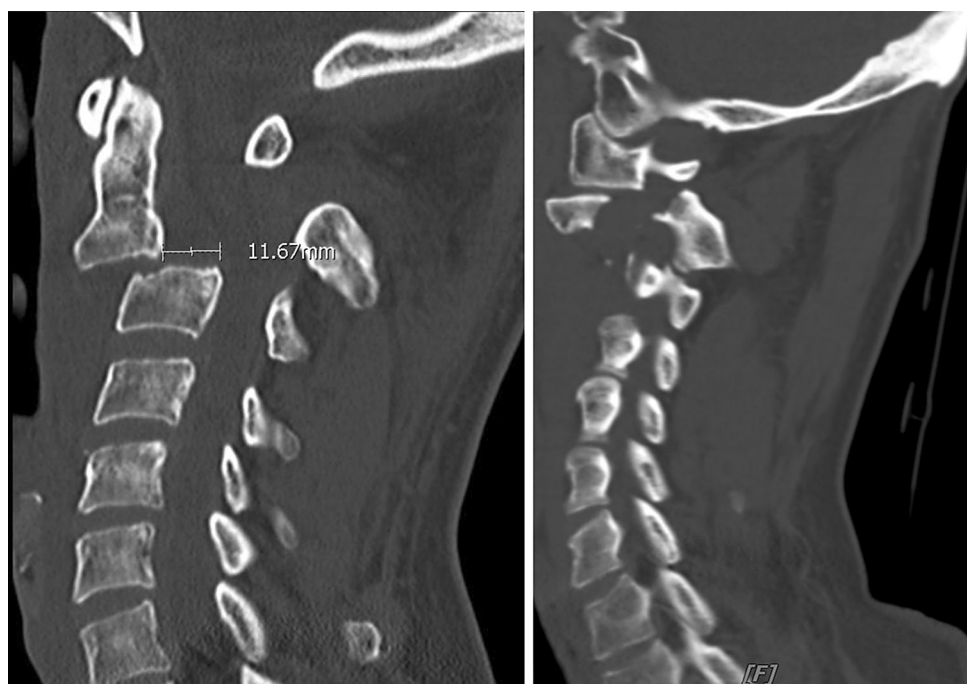
Fig. 2 Initial sagittal MRI demonstrating granulation tissue and healing of the surrounding soft tissue, severe central stenosis and damage to the ALL, PLL and disk

lacking in this regard and it is the authors' suggestion that future studies include functional outcome scores as a means of differentiating the most beneficial treatment for an individual patient [4]. According to the review, 74% of all Hangman's fractures are treated non-operatively with a halo fixator, while the remaining quarter are usually Effendi type IIa and III injuries in which the axis has been determined to be unstable and thus an appropriate candidate for surgical intervention [5]. An anterior fixation via plating or fusion due to disk injury is a common method of fixation as disk injury itself confers instability [6–8].

Fig. 1 a Initial sagittal CT demonstrating bilateral fractures of the C2 pars interarticularis, with anterior subluxation of C2 over C3 and 1.2 cm of displacement in the sagittal plane. **b** Same sagittal CT demonstrating locked C2/C3 facet joint



Additionally, in a narrative review published in 2015 by Schleicher et al., it was similarly concluded that there is a paucity of literature regarding return to work, functional and patient reported outcomes which leads to difficulty in standardizing a proper management protocol. It was noted, however, that 75% of patients were expected to be pain-free with self-reported full range of motion after 1 year across all treatment modalities [9].

Rationale for treatment

Our patient was treated with both anterior and posterior stabilization. There were several reasons for this clinical decision. There are several indications in the literature for a posterior approach for stabilization and fusion including fracture of the atlas, contraindications to anterior approach, vertebral artery access, locked facet joints or any fracture the clinician is unable to close reduce [6, 8–10]. The presence of locked facet joints in our patient that needed to be addressed posteriorly, as well as the disrupted PLL contributed to the decision to include posterior stabilization. Due to the severe soft-tissue instability of C2 and C3 anteriorly as well as severe disk disruption, it was decided that an ACDF of C2–C3 was also necessary. Furthermore, the patient history of alcoholism and frequent falls guided decision-making towards the most stable construct possible to prevent future failure and potentially devastating re-injury (Fig. 3).

Procedure

With maintenance of successful closed reduction, the patient was brought to the operating room the following morning for ACDF of C2 and C3, the first stage of a two-staged procedure. The patient was prepped and draped in a sterile fashion and under fluoroscopic imaging the C2 and C3 bodies were visualized. A 2-cm midline incision was then made between them followed by dissection of the soft tissues and platysma which revealed a marked amount of granulation tissue, edema and hypertrophy of the ALL. Once the disk space was visualized, annulotomy was performed. The disk space was visualized and it was noted that the nucleus pulposus was completely sheared off. The disk material was then removed and posterior dissection was carried out all the way to the posterior osteophyte. Using microscopic visualization, the endplates were prepared with placement of autograft and allograft spacer device. The anterior cervical plate of 14-mm was placed and appropriate-sized screws were inserted. Final radiographs were then obtained (Fig. 4), the wound was irrigated, closed and a hemovac drain was placed.

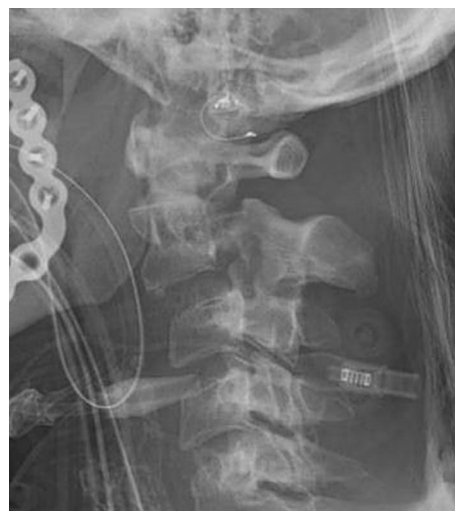

Fig. 3 Post-reduction sagittal X-ray with 6.1 mm displacement

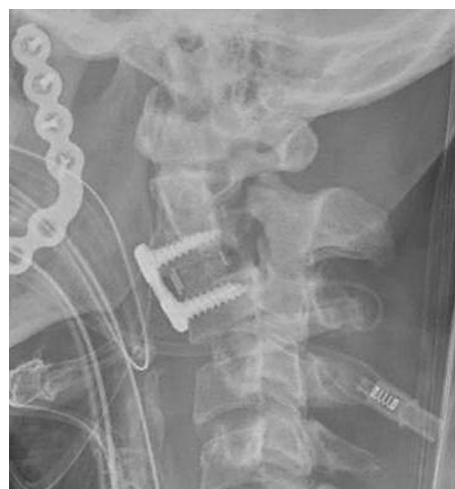

Fig. 4 Sagittal X-ray following ACDF C2–C3 demonstrating 6.1 mm displacement

On post-op day five, the patient returned to the operating room for the second stage of his fusion via posterior approach. The patient was placed in the prone position and the Mayfield head holder was attached to the table in secure position. Using fluoroscopic imaging, the reduction maneuvers were performed to allow maximal extension to bring the C2 body into anatomical alignment. Once this was accomplished, the posterior portion of the neck was prepped and draped in sterile fashion and a midline incision was made from the base of the skull to approximately C4. After appropriate dissection, it was noted that the C1 posterior arch had been subluxed anteriorly. The facet joint of C2–C3 was exposed laterally and the C3–C4 joint was exposed with preservation of the capsule. Under fluoroscopic visualization, a high speed drill was used to

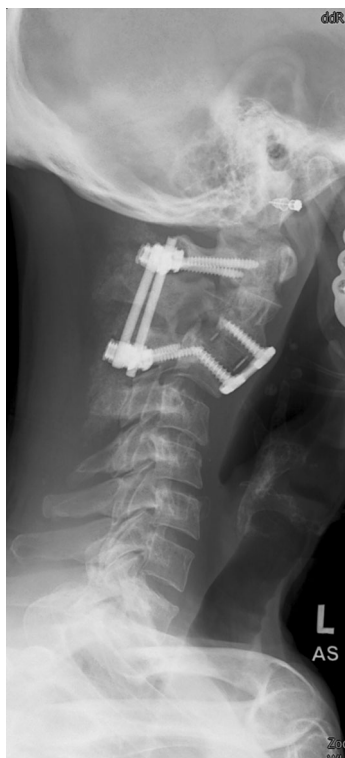

Fig. 5 Radiographs at 6-month follow-up revealed good placement of all implants with good reduction and maintenance of reduction at C2–C3 level

cannulate down the C1 lateral mass. Twenty-six millimeter screws were placed in the bilateral lateral masses of C1 as well as C3 with good purchase. All bony processes were decorticated. A rod was cut, contoured and placed into the tulips of the lateral mass screws at C1 and C3 posteriorly. Final radiographs revealed good placement of all implants with good reduction and maintenance of reduction at C2–C3 level (Fig. 5). The wound was closed, sterile dressings applied and hemovac placed.

Procedure imaging section

Outcome

The patient tolerated all procedures well and remained neurovascularly intact through the course of his stay. He

was subsequently discharged to a sub-acute rehabilitation facility in excellent condition. Patient was seen at 6 months post-operatively at office follow-up visit, had no neurologic deficits and radiographs showed no evidence of fracture of new degenerative changes. His Neck Disability Index (NDI) Raw Score at 6 months was 20 equating to moderate impairment. It is impossible, however, to compare this score to the literature as no quality studies have assessed these clinical scores across treatment modalities. The patient was lost to follow-up afterwards.

Compliance with ethical standards

Conflict of interest All authors declared that they have no potential conflict of interest.

References

1. Effendi B, Roy D, Cornish B et al (1981) Fractures of the ring of the axis. A classification based on the analysis of 131 cases. *J Bone Jt Surg Br* 63-B:319–327
2. Greene KA, Dickman CA, Marciano FF et al (1997) Acute axis fractures. Analysis of management and outcome in 340 consecutive cases. *Spine (Phila Pa 1976)* 22:1843–1852
3. Levine AM, Edwards CC (1985) The management of traumatic spondylolisthesis of the axis. *J Bone Jt Surg Am* 67:217–226
4. Koller H, Kathrein A (2006) Letter to the Editor concerning: A systematic review of the management of hangman's fractures by Xin-Feng Li et al. (2006). *Eur Spine J* 15:257–269 (**Eur Spine J** 15:1415–8; **author reply** 9–21)
5. Li XF, Dai LY, Lu H et al (2006) A systematic review of the management of hangman's fractures. *Eur Spine J* 15:257–269
6. Chittiboina P, Wylen E, Ogden A et al (2009) Traumatic spondylolisthesis of the axis: a biomechanical comparison of clinically relevant anterior and posterior fusion techniques. *J Neurosurg Spine* 11:379–387
7. Hadley MN, Walters BC (2013) Introduction to the guidelines for the management of acute cervical spine and spinal cord injuries. *Neurosurgery* 72(Suppl 2):5–16
8. Duggal N, Chamberlain RH, Perez-Garza LE et al (2007) Hangman's fracture: a biomechanical comparison of stabilization techniques. *Spine (Phila Pa 1976)* 32:182–187
9. Schleicher P, Scholz M, Pingel A et al (2015) Traumatic spondylolisthesis of the axis vertebra in adults. *Glob Spine J* 5:346–358
10. Hadley MN, Dickman CA, Browner CM et al (1989) Acute axis fractures: a review of 229 cases. *J Neurosurg* 71:642–647