

---

*Bilateral pitting oedema in an elderly patient: a typical case of RS3PE syndrome and literature review*

**Dimitrios Karokis**

**Mediterr J Rheumatol 2016; 27(3):111-4**



E-ISSN: 2459-3516



## Bilateral pitting oedema in an elderly patient: a typical case of RS<sub>3</sub>PE syndrome and literature review

Dimitrios Karokis 

Patras, Greece

### ABSTRACT

Remitting Seronegative Symmetrical Synovitis with Pitting (o)Edema (RS<sub>3</sub>PE) syndrome is a rare inflammatory syndrome affecting the elderly, characterized by diffuse symmetrical swelling of the extremities and rapid response to steroids. We present a case of an 84-year old lady, who presented with the typical clinical, laboratory and ultrasonographic findings of the disease, and responded promptly to medium-dose steroids. Then, the epidemiology, pathogenesis, clinical features, differential diagnosis and possible associations of the syndrome with other rheumatological conditions and malignancies are briefly discussed.

**Corresponding author:**  
Dimitrios Karokis, MD, MSc  
Private Practice Rheumatologist  
20 Maizonos Str., Patras,  
26223, Greece  
Tel.: +306937169016  
Fax: +302610225432  
E-mail: dkarakis@hotmail.com

*Mediterr J Rheumatol* 2016;27(3):111-4

<https://doi.org/10.31138/mjr.27.3.111>

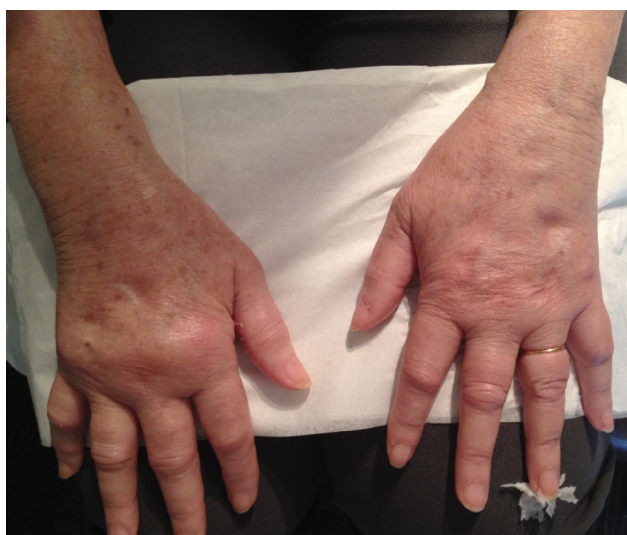**Keywords:** Remitting Seronegative Symmetrical Synovitis with Pitting oedema, RS<sub>3</sub>PE.

## CASE REPORT

An 84-year old lady presented with a 1-month history of pain and diffuse swelling of wrists and hands, worse in the morning, with stiffness lasting for about an hour. She reported no fever or rash or any other constitutional symptoms.

On 2004 she was diagnosed with polymyalgia rheumatica, for which she was treated with corticosteroids for about a year, and cured completely. Her medical history also included hypertension, hyperlipidaemia and osteoporosis. Her family history was notable only for coronary artery disease.

On clinical examination, there was synovitis of the wrists and metacarpophalangeal joints of both hands, more prominent on the right, and a marked diffuse swelling of both hands, with a pitting oedema (**Figure 1**). Ultrasonography revealed diffuse subcutaneous oedema of her hands and tenosynovitis of the extensor tendons (**Figure 2**).



**Figure 1.** RS<sub>3</sub>PE syndrome. Diffuse swelling of the hands with pitting oedema and synovitis of the metacarpophalangeal joints on the right hand.

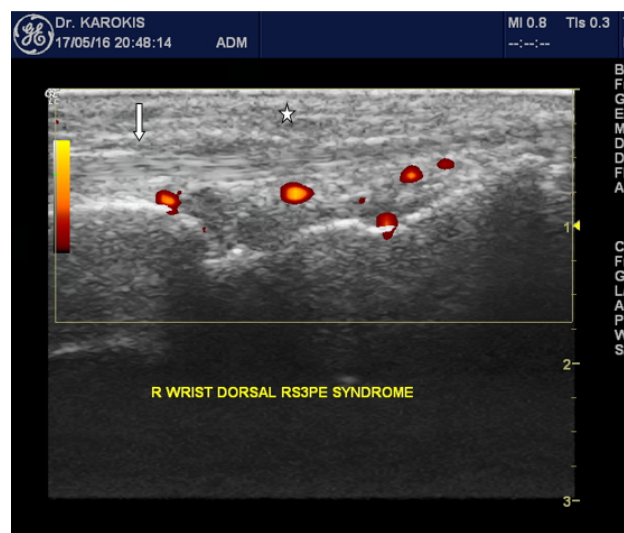
Her laboratory tests revealed a mild normochromic normocytic anemia with Hb of 10.2 mg/dl, a normal white blood cell count and an elevated ESR at 67 mm/1h and CRP at 1.69 mg/dl (upper normal limit 0.8 mg/dl). She was negative for RF, anti-CCP2 and antinuclear antibodies. The rest of her tests, including biochemistry, serum protein electrophoresis, chest x-ray and ultrasound of the abdomen were without any significant pathology.

A diagnosis of remitting seronegative symmetrical synovitis with pitting oedema (RS<sub>3</sub>PE) syndrome was made

and she was treated with prednisolone (initial dose 10 mg in the morning and 5 mg at night), along with her anti-osteoporosis treatment and gastroprotection. Her symptoms resolved completely within a week, and we started tapering the steroid dose after 20 days, resulting in complete discontinuation in about 3 months' time.

## DISCUSSION

Remitting Seronegative Symmetrical Synovitis with Pitting (o)Edema (RS<sub>3</sub>PE) syndrome was first described by McCarthy et al. in 1985, who actually described it as "boxing glove hand" because of its characteristic swelling.<sup>1</sup> It is a rare syndrome. Karmacharya et al, in a most recent systematic review and meta-analysis of all relevant publications, identified 331 cases from 121 articles.<sup>2</sup> The exact incidence and prevalence is not known, but it seems that it affects predominantly men with a ratio 2:1 to women.<sup>3</sup>



**Figure 2.** RS<sub>3</sub>PE syndrome. Ultrasound scan of right wrist, dorsal surface. Diffuse subcutaneous oedema is noted (white star). The extensor tendon is enlarged (white arrow), with positive power Doppler sign, indicative of extensor tenosynovitis.

Based on their review, Karmacharya et al. revised the initial diagnostic criteria described by Olive et al. in 1997<sup>4</sup> and suggested the following criteria: abrupt onset, marked pitting oedema of hands (mainly) and/or feet, age of onset >60 years, good and quick response to short course of 10-20 mg of steroids daily, seronegativity for RF and ACPA, and absence of radiographic erosions. Typically, as indicated by its definition, the disease presents with symmetrical bilateral involvement, but very rare unilateral cases have also been reported.<sup>5</sup> Ultrasonographic evidence of extensor tenosynovitis of

wrists and metacarpals may also be a characteristic feature, but this has to be proven in future cases.<sup>2</sup>

The syndrome has been reported to be associated with HLA-B7<sup>1</sup> and A2<sup>6</sup>. The Vascular Endothelial Growth Factor has been implicated in the pathogenesis, as responsible for both hypervascularity (a feature of synovitis) and vascular permeability (leading to subcutaneous oedema).<sup>7</sup>

Laboratory investigations reveal chronic anemia and elevated indices of inflammation, whereas there is very limited data about synovial fluid (variable cell count, less than 3000/mm<sup>3</sup> with neutrophil predominance),<sup>8</sup> and a few reports of synovial biopsies showing non-specific synovitis.<sup>9</sup>

The long-standing question if RS<sub>3</sub>PE syndrome is a distinct clinical entity, a variant of other rheumatological diseases or a paraneoplastic manifestation remains unanswered. Initial reports suggested that RS<sub>3</sub>PE syndrome may represent late onset of rheumatic diseases like seronegative late-onset rheumatoid arthritis, polymyalgia rheumatica (PMR), spondyloarthropathies, Sjögren's, and even sarcoidosis.<sup>2,10</sup> However, Karmacharya et al. in their review and meta-analysis, reported that only 4.23% of all published cases were associated with a definite confirmed concomitant rheumatological disease.<sup>2</sup>

Regarding late-onset rheumatoid arthritis, the RS<sub>3</sub>PE syndrome is seronegative for RF and ACPA antibodies, has no radiographic erosions and no subcutaneous nodules, no association with HLA-DRB1. Imaging shows non-synovial pathology and the disease responds very well to low-dose steroids. Collectively these observations suggest that late-onset rheumatoid arthritis and RS<sub>3</sub>PE are two distinct clinical entities.<sup>2</sup>

The main issue is whether RS<sub>3</sub>PE represents a variant of PMR. The two diseases share common characteristics, like acute onset in the elderly, non-synovial pathology and prompt response to steroids. However, RS<sub>3</sub>PE is more common in males, and distal extremities are involved, whereas in PMR there is a female predominance and involvement of proximal extremities (shoulders, hips). Moreover, PMR requires much longer treatment and there are frequent flares and relapses when trying to taper steroids.<sup>11</sup> In addition, ultrasonography in PMR very frequently reveals abnormal findings from shoulders and hips, like subdeltoid bursitis and/or biceps tenosynovitis and/or glenohumeral synovitis, as well as hip synovitis and/or trochanteric bursitis, as indicated in the 2012 EULAR/ACR provisional classification criteria,<sup>12</sup> whereas in RS<sub>3</sub>PE syndrome ultrasonography has only shown extensor (mainly) and flexor tendon tenosynovitis in the hands.<sup>13</sup> The differentiation between the two entities may be very important as the patients are elderly people with multiple medical problems and prolonged steroid treatment (like in PMR) may

enhance co-morbidity.<sup>3</sup>

Despite these significant differences, the differential diagnosis of RS<sub>3</sub>PE syndrome remains broad and includes PMR, rheumatoid arthritis, late-onset spondyloarthropathies, crystal-induced arthropathies, amyloid arthropathy, thyroid arthropathy, paraneoplastic syndromes, early scleroderma and mixed connective tissue disease.<sup>2,3</sup> When RS<sub>3</sub>PE presents with pedal oedema, one has to exclude other causes like congestive heart failure, nephrotic syndrome and hypothyroidism.<sup>3</sup> A major concern is the possible association of RS<sub>3</sub>PE syndrome with an underlying malignancy, as a paraneoplastic manifestation. Several types of malignancies have been reported in association with RS<sub>3</sub>PE syndrome.<sup>14,15</sup> In the review and meta-analysis by Karmacharya et al., a concurrent malignancy was reported in 16.01% of the cases, most of which were solid organ tumours (11,18%) of the gastrointestinal and genitourinary tracts,<sup>2</sup> whereas in RA and other rheumatological diseases there is a higher rate of hematologic and lung malignancies.<sup>16</sup> In another recent review by Manger and Schett, malignancy was reported in 22 out of 89 patients with RS<sub>3</sub>PE syndrome.<sup>17</sup> The need for cancer screening in patients with RS<sub>3</sub>PE syndrome remains a matter of debate and requires further research: nevertheless, the clinician should keep such possible associations in mind. Poor responsiveness to steroids and significant constitutional symptoms (weight loss, fever, anorexia, etc.) should alert towards this possibility.<sup>2,3</sup>

Typically, patients with RS<sub>3</sub>PE syndrome respond to medium-dose steroids, mostly within 1-2 weeks.<sup>18,19</sup> As mentioned earlier, poor responsiveness to steroids may be a red flag for underlying malignancy. In patients with significant co-morbidity, DMARDs like hydroxychloroquine or methotrexate can and have been used as steroid-sparing agents.<sup>20</sup> The use of biologic agents like tocilizumab<sup>21,22</sup> or etanercept<sup>23</sup> in isolated cases has also been reported. The prognosis is excellent and most patients are able to taper off steroids within 2-3 months, with a very low rate of recurrence.<sup>2</sup> A follow-up study of RS<sub>3</sub>PE patients 6 years after cessation of treatment, revealed that the vast majority of patients were asymptomatic and not on any relevant treatment.<sup>24</sup> In conclusion, the reported patient presented with all the clinical, laboratory and ultrasonographic characteristics of the RS<sub>3</sub>PE syndrome. Detailed screening for underlying malignancy was negative, and she responded very quickly to medium-dose steroids.

The RS<sub>3</sub>PE syndrome is a rare disease which requires awareness and high index of suspicion by the treating physician, as possible association with other rheumatological diseases and various malignancies is yet to be established.

## CONFLICT OF INTEREST

The author declares no conflict of interest.

## REFERENCES

- McCarthy D J, O'Duffy D J, Pearson L, et al. Remitting Seronegative Symmetrical Synovitis with Pitting oedema. RS3PE Syndrome. *JAMA* 1985;254:2763-7.
- Karmacharya P, Donato A A, Aryal M R, Ghimire S, Pathak P, Shah K, et al. RS3PE revisited. A systematic review and meta-analysis of 331 cases. *Clin Exp Rheum* 2016;34:404-15.
- Salam A, Rafik H, Sheeran T. Acute onset polyarthritis in older people. Is it RS3PE syndrome? *Cases Journal* 2008;1:132.
- Olive A, del Bianco J, Pons M, Vaquero M, Tena X. The clinical spectrum of remitting seronegative symmetrical synovitis with pitting oedema. The Catalan Group for the Study of RS3PE. *J Rheumatology* 1997;24:333-6.
- Dudler J, Gerster J C, So A. Polyarthritis and pitting oedema. *Ann Rheum Dis* 1999;58:142-7.
- Shaefferbeke T, Vernhes J P, Bannwarth B, Dehais J. Is remitting seronegative symmetrical synovitis with pitting oedema (RS3PE syndrome) associated with HLA-A2? *Br J Rheumatology* 1995;34:889-890.
- Arima K, Origuchi T, Tamai M, Iwanaga N, Izumi Y, Huang M, et al. RS3PE syndrome presenting as vascular endothelial growth factor associated disorder. *Ann Rheum Dis* 2005;64:1653-5.
- Roblot P, Zaim A, Azais I, et al. RS3PE: A clinical diagnosis, a prognosis more simple than its name. *Rev Med Interne* 1998;19:542-7.
- Russell E B, Hunter J B, L Pearson, et al. Remitting, seronegative, symmetrical synovitis with pitting oedema- 13 additional cases. *J Rheumatol* 1990;17:633-9.
- Healey L A. RS3PE syndrome. *J Rheumatol* 1990;17:414.
- Kimura M, Tokuda Y, Oshiawa H, et al. Clinical characteristics of patients with remitting seronegative symmetrical synovitis with pitting oedema compared to patients with pure polymyalgia rheumatica. *J Rheumatol* 2012;39:148-53.
- Dasgupta B, Cimmino M A, Cremers H M, Schmidt W A, Schirmer M, Salvarani C, et al. 2012 provision classification criteria for polymyalgia rheumatica: A European League Against Rheumatology/American College of Rheumatology collaborative initiative. *Arthritis Rheum* 2012 Apr;64:943-54.
- Agarwal V, Dabra A K, Kaur R, et al. Remitting seronegative symmetrical synovitis with pitting oedema (RS3PE) syndrome: Ultrasonography as a diagnostic tool. *Clin Rheumatol* 2005;24:476-9.
- Cantini F, Salvarani C, Olivieri I. Paraneoplastic remitting seronegative symmetrical synovitis. *Clin Exp Rheumatol* 1999;17:741-4.
- Sayarlioglu M. Remitting seronegative symmetrical synovitis with pitting oedema (RS3PE) syndrome and malignancy. *Eur J Ger Med* 2004;1:3-5.
- Smitten A L, Simon T A, Hochberg M C, et al. A meta-analysis of the incidence of malignancy in adult patients with rheumatoid arthritis. *Arthr Res Ther* 2008;10:R45.
- Manger B, Schett G. Araneoplastic syndromes in Rheumatology. *Nature Rev Rheumatology* 2014;10:662-70.
- Shaefferbeke T, Fatout E, Marce S, Vernhes J P, Halle O, Antoine J F, et al. Remitting seronegative symmetrical synovitis with pitting oedema: disease or syndrome? *Ann Rheum Dis* 1995;54:681-4.
- Paira S, Graf C, Roverano S, et al. Remitting seronegative symmetrical synovitis with pitting oedema: A study of 12 cases. *Clin Rheumatol* 2002;21:146-9.
- Calis M, Cuce I, Akgul O, Cuce E G, Candan V. The treatment approach for the remitting seronegative symmetrical synovitis with pitting oedema (RS3PE) syndrome. *Doi:100136/annrheum-dis-2015-eular.3312*.
- Izumi K, Kuda H, Ushikubo M, Kuwana M, Takeuchi T, Oshima H. Tocilizumab is effective against polymyalgia rheumatica. Experience in 13 intractable cases. *RMD Open* 2015;1:e000162.
- Furst D, Fleishman R, Kalden J, Kavanaugh A, Sieper J, Mease P, et al. Documentation of off-label use of biologics in Rheumatoid Arthritis. *Ann Rheum Dis* 2013;72:ii35-ii51.
- Mehta P, Chong S, Carulli M, Haskard D. Steroid-resistant remitting seronegative symmetrical synovitis with pitting oedema associated with gout treated with etanercept (letter). *Rheumatology* 2014;53:1908-10.
- Guma M, Casado E, Tena X. RS3PE: Six years later. *Ann Rheum Dis* 1999;58:722-3.