

# Maxillary Sinus Floor Augmentation with Autogenous Bone Graft Alone Compared with Alternate Grafting Materials: a Systematic Review and Meta-Analysis Focusing on Histomorphometric Outcome

Thomas Starch-Jensen<sup>1</sup>, Daniel Deluiz<sup>2</sup>, Niels Henrik Bruun<sup>3</sup>, Eduardo Muniz Barretto Tinoco<sup>2</sup>

<sup>1</sup>Department of Oral and Maxillofacial Surgery, Aalborg University Hospital, Aalborg, Denmark.

<sup>2</sup>Department of Periodontology, Rio de Janeiro State University, Rio de Janeiro, Brazil.

<sup>3</sup>Unit of Clinical Biostatistics, Aalborg University Hospital, Aalborg, Denmark.

## Corresponding Author:

Thomas Starch-Jensen

Department of Oral and Maxillofacial Surgery

Aalborg University Hospital

18-22 Hobrovej, DK-9000 Aalborg

Denmark

Phone: +45 97 66 27 98

Fax: +45 97 66 28 25

E-mail: [thomas.jensen@rn.dk](mailto:thomas.jensen@rn.dk)

## ABSTRACT

**Objectives:** The objective of present systematic review was to test the hypothesis of no difference in histomorphometric outcome after maxillary sinus floor augmentation with autogenous bone graft alone compared with alternate grafting materials applying the lateral window technique.

**Material and Methods:** MEDLINE (PubMed), Embase and Cochrane library search in combination with hand-search of relevant journals were conducted. Human studies published in English until the 25<sup>th</sup> of March, 2020 were included. Histomorphometric outcomes were evaluated by descriptive statistics and meta-analysis including 95% confidence interval (CI).

**Results:** Electronic search and hand-searching resulted in 1902 entries. Sixteen randomized controlled trials with unclear risk of bias fulfilled the inclusion criteria. Descriptive statistics showed comparable or improved histomorphometric outcomes with autogenous bone graft. Meta-analysis revealed a mean difference of -7.1% (CI = -11.0 to -3.2) indicating a significant higher amount of bone after maxillary sinus floor augmentation with autogenous bone graft compared with alternate grafting materials. Subgroup analysis demonstrated a non-significantly differences of -3.7% (CI = -10.9 to 3.4), -11.5% (CI = -25.9 to 2.8), 2.2% (CI = -16.9 to 21.3), and -4.6% (CI = -14.4 to 5.2), when autogenous bone graft was compared with allogeneic bone graft, xenograft, composite grafting materials involving xenograft or synthetic biomaterial mixed with autogenous bone graft, respectively.

**Conclusions:** Maxillary sinus floor augmentation with autogenous bone graft seems to facilitate improved histomorphometric outcomes compared with alternate grafting materials. However, the included studies were characterised by an unclear risk of bias and various methodological confounding factors. Hence, the conclusions drawn from the results of present study should be interpreted with caution.

**Keywords:** alveolar ridge augmentation; dental implants; oral surgical procedures; review; sinus floor augmentation.

Accepted for publication: 10 September 2020

### To cite this article:

Starch-Jensen T, Deluiz D, Bruun NH, Tinoco EMB.

Maxillary Sinus Floor Augmentation with Autogenous Bone Graft Alone Compared with Alternate Grafting Materials: a Systematic Review and Meta-Analysis Focusing on Histomorphometric Outcome

J Oral Maxillofac Res 2020;11(3):e2

URL: <http://www.ejomr.org/JOMR/archives/2020/3/e2/v11n3e2.pdf>

doi: [10.5037/jomr.2020.11302](https://doi.org/10.5037/jomr.2020.11302)

## INTRODUCTION

Maxillary sinus floor augmentation (MSFA) was originally developed by Tatum in the mid-seventies and afterwards described by Boyne and James in 1980 [1,2]. Nowadays, MSFA applying the lateral window technique is the most commonly used surgical procedure to increase the vertical alveolar bone height of the posterior maxilla before or in conjunction with placement of dental implants, and the treatment outcome involving various types of grafting materials have been documented in systematic reviews and meta-analyses [3-10]. Autogenous bone graft is generally considered the preferred grafting material for MSFA due to its osteoinductive, osteogenic and osteoconductive characteristics [11]. Long-term studies have demonstrated high survival rates of suprastructures and implants, limited peri-implant marginal bone loss and few complications after MSFA with autogenous bone graft [12,13]. However, harvesting of autogenous bone graft is associated with risk of donor site morbidity and prolonged treatment time [14,15]. Various bone substitutes of biologic or synthetic origin are therefore used increasingly to simplify the surgical procedure by diminishing the need for bone harvesting [4]. On the contrary, allogeneic bone graft, synthetic biomaterials or bone substitutes of natural transplants involves a risk of contamination, activation of host immune system and disease transmission as well as they can be refused by patients for religious reasons or because they are in contrast with chosen lifestyle. Thus, selection of the most appropriate grafting material for MSFA sustains a matter of controversy.

Impaired bone quality and quantity is detrimental to obtaining adequate osseointegration of implants in the posterior part of the maxilla [16]. MSFA with the use of a grafting material facilitates bone regeneration and increases bone volume, which enhances the potential for achieving sufficient bone-to-implant contact (BIC) and long-term implant survival [17]. Histomorphometric analysis of tissue specimens or micro-computed tomography are the most commonly applied methods for assessing percentage of newly formed bone, non-mineralized tissue, residual grafting material and BIC. Histomorphometric parameters are frequently presented as total bone volume (TBV), bone area fraction (BAF) or newly formed bone, non-mineralized tissue and residual graft material in a clearly specified region of interest. Experimental studies evaluating histomorphometric variables and BIC after MSFA with autogenous

bone graft compared with various grafting materials have revealed disputing results, without significantly beneficial histomorphometric characteristics with any of the used grafting materials [17-25]. A recent published systematic review and meta-analysis assessing MSFA in humans concluded that autogenous bone graft enables the highest amount of newly formed bone compared with the use of bone substitutes alone or different compositions of bone substitutes and autogenous bone graft [17]. This is in accordance with a previous published meta-analysis demonstrating that MSFA with autogenous bone graft generates a significantly higher TBV in the early healing period compared with bone substitutes alone or different compositions of autogenous bone graft and bone substitutes, while a non-significant difference was reported after a longer observation period [26]. Consequently, type and composition of the grafting material as well as length of healing period seems to influence the histomorphometric outcome. Therefore, the objective of the present systematic review and meta-analysis was to test the hypothesis of no differences in histomorphometric outcomes after maxillary sinus floor augmentation with autogenous bone graft alone compared with alternate grafting materials.

## MATERIAL AND METHODS

### Protocol and registration

The present systematic review was conducted in accordance with the Preferred Reporting Items for Systematic Reviews and Meta-Analyses (PRISMA) statement for reporting systematic reviews [27]. Methods of the analysis and inclusion criteria were specified in advance and documented in a protocol and registered in PROSPERO, an international prospective register of systematic reviews.

Registration number: CRD42020177003.

The protocol can be accessed at:

[https://www.crd.york.ac.uk/prospERO/display\\_record.php?ID=CRD42020177003](https://www.crd.york.ac.uk/prospERO/display_record.php?ID=CRD42020177003).

### Focus question

The focus question was developed according to the Patient, Intervention, Comparison and Outcome (PICO) framework as described in Table 1:

Are there any differences in the histomorphometric outcomes after MSFA with autogenous bone graft alone compared with alternate grafting materials?

**Table 1.** PICOS guidelines

<b>Patient and population (P)</b>	Healthy adult patients with vertical atrophy of the posterior part of the maxilla receiving maxillary sinus floor augmentation applying the lateral window technique.
<b>Intervention (I)</b>	Autogenous bone graft alone.
<b>Comparator or control group (C)</b>	Alternate grafting materials.
<b>Outcomes (O)</b>	Bone-to-implant contact, total bone volume, bone area fraction, newly formed bone, non-mineralized tissue and residual graft material.
<b>Study design (S)</b>	Randomized controlled trials.
<b>Focused question</b>	Are there any differences in histomorphometric outcomes after maxillary sinus floor augmentation with autogenous bone graft alone compared with alternate grafting materials?

## Types of studies and publications

Randomized controlled trials in humans.

## Population

Included studies involved healthy adult partially or totally edentulous patients with atrophy of the posterior part of the maxilla receiving MSFA applying the lateral window technique with autogenous bone graft alone compared with alternate grafting materials.

## Types of outcome measures

- BIC defined as percentage of bone area in direct contact with the implant surface.
- TBV defined as percentage of bone volume of the examined tissue sample.
- BAF defined as percentage of bone area in a clearly specified region of interest.
- Percentage of newly formed bone, non-mineralized tissue and residual graft material as evaluated by histomorphometric analysis or micro-computed tomography.

## Information sources

The search strategy incorporated examinations of electronic databases, supplemented by a thorough hand-search page by page of relevant journals including “British Journal of Oral and Maxillofacial Surgery”, “Clinical Implant Dentistry and Related Research”, “Clinical Oral Implants Research”, “European Journal of Oral Implantology”, “Implant Dentistry”, “International Journal of Oral and Maxillofacial Implants”, “International Journal of Oral and Maxillofacial Surgery”, “International Journal of Periodontics and Restorative Dentistry”, “International Journal of Prosthodontics”, “Journal of Clinical Periodontology”, “Journal of Dental Research”, “Journal of Oral Implantology”, “Journal of Oral & Maxillofacial Research”, “Journal of

Periodontology”, “Journal of Prosthetic Dentistry”, “Journal of Craniofacial Surgery”, “Journal of Cranio-Maxillo-Facial Surgery”, “Journal of Oral and Maxillofacial Surgery”, “Periodontology 2000”, “Oral and Maxillofacial Surgery” and “Oral Surgery Oral Medicine Oral Pathology Oral Radiology”. The manual search also included the bibliographies of all articles selected for full-text screening as well as previously published reviews relevant for the present systematic review.

## Search

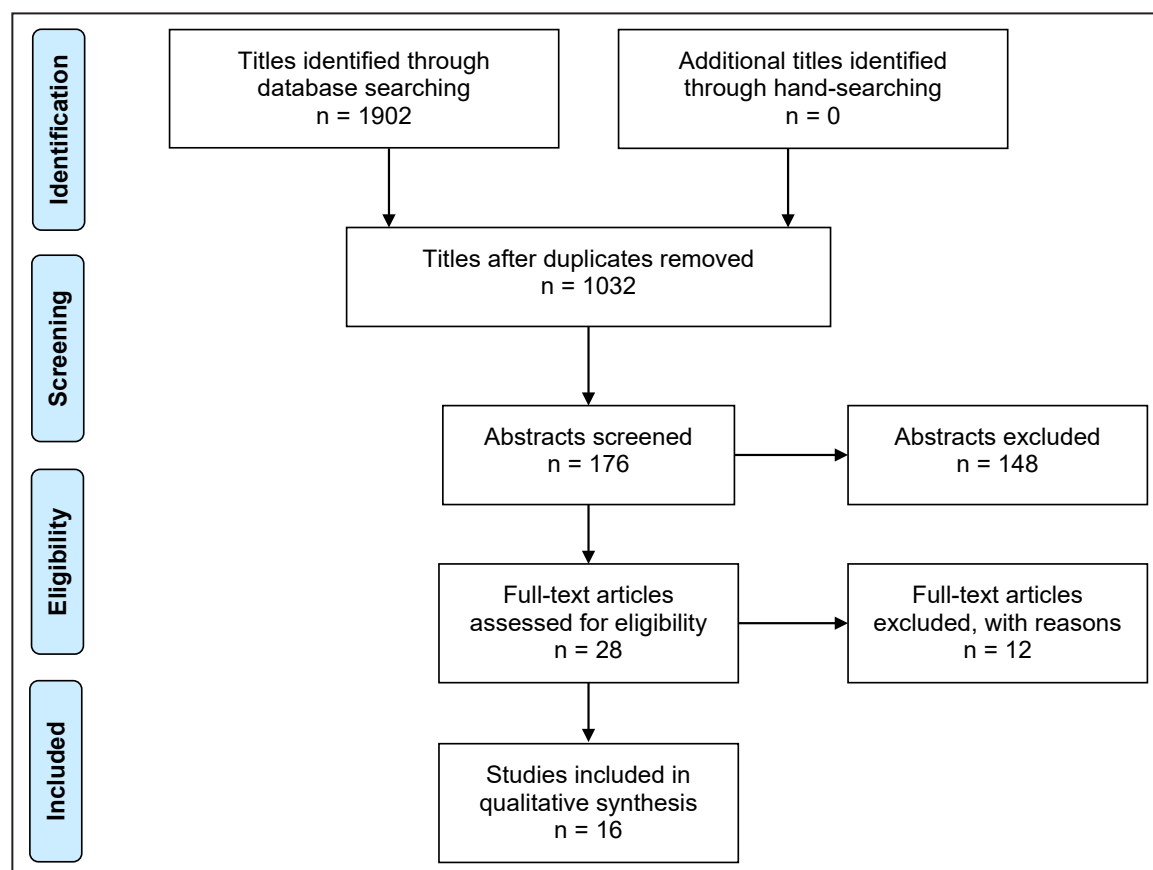
A MEDLINE (PubMed), Embase, and Cochrane Library search was conducted. Human studies published in English until the 25<sup>th</sup> of March, 2020 were included. Grey literature, unpublished literature as well as other databases like Scopus, Google Scholar, or Research Gate were not included in the search strategy of the present systematic review. The search strategy was performed in collaboration with a librarian and utilized a combination of Medical subject heading (MeSH) and free text terms. A detailed description of the search strategy is outlined in [Appendices 1, 2 and 3](#).

## Selection of studies

PRISMA flow diagram presents an overview of the selection process (Figure 1). Titles of identified reports were initially screened with duplicates removed. Abstracts were assessed when the title indicated that the study was relevant. Full-text analysis was obtained for those with apparent relevance or when the abstract was unavailable. References of papers identified and previously published systematic reviews were cross-checked for unidentified articles. Study selection was performed by one reviewer (T.S-J.).

## Inclusion criteria

Studies assessing MSFA with particulated autogenous



**Figure 1.** PRISMA (Preferred Reporting Items for Systematic Reviews and Meta-Analyses) flow diagram demonstrating the results of the systematic literature search.

bone graft alone compared with alternate grafting material were included by addressing the previous described outcome measures. The review exclusively focused on studies presenting histomorphometric outcome. In addition, at least five patients involving five sinus augmentation procedures in each group should be included and the used grafting material as well as number of sinus augmentation procedures had to be clearly specified.

### Exclusion criteria

Following exclusion criteria were applied: MSFA with autogenous bone block graft, unspecified length of observation period as well as studies involving medically compromised patients. Moreover, letters, editorials, PhD theses, letters to the editor, case reports, abstracts, technical reports, conference proceedings, animal or *in vitro* studies and literature review papers were also excluded.

### Data extraction

Data were extracted by one reviewer (T.S-J.) according to a data-collection form ensuring systematic recording of the outcome measures. In addition,

relevant characteristics of the study were recorded. Corresponding authors were contacted by e-mail in the absence of important information or ambiguities.

### Data items

Following items were collected and arranged in the following fields: author, year of publication, study design, number of patients, MSFA procedures, residual alveolar bone height, type of grafting material, length of observation period, number of biopsies, BIC, bone regeneration including percentage of TBV, BAF, newly formed bone, non-mineralized tissue and residual graft material.

### Assessment of methodological quality

Quality assessment was undertaken by one review author (T.S-J.) as part of the data extraction process. Cochrane Collaboration's tool for assessing the risk of bias suggested in the Cochrane Handbook for Systematic Reviews of Interventions was used for included randomized controlled trials (version 5.1.0) [28]. Following items were evaluated:

- Random sequence generation;
- Allocation concealment;

- Patient blinding;
- Outcome blinding;
- Incomplete outcome data addressed;
- Selective reporting.
- Publications were grouped into the following categories [29]:
- Low risk of bias (possible bias not seriously affecting results) if all criteria were met.
- High risk of bias (possible bias seriously weakening reliability of results) if one or more criteria were not met.
- Unclear risk of bias when too few details were available for classification as high or low risk.

### Statistical analysis

Meta-analysis (with random effect) where conducted to combine data from multiple studies where similar effects were measured. Results were expressed as the mean difference (MD) between autogenous bone graft alone compared with alternate grafting materials. The 95% confidence interval (CI) was also calculated. Parametric data are expressed as mean and standard deviation (M [SD]). Statistical significance level was defined at  $P = 0.05$ .

### Assessment of heterogeneity

The significance of any discrepancies in the estimates of the treatment effects of the different studies was assessed by means of Cochran's test for heterogeneity and the  $I^2$  statistic, which describes the percentage of total variation across studies that is due to heterogeneity rather than chance. Heterogeneity by Cochran's test was considered statistically significant if  $P < 0.1$ . A rough guide to the interpretation of  $I^2$  given in the Cochrane Handbook for Systematic Reviews of Interventions is as follows [28]:

- 0 - 40% the heterogeneity might not be important;
- 30 - 60% may represent moderate heterogeneity;
- 50 - 90% may represent substantial heterogeneity;
- 75 - 100% may represent considerable heterogeneity.

## RESULTS

### Study selection

Article review and data extraction were performed according to the PRISMA flow diagram (Figure 1). The systematic electronic literature search resulted in 1902 entries. No additional articles were identified through hand-searching. Of these 1902 articles, 870 were excluded because they had been retrieved in more than one search. A total of 176 abstracts were

reviewed and full-text analysis included 28 articles. Finally, 16 studies were included [30-45].

### Exclusion of studies

Reasons for excluding studies after full-text assessment were as follows: less than five patients included [46], less than five sinus augmentation procedures in each group [47], controlled clinical trials without randomization [48-52], MSFA in conjunction with additional augmentation procedures [53], alveolar ridge augmentation not involving MSFA [54], autogenous bone block graft was used as grafting material [55], histomorphometric outcome was not expressed in percentage [56], and MSFA was conducted with the use of space-maintaining mesh [57].

### Study characteristics

Included studies consisted of 16 randomized controlled trials with an unclear risk of bias [30-45]. Partially and totally edentulous patients with atrophy of the posterior maxilla were enrolled in the included studies. Power calculation was performed in three studies [42,44,45]. A split-mouth study design was used in seven studies [30,31,33-35,40,41]. No significant difference in patient demographics was reported in one study [35]. Residual bone height as well as inclusion and exclusion criteria were clearly specified in all included studies [30-45]. Randomization was conducted using a randomization table [32,35,40], computer-generated randomization code [41], allocation concealment process [37], drawing lots [42-45], coin-toss method [34], or no information was provided about the randomization procedure [30,31,33,36,38,39]. The surgical procedure was performed by one surgeon [36,39,40,44] or no information was provided about the number of surgeons involved [30-35,37,38,41-43,45]. Autogenous bone graft was harvested from the ascending mandibular ramus [31,37,38,40,42-45], mandibular symphysis [32,37,42-45], lateral sinus wall [41], zygomatic buttress [36,41], tuberosity area [39,41] or iliac crest [30,32,33,35]. Autogenous bone graft was compared with a synthetic biomaterial alone involving BioGran® (3i Implant Innovations, Inc.; Palm Beach Gardens, FL, USA) [32,45], BoneCeramic® (Straumann AG; Basal, Switzerland) [38,39,41], Cerasorb® (Curasan AG; Kleinostheim, Deutschland) [34], and chronOS® (Synthes Inc.; West Chester, PA, USA) [43] or composite graft consisting of 50% BioGran® and 50% autogenous bone graft [30,42,44,45] or 50% chronOs® and 50% autogenous bone graft [43]. Autogenous bone graft was compared



with xenograft alone involving Bio-Oss® (Geistlich Pharma AG; Wolhusen, Switzerland) [38], OsteoBio® (Tecnoss Dental s.r.l.; Turin, Italy) [33] or a composite xenograft involving 20% Bio-Oss® mixed with 80% autogenous bone graft [31]. Autogenous bone graft was compared with allogeneic bone graft involving Puros® (Zimmer Dental GmbH; Munich, Germany) [38] or fresh frozen bone [40]. Autogenous bone graft was also compared with platelet-rich plasma mixed with autogenous bone graft [35,37] or blood coagulum including replacement of the lateral bone window or barrier membrane coverage of the lateral window [36]. Different collagen barrier membranes were used to cover the lateral window involving Bio-Gide® (Geistlich Pharma AG; Wolhusen, Switzerland) [31,38-40], Tecnoss® (Tecnoss Dental s.r.l.; Torino, Italy) [33], Spongostan® film (Johnson & Johnson Medical N.V.; Courcelles, Belgium) [36], type of membrane was not specified [37,41], no information was provided about the use of a membrane [30,35,42-45] or no membrane was used [32,34]. None of the membranes were fixed with tacks. Experimental micro-implants were retrieved for assessment of BIC after six [31] and seven months [36]. MSFA with simultaneous implant placement was performed in one study [36], while delayed implant placement was conducted after four months [30,37], five months [30,33,38], six months [30-32,34,35,37,40-45], nine months [39] or 16 months [30], respectively. Different implant systems were used including Ankylos® (Dentsply Implants Manufacturing GmbH; Mannheim, Germany) [34], Conexão System® (Gestão de TI e Impressão; São Paulo, Brazil) [40], Nobel Biocare® (Nobel Biocare AB; Gothenburg, Sweden) [31], Premium TG® (Sweden & Martina SpA; Padova, Italy) [33], Protetim® (Protetim Orvosi Műszergyártó Kft.; Hódmezővásárhely, Hungary) [34], Spectra-System® (Core-Vent Corporation, Las Vegas, NV, USA) [37], Straumann® (Straumann AG; Basal, Switzerland) [32,36,38,39,41], whereas the used implant system was not specified in six studies [30,35,42-45]. Histomorphometric assessment involving micro-computed tomography was performed after six months [45] and seven months [36], respectively. Tissue specimens were evaluated after four months [30,37], five months [30,33,38], six months [30-32,34,35,37,40-45], nine months [39] and 16 months [30], respectively. Number of biopsies were clearly specified in eight studies [30-36,40], while no information was provided in seven studies [37,39,41-45]. Bone cores were retrieved with trephine drill through the previous lateral window [31,32,40,41], at planned implant site [30,33,34,38,39], or not specified [35-37,42-45]. Percentage of BIC was

evaluated in two studies [31,36]. Percentage of TBV was assessed in seven studies [30,32-35,37,45], BAF in three studies [31,38,39], and percentage of newly formed bone was estimated in five studies [40-44]. None of the included studies provided information about blinding, training or calibration of surgeons or the examiners assessing the clinical and radiographic outcome. Numbers of drop-outs were reported in three studies [43-45].

## Outcome measures

BIC, TBV, BAF and newly formed bone are considered the primary outcome measures, while non-mineralized tissue and residual graft material are surrogate outcome. Percentage of non-mineralized tissue and residual graft material are therefore solely presented in Table 2. Results of each primary outcome are described below including a short summary and outlined in Table 2.

## Bone-to-implant contact

Percentage of BIC with autogenous bone graft compared with mixture of 80% Bio-Oss® and 20% autogenous bone graft were 34.6 (9.5) and 54.3 (33.1) after six to seven months, respectively [31]. There was no significant difference ( $P > 0.05$ ) [31].

Percentage of BIC with autogenous bone graft compared with blood coagulum including either replacement of the lateral bone window or barrier membrane coverage were 93.5 (3.3), 93.5 (3.3) and 92 (4.1) after seven months, respectively [36]. There was no significant difference ( $P = 0.502$ ) [36].

## Summary

BIC after MSFA with autogenous bone graft was comparable to alternate grafting material consistent of 80% xenograft mixed with 20% autogenous bone graft or blood coagulum.

## Total bone volume

Percentage of TBV with autogenous bone graft was 40.9 (3.3), 42.2 (4.5), 43.7 (2.4), and 45.1 (38.1) after four, five, six, and 16 months, respectively [30]. Corresponding measurements for 50% BioGran® and 50% autogenous bone graft were 28.5 (1.4), 34.5 (1.6), 38.1 (5.7), and 44.5. No statistical analysis was performed [30].

Percentage of TBV with autogenous bone graft compared with Cerasorb® was 41 (10) and 17.5 (5) after six months, respectively [32].

**Table 2.** Histomorphometric outcomes after maxillary sinus floor augmentation with autogenous bone graft compared with alternate grafting materials

Study	Year of publication	Number of patients	Materials and methods					Outcome measures							
			Maxillary sinus floor augmentation	RBH (mm)	Type of grafting material	Length of observation period (months)	Number of biopsies	Bone-to-implant contact (%)	Bone regeneration						
									TBV, BAF or NFB				Non-mineralized tissue		Residual graft
									Mean (SD)				Mean (SD)		
Tadjoedin et al. [30]	2000	10	10	< 3	50% Biogran®; 50% autogenous	4 - 16	36	NR	4 month	5 month	6 month	16 month	NR	NR	
			28.5 (1.4)		34.5 (1.6)				38.1 (5.7)	44.5					
			40.9 (3.3)		42.2 (4.5)				43.7 (2.4)	45.1					
Hallman et al. [31]	2002	21	11	< 5	20% Bio-Oss®; 80% autogenous	6.5	8	54.3 (33.1)	39.9 (8)				NR	12.3 (8.5)	
			11		Autogenous			8	34.6 (9.5)	37.7 (31.3)					
Zerbo et al. [32]	2004	9	9	4 - 8	Cerasorb®	6	32	NR	17 (5)				NR	NR	
			5		Autogenous				41 (10) <sup>a</sup>						
Barone et al. [33]	2005	18	18	< 3	OsteoBiol®	5	NR	NR	67 (14.9)				NR	NR	
			18		Autogenous				70 (19.9)						
Szabó et al. [34]	2005	20	20	< 5	Cerasorb®	6	40	NR	36.5 (6.9)				NR	NR	
			20		Autogenous				38.3 (7.4)						
Bettega et al. [35]	2009	18	9	3	Autogenous mixed with PRP	6	9	NR	43.2				NR	NR	
			9	3.5	Autogenous				50						
Johansson et al. [36]	2013	24	10	4.3	Bloodclot	7	10	93.5 (3.3)	NR				NR	NR	
			10	3.5	Bloodclot and membrane		9	92 (4.1)							
			10	4.3	Autogenous		10	93.5 (3.3)							
Khairy et al. [37]	2013	15	10	< 5	Autogenous mixed with PRP	4 - 6	NR	NR	4 month		6 month		NR	NR	
			27.3 (6.3)		28 (4.1)										
			5		Autogenous				6	NR		39.5 (7.4) <sup>b</sup>			
Schmitt et al. [38]	2013	30	45	2.3	BoneCeramic®	5	14	NR	30.3 (2.2)				55.2 (5.6)	15.2 (2.1)	
				2.5	Bio-Oss®		15		24.9 (5.7)				53.7 (8.1)	21.4 (4.8)	
				2.6	Puros®		12		35.4 (2.8)				64.6 (2.8)	NR	
				2.2	Autogenous		12		42.7 (2.1) <sup>c</sup>				57.3 (2.1)		
Tosta et al. [39]	2013	30	15	4.1	BoneCeramic®	9	NR	NR	Intermediate		Apical		Intermediate	Apical	NR
			33.7 (8.1)		26.7 (3.9)				33.4 (8)	39.6 (11.1)					
			15		Autogenous				41 (4.6) <sup>d</sup>		38.6 (7.5) <sup>e</sup>		59.2 (4.7) <sup>f</sup>	60.6 (7.2) <sup>g</sup>	
Xavier et al. [40]	2015	15	15	≤ 3	Fresh frozen bone	6	15	NR	8.3 (3)				56.8 (7.3)		34.9 (6.4)
			15		Autogenous				8.3 (3.4)				55.6 (14.5)		36.1 (12.8)
Danesh-Sani et al. [41]	2016	10	10	< 5	BoneCeramic®	6 - 8	10	NR	28.2 (8.4)				38.9 (14.9)		32.9 (8.1)
			10		Autogneous				36.8 (11.5) <sup>h</sup>				58.4 (10) <sup>i</sup>		4.8 (2.4) <sup>j</sup>
Pereira et al. [42]	2017	30	10	< 5	Biogran®	6	NR	NR	Intermediate		Apical		Intermediate	Apical	NR
			40.7 (14)		45.6 (13.5)				56.6 (15.3)	47.9 (12.1)					
			33.2 (13.3)		45.8 (13.9)				62.5 (14.7)	48.8 (17.7)					
			35.3 (14.7)		39.9 (15.8)				61.2 (15.7)	57.8 (16.2)					
Pereira et al. [43]	2017	22	12	< 5	chronOS®	6	NR	NR	Intermediate		Apical		Intermediate	Apical	NR
			47.6 (9.9)		44.8 (22.1)				52.3 (9.9)	55.1 (22.1)					
			32.5 (13.7)		32.8 (16)				60.1 (13.9)	55.5 (9.2)					
			31 (13)		46.1 (16.3)				65 (10.2)	50.2 (14.5)					
Menezes et al. [44]	2018	21	14	< 5	50% Biogran®; 50% autogenous	6	NR	NR	Intermediate		Apical		NR	NR	
			33.2 (13.3)		45.8 (13.8)										
			13		Autogenous				35 (13.9)		42 (16.6)				
Pereira et al. [45]	2018	10	12	< 5	Biogran®	6	NR	NR	52.1				NR	NR	
		7	9		50% Biogran®; 50% autogenous				57.4						
		10	12		Autogenous bone				57.2						

<sup>a</sup>P < 0.05 (Independent t-test); <sup>b</sup>P = 0.003 (Paired t-test); <sup>c</sup>P = 0.0001 (Kruskal-Wallis test); <sup>d</sup>P = 0.008 (Mann-Whitney test); <sup>e</sup>P < 0.0001 (Mann-Whitney test); <sup>f</sup>P < 0.0001 (Mann-Whitney test); <sup>g</sup>P < 0.0001 (Mann-Whitney test); <sup>h</sup>P = 0.0032 (Paired t-test); <sup>i</sup>P = 0.0001 (Paired t-test); <sup>j</sup>P < 0.0001 (Paired t-test). BAF = bone area fraction; NFB = newly formed bone; NMT = non-mineralized tissue; PRP = platelet rich plasma; RBH = residual bone height; RCT = randomized controlled trial; SD = standard deviation; TBV = total bone volume.

The difference was significant demonstrating higher TBV with autogenous bone graft ( $P = 0.05$ ) [32].

Percentage of TBV with autogenous bone graft compared with OsteoBio1® was 70 (19.9) and 67 (14.9) after five months, respectively [33]. There was no significant difference ( $P > 0.05$ ) [33].

Percentage of TBV with autogenous bone graft compared with Cerasorb® were 38.3 (7.4) and 36.5 (6.9) after six months, respectively [34]. There was no significant difference ( $P = 0.25$ ) [34].

Percentage of TBV with autogenous bone graft compared with platelet-rich plasma mixed with autogenous bone graft was 50 (range 38 to 70) and 43.2 (range 40 to 54.8) after six months, respectively [35]. There was no significant difference ( $P = 0.474$ ) [35].

Percentage of TBV with autogenous bone graft was 39.5 (7.4) after six months [37]. Corresponding measurements for platelet-rich plasma mixed with autogenous bone graft were 27.3 (6.3) and 28 (4.1) after four and six months, respectively. The difference was significant demonstrating higher TBV with autogenous bone graft ( $P = 0.003$ ) [37].

Percentage of TBV with autogenous bone graft compared with mixture of 50% Biogran® and 50% autogenous bone graft or Biogran® alone were 52.1, 57, and 57.2 after six months, respectively [41]. There was no significant difference ( $P > 0.05$ ) [45].

### Summary

TBV after MSFA with autogenous bone graft was comparable with alternate grafting materials consistent of synthetic bone graft or xenograft alone as well as autogenous bone graft mixed with synthetic bone graft or platelet-rich plasma. However, TBV was statistically significant higher with autogenous bone graft compared with synthetic bone graft alone or platelet-rich plasma mixed with autogenous bone graft in other studies with similar observation period. Thus, percentage of TBV seems to be equivalent or enhanced after MSFA with autogenous bone graft compared with alternate grafting materials.

### Bone area fraction

Percentage of BAF with autogenous bone graft compared with mixture of 80% Bio-Oss® and 20% autogenous bone graft was 37.7 (31.3) and 39.9 (8) after six months, respectively [31]. There was no significant difference ( $P > 0.05$ ) [31].

Percentage of BAF with autogenous bone graft was 42.7 (2.1) after five months [38]. Corresponding measurement for BoneCeramic®, Bio-Oss®

and Puros® were 30.3 (2.2), 24.9 (5.7) and 35.4 (2.8), respectively. The difference was significant demonstrating higher BAF with autogenous bone graft compared with BoneCeramic® ( $P < 0.000$ ) and Bio-Oss® ( $P < 0.000$ ) [38].

Percentage of BAF with autogenous bone graft compared with BoneCeramic® in the intermediate region of the biopsies were 41 (4.6) and 33.7 (8.1) after nine months, respectively [39]. Corresponding measurements in the apical region of the biopsies were 38.6 (7.5) and 26.7 (3.9). The difference was significant demonstrating higher BAF with autogenous bone graft in the intermediate region ( $P = 0.008$ ) and apical region ( $P < 0.001$ ), respectively [39].

### Summary

BAF after MSFA with autogenous bone graft was comparable with alternate grafting materials consistent of allogeneic bone graft alone and autogenous bone graft mixed with xenograft. However, BAF was statistically significant higher with autogenous bone graft compared with synthetic bone graft or xenograft alone in other studies with similar observation period. Thus, percentage of BAF seems to be equivalent or enhanced after MSFA with autogenous bone graft compared with alternate grafting materials.

### Newly formed bone

Percentage of newly formed bone with autogenous bone graft compared with fresh frozen bone were 8.3 (3.4) and 8.3 (3) after six months, respectively [40]. There was no significant difference ( $P > 0.05$ ) [40].

Percentage of newly formed bone with autogenous bone graft compared with BoneCeramic® were 36.8 (11.5) and 28.2 (8.4) after six months, respectively [41]. The difference was significant demonstrating more newly formed bone with autogenous bone graft ( $P = 0.0032$ ) [41].

Percentage of newly formed bone with autogenous bone graft compared with mixture of 50% Biogran® and 50% autogenous bone graft or Biogran® alone in the intermediate region of the biopsies were 35.3 (14.7), 33.2 (13.3), and 40.7 (14) after six months, respectively [42]. Corresponding measurements in the apical region of the biopsies were 39.9 (15.8), 45.8 (13.9), and 45.6 (13.5). There was no significant difference between the different graft compositions in either the intermediate or apical region of the biopsies ( $P > 0.05$ ) [42].

Percentage of newly formed bone with autogenous



bone graft compared with mixture of 50% chronOS® and 50% autogenous bone graft or chronOS® alone in the intermediate region of the biopsies were 31 (13), 32.5 (13.7), and 47.6 (9.9) after six months, respectively [43]. Corresponding measurements in the apical region of the biopsies were 46.1 (16.3), 32.8 (16), and 44.8 (22.1). There was no significant difference in either the intermediate or apical region of the biopsies between the two treatment modalities ( $P > 0.05$ ) [43].

Percentage of newly formed bone with autogenous bone graft compared with mixture of 50% Biogran® and 50% autogenous bone graft in the intermediate region of the biopsies were 35 (13.9) and 33.2 (13.3) after six months, respectively [44]. Corresponding measurements in the apical region of the biopsies were 42 (16.6) and 45.8 (13.8). There was no significant difference in either the intermediate or apical region of the biopsies between the two treatment modalities ( $P > 0.05$ ) [44].

### Summary

Percentage of newly formed bone after MSFA with autogenous bone graft was comparable with alternate grafting materials consistent of allogeneic bone graft or synthetic biomaterials and autogenous bone graft mixed with synthetic biomaterials. However, percentage of newly formed bone was statistically significant higher with autogenous bone graft compared with synthetic biomaterials in other studies with similar observation period. Thus, percentage of newly formed bone seems to be equivalent or higher after MSFA with autogenous bone graft compared with alternate grafting materials.

### Meta-analysis

A meta-analysis can only be conducted for continuous data if both the mean and standard deviation are available. Thirteen studies met the inclusion requirement for the meta-analysis [30-34,37-44], and the remaining three studies [35,36,45] were excluded. However, the included studies of the meta-analysis revealed variations in study design, i.e. residual height of the alveolar process, harvesting of autogenous bone graft from dissimilar locations, with or without barrier membrane coverage of the lateral window, number of biopsies, bone cores for histomorphometric analysis were retrieved at different locations, and histomorphometric parameters were presented differently. A forest plot was drawn to show a summary of total amount of bone including values of TBV, BAF and newly formed bone,

respectively. Solely values retrieved from the apical part of the biopsies were included in the meta-analysis, when histomorphometric outcome from both the intermediate and apical part of the biopsy were reported [39,42-44]. Random effect analysis and test for heterogeneity was inconclusive due to the limited number of studies included. Statistically significant difference in heterogeneity between the included studies was found for allogeneic bone graft ( $I^2 = 96.92\%$ ,  $P = 0.001$ ) [38,40], xenograft ( $I^2 = 83.95\%$ ,  $P = 0.01$ ) [33,38] and synthetic biomaterials ( $I^2 = 92.01\%$ ,  $P = 0.001$ ) [32,34,38,39,41-44]. Studies assessing synthetic biomaterials mixed with autogenous bone graft disclosed substantial heterogeneity ( $I^2 = 66.9\%$ ,  $P = 0.11$ ) [30,42,43]. Meta-analysis revealed an overall mean difference of  $-7.1\%$  (95% CI =  $-11$  to  $-3.2$ ) indicating a statistically significant higher amount of bone after MSFA with autogenous bone graft alone compared with alternate grafting materials. Subgroup analysis disclosed a non-significantly differences of  $-3.7\%$  (95% CI =  $-10.9$  to  $3.4$ ),  $-11.5\%$  (95% CI =  $-25.9$  to  $2.8$ ),  $2.2\%$  (95% CI =  $-16.9$  to  $21.3$ ), and  $-4.6\%$  (95% CI =  $-14.4$  to  $5.2$ ), when autogenous bone graft alone was compared with allogeneic bone graft, xenograft, composite grafting materials involving xenograft or synthetic biomaterial mixed with autogenous bone graft, respectively (Figure 2).

A funnel plot of the included studies is presented (Figure 3). Larger studies with higher power are placed towards the top (smaller standard errors), while lower powered studies are placed towards the bottom. Eggers test did not indicate small-study effects ( $P = 0.08$ ).

### Quality assessment

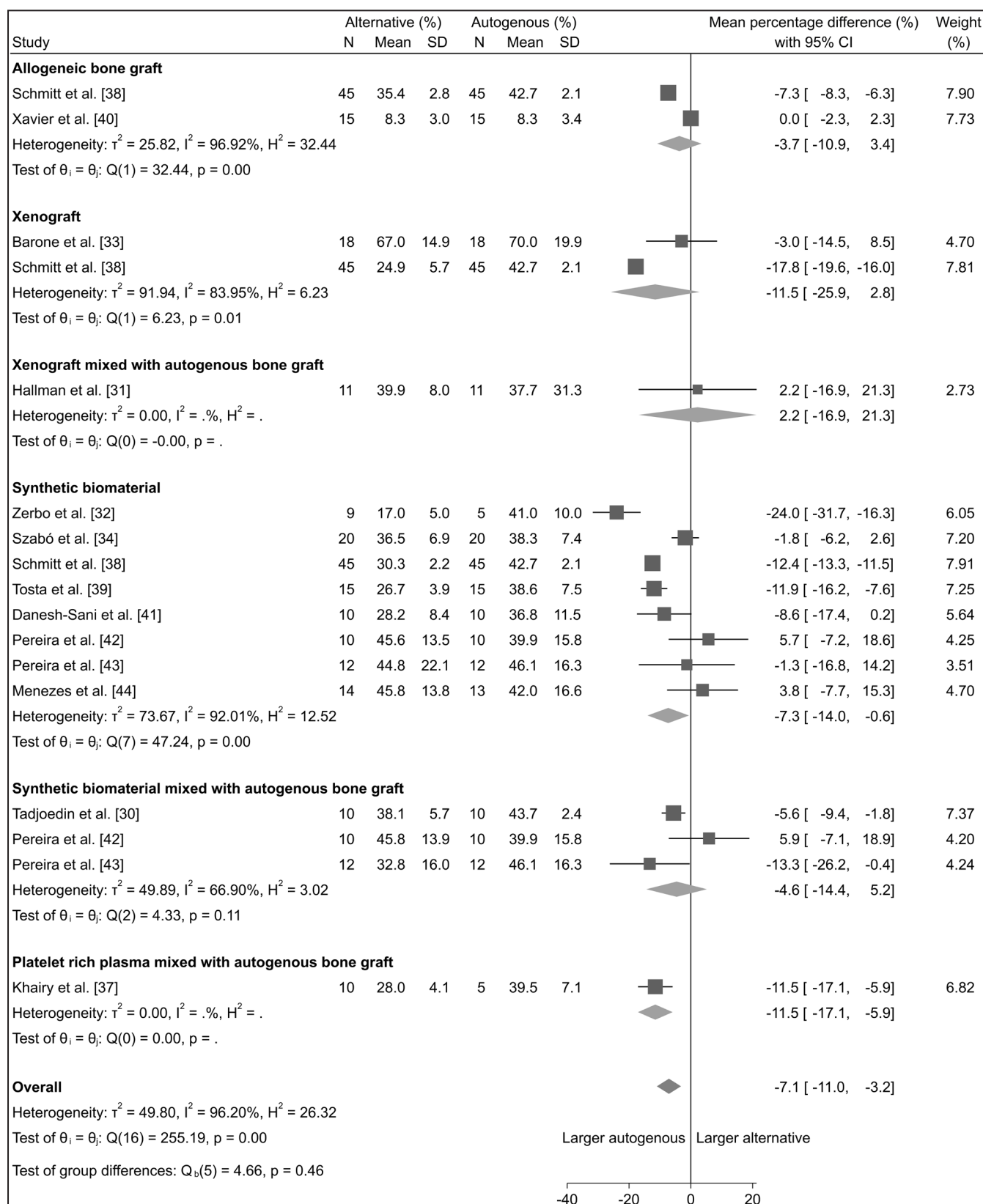
The quality of the included studies is summarized in Table 3. All the included studies were characterized by unclear risk of bias [30-45].

## DISCUSSION

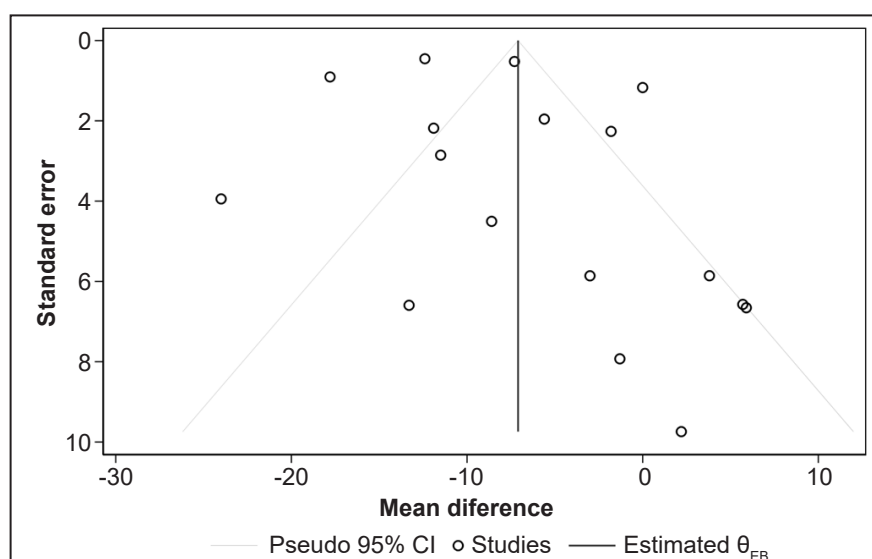
The objective of the present systematic review and meta-analysis was to test the hypothesis of no difference in histomorphometric outcomes after MSFA with autogenous bone graft alone compared with alternate grafting materials. The electronic search and hand-searching resulted in 1068 entries after duplicates have been removed. Sixteen randomized controlled trials with unclear risk of bias fulfilled inclusion criteria and were included in the final synthesis [30-45].

Descriptive statistics demonstrated that the percentage of BIC, TBV, BAF and newly formed bone were equivalent or higher with autogenous bone graft compared with alternate grafting materials [30-45].

Meta-analysis demonstrated significantly improved histomorphometric outcomes after MSFA with autogenous bone graft compared with alternate grafting materials. However, subgroup analysis



**Figure 2.** Meta-analysis using a random effect model assessing total amount of bone after maxillary sinus floor augmentation with autogenous bone graft alone compared with alternate grafting materials.



**Figure 3.** Funnel plot to visualized heterogeneity among the included studies. Larger studies with higher power are placed towards the top (smaller standard errors) and lower powered studies towards the bottom. An asymmetry in the funnel plot indicate bias. Eggers test did not indicate small-study effects (P-value = 0.08).

**Table 3.** Quality assessment of included studies

Author	Random sequence generation	Allocation concealment	Patient blinding	Outcome blinding	Incomplete outcome data addressed	Selective reporting
Tadjoedin et al. [30]	+	?	?	?	+	+
Hallman et al. [31]	+	?	?	?	+	+
Zerbo et al. [32]	+	+	?	?	+	+
Barone et al. [33]	+	?	?	?	+	+
Szabó et al. [34]	+	?	?	?	+	+
Bettega et al. [35]	+	?	?	?	+	+
Johansson et al. [36]	+	?	?	?	+	+
Khairy et al. [37]	+	+	?	?	+	+
Schmitt et al. [38]	+	?	?	?	+	+
Tosta et al. [39]	+	?	?	?	+	+
Xavier et al. [40]	+	?	?	?	+	+
Danesh-Sani et al. [41]	+	?	?	?	+	+
Pereira et al. [42]	+	?	?	?	+	+
Pereira et al. [43]	+	?	?	?	+	+
Menezes et al. [44]	+	?	?	?	+	+
Pereira et al. [45]	+	?	?	?	+	+

+ = low risk of bias; ÷ = high risk of bias; ? = unclear risk of bias.

revealed a non-significantly differences, when autogenous bone graft was compared with allogeneic bone graft or xenograft as well as composite grafting materials consist of xenograft or synthetic biomaterial mixed with autogenous bone graft. The included studies presented to some extent opposing results and conclusions drawn from the results of the present systematic review and meta-analysis should therefore be interpreted with caution. Moreover, histomorphometric outcomes after MSFA are influenced by various confounding factors including

sinus cavity dimensions, size of the lateral window, barrier membrane coverage of the lateral window, and retrieval of bone cores for histomorphometric analysis at different locations [58-61]. Varying degree of heterogeneity according to these parameters were present among the included studies [30-45]. Thus, the histomorphometric outcomes of the present systematic review are not factual comparable and influenced by various methodological confounding factors, which has not been assessed.

Osseointegration is defined as a direct structural and functional connection between living bone and the surface of a load-carrying implant [62]. Placement of implants in pristine or augmented bone elicits a sequence of biological events at the bone-to-implant interface, which influence the degree of osseointegration and percentage of BIC [63-65]. Numerous factors seem to enhance or inhibit osseointegration during the healing process including bone quality and quantity, implant surface characteristics and intrinsic healing potential [63-65]. Establishment of osseointegration and BIC of 50 - 80% are considered as a prerequisite for implant loading and long-term implant survival [17,65,66]. The ideal grafting material for MSFA should therefore ensure the highest BIC within the shortest healing period. Autogenous bone graft accelerates bone regeneration due to its osteoinductive, osteogenic and osteoconductive characteristics, while bone substitutes solely provide an osteoconductive framework and relies on recruitment and migration of osteogenic cells to the implant surface. Thus, from a theoretical point of view, autogenous bone graft alone or in combination with a bone substitute are expected to facilitate a higher percentage of BIC compared with bone substitute alone, which have been demonstrated in an experimental study revealing statistically significantly higher BIC values after MSFA with autogenous bone graft alone or in combination with different ratios of xenograft compared with xenograft alone [23]. However, none of the included studies of the present systematic review reported a higher percentage of BIC with autogenous bone graft alone compared with alternate grafting materials [31,36]. Moreover, BIC was considerably lower after MSFA with autogenous bone graft alone compared with mixture of autogenous bone graft and xenograft [31]. A previous published systematic review in animals concluded that BIC increases with the length of the observation period, but a healing period of more than eight months seemed not to improve BIC substantially in conjunction with MSFA [67]. In the present systematic review, BIC was assessed after 6.5 months and seven months, respectively [31,36]. In conclusion, MSFA with autogenous bone graft alone seems not to significantly improve percentage of BIC compared with alternate grafting materials. Though, this assumption should be interpreted with caution, since only two studies assessing BIC were included in the present systematic review [31,36].

Histological analysis present qualitative data of bone regeneration, while histomorphometric analysis focuses on the quantitative data. Percentage of TBV, BAF and newly formed bone are commonly used

for quantitatively assessment of mineralization in conjunction with alveolar ridge augmentation [17]. The included studies of the present systematic review demonstrated that the percentage of TBV, BAF and newly formed bone after MSFA with autogenous bone graft alone varied between 37.7% to 70% [30-35,37-45]. Corresponding measurements for synthetic biomaterials, xenograft and allogeneic bone graft were 17 - 52.1% [32,34,38,41-45], 24.9 - 67% [33,38], and 8.3 - 35.4% [38,40], respectively. Values for composite grafting materials including autogenous bone graft mixed with different ratios of synthetic biomaterials, xenograft or platelet-rich plasma were 28.5 - 57.4% [30,42-45], 39.9% [31], and 28 - 43.2% [35,37], respectively. Descriptive statistics seems to indicate that percentage of TBV, BAF and newly formed bone after MSFA with autogenous bone graft alone is comparable or higher compared with alternate grafting materials, which is in accordance with conclusion of a previous systematic review and meta-analysis [17].

Microcomputed tomography analysis of bone biopsies harvested in the pristine non-atrophic posterior maxilla have demonstrated a mean bone volume fraction of 51.9% (28.4) [68]. A previous study comparing bone biopsies obtained from pristine non-atrophic posterior maxilla with biopsies from the augmented region after MSFA with autogenous bone graft mixed with xenograft revealed no statistically significant difference in histomorphometric outcomes [69]. These results are in accordance with the present systematic review disclosing no statistically significant differences in the histomorphometric outcomes between pristine bone compared with the intermediate or apical region after MSFA with autogenous bone graft, synthetic biomaterials or autogenous bone graft mixed with synthetic biomaterials, after six months [42-44]. However, a statistically significant higher percentage of mineralized bone was reported in the pristine bone region compared with the augmented region after MSFA with a synthetic biomaterial, whereas no significant differences was revealed with the use of autogenous bone graft, after nine months [39]. The histomorphometric outcome after MSFA with autogenous bone graft alone or in combination with a bone substitute seems therefore comparable with pristine bone.

A systematic review is a detailed and comprehensive search strategy of published literature, which attempts to gather all available empirical research by using clearly defined, systematic methods to obtain answers to a well-defined research question. Meta-analysis is the statistical synthesis for meticulous analysing



and combining the numerical data withdrawal from comparable studies. The strength of evidence from a systematic review and meta-analysis is therefore related to the quality of the included studies. The histomorphometric outcomes of the present systematic review and meta-analysis are based on randomized controlled trials with an unclear risk of bias and various methodological confounding factors [30-45]. Consequently, the current level of evidence is inadequate to propose specified implications for evidence based clinical guidelines according to the focus question of the present systematic review, though MSFA with autogenous bone graft alone seems to improve histomorphometric outcomes compared with alternate grafting materials.

## CONCLUSIONS

The present systematic review and meta-analysis revealed a statistically significant difference in histomorphometric outcome after maxillary sinus floor augmentation with autogenous bone graft alone compared with alternate grafting materials.

Autogenous bone graft alone or in combination with a bone substitute is therefore considered to be the optimal grafting material for maxillary sinus floor augmentation. Bone substitutes alone seem to be a valid alternative, when harvesting of autogenous bone graft is not an option. However, the included studies of the present systematic review are characterised by an unclear risk of bias and various methodological confounding factors. Hence, the conclusions drawn from the results of the present systematic review should be interpreted with caution.

## ACKNOWLEDGMENTS AND DISCLOSURE STATEMENTS

The authors declare that there are no financial or other conflicts of interest related to this publication. The authors would like to give a special thanks to Conni Skrubbeltrang (Head of Medical Library, Aalborg University Hospital, Aalborg, Denmark) for her assistance with the search strategy. There were no sources of funding for this systematic review.

## REFERENCES

1. Boyne PJ, James RA. Grafting of the maxillary sinus floor with autogenous marrow and bone. *J Oral Surg.* 1980 Aug;38(8):613-6. [Medline: [6993637](#)]
2. Tatum H Jr. Maxillary and sinus implant reconstructions. *Dent Clin North Am.* 1986 Apr;30(2):207-29. [Medline: [3516738](#)]
3. Starch-Jensen T, Aludden H, Hallman M, Dahlin C, Christensen AE, Mordenfeld A. A systematic review and meta-analysis of long-term studies (five or more years) assessing maxillary sinus floor augmentation. *Int J Oral Maxillofac Surg.* 2018 Jan;47(1):103-116. [Medline: [28545806](#)] [doi: [10.1016/j.ijom.2017.05.001](#)]
4. Starch-Jensen T, Mordenfeld A, Becktor JP, Jensen SS. Maxillary Sinus Floor Augmentation With Synthetic Bone Substitutes Compared With Other Grafting Materials: A Systematic Review and Meta-analysis. *Implant Dent.* 2018 Jun;27(3):363-374. [Medline: [29771732](#)] [doi: [10.1097/ID.0000000000000768](#)]
5. Starch-Jensen T, Jensen JD. Maxillary Sinus Floor Augmentation: a Review of Selected Treatment Modalities. *J Oral Maxillofac Res.* 2017 Sep 30;8(3):e3. [Medline: [29142655](#)] [PMC free article: [5676313](#)] [doi: [10.5037/jomr.2017.8303](#)]
6. Jensen T, Schou S, Stavropoulos A, Terheyden H, Holmstrup P. Maxillary sinus floor augmentation with Bio-Oss or Bio-Oss mixed with autogenous bone as graft: a systematic review. *Clin Oral Implants Res.* 2012 Mar;23(3):263-73. [Medline: [21443592](#)] [doi: [10.1111/j.1600-0501.2011.02168.x](#)]
7. Raghoobar GM, Onclin P, Boven GC, Vissink A, Meijer HJA. Long-term effectiveness of maxillary sinus floor augmentation: A systematic review and meta-analysis. *J Clin Periodontol.* 2019 Jun;46 Suppl 21:307-318. [Medline: [30624789](#)] [doi: [10.1111/jcpe.13055](#)]
8. Antonoglou GN, Stavropoulos A, Samara MD, Ioannidis A, Benic GI, Papageorgiou SN, Sándor GK. Clinical Performance of Dental Implants Following Sinus Floor Augmentation: A Systematic Review and Meta-Analysis of Clinical Trials with at Least 3 Years of Follow-up. *Int J Oral Maxillofac Implants.* 2018 May/Jun;33(3):e45-e65. [Medline: [29763503](#)] [doi: [10.11607/jomi.6417](#)]
9. Yang J, Xia T, Wang H, Cheng Z, Shi B. Outcomes of maxillary sinus floor augmentation without grafts in atrophic maxilla: A systematic review and meta-analysis based on randomised controlled trials. *J Oral Rehabil.* 2019 Mar;46(3):282-290. [Medline: [30537184](#)] [doi: [10.1111/joor.12753](#)]
10. Esposito M, Grusovin MG, Rees J, Karasoulos D, Felice P, Alissa R, Worthington H, Coulthard P. Effectiveness of sinus lift procedures for dental implant rehabilitation: a Cochrane systematic review. *Eur J Oral Implantol.* 2010 Spring;3(1):7-26. [Medline: [20467595](#)]

11. Sakkas A, Wilde F, Heufelder M, Winter K, Schramm A. Autogenous bone grafts in oral implantology-is it still a “gold standard”? A consecutive review of 279 patients with 456 clinical procedures. *Int J Implant Dent.* 2017 Dec;3(1):23. [Medline: [28573552](#)] [PMC free article: [5453915](#)] [doi: [10.1186/s40729-017-0084-4](#)]
12. Nissen KJ, Starch-Jensen T. Maxillary Sinus Floor Augmentation With Autogenous Bone Graft From the Ascending Mandibular Ramus. *Implant Dent.* 2019 Feb;28(1):46-53. [Medline: [30475244](#)] [doi: [10.1097/ID.0000000000000845](#)]
13. Maddalone M, Mirabelli L, Venino PM, Karanxha L, Porcaro G, Del Fabbro M. Long-term stability of autologous bone graft of intraoral origin after lateral sinus floor elevation with simultaneous implant placement. *Clin Implant Dent Relat Res.* 2018 Oct;20(5):713-721. [Medline: [30144262](#)] [doi: [10.1111/cid.12649](#)]
14. Clavero J, Lundgren S. Ramus or chin grafts for maxillary sinus inlay and local onlay augmentation: comparison of donor site morbidity and complications. *Clin Implant Dent Relat Res.* 2003;5(3):154-60. [Medline: [14575631](#)] [doi: [10.1111/j.1708-8208.2003.tb00197.x](#)]
15. Nkenke E, Neukam FW. Autogenous bone harvesting and grafting in advanced jaw resorption: morbidity, resorption and implant survival. *Eur J Oral Implantol.* 2014 Summer;7 Suppl 2:S203-17. [Medline: [24977256](#)]
16. Alghamdi HS. Methods to Improve Osseointegration of Dental Implants in Low Quality (Type-IV) Bone: An Overview. *J Funct Biomater.* 2018 Jan 13;9(1):7. [Medline: [29342830](#)] [PMC free article: [5872093](#)] [doi: [10.3390/jfb9010007](#)]
17. Danesh-Sani SA, Engebretson SP, Janal MN. Histomorphometric results of different grafting materials and effect of healing time on bone maturation after sinus floor augmentation: a systematic review and meta-analysis. *J Periodontal Res.* 2017 Jun;52(3):301-312. [Medline: [27534916](#)] [doi: [10.1111/jre.12402](#)]
18. Kim YS, Kim SH, Kim KH, Jhin MJ, Kim WK, Lee YK, Seol YJ, Lee YM. Rabbit maxillary sinus augmentation model with simultaneous implant placement: differential responses to the graft materials. *J Periodontal Implant Sci.* 2012 Dec;42(6):204-11. [Medline: [23346463](#)] [PMC free article: [3543935](#)] [doi: [10.5051/jpis.2012.42.6.204](#)]
19. Sicca CM, Corotti MV, Sgarbosa SH, Cestari TM, Cavalcanti MG, Ferreira PM, Taga R, Granjeiro JM. Comparative histomorphometric and tomographic analysis of maxillary sinus floor augmentation in rabbits using autografts and xenografts. *J Biomed Mater Res B Appl Biomater.* 2008 Jul;86(1):188-96. [Medline: [18161780](#)] [doi: [10.1002/jbm.b.31005](#)]
20. Wada K, Niimi A, Watanabe K, Sawai T, Ueda M. Maxillary sinus floor augmentation in rabbits: a comparative histologic-histomorphometric study between rhBMP-2 and autogenous bone. *Int J Periodontics Restorative Dent.* 2001 Jun;21(3):252-63. [Medline: [11490402](#)]
21. Lee J, Susin C, Rodriguez NA, de Stefano J, Prasad HS, Buxton AN, Wikesjö UM. Sinus augmentation using rhBMP-2/ACS in a mini-pig model: relative efficacy of autogenous fresh particulate iliac bone grafts. *Clin Oral Implants Res.* 2013 May;24(5):497-504. [Medline: [22276816](#)] [doi: [10.1111/j.1600-0501.2011.02419.x](#)]
22. Schlegel KA, Zimmermann R, Thorwarth M, Neukam FW, Klongnoi B, Nkenke E, Felszeghy E. Sinus floor elevation using autogenous bone or bone substitute combined with platelet-rich plasma. *Oral Surg Oral Med Oral Pathol Oral Radiol Endod.* 2007 Sep;104(3):e15-25. [Medline: [17618141](#)] [doi: [10.1016/j.tripleo.2007.04.021](#)]
23. Jensen T, Schou S, Gundersen HJ, Forman JL, Terheyden H, Holmstrup P. Bone-to-implant contact after maxillary sinus floor augmentation with Bio-Oss and autogenous bone in different ratios in mini pigs. *Clin Oral Implants Res.* 2013 Jun;24(6):635-44. [Medline: [22530746](#)] [doi: [10.1111/j.1600-0501.2012.02438.x](#)]
24. Klongnoi B, Rupprecht S, Kessler P, Thorwarth M, Wiltfang J, Schlegel KA. Influence of platelet-rich plasma on a bioglass and autogenous bone in sinus augmentation. An explorative study. *Clin Oral Implants Res.* 2006 Jun;17(3):312-20. [Medline: [16672027](#)] [doi: [10.1111/j.1600-0501.2005.01215.x](#)]
25. Palma VC, Magro-Filho O, de Oliveria JA, Lundgren S, Salata LA, Sennerby L. Bone reformation and implant integration following maxillary sinus membrane elevation: an experimental study in primates. *Clin Implant Dent Relat Res.* 2006;8(1):11-24. [Medline: [16681489](#)] [doi: [10.2310/j.6480.2005.00026.x](#)]
26. Handschel J, Simonowska M, Naujoks C, Depprich RA, Ommerborn MA, Meyer U, Kübler NR. A histomorphometric meta-analysis of sinus elevation with various grafting materials. *Head Face Med.* 2009 Jun 11;5:12. [Medline: [19519903](#)] [PMC free article: [2700082](#)] [doi: [10.1186/1746-160X-5-12](#)]
27. Welch V, Petticrew M, Tugwell P, Moher D, O'Neill J, Waters E, White H; PRISMA-Equity Bellagio group. PRISMA-Equity 2012 extension: reporting guidelines for systematic reviews with a focus on health equity. *PLoS Med.* 2012;9(10):e1001333. [Medline: [23222917](#)] [PMC free article: [3484052](#)] [doi: [10.1371/journal.pmed.1001333](#)]
28. Higgins JPT, Altman DG, Sterne JAC. Chapter 8: assessing risk of bias in included studies. In: Higgins JPT, Green S, editors. *Cochrane handbook for systematic reviews of interventions version 5.1.0* (updated March 2011). The Cochrane Collaboration. 2011. [URL: <http://handbook.cochrane.org/>]
29. Higgins JP, Altman DG, Gøtzsche PC, Jüni P, Moher D, Oxman AD, Savovic J, Schulz KF, Weeks L, Sterne JA; Cochrane Bias Methods Group; Cochrane Statistical Methods Group. The Cochrane Collaboration's tool for assessing risk of bias in randomised trials. *BMJ.* 2011 Oct 18;343:d5928. [Medline: [22008217](#)] [PMC free article: [3196245](#)] [doi: [10.1136/bmj.d5928](#)]
30. Tadjedin ES, de Lange GL, Holzmann PJ, Kulper L, Burger EH. Histological observations on biopsies harvested following sinus floor elevation using a bioactive glass material of narrow size range. *Clin Oral Implants Res.* 2000 Aug;11(4):334-44. [Medline: [11168226](#)] [doi: [10.1034/j.1600-0501.2000.011004334.x](#)]

31. Hallman M, Sennerby L, Lundgren S. A clinical and histologic evaluation of implant integration in the posterior maxilla after sinus floor augmentation with autogenous bone, bovine hydroxyapatite, or a 20:80 mixture. *Int J Oral Maxillofac Implants*. 2002 Sep-Oct;17(5):635-43. [Medline: [12381063](#)]
32. Zerbo IR, Zijdeveld SA, de Boer A, Bronckers AL, de Lange G, ten Bruggenkate CM, Burger EH. Histomorphometry of human sinus floor augmentation using a porous beta-tricalcium phosphate: a prospective study. *Clin Oral Implants Res*. 2004 Dec;15(6):724-32. [Medline: [15533134](#)] [doi: [10.1111/j.1600-0501.2004.01055.x](#)]
33. Barone A, Crespi R, Aldini NN, Fini M, Giardino R, Covani U. Maxillary sinus augmentation: histologic and histomorphometric analysis. *Int J Oral Maxillofac Implants*. 2005 Jul-Aug;20(4):519-25. [Medline: [16161735](#)]
34. Szabó G, Huys L, Coulthard P, Maiorana C, Garagiola U, Barabás J, Németh Z, Hrabák K, Suba Z. A prospective multicenter randomized clinical trial of autogenous bone versus beta-tricalcium phosphate graft alone for bilateral sinus elevation: histologic and histomorphometric evaluation. *Int J Oral Maxillofac Implants*. 2005 May-Jun;20(3):371-81. [Medline: [15973948](#)]
35. Bettega G, Brun JP, Boutonnat J, Cracowski JL, Quesada JL, Hegelhofer H, Drillat P, Richard MJ. Autologous platelet concentrates for bone graft enhancement in sinus lift procedure. *Transfusion*. 2009 Apr;49(4):779-85. [Medline: [19171004](#)] [doi: [10.1111/j.1537-2995.2008.02036.x](#)]
36. Johansson LA, Isaksson S, Bryington M, Dahlin C. Evaluation of bone regeneration after three different lateral sinus elevation procedures using micro-computed tomography of retrieved experimental implants and surrounding bone: a clinical, prospective, and randomized study. *Int J Oral Maxillofac Implants*. 2013 Mar-Apr;28(2):579-86. [Medline: [23527363](#)] [doi: [10.11607/jomi.2892](#)]
37. Khairy NM, Shendy EE, Askar NA, El-Rouby DH. Effect of platelet rich plasma on bone regeneration in maxillary sinus augmentation (randomized clinical trial). *Int J Oral Maxillofac Surg*. 2013 Feb;42(2):249-55. [Medline: [23078753](#)] [doi: [10.1016/j.ijom.2012.09.009](#)]
38. Schmitt CM, Doering H, Schmidt T, Lutz R, Neukam FW, Schlegel KA. Histological results after maxillary sinus augmentation with Straumann® BoneCeramic, Bio-Oss®, Puros®, and autologous bone. A randomized controlled clinical trial. *Clin Oral Implants Res*. 2013 May;24(5):576-85. [Medline: [22324456](#)] [doi: [10.1111/j.1600-0501.2012.02431.x](#)]
39. Tosta M, Cortes AR, Corrêa L, Pinto Ddos S Jr, Tumenas I, Katchburian E. Histologic and histomorphometric evaluation of a synthetic bone substitute for maxillary sinus grafting in humans. *Clin Oral Implants Res*. 2013 Aug;24(8):866-70. [Medline: [22168624](#)] [doi: [10.1111/j.1600-0501.2011.02384.x](#)]
40. Xavier SP, Dias RR, Sehn FP, Kahn A, Chaushu L, Chaushu G. Maxillary sinus grafting with autograft vs. fresh frozen allograft: a split-mouth histomorphometric study. *Clin Oral Implants Res*. 2015 Sep;26(9):1080-5. [Medline: [24734909](#)] [doi: [10.1111/clr.12404](#)]
41. Danesh-Sani SA, Wallace SS, Movahed A, El Chaar ES, Cho SC, Khouly I, Testori T. Maxillary Sinus Grafting With Biphasic Bone Ceramic or Autogenous Bone: Clinical, Histologic, and Histomorphometric Results From a Randomized Controlled Clinical Trial. *Implant Dent*. 2016 Oct;25(5):588-93. [Medline: [27513162](#)] [doi: [10.1097/ID.0000000000000474](#)]
42. Pereira RDS, Menezes JD, Bonardi JP, Griza GL, Okamoto R, Hochuli-Vieira E. Histomorphometric and immunohistochemical assessment of RUNX2 and VEGF of Biogran™ and autogenous bone graft in human maxillary sinus bone augmentation: A prospective and randomized study. *Clin Implant Dent Relat Res*. 2017 Oct;19(5):867-875. [Medline: [28608398](#)] [doi: [10.1111/cid.12507](#)]
43. Pereira RS, Gorla LF, Boos FBJD, Okamoto R, Garcia Júnior IR, Hochuli-Vieira E. Use of autogenous bone and beta-tricalcium phosphate in maxillary sinus lifting: histomorphometric study and immunohistochemical assessment of RUNX2 and VEGF. *Int J Oral Maxillofac Surg*. 2017 Apr;46(4):503-510. [Medline: [28185708](#)] [doi: [10.1016/j.ijom.2017.01.002](#)]
44. Menezes JD, Pereira RDS, Bonardi JP, Griza GL, Okamoto R, Hochuli-Vieira E. Bioactive glass added to autogenous bone graft in maxillary sinus augmentation: a prospective histomorphometric, immunohistochemical, and bone graft resorption assessment. *J Appl Oral Sci*. 2018 Jun 11;26:e20170296. [Medline: [29898173](#)] [PMC free article: [6007965](#)] [doi: [10.1590/1678-7757-2017-0296](#)]
45. Pereira RS, Menezes JD, Bonardi JP, Griza GL, Okamoto R, Hochuli-Vieira E. Comparative study of volumetric changes and trabecular microarchitecture in human maxillary sinus bone augmentation with bioactive glass and autogenous bone graft: a prospective and randomized assessment. *Int J Oral Maxillofac Surg*. 2018 May;47(5):665-671. [Medline: [29246424](#)] [doi: [10.1016/j.ijom.2017.11.016](#)]
46. Tadjoeidin ES, de Lange GL, Lyaruu DM, Kuiper L, Burger EH. High concentrations of bioactive glass material (BioGran) vs. autogenous bone for sinus floor elevation. *Clin Oral Implants Res*. 2002 Aug;13(4):428-36. [Medline: [12175381](#)] [doi: [10.1034/j.1600-0501.2002.130412.x](#)]
47. Consolo U, Zaffe D, Bertoldi C, Ceccherelli G. Platelet-rich plasma activity on maxillary sinus floor augmentation by autologous bone. *Clin Oral Implants Res*. 2007 Apr;18(2):252-62. [Medline: [17348891](#)] [doi: [10.1111/j.1600-0501.2006.01330.x](#)]
48. Zijdeveld SA, Zerbo IR, van den Bergh JP, Schulten EA, ten Bruggenkate CM. Maxillary sinus floor augmentation using a beta-tricalcium phosphate (Cerasorb) alone compared to autogenous bone grafts. *Int J Oral Maxillofac Implants*. 2005 May-Jun;20(3):432-40. [Medline: [15973955](#)]



49. Scarano A, Degidi M, Iezzi G, Pecora G, Piattelli M, Orsini G, Caputi S, Perrotti V, Mangano C, Piattelli A. Maxillary sinus augmentation with different biomaterials: a comparative histologic and histomorphometric study in man. *Implant Dent*. 2006 Jun;15(2):197-207. [Medline: [16766904](#)] [doi: [10.1097/01.id.0000220120.54308.f3](#)]
50. Suba Z, Takács D, Matusovits D, Barabás J, Fazekas A, Szabó G. Maxillary sinus floor grafting with beta-tricalcium phosphate in humans: density and microarchitecture of the newly formed bone. *Clin Oral Implants Res*. 2006 Feb;17(1):102-8. [Medline: [16441791](#)] [doi: [10.1111/j.1600-0501.2005.01166.x](#)]
51. Thor A, Franke-Stenport V, Johansson CB, Rasmusson L. Early bone formation in human bone grafts treated with platelet-rich plasma: preliminary histomorphometric results. *Int J Oral Maxillofac Surg*. 2007 Dec;36(12):1164-71. [Medline: [17855054](#)] [doi: [10.1016/j.ijom.2007.05.023](#)]
52. de Castilho TR, Tortamano P, Marotti J, de Andrade JC Jr, Chilvarquer I, Ximenez ME, Alves MT. Clinical and Histomorphometric Evaluation of Fresh Frozen Bone Allograft in Sinus Lift Surgery. *Clin Implant Dent Relat Res*. 2016 Feb;18(1):40-50. [Medline: [24909241](#)] [doi: [10.1111/cid.12234](#)]
53. Schaaf H, Streckbein P, Lendeckel S, Heidinger K, Görtz B, Bein G, Boedeker RH, Schlegel KA, Howaldt HP. Topical use of platelet-rich plasma to influence bone volume in maxillary augmentation: a prospective randomized trial. *Vox Sang*. 2008 Jan;94(1):64-9. [Medline: [18005082](#)] [doi: [10.1111/j.1423-0410.2007.00997.x](#)]
54. de Faria Vasconcelos K, Dos Santos Corpas L, da Silveira BM, Laperre K, Padovan LE, Jacobs R, de Freitas PH, Lambrechts I, Bóscolo FN. MicroCT assessment of bone microarchitecture in implant sites reconstructed with autogenous and xenogenous grafts: a pilot study. *Clin Oral Implants Res*. 2017 Mar;28(3):308-313. [Medline: [26932194](#)] [doi: [10.1111/clr.12799](#)]
55. Raghoobar GM, Schortinghuis J, Liem RS, Ruben JL, van der Wal JE, Vissink A. Does platelet-rich plasma promote remodeling of autologous bone grafts used for augmentation of the maxillary sinus floor? *Clin Oral Implants Res*. 2005 Jun;16(3):349-56. [Medline: [15877756](#)] [doi: [10.1111/j.1600-0501.2005.01115.x](#)]
56. Bonardi JP, Pereira RDS, Boos Lima FBDJ, Faverani LP, Griza GL, Okamoto R, Hochuli-Vieira E. Prospective and Randomized Evaluation of ChronOS and Bio-Oss in Human Maxillary Sinuses: Histomorphometric and Immunohistochemical Assignment for Runx 2, Vascular Endothelial Growth Factor, and Osteocalcin. *J Oral Maxillofac Surg*. 2018 Feb;76(2):325-335. [Medline: [29100829](#)] [doi: [10.1016/j.joms.2017.09.020](#)]
57. Ahmed M, Abu Shama A, Hamdy RM, Ezz M. Bioresorbable versus titanium space-maintaining mesh in maxillary sinus floor elevation: a split-mouth study. *Int J Oral Maxillofac Surg*. 2017 Sep;46(9):1178-1187. [Medline: [28476313](#)] [doi: [10.1016/j.ijom.2017.04.001](#)]
58. Starch-Jensen T, Deluiz D, Duch K, Tinoco EMB. Maxillary Sinus Floor Augmentation With or Without Barrier Membrane Coverage of the Lateral Window: a Systematic Review and Meta-Analysis. *J Oral Maxillofac Res*. 2019 Dec 30;10(4):e1. [Medline: [32158525](#)] [PMC free article: [7012617](#)] [doi: [10.5037/jomr.2019.10401](#)]
59. Avila G, Wang HL, Galindo-Moreno P, Misch CE, Bagramian RA, Rudek I, Benavides E, Moreno-Riestra I, Braun T, Neiva R. The influence of the bucco-palatal distance on sinus augmentation outcomes. *J Periodontol*. 2010 Jul;81(7):1041-50. [Medline: [20450402](#)] [doi: [10.1902/jop.2010.090686](#)]
60. Bertl K, Mick RB, Heimel P, Gahleitner A, Stavropoulos A, Ulm C. Variation in bucco-palatal maxillary sinus width does not permit a meaningful sinus classification. *Clin Oral Implants Res*. 2018 Dec;29(12):1220-1229. [Medline: [30430654](#)] [doi: [10.1111/clr.13387](#)]
61. Avila-Ortiz G, Wang HL, Galindo-Moreno P, Misch CE, Rudek I, Neiva R. Influence of lateral window dimensions on vital bone formation following maxillary sinus augmentation. *Int J Oral Maxillofac Implants*. 2012 Sep-Oct;27(5):1230-8. [Medline: [23057039](#)]
62. Parithimarkalaignan S, Padmanabhan TV. Osseointegration: an update. *J Indian Prosthodont Soc*. 2013 Mar;13(1):2-6. [Medline: [24431699](#)] [PMC free article: [3602536](#)] [doi: [10.1007/s13191-013-0252-z](#)]
63. Guglielmotti MB, Olmedo DG, Cabrini RL. Research on implants and osseointegration. *Periodontol*. 2000. 2019 Feb;79(1):178-189. [Medline: [30892769](#)] [doi: [10.1111/prd.12254](#)]
64. Elias CN, Meirelles L. Improving osseointegration of dental implants. *Expert Rev Med Devices*. 2010 Mar;7(2):241-56. [Medline: [20214429](#)] [doi: [10.1586/erd.09.74](#)]
65. Bosshardt DD, Chappuis V, Buser D. Osseointegration of titanium, titanium alloy and zirconia dental implants: current knowledge and open questions. *Periodontol*. 2000. 2017 Feb;73(1):22-40. [Medline: [28000277](#)] [doi: [10.1111/prd.12179](#)]
66. Lian Z, Guan H, Ivanovski S, Loo YC, Johnson NW, Zhang H. Effect of bone to implant contact percentage on bone remodelling surrounding a dental implant. *Int J Oral Maxillofac Surg*. 2010 Jul;39(7):690-8. [Medline: [20418064](#)] [doi: [10.1016/j.ijom.2010.03.020](#)]
67. Jensen T, Schou S, Stavropoulos A, Terheyden H, Holmstrup P. Maxillary sinus floor augmentation with Bio-Oss or Bio-Oss mixed with autogenous bone as graft in animals: a systematic review. *Int J Oral Maxillofac Surg*. 2012 Jan;41(1):114-20. [Medline: [22000958](#)] [doi: [10.1016/j.ijom.2011.08.010](#)]
68. Monje A, González-García R, Monje F, Chan HL, Galindo-Moreno P, Suarez F, Wang HL. Microarchitectural pattern of pristine maxillary bone. *Int J Oral Maxillofac Implants*. 2015 Jan-Feb;30(1):125-32. [Medline: [25153004](#)] [doi: [10.11607/jomi.3681](#)]



69. Galindo-Moreno P, Moreno-Riestra I, Avila G, Fernández-Barbero JE, Mesa F, Aguilar M, Wang HL, O'Valle F. Histomorphometric comparison of maxillary pristine bone and composite bone graft biopsies obtained after sinus augmentation. Clin Oral Implants Res. 2010 Jan;21(1):122-8. [Medline: [19845707](#)] [doi: [10.1111/j.1600-0501.2009.01814.x](#)]

**To cite this article:**

Starch-Jensen T, Deluiz D, Bruun NH, Tinoco EMB.

Maxillary Sinus Floor Augmentation with Autogenous Bone Graft Alone Compared with Alternate Grafting Materials: a Systematic Review and Meta-Analysis Focusing on Histomorphometric Outcome

J Oral Maxillofac Res 2020;11(3):e2

URL: <http://www.ejomr.org/JOMR/archives/2020/3/e2/v11n3e2.pdf>

doi: [10.5037/jomr.2020.11302](#)

**Copyright** © Starch-Jensen T, Deluiz D, Bruun NH, Tinoco EMB. Published in the JOURNAL OF ORAL & MAXILLOFACIAL RESEARCH (<http://www.ejomr.org>), 30 September 2020.

This is an open-access article, first published in the JOURNAL OF ORAL & MAXILLOFACIAL RESEARCH, distributed under the terms of the [Creative Commons Attribution-Noncommercial-No Derivative Works 3.0 Unported License](#), which permits unrestricted non-commercial use, distribution, and reproduction in any medium, provided the original work and is properly cited. The copyright, license information and link to the original publication on (<http://www.ejomr.org>) must be included.

**Appendix 1.** PubMed search until the 25<sup>th</sup> of March, 2020

Search	Add to builder	Query	Items found
<a href="#">#58</a>	<a href="#">Add</a>	Search (((((((“Sinus Floor Augmentation”[Mesh]) OR ((sinus augment*[Text Word] OR sinus floor augment*[Text Word]))) OR ((sinus floor elevat*[Text Word] OR sinus elevat*[Text Word] OR sinus lift*[Text Word]))) AND (((“Bone Transplantation”[Mesh:NoExp]) OR bone transplant*[Text Word]) OR ((Autolog*[Text Word] OR autogen*[Text Word]))) OR graft*[Text Word]) OR “Bone Substitutes”[Mesh])) AND (((((((“Prospective Studies”[Mesh]) OR “Retrospective Studies”[Mesh]) OR “Controlled Clinical Trials as Topic”[Mesh]) OR “Controlled Clinical Trial” [Publication Type])) OR (((randomized[Text Word] OR randomised[Text Word] OR controlled[Text Word] OR prospective*[Text Word] OR retrospektiv*[Text Word])) AND (trial[Text Word] OR trials[Text Word] OR study[Text Word] OR studies[Text Word])))	<a href="#">681</a>
<a href="#">#57</a>	<a href="#">Add</a>	Search (((((((“Prospective Studies”[Mesh]) OR “Retrospective Studies”[Mesh]) OR “Controlled Clinical Trials as Topic”[Mesh]) OR “Controlled Clinical Trial” [Publication Type])) OR (((randomized[Text Word] OR randomised[Text Word] OR controlled[Text Word] OR prospective*[Text Word] OR retrospektiv*[Text Word])) AND (trial[Text Word] OR trials[Text Word] OR study[Text Word] OR studies[Text Word])))	<a href="#">2535650</a>
<a href="#">#56</a>	<a href="#">Add</a>	Search ((randomized[Text Word] OR randomised[Text Word] OR controlled[Text Word] OR prospective*[Text Word] OR retrospektiv*[Text Word])) AND (trial[Text Word] OR trials[Text Word] OR study[Text Word] OR studies[Text Word])	<a href="#">1809479</a>
<a href="#">#55</a>	<a href="#">Add</a>	Search (((“Prospective Studies”[Mesh]) OR “Retrospective Studies”[Mesh]) OR “Controlled Clinical Trials as Topic”[Mesh]) OR “Controlled Clinical Trial” [Publication Type]	<a href="#">1935320</a>
<a href="#">#44</a>	<a href="#">Add</a>	Search (((((((“Sinus Floor Augmentation”[Mesh]) OR ((sinus augment*[Text Word] OR sinus floor augment*[Text Word]))) OR ((sinus floor elevat*[Text Word] OR sinus elevat*[Text Word] OR sinus lift*[Text Word]))) AND (((“Bone Transplantation”[Mesh:NoExp]) OR bone transplant*[Text Word]) OR ((Autolog*[Text Word] OR autogen*[Text Word]))) OR graft*[Text Word]) OR “Bone Substitutes”[Mesh])	<a href="#">1994</a>
<a href="#">#43</a>	<a href="#">Add</a>	Search (((((((“Bone Transplantation”[Mesh:NoExp]) OR bone transplant*[Text Word]) OR ((Autolog*[Text Word] OR autogen*[Text Word]))) OR graft*[Text Word]) OR “Bone Substitutes”[Mesh])	<a href="#">501964</a>
<a href="#">#42</a>	<a href="#">Add</a>	Search “Bone Substitutes”[Mesh]	<a href="#">9402</a>
<a href="#">#29</a>	<a href="#">Add</a>	Search graft*[Text Word]	<a href="#">388892</a>
<a href="#">#26</a>	<a href="#">Add</a>	Search (Autolog*[Text Word] OR autogen*[Text Word])	<a href="#">134804</a>
<a href="#">#24</a>	<a href="#">Add</a>	Search bone transplant*[Text Word]	<a href="#">31239</a>
<a href="#">#23</a>	<a href="#">Add</a>	Search “Bone Transplantation”[Mesh:NoExp]	<a href="#">30739</a>
<a href="#">#11</a>	<a href="#">Add</a>	Search (((“Sinus Floor Augmentation”[Mesh]) OR ((sinus augment*[Text Word] OR sinus floor augment*[Text Word]))) OR ((sinus floor elevat*[Text Word] OR sinus elevat*[Text Word] OR sinus lift*[Text Word]))	<a href="#">2742</a>
<a href="#">#10</a>	<a href="#">Add</a>	Search (sinus floor elevat*[Text Word] OR sinus elevat*[Text Word] OR sinus lift*[Text Word])	<a href="#">1756</a>
<a href="#">#8</a>	<a href="#">Add</a>	Search (sinus augment*[Text Word] OR sinus floor augment*[Text Word])	<a href="#">1921</a>
<a href="#">#7</a>	<a href="#">Add</a>	Search “Sinus Floor Augmentation”[Mesh]	<a href="#">1092</a>

**Appendix 2.** Embase search until the 25<sup>th</sup> of March, 2020

No.	Query	Results
#12	#8 AND #11	811
#11	#9 OR #10	8770065
#10	(randomized OR randomised OR controlled OR prospective* OR retrospektiv*) NEAR/3 (trial OR trials OR study OR studies)	8241012
#9	‘controlled clinical trial’/exp OR ‘prospective study’/exp OR ‘retrospective study’/exp	2112073
#8	#3 AND #7	2015
#7	#4 OR #5 OR #6	576210
#6	‘bone substitut*’:ti,ab,kw,de	4876
#5	autolog*:ti,ab,kw OR autogen*:ti,ab,kw OR graft*:ti,ab,kw,de	800216
#4	‘bone transplantation’/de OR ‘bone graft’/de OR ‘bone allograft’/de OR ‘synthetic bone graft’/de	48636
#3	#1 OR #2	3097
#2	(sinus NEAR/3 (augment* OR lift* OR elevat*)):ti,ab,kw	2999
#1	‘sinus floor augmentation’/exp	1102

**Appendix 3.** Cochrane Library search until the 25<sup>th</sup> of March, 2020

<b>ID</b>	<b>Search</b>	<b>Hits</b>
#1	MeSH descriptor: [Sinus Floor Augmentation] this term only	143
#2	(sinus augment* OR sinus floor augment* OR sinus floor elevat* OR sinus elevat* OR sinus lift*):ti,ab,kw	896
#3	#1 OR #2	896
#4	MeSH descriptor: [Bone Transplantation] this term only	855
#5	MeSH descriptor: [Bone Substitutes] explode all trees	531
#6	(Autolog* OR autogen* OR graft* OR bone transplant*):ti,ab,kw	41416
#7	#4 OR #5 OR #6	41539
#8	#3 AND #7	410