

## ORIGINAL ARTICLE



WILEY

# Initial joint bleed volume in a delayed on-demand treatment setup correlates with subsequent synovial changes in hemophilic mice

Kåre Kryger Vøls<sup>1,2</sup>  | Mads Kjelgaard-Hansen<sup>3</sup> | Carsten Dan Ley<sup>1</sup> | Axel Kornerup Hansen<sup>2</sup> | Maj Petersen<sup>1</sup>

<sup>1</sup>Global Drug Discovery, Novo Nordisk A/S, Maaloev, Denmark

<sup>2</sup>Veterinary and Animal Sciences, University of Copenhagen, Frederiksberg, Denmark

<sup>3</sup>Veterinary Clinical Sciences, University of Copenhagen, Frederiksberg, Denmark

## Correspondence

Kåre Kryger Vøls, Novo Nordisk A/S, Novo Nordisk Park 1, 2760 Maaloev, Denmark.  
Email: krkv@novonordisk.com

## Funding information

LIFEHARM - University of Copenhagen

## Abstract

**Background:** Hemophilic arthropathy is a debilitating morbidity of hemophilia caused by recurrent joint bleeds. We investigated if the joint bleed volume, before initiation of treatment, was linked to the subsequent degree of histopathological changes and the development of bone pathology in a mouse model of hemophilic arthropathy.

**Methods:** FVIII knock-out (F8-KO) mice were dosed with a micro-CT blood pool agent prior to induction of hemarthrosis. Eight hours after induction, the bleed volume was quantified with micro computed tomography (micro-CT) and recombinant FVIII treatment initiated. On Day 8, inflammation in the knees was characterized by fluorescence molecular tomography. On Day 14, knee pathology was characterized by micro-CT and histopathology. In a second study, contrast agent was injected into the knee of wild-type (WT) mice, followed by histopathological evaluation on Day 14. **Results:** The average joint bleed volume before treatment was 3.9 mm<sup>3</sup>. The inflammation-related fluorescent intensities in the injured knees were significantly increased on Day 8. The injured knees had significantly increased synovitis scores, vessel counts, and areas of hemosiderin compared to un-injured knees. However, no cartilage- or bone pathology was observed. The bleed volume before initiation of treatment correlated with the degree of synovitis and was associated with high fluorescent intensity on Day 8. In F8-KO and WT mice, persistence of contrast agent in the joint elicited morphological changes.

**Conclusion:** When applying a delayed on-demand treatment regimen to hemophilic mice subjected to an induced knee hemarthrosis, the degree of histopathological changes on Day 14 reflected the bleed volume prior to initiation of treatment.

## KEYWORDS

Animal models, arthropathy, hemarthrosis, haemophilia A, in vivo imaging, micro-CT

This is an open access article under the terms of the Creative Commons Attribution-NonCommercial License, which permits use, distribution and reproduction in any medium, provided the original work is properly cited and is not used for commercial purposes.

© 2020 The Authors. *Animal Models and Experimental Medicine* published by John Wiley & Sons Australia, Ltd on behalf of The Chinese Association for Laboratory Animal Sciences

## 1 | INTRODUCTION

Spontaneous joint bleeds which in time lead to debilitating arthropathy are a major cause of morbidity in patients with Hemophilia A.<sup>1</sup> Since the introduction of prophylactic FVIII replacement therapy, in parts of the world, the annualized bleeding rate in patients with severe hemophilia A has been reduced from 20 to 30 bleeding episodes per year to only a few.<sup>2,3</sup> Yet, despite prophylactic treatment patients are still not protected from development of arthropathy,<sup>4</sup> suggesting that treatment should effectively eliminate joint bleeds to completely prevent arthropathy.<sup>5</sup>

It has been proposed that if the amount of blood accumulating in the joint following a single joint bleed exceeds a certain threshold, it may result in chronic changes.<sup>6</sup> Further, the damaging effect of blood on cartilage has been shown to be dependent on the concentration of blood *in vitro*.<sup>7</sup> However, even though several clinical studies have investigated the relation between the number of clinically evident joint bleeds and the degree of arthropathy, none of these studies quantified or described the individual bleeds in higher detail.<sup>8–11</sup> Thus, it remains unknown if the severity of the individual joint bleeds is linked to the subsequent development of arthropathy.

To address this question, the hemophilic mouse model—in which hemophilic arthropathy develops after induced hemarthrosis<sup>12,13</sup>—can be used. Within hours after induced hemarthrosis, the entire joint may be filled with blood.<sup>14</sup> Macrophages and neutrophils have invaded the joint and inflammatory cytokines and proteases (eg interleukin 1-beta (IL-1 $\beta$ ), IL-6, tumor necrosis factor alpha (TNF- $\alpha$ ) and matrix metalloproteinases) are expressed.<sup>15,16</sup> These initiate pathways that are known to lead to synovitis, cartilage damage and bone pathology.<sup>17–19</sup> In addition, we recently showed that the early joint bleed volume (12 hours after induction as described by micro computed tomography (micro-CT)) was linked to the subsequent degree of histopathological changes and development of bone pathology in untreated FVIII knock-out (F8-KO) mice.<sup>14</sup>

In this study, we assess if the joint bleed volume before initiation of intensive replacement therapy with recombinant FVIII, influenced the subsequent joint outcome. We hypothesized that the bleed volume before treatment would correlate with the subsequent degree of histopathological changes and development of bone pathology.

## 2 | METHODS

### 2.1 | Animals

Animal studies were conducted according to the EU Directive 2010/63/EU and the Danish Animal Experimentation Act and approved by the Danish Animal Experiments Council, the Danish Ministry of Environment and Food as well as the Novo Nordisk Animal Welfare Body. All animal procedures were conducted under inhalation anesthesia (induction: 5% isoflurane (Isoflurane, Merck & Co), 0.7 L/min N<sub>2</sub>O, 0.3 L/min O<sub>2</sub>, maintenance: 2% isoflurane, 0.7 L/min N<sub>2</sub>O, 0.3 L/min O<sub>2</sub>).

Sixteen weeks old hemophilia A (B6;129S4-F8<sup>tm1Kaz</sup>; Taconic; n = 22, referred to as “F8-KO”) mice<sup>20</sup> were included in the study and group housed in environmentally enriched cages at 12/12 h light-dark cycle, ad libitum water and ad libitum rodent chow (1324 maintenance diet; Altromin GmbH).

The day before entering the study, the lower body of the mice were depilated to allow for optical imaging of the knee joints, by shaving the area and applying a depilatory cream (Veet® Green; Reckitt Benckiser Group) for 1 minute before a wash with lukewarm water. Extra nesting material was provided throughout the study.

Analgesia (buprenorphine, Temgesic®; Indivior UK Limited) was provided as repeated subcutaneous doses on the first day (0.1 mg/kg at 5 minutes before, and 4 and 8 hours after induced joint bleed) and through the drinking water (0.3 mg/50 mL) from 8 hours onward. Mice were excluded from the study if they met predefined humane endpoints (n = 0) or if any intravenous treatment was unsuccessful (n = 2).

On Day 14 after induced joint bleed, the mice were euthanized by cervical dislocation while in general anesthesia (5% isoflurane, 0.7 L/min N<sub>2</sub>O, 0.3 L/min O<sub>2</sub>).

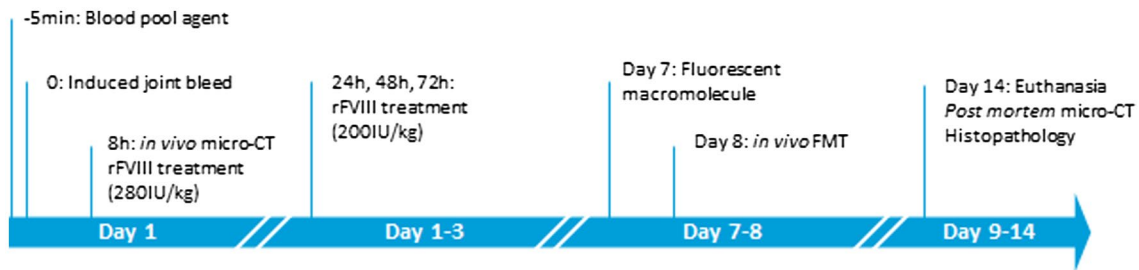
In a satellite group, 5 wild-type (WT mice; C57BL/6N; Taconic) of both genders, aged 14 weeks, were included. Analgesia was provided before intra-articular injection and through the water as described above.

### 2.2 | Study design

Study design is depicted in Figure 1. Briefly, hemophilic mice were dosed with a micro-CT blood pool agent (Exitron nano 12 000; Miltenyi Biotec; 55  $\mu$ L/25 g bodyweight) through a catheter in the lateral tail vein. This blood pool agent is specifically designed for visualizing vasculature in rodents (blood half-life 4 hours), and is eventually removed from the circulation by cells of the reticuloendothelial system.<sup>21</sup>

Five minutes after dosing of the blood pool agent, a joint bleed in the left knee was induced by advancing a 30-gauge needle approximately 2 mm into the knee joint through the patellar ligament, as described.<sup>22</sup>

Eight hours after induction of the joint bleed, the mice were anesthetized and intravenously (iv) dosed with rFVIII (ADVATE®; 280 IU/kg) through a tail vein catheter, followed by *in vivo* micro-CT of the injured knee (acquisition time 3 minutes, 90 kV, 160  $\mu$ A, field of view 10 mm) using the Quantum FX (Perkin Elmer) to quantify the joint bleed volume, as described.<sup>14</sup> The 8 hours time point was chosen as it represents the latest time point where accurate quantification of the joint bleed volume is possible when taking into consideration the half-life of the blood pool agent in circulation. Treatment with rFVIII was continued by additional doses (200 IU/kg) at 24, 48, and 72 hours after induction. Based on the duration of effect and half-life in circulation of this FVIII molecule, this treatment should effectively stop bleeding and prevent re-bleeding throughout the treatment period.<sup>23,24</sup>



**FIGURE 1** Study design. Hemophilic mice ( $n = 22$ ) were dosed with a micro-CT blood pool agent 5 min prior to induction of joint bleed in the left knee. 8 h after induction, the mice were dosed with recombinant FVIII (rFVIII; 280 IU/kg) and the injured knee micro-CT imaged. At 24, 48, and 72 h after induction of joint bleeds, the mice received rFVIII treatment (200 IU/kg). On Day 7, a fluorescent macromolecule was dosed and on Day 8 the lower body of the mice was imaged with fluorescence molecular tomography (FMT). On Day 14, the mice were euthanized and the knee joints micro-CT imaged and processed for histopathology

On Day 7, the mice were dosed intravenously with a near-infrared fluorescent macromolecule (AngioSense750; Perkin Elmer; 100  $\mu\text{L}/25\text{ g}$ ) which has previously been used to characterise induced joint bleeds in the mouse model of hemophilic arthropathy.<sup>25</sup> Twenty-four hours after dosing, the mice were anesthetized and placed in prone position in the FMT1500 (Perkin Elmer) for imaging of the lower body by transillumination (745 nm channel; 5 minutes acquisition time) in order to quantify inflammation-mediated blood volume changes in the knee joint regions at this time point by fluorescence molecular tomography (FMT).

After euthanasia on Day 14, joint pathology was evaluated by micro-CT and histology.

In the satellite group, 55  $\mu\text{L}$  of the micro-CT blood pool agent was diluted in 2 mL phosphate buffered saline to mimic the maximum concentration of contrast agent in blood in the main study. The diluted contrast agent was then injected intra-articularly (approximately 5–6  $\mu\text{L}$ ) into the left knee of anesthetized WT mice. The injected knee was micro-CT imaged 3 minutes post injection to confirm successful intra-articular injection. Fourteen days after the intra-articular injection, the mice were euthanized and the knee joints assessed by histopathology.

### 2.3 | Analysis of in vivo micro-CT to quantify joint bleed volumes

In order to quantify joint bleed volumes, the in vivo micro-CT scans were divided into 2 objects (bone and contrast agent) by semi-automatic threshold-based image segmentation in image analysis software (Analyze 12.0; AnalyzeDirect). Then, the volume of the contrast agent was determined by automatic image sampling and used as surrogate for the bleed volume, as described.<sup>14</sup>

### 2.4 | Analysis of in vivo FMT to quantify blood volume changes in the knee regions

In order to quantify blood volume changes in the knee joint regions 8 days after induction of hemarthrosis, volumes of interest (VOI) of

approximately 2500  $\text{mm}^3$  were centred around the knee joints using TrueQuant 4.0 imaging software (Perkin Elmer). The fluorescent intensities in the VOI were calculated automatically and used as surrogate for the blood volume in the region. Three mice were excluded from the analysis due to melanin-pigments (that attenuate the signal) overlying the analyzed regions.

### 2.5 | Assessment of bone pathology with post mortem micro-CT

In order to semi-quantitatively assess development of bone pathology, *post mortem* micro-CT scans were evaluated for presence/absence of osteophytosis (femur, patella, tibia) and periosteal bone formation (femur, tibia), using Quantum FX 2.2 software (Perkin Elmer). A score of 5 indicated that all pathological changes were present, and a score of 0 indicated that no pathological changes were present, as described.<sup>26</sup>

### 2.6 | Histological assessment of blood-induced joint damage

*Post mortem*, knee joints were fixed in neutral buffered formalin for 48 hours before decalcification for 14 days in 12.5% EDTA at pH 7.4 to avoid loss of iron from the tissues, which can occur if acidic decalcification is applied.<sup>27</sup> Coronal sections (3  $\mu\text{m}$ ) were stained with hematoxylin and eosin to grade hemophilic synovitis.<sup>28</sup> Briefly, a score for synovial hyperplasia (0–3) and vascularity (0–3) as well as the presence of hemosiderin, blood, villi, and cartilage erosion (0–1 for each) was pooled to a composite score from 0–10.

The number of chondrocytes was evaluated by averaging the total number of chondrocytes (counted manually) in 4 high-power fields (400 $\times$ ); 2 on the tibial cartilage and 2 on the femoral cartilage.

In addition, an anti-alpha smooth muscle actin ( $\alpha\text{-sma}$ ) antibody stain (ab5694; Abcam) was used to manually count the number of  $\alpha\text{-sma}$  positive vessels in the synovial- and subsynovial tissue along the femur, from the attachment sites of the collateral ligaments to the trochlear groove both laterally and medially.

Perls' Prussian Blue stain was used to quantify the hemosiderin-stained area in the joint (outside the bone marrow) using automatic image analysis (VIS 2019.02.1.6005; Visiopharm). One mouse was excluded from this analysis (folded synovium on the slide).

One mouse was excluded from all the comparative analyses between the injured and contralateral knee due to spontaneous hemophilic arthropathy in the contralateral knee (which has been described to occur occasionally in this mouse model<sup>29</sup>).

## 2.7 | Statistics

To compare measurements between contralateral and injured knees, paired *t* test (for Gaussian-distributed samples with equal variances) or Wilcoxon's matched-pairs signed rank test (for non-Gaussian distributed samples and/or unequal variances) was used. For comparison of non-paired samples, one-tailed *t* test or Mann-Whitney was used based on the same principles. Correlation analysis was performed with one-tailed Pearson's correlation. All analyses were performed with the observer blinded to the animal ID.

Statistical analyses were performed in GraphPad Prism (version 8.02; GraphPad Software Inc).

## 3 | RESULTS

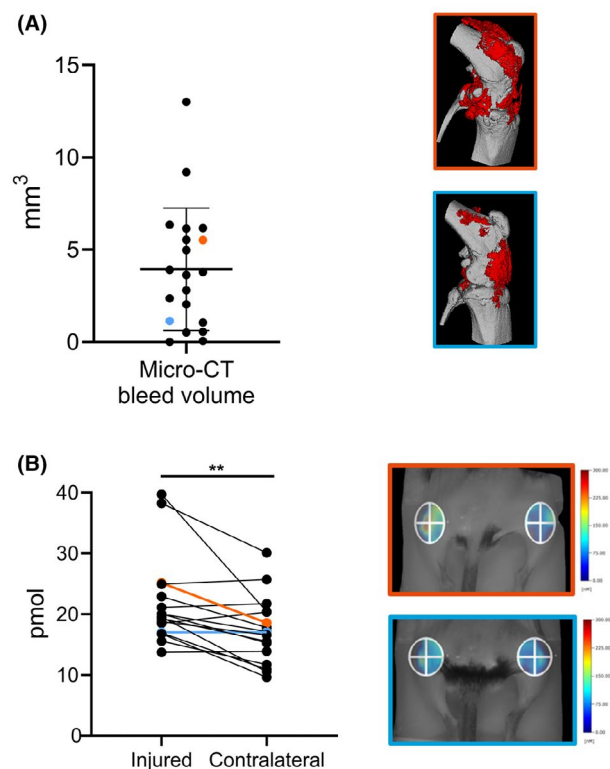
### 3.1 | In vivo characterisation of bleeding

Eight hours after induced hemarthrosis, the bleed volume in the knee joint region was quantified with contrast-enhanced micro-CT using a blood-pool agent as surrogate for blood. When segmenting the bone and contrast-derived voxel intensities in the micro-CT volumes we found that the average bleed volume (ie contrast volume) in the injured knees was 3.9 mm<sup>3</sup>. As observed on the 3D representations of the segmentations, the entire joint was filled with blood in 8 of the 20 mice (based on visual inspection of segmented 3D volumes; Figure 2A).

Eight days after induction, iv injection of a fluorescent macro-molecule was used to characterize the inflammation-mediated blood volume changes in the knee joint regions with live optical imaging. The fluorescent intensity was significantly increased in the injured knee compared to the contralateral ( $P = .002$ ; Figure 2B); thus, indicative of increased inflammation-mediated blood and/or bleed volume in the region.

### 3.2 | Mild to moderate synovial pathology observed after 14 days

On Day 14, knee pathology was evaluated by histopathology and micro-CT. On histopathology, hemophilic synovitis was graded on a semiquantitative score<sup>28</sup>. The injured knees had a significantly increased synovitis score compared to the contralateral knees (mean

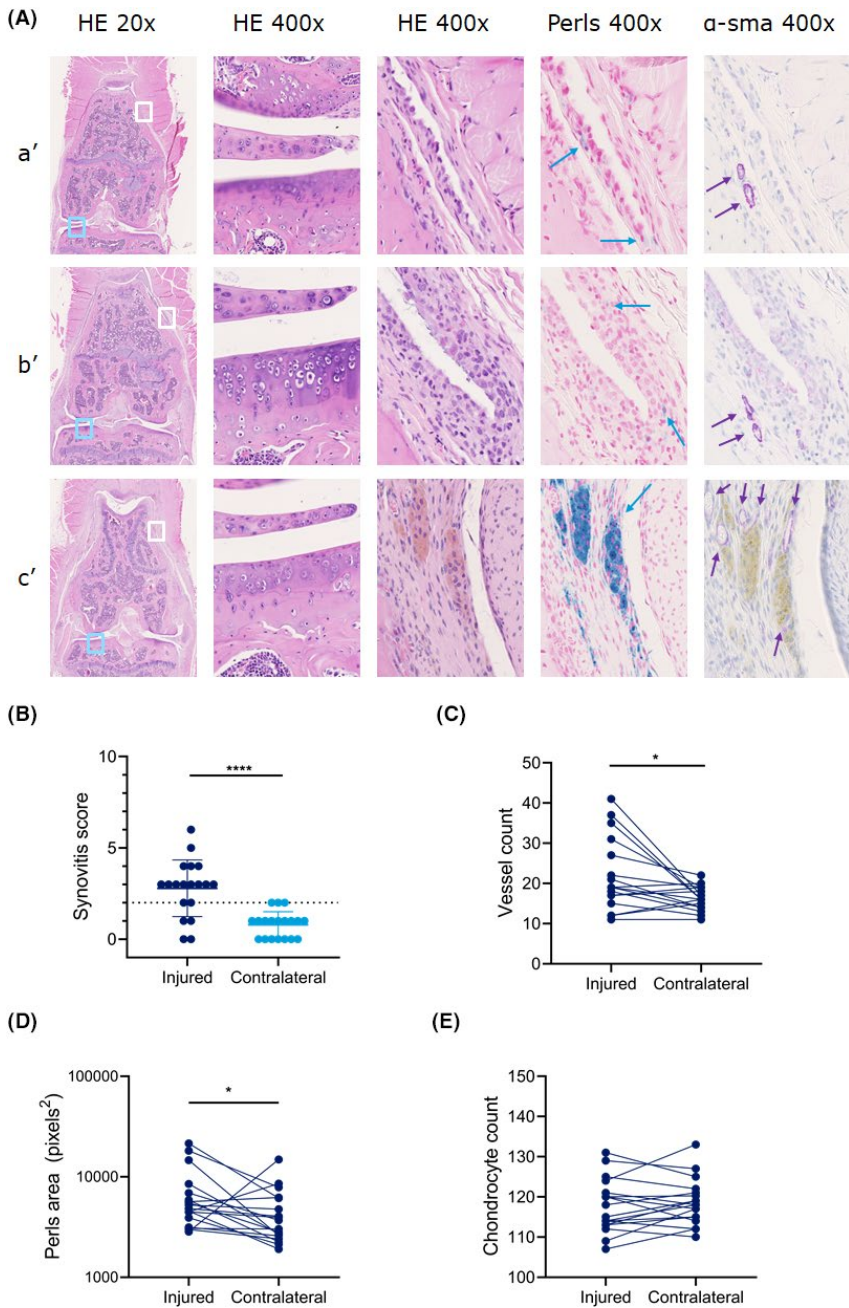


**FIGURE 2** In vivo characterization of induced joint bleeds in hemophilic mice. A, Bleed volume as determined by in vivo contrast-enhanced micro-CT just after initiation of treatment 8 h after induction. Error bars represent mean  $\pm$  SD. The 3D volumes represent segmented in vivo micro-CT scans (blood: red, bone: gray) of the 2 mice marked with the blue and orange bullets in the graph, respectively. B, Fluorescent signal intensity in the injured compared with the contralateral knee as determined by in vivo FMT 8 d after induction of joint bleed. The FMT images framed in blue and red represent the blue and red bullets in the graphs, respectively. Volumes of interest are shown around the knee joints. Color-bar indicates intensity of fluorescent signal

score 2.7 vs 0.8,  $P < .0001$ ; Figure 3A,B). A specific score of the individual parameters of the hemophilic synovitis score can be found in Figure S1. Notably, acute intra-articular bleeding at the time of euthanasia was observed in 2 mice. Further, the number of  $\alpha$ -sma positive vessels was significantly increased in the injured knees (mean vessel counts 22 vs 17,  $P = .013$ ; Figure 3A,C), along with the hemosiderin-stained area which was increased in the injured knees (mean area 7020 vs 4586 pixels<sup>2</sup>,  $P = .03$ ; Figure 3D) compared to the contralateral. As cartilage erosion was not present in any of the mice (as graded in the Valentino score), potential cartilage damage was evaluated by counting chondrocytes: Here, no difference in chondrocyte numbers were found between the injured and contralateral knee ( $P = .47$ ; Figure 3E).

On micro-CT, no bone pathology was observed in the injured knees, whereas 1 contralateral knee had a positive score of 4, most likely due to spontaneously-occurring arthropathy that had developed before study start (Figure 4). In addition, remnants of contrast agent in the injured joints were observed, as described.<sup>14</sup>





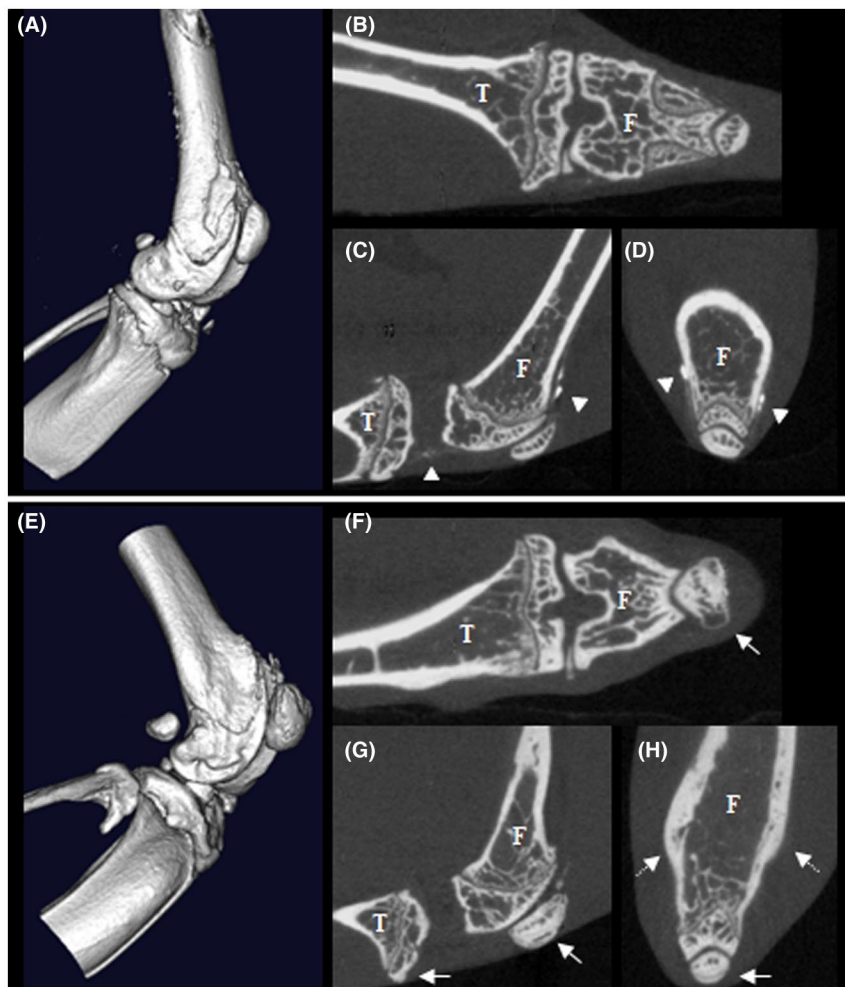
**FIGURE 3** Histopathological evaluation of knees 14 days after induced joint bleed. A, Representative histological images of injured knees (a', b') and 1 contralateral knee displaying spontaneous hemophilic arthropathy (c'). First column: Hematoxylin eosin (HE) stain at 20 × magnification. Blue rectangle shows the area magnified in the second column, whereas the white rectangle shows the area magnified in columns 3-5, all at 400 × magnification. Second column: HE of tibial cartilage, showing no loss of chondrocytes or cartilage erosion. Third column: HE of the synovium, with hyperplasia present in b' and c'. Fourth column: Perl's Prussian blue stain; arrows indicate hemosiderin deposition. Fifth column: α-sma stain, arrows mark blood vessels. B, Synovitis score in injured and contralateral knees (mean ± SD). C, Vessel count in the synovium along the femur in injured and contralateral knees. D, Area of hemosiderin (Perls area) in injured and contralateral knees. E, Chondrocyte in injured and contralateral knees. Significance levels are marked as follows: \* $P < .05$ , \*\*\*\* $P < .0001$

### 3.3 | Correlation between bleed volume before treatment and subsequent development of pathology

Next, we evaluated whether the pathological changes on Day 14 could be related to the observed bleed volume before initiation of treatment 8 hours post-induction of knee injury. We found that mice with a large ( $\geq 25\%$ ,  $n = 9$ ) fluorescent signal in the injured knee relative to the contralateral, indicating increased inflammation-mediated blood volume in the injured knee, had significantly increased initial bleed volumes as measured with micro-CT compared to mice with a small ( $< 25\%$ ,  $n = 8$ ) fluorescent signal in the injured knee ( $P = .036$ ) (Figure 5A). The cut-off value of 25% increase in fluorescent signal was chosen based on previous studies evaluating the noise with this modality.

Also, we found a statistically significant correlation between the hemophilic synovitis score and the 8 hours bleed volume ( $r^2 = .20$ ,  $P = .024$ ; Figure 5B), and further the mice that had a Valentino score of  $\geq 3$  (more than the "maximum baseline score" observed in uninjured control knees) had a higher 8 hours bleed volume than the mice that had a synovitis score of  $\leq 2$  ( $P = .002$ ; Figure 5C). No difference was found in the 8 hours bleed volume between mice with a highly increased ( $\geq 25\%$ ) vs less increased ( $< 25\%$ ) vessel count in the injured knee compared to the mean vessel count of the contralateral knees ( $P = .44$ ; Figure 5D). Finally, the hemosiderin area at Day 14 did not correlate with the 8 hours bleed volume before treatment was initiated, although a trend was observed ( $r^2 = .10$ ,  $P = .09$ ; Figure 5E).

**FIGURE 4** Post mortem evaluation of bone pathology by micro-CT 14 d after induced joint bleeds. A, 3D volume of an injured knee with no signs of bone pathology. B-D, Coronal, sagittal and transverse plane of the same knee. No pathological bone changes are present. Minor remnants of contrast agent are marked by arrowheads. E, 3D volume of a contralateral knee with spontaneous hemophilic arthropathy. F-H, Coronal, sagittal and transverse plane of the same knee, showing osteophytosis on tibia and patella (arrows, F, G, H) and periosteal bone formation on femur (dashed arrows, H). F, femur, T, tibia



### 3.4 | Remnants of contrast agent in the joint induces morphological changes

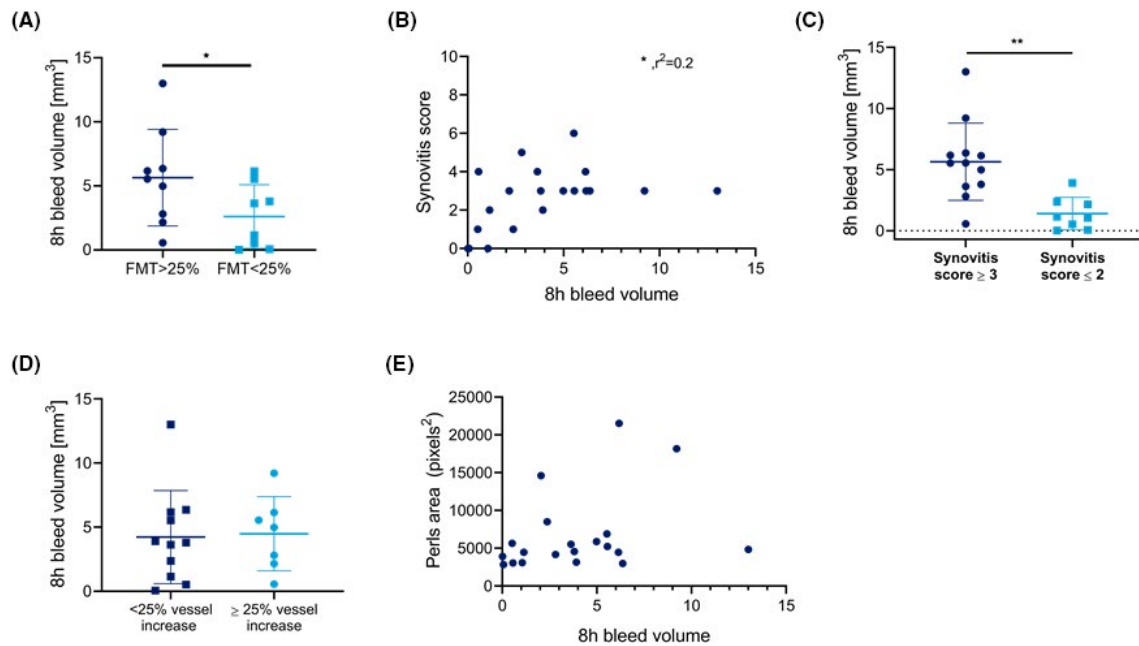
Besides the pathological changes in knee-injured hemophilic mice, we observed morphological changes in clusters of mononuclear cells in the synovial- and/or subsynovial tissue. The cells were normo- to hypertrophic and with a granular cytoplasm, most likely due to phagocytosis of contrast agent<sup>30</sup> (Figure S2). To test whether this has an effect on the measured outcomes, 5 WT mice were injected intra-articularly with contrast agent in a concentration corresponding to the maximum concentration in blood. In the WT mice, we saw the same granular cytoplasm and hypertrophy in some of the synovial cells, but pathological changes on the synovitis score was no different to what was observed in the contralateral knee joints of the main study (mean score of 0.4).

## 4 | DISCUSSION

In this study, we tested whether the volume of blood in the knee joint 8 hours after an induced knee bleed, and prior to initiation of on-demand recombinant FVIII replacement therapy, was linked to the subsequent degree of histopathological changes and development

of bone pathology in a hemophilia A mouse model of arthropathy. Delayed on-demand treatment was initiated 8 hours after induction; a time point at which the inflammatory response is initiated,<sup>15,16</sup> and at which we observed that the entire joint was filled with blood in 40% of mice. Still, the applied FVIII therapy effectively prevented bleeding-induced bone pathology, cartilage erosion and loss of chondrocytes, whereas mild to moderate synovial changes as well as increased vessel counts and increased areas of hemosiderin deposits were present on Day 14. In addition, the concentration of a fluorescent macromolecule was significantly increased in the injured knees 8 days after induction, as measured by in vivo FMT, suggesting that the injured knees were inflamed at this time point.

Importantly, we found that the bleed volume before initiation of treatment was linked to the subsequent degree of synovial changes in the joint 14 days later. Thus, larger bleeds were associated with more pronounced synovial changes. These synovial changes (hyperplasia and increased vascularization) could predispose the synovium to repeated bleedings.<sup>31,32</sup> In turn, repeated bleedings could exacerbate the synovial changes and potentially lead to a vicious cycle in which the joint could become a target joint.<sup>33</sup> Indeed, we did observe active intra-articular bleeding at the time of euthanasia on Day 14 in 2 of the injured knees.



**FIGURE 5** Relations between in vivo bleed volume before initiation of treatment and subsequent pathological outcomes. A, In mice with a highly increased fluorescent intensity (>25% compared with the contralateral) in the injured knee on Day 8 after induced joint bleed, increased bleed volumes were observed 8 h after induction. B, The 8 h bleed volume correlated significantly with the histological synovitis score. C, Mice in which the synovitis score of the injured knee was higher than the max score of uninjured contralateral knees had significantly increased bleed volumes 8 h after induction. D, No difference was found between mice with a large and small increase in the number of vessels in the synovium along the femur. E, There was no significant correlation between the 8 h bleed volume and the area of hemosiderin deposition. Significance levels are marked: \* $P < .05$ , \*\* $P < .01$ . Bars indicate mean  $\pm$  SD

Interestingly, WT mice do not develop noteworthy synovial changes after injection of blood (5  $\mu$ L) into the joint.<sup>34</sup> As we restored the hemostatic potential of the hemophilic mice in this study for 4 days by initiating an intensive FVIII replacement treatment regimen, the observed pathology—which is not seen in WT mice injected with blood into the joint—may reflect 2 things. First, delayed on-demand treatment was initiated in the hemophilic mice after active intra-articular bleeding for 8 hours. In contrast, WT mice start to clear the injected blood immediately, leading to complete resolution of the bleeding within a day.<sup>34</sup> Second, the applied treatment in this study lasted for roughly 4 days. As coagulation plays an important role in wound healing,<sup>35</sup> it is possible that a 4 day treatment effect is not sufficient to allow for normal healing. However, this delayed on-demand treatment regimen was chosen as studies have demonstrated the superiority of early and aggressive FVIII replacement treatment as compared to moderate but prolonged treatment.<sup>36</sup>

From a clinical perspective, our findings support that in case of an acute joint bleed on-demand treatment should be initiated as soon as possible in order to halt the active bleeding and thereby minimize the amount of blood entering the joint, prevent re-bleeding, and aid in wound healing.<sup>35,37</sup> It does, however, also raise the hypothetical question of whether aspiration of blood from large active joint bleeds under pro-coagulant conditions would be beneficial to quickly reduce the blood-load in the joint, as larger bleeds were associated with a higher degree of synovitis. Currently, there is no

treatment available that directly targets the effect of blood already in the joint,<sup>17</sup> and only a few clinical studies have investigated the effect of joint aspiration after joint bleeding in hemophilia patients. These studies demonstrate a faster recovery after aspiration, however the long-term effect on joint health is not known.<sup>38–41</sup> It is, however, not possible to investigate the effect of joint aspiration in the mouse model due to the small size of the joint, which makes it unfeasible to perform aspiration without doing concomitant damage to the joint. In addition, our data could indicate that in the clinic, large joint bleeds warrant a more thorough follow-up period, as transient synovial changes which make the joint more susceptible to repeated bleeding may be present until homeostasis is re-established in the joint.

We also observed moderately increased fluorescent intensities in the injured knees 8 days after joint bleed induction when using a blood specific fluorescent macromolecule, suggesting an increased blood volume in the knee joint area at the time of imaging.<sup>42</sup> However, due to the resolution of FMT we cannot decipher whether the fluorescent signal originated from hyperaemia or increased vascularization in the area, or from diffusion of the fluorescent macromolecule into the knee joint region due to increased vascular permeability, or from actual bleeding into the knee joint at this time point. Still, in future studies the use of fluorescent probes activated by specific enzymes could make FMT a powerful tool to longitudinally investigate ongoing inflammation following induced hemarthrosis in the mouse model.<sup>43</sup>

On histology, the hemosiderin depositions in the injured knees were in general quite discrete, even in the mice in which the entire joint had been filled with blood before initiation of treatment (based on visual inspection of the in vivo micro-CT scans). In fact, the largest area of hemosiderin deposition in an injured knee in this study only corresponded to 7% of the area found in the mouse with spontaneous hemophilic arthropathy which was excluded from the analysis. Similar to our findings, Jansen et al reported that following injection of a large amount of blood into the knee joint in a wild-type canine model, only very limited hemosiderin deposition was observed.<sup>44</sup> Whereas those findings may be attributed to the time of evaluation and the rapid clearance of blood from the joint in wild-type animals,<sup>34</sup> our results suggest that even though treatment was not initiated before 8 hours after induction, the subsequent clearance of blood from the joint in the treated hemophilic mice had been very effective. This was further supported by the fact that we did not observe a correlation between the area of hemosiderin deposition and the 8 hours bleed volume, suggesting that even the largest bleeds had been effectively cleared. It does not, however, necessarily mean that hemosiderin depositions had not been present to a larger extent at earlier timepoints. Following induced hemarthrosis in untreated hemophilic mice, hemosiderin deposition decreases beyond 4 weeks after induced hemarthrosis,<sup>34</sup> and it is possible that this decrease is seen earlier in treated mice.

One important limitation in this study was that we observed clusters of mononuclear cells in the synovial/subsynovial tissue with a granular cytoplasm, with some of the cells being hypertrophic. The altered morphology of these cells is most likely due to the uptake of the micro-CT contrast agent which after being phagocytosed stays in the cells for prolonged time, providing the basis for longitudinal imaging of liver and spleen with this agent.<sup>45</sup> This phenomenon has also been observed in the liver, but here it was not associated with an inflammatory response.<sup>30</sup> To address this further, we injected contrast agent into the knee joints of WT mice. Here, we observed the same morphological changes, indicating that these were indeed caused by the contrast agent. Although the hemophilic synovitis score was no different from what we observed in the contralateral knees in the main study, it cannot be ruled out entirely that the contrast agent may interfere with the observed pathology, and therefore an easily cleared agent with strong contrast and long circulation time would be preferable in future studies. This is, however, not currently commercially available to our knowledge.

In conclusion, in this study we showed that the bleed volume before initiation of on-demand FVIII therapy was correlated to the subsequent degree of synovial changes in a hemophilia A mouse model of arthropathy. These synovial changes may predispose the joint for repeated bleeding until homeostasis has been re-established, supporting that on-demand treatment should be initiated as soon as possible in order to keep the joint bleed volume to a minimum.

## ACKNOWLEDGMENTS

We acknowledge J. Juul and MN Nielsen for help with the histological staining.

## CONFLICT OF INTEREST

CD Ley, M Petersen, and KK Vøls are employees and shareholders of Novo Nordisk A/S. KK Vøls reports grants from the University of Copenhagen and Novo Nordisk A/S during the course of the study. AK Hansen has received funding from Novo Nordisk A/S. M Kjelgaard-Hansen has nothing to disclose.

## AUTHOR CONTRIBUTIONS

All authors contributed to the design of the study. KK Vøls performed the experimental part of the study. KK Vøls and CD Ley conducted the statistical analysis. All authors contributed to the data analysis. KK Vøls prepared the manuscript. All authors revised the manuscript and approved the final version.

## ORCID

Kåre Kryger Vøls  <https://orcid.org/0000-0002-6701-2087>

## REFERENCES

- Ahlberg A. Haemophilia in Sweden. VII. Incidence, treatment and prophylaxis of arthropathy and other musculo-skeletal manifestations of haemophilia A and B. *Acta Orthop Scand Suppl.* 1965;36:73-132.
- Mannucci PM, Tuddenham EG. The hemophilias—from royal genes to gene therapy. *N Engl J Med.* 2001;344(23):1773-1779.
- Fischer K, Steen Carlsson K, Petrini P, et al. Intermediate-dose versus high-dose prophylaxis for severe hemophilia: comparing outcome and costs since the 1970s. *Blood.* 2013;122(7):1129-1136.
- Oldenburg J. Optimal treatment strategies for hemophilia: achievements and limitations of current prophylactic regimens. *Blood.* 2015;125(13):2038-2044.
- Gringeri A, Ewenstein B, Reininger A. The burden of bleeding in haemophilia: is one bleed too many? *Haemophilia.* 2014;20(4):459-463.
- van Vulpen LFD, Mastbergen SC, Lafeber FPJG, Schutgens REG. Differential effects of bleeds on the development of arthropathy—basic and applied issues. *Haemophilia.* 2017;23(4):521-527.
- Jansen NW, Roosendaal G, Bijlsma JW, Degroot J, Lafeber FP. Exposure of human cartilage tissue to low concentrations of blood for a short period of time leads to prolonged cartilage damage: an in vitro study. *Arthritis Rheum.* 2007;56(1):199-207.
- Manco-Johnson MJ, Abshire TC, Shapiro AD, et al. Prophylaxis versus episodic treatment to prevent joint disease in boys with severe hemophilia. *N Engl J Med.* 2007;357(6):535-544.
- Fischer K, van Hout BA, van der Bom JG, Grobbee DE, van den Berg HM. Association between joint bleeds and Pettersson scores in severe haemophilia. *Acta Radiol.* 2002;43(5):528-532.
- Aledort LM, Haschmeyer RH, Pettersson H. A longitudinal study of orthopaedic outcomes for severe factor-VIII-deficient haemophiliacs. The Orthopaedic Outcome Study Group. *J Intern Med.* 1994;236(4):391-399.
- Den Uijl IE, De Schepper AM, Camerlinck M, Grobbee DE, Fischer K. Magnetic resonance imaging in teenagers and young adults with limited haemophilic arthropathy: baseline results from a prospective study. *Haemophilia.* 2011;17(6):926-930.
- Sabatino DE, Nichols TC, Merricks E, Bellingier DA, Herzog RW, Monahan PE. Animal models of hemophilia. *Prog Mol Biol Transl Sci.* 2012;105:151-209.



13. Hakobyan N, Kazarian T, Valentino LA. Synovitis in a murine model of human factor VIII deficiency. *Haemophilia*. 2005;11(3):227-232.
14. Vøls KK, Kjelgaard-Hansen M, Ley CD, Hansen AK, Petersen M. Bleed volume of experimental knee haemarthrosis correlates with the subsequent degree of haemophilic arthropathy. *Haemophilia*. 2019;25(2):324-333.
15. Christensen KR, Kjelgaard-Hansen M, Nielsen LN, et al. Rapid inflammation and early degeneration of bone and cartilage revealed in a time-course study of induced haemarthrosis in haemophilic rats. *Rheumatology (Oxford)*. 2019;58(4):588-599.
16. Sen D, Chapla A, Walter N, Daniel V, Srivastava A, Jayandharan GR. Nuclear factor (NF)- $\kappa$ B and its associated pathways are major molecular regulators of blood-induced joint damage in a murine model of hemophilia. *J Thromb Haemost*. 2013;11(2):293-306.
17. Srivastava A. Inflammation is key to hemophilic arthropathy. *Blood*. 2015;126(19):2175-2176.
18. van Vulpén LFD, Schutgens REG, Coeleveld K, et al. IL-1 $\beta$ , in contrast to TNF $\alpha$ , is pivotal in blood-induced cartilage damage and is a potential target for therapy. *Blood*. 2015;126(19):2239-2246.
19. Haxaire C, Hakobyan N, Pannellini T, et al. Blood-induced bone loss in murine hemophilic arthropathy is prevented by blocking the iRhom2/ADAM17/TNF- $\alpha$  pathway. *Blood*. 2018;132(10):1064-1074.
20. Bi L, Lawler AM, Antonarakis SE, High KA, Gearhart JD, Kazanian HH. Targeted disruption of the mouse factor VIII gene produces a model of haemophilia A. *Nat Genet*. 1995;10(1):119-121.
21. Boll H, Nittka S, Doyon F, et al. Micro-CT based experimental liver imaging using a nanoparticulate contrast agent: a longitudinal study in mice. *PLoS ONE*. 2011;6(9):e25692.
22. Hakobyan N, Enockson C, Cole AA, Sumner DR, Valentino LA. Experimental haemophilic arthropathy in a mouse model of a massive haemarthrosis: gross, radiological and histological changes. *Haemophilia*. 2008;14(4):804-809.
23. Elm T, Karpf DM, Øvlisen K, et al. Pharmacokinetics and pharmacodynamics of a new recombinant FVIII (N8) in haemophilia A mice. *Haemophilia*. 2012;18(1):139-145.
24. Valentino LA, Cong L, Enockson C, et al. The biological efficacy profile of BAX 855, a PEGylated recombinant factor VIII molecule. *Haemophilia*. 2015;21(1):58-63.
25. Vøls KK, Kjelgaard-Hansen M, Ley CD, Hansen AK, Petersen M. In vivo fluorescence molecular tomography of induced haemarthrosis in haemophilic mice: link between bleeding characteristics and development of bone pathology. *BMC Musculoskelet Disord*. 2020;21(1):241.
26. Christensen KR, Roepstorff K, Petersen M, et al. Visualization of haemophilic arthropathy in F8(-/-) rats by ultrasonography and micro-computed tomography. *Haemophilia*. 2016;23(1):152-162.
27. Ghadially FN, Oryschak AF, Ailsby RL, Mehta PN. Electron probe x-ray analysis of siderosomes in haemarthrotic articular cartilage. *Virchows Arch B Cell Pathol*. 1974;16(1):43-49.
28. Valentino LA, Hakobyan N. Histological changes in murine haemophilic synovitis: a quantitative grading system to assess blood-induced synovitis. *Haemophilia*. 2006;12(6):654-662.
29. Staber JM, Pollpeter MJ. Shortened lifespan and lethal hemorrhage in a hemophilia A mouse model. *PLoS ONE*. 2016;11(5):e0154857.
30. Liu CN, Morin J, Dokmanovich M, et al. Nanoparticle contrast-enhanced micro-CT: a preclinical tool for the 3D imaging of liver and spleen in longitudinal mouse studies. *J Pharmacol Toxicol Methods*. 2019;96:67-77.
31. Ceponis A, Wong-Sefidan I, Glass CS, von Drygalski A. Rapid musculoskeletal ultrasound for painful episodes in adult haemophilia patients. *Haemophilia*. 2013;19(5):790-798.
32. Bhat V, Olmer M, Joshi S, et al. Vascular remodeling underlies rebleeding in hemophilic arthropathy. *Am J Hematol*. 2015;90(11):1027-1035.
33. Mulder K, Llinás A. The target joint. *Haemophilia*. 2004;10(Suppl 4):152-156.
34. Sun J, Hua B, Livingston EW, et al. Abnormal joint and bone wound healing in hemophilia mice is improved by extending factor IX activity after hemarthrosis. *Blood*. 2017;129(15):2161-2171.
35. Monroe DM, Hoffman M. The clotting system—a major player in wound healing. *Haemophilia*. 2012;18(Suppl 5):11-16.
36. He P, Zhang F, Zhong C, et al. Timely and large dose of clotting factor IX provides better joint wound healing after hemarthrosis in hemophilia B mice. *Int J Hematol*. 2019;110(1):59-68.
37. Srivastava A, Brewer AK, Mauser-Bunschoten EP, et al. Guidelines for the management of hemophilia. *Haemophilia*. 2013;19(1):e1-e47.
38. Banta JV, Boone DC, Smith CF. Arthrocentesis of the knee in acute hemophilic arthropathy. *West J Med*. 1975;122(4):285-288.
39. Ingram GI, Mathews JA, Bennett AE. Controlled trial of joint aspiration in acute haemophilic haemarthrosis. *Ann Rheum Dis*. 1972;31(5):423.
40. De la Corte-Rodriguez H, Rodriguez-Merchan EC, Alvarez-Roman MT, Martin-Salces M, Romero-Garrido JA, Jimenez-Yuste V. Accelerating recovery from acute hemarthrosis in patients with hemophilia: the role of joint aspiration. *Blood Coagul Fibrinolysis*. 2019;30(3):111-119.
41. Valentino LA, Hakobyan N, Enockson C, et al. Exploring the biological basis of haemophilic joint disease: experimental studies. *Haemophilia*. 2012;18(3):310-318.
42. Haller J, Hyde D, Deliolanis N, de Kleine R, Niedre M, Ntziachristos V. Visualization of pulmonary inflammation using noninvasive fluorescence molecular imaging. *J Appl Physiol*. 2008;104(3):795-802.
43. Wunder A, Tung CH, Müller-Ladner U, Weissleder R, Mahmood U. In vivo imaging of protease activity in arthritis: a novel approach for monitoring treatment response. *Arthritis Rheum*. 2004;50(8):2459-2465.
44. Jansen N, Roosendaal G, Wenting M, et al. Very rapid clearance after a joint bleed in the canine knee cannot prevent adverse effects on cartilage and synovial tissue. *Osteoarthritis Cartilage*. 2009;17(4):433-440.
45. Boll H, Figueiredo G, Fiebig T, et al. Comparison of Fenestra LC, ExiTron nano 6000, and ExiTron nano 12000 for micro-CT imaging of liver and spleen in mice. *Acad Radiol*. 2013;20(9):1137-1143.

## SUPPORTING INFORMATION

Additional supporting information may be found online in the Supporting Information section.

**How to cite this article:** Vøls KK, Kjelgaard-Hansen M, Ley CD, Hansen AK, Petersen M. Initial joint bleed volume in a delayed on-demand treatment setup correlates with subsequent synovial changes in hemophilic mice. *Anim Models Exp Med*. 2020;3:160-168. <https://doi.org/10.1002/ame2.12118>