

ORIGINAL RESEARCH

The Functional & Quality of Life Outcomes of Total Glossectomy with Laryngeal Preservation

Justin M. Pyne MD¹ | Peter T. Dziegielewski MD, FRCSC² |
 Gabriela Constantinescu PhD^{3,4}  | Agnieszka Dzioba PhD¹ |
 Daniel A. O'Connell MD, MSc, FRCSC¹ | David W. J. Côté MD, MPH, CCFP, FRCSC¹ |
 Khalid Ansari MD, MEd, FRCSC¹ | Jeffrey Harris MD, MHA, FRCSC¹ |
 Dustin Conrad MD, MSc¹ | Fawaz M. Makki MD, MSc, FRCSC^{1,5} |
 Matthew Hearn MD, FRCSC¹ | Vincent L. Biron MD, PhD, FRCSC¹  |
 Hadi Seikaly MD, MAL, FRCSC¹ 

¹Department of Surgery, Division of Otolaryngology – Head and Neck Surgery, University of Alberta, Edmonton, Alberta, Canada

²Department of Otolaryngology, University of Florida, Gainesville, Florida

³Institute for Reconstructive Sciences in Medicine, Caritas Health Group, Edmonton, Alberta, Canada

⁴Communication Sciences and Disorders, University of Alberta, Edmonton, Alberta, Canada

⁵Department of Otolaryngology Head & Neck Surgery, King Faisal Specialist Hospital & Research Center, Riyadh, Saudi Arabia

Correspondence

Hadi Seikaly, MD, MAL, FRCSC, 1E4.29
 Walter C Mackenzie Center 8440-112 Street
 NW Edmonton, AB, Canada T6G 2B7.
 Email: hadi.seikaly@albertahealthservices.ca

Abstract

Background: The tongue is an essential organ for human interaction, communication and survival. To date, there is a paucity of objective functional, patient reported, or quality of life outcomes of patients undergoing a total glossectomy with preservation of the larynx (TGLP).

Objective: To examine prospectively collected objective, self-reported functional and quality of life (QOL) data in patients undergoing TGLP and free flap reconstruction.

Methods: Sixteen TGLP patients were identified in the prospective head and neck cancer and functional outcomes database between January of 2009 and December 2017. Data collection included patient age, sex, performance status, TNM staging, diagnosis and adjuvant treatment. Swallowing and speech functions were measured and prospectively recorded pre- and postoperatively. Patient reported outcomes were measured with the Speech Handicap Index (SHI) and the M.D. Anderson Dysphagia Inventory (MDADI).

Results: All patients had a significant reduction in their objective swallowing ($P = 0.035$), sentence ($P = 0.001$) and word intelligibility ($P < .001$) scores. There was no significant reduction in SHI or total MDADI scores. All patients maintained their QOL in the post-treatment time frame. There was no relationship between free-flap type and outcome.

Conclusion: Total glossectomy with laryngeal sparing and free flap reconstruction results in significant reduction in objective functional measurements, but patients report stable functional and quality of life outcomes after treatment.

KEYWORDS

anterolateral thigh free-flap, free-flap, functional outcomes, larynx preservation, oral cancer, quality of life, total glossectomy

1 | INTRODUCTION

The tongue is an essential organ for human interaction, communication and survival. Proper functioning of the tongue is vital for effortless speech production, deglutition and respiration. Impairment of this organ's performance can condemn the individual to a difficult life of tracheal breathing, enteral feeding and unintelligible speech production, which would significantly impact the person's quality of life.

The best survival outcome for patients with oral cavity squamous cell carcinoma is primary surgery followed with adjuvant treatment as needed.^{1,2} This places the surgical oncologist in the difficult position of balancing the aggressive treatment essential for survival with the eventual quality of life outcome when advising the patient suffering from this disease.³ An informed decision of treatment protocols therefore requires knowledge of survival, functional and quality of life outcomes.⁴

There is a paucity of this essential data of objective functional, patient reported and quality of life outcomes of patients undergoing a total glossectomy with preservation of the larynx (TGLP) with free flap reconstruction. The purpose of this study was to examine prospectively collected swallowing, speech and patient reported outcomes in patients undergoing TGLP, free flap reconstruction and postoperative radiation treatment (RT).

2 | PATIENTS AND METHODS

2.1 | Patient selection

Inclusion criteria:

1. Tongue squamous cell carcinoma.
2. Primary treatment: TGLP and free-flap reconstruction.
3. Availability of preoperative and postoperative functional outcomes measurements.

Exclusion criteria:

1. Previous RT to the head and neck.
2. Previous head and neck malignancy.
3. Presence of any other conditions affecting function.

2.2 | Treatment

As part of standard institutional protocols, all patients included in this study underwent a metastatic work-up including full body positron

emission tomography-computed tomography (PET-CT) and panendoscopy prior to establishing a treatment regime. Primary surgery was comprised of a single-staged procedure including tumor extirpation and defect reconstruction.

Resection: Surgery included bilateral neck dissections, lip-splitting mandibulotomy approach⁵⁻⁷ and total glossectomy. The larynx was preserved and laryngeal suspension was performed for all resections.^{3,8-11}

Tongue Reconstruction: A neo-tongue was constructed from an anterolateral thigh free-flap (ALTF) or a beavertail modified radial forearm free flap (BTRFF).¹² The ALTF reconstruction was performed with a perforator flap but included a portion of motor neurotized vastus lateralis muscle when extra bulk was required.^{8,13,14}

Adjuvant Treatment: RT was initiated four-to-six weeks post-operatively with patients receiving fractions of 50 to 70 Gy of conventional RT five times per week for six weeks. Concomitant chemotherapy was offered whenever appropriate based on the final pathology and consisted of a standard platinum-based regimen.

Rehabilitation: Patients received varying degrees of postoperative speech and swallowing rehabilitation with the program's speech and swallowing practitioners. Therapy was patient-specific and ranged from home programs to individual and group sessions.

2.3 | Data Collection

TGLP patients were identified in the Institute for Reconstructive Sciences in Medicine (iRSM) prospective head and neck cancer functional outcomes database between January of 2009 and December 2017. Patients who met study criteria were included in the cohort. Prospectively collected data included functional and quality of life outcome measurements and European Cooperative Oncology Group (ECOG) performance status. Missing data from the prospective database were collected retrospectively from the patients' charts and included age, sex, TNM staging, diagnosis and adjuvant treatment. Ethics approval HREBA.CC-19-0114 was obtained from the Health Research Ethics Board of Alberta prior to commencing the study. All patients participating in the study gave their informed consent to do so.

2.4 | Primary outcomes

1. Objective:
 - a. Swallowing function measured as g-tube dependency and aspiration
 - b. Speech production measured as word, and sentence intelligibility

2. Subjective and patient reported outcomes:

- a. Functional and quality of life outcomes measured by two validation patient administered questionnaires
 - i. Speech Handicap Index (SHI)
 - ii. M.D. Anderson Dysphagia Inventory (MDADI)

2.5 | Outcome measures

All outcomes measures were taken at one-month preoperatively and at one, six, and 12-month intervals postoperatively.

Objective outcomes: Swallowing and speech functions were measured prospectively at the *Head and Neck Surgery Functional Assessment Laboratory* (HNSFAL) at the iRSM.

Swallowing: Swallowing ability was the primary outcome and was defined acceptable when there was an absence of and complete independence from a g-tube to maintain daily caloric requirements.

Speech: Naïve listeners' assessments of speech intelligibility were completed using Computerized Assessment of Intelligibility of Dysarthric Speech (CAIDS; Pro-Ed, Austin, Texas).¹⁵ Patients read a standardized passage, which was then recorded and played to naïve listeners who were neither a trained speech pathologist nor familiar with the patient. The listeners interpreted the recording, which was scored for single word and sentence intelligibility. For all outcomes when more than one measure was obtained post-operatively, the best value was used.

TABLE 1 Characteristics of patients with TGLP included in this study.

	n (%)
Age, range	52.9, 28-73
ECOG	
0	5 (31.3)
1	7 (43.8)
2	4 (25)
Male	11 (69)
T-Stage 4	10 (63)
T-Stage 3	6 (37)
TNM Stage 4	16 (100)
Reconstruction with ALTF	11 (69)

Abbreviations: ALTF, anterolateral thigh flap; ECOG, European Cooperative Oncology Group performance status; TGLP, total glossectomy with preservation of the larynx.

TABLE 2 Objective functional outcomes of 16 advanced stage oral cavity squamous cell carcinoma patients treated with TGLP.

	G-tube dependence	Word intelligibility	Sentence intelligibility
Preoperative	2/16 (13%)	81.5%	93.3%
Postoperative	9/16 (56%)	46.9%	61.6%
P-value	.048	<.001	<.001

Abbreviation: TGLP, total glossectomy with preservation of the larynx.

Subjective outcomes: Patient reported functional and quality of life outcomes as measured by validated questionnaires:

1. Speech Handicap Index (SHI)—A 30-point questionnaire based on speech problems.¹⁶
2. M.D Anderson Dysphagia Inventory (MDADI)¹⁷

2.6 | Statistics

Statistical differences between perioperative data were measured using nonparametric Wilcoxon Signed Rank test in SPSS 25. *P*-values less than 0.05 were considered significant. We were unable to perform a multivariate analysis because of the small patient numbers.¹⁷

3 | RESULTS

Twenty-two candidate patients with TGLP were identified in the iRSM database and 16 met the inclusion criteria. All patients underwent primary surgery followed by adjuvant radiation or chemoradiation. The relevant patient demographics are displayed in Table 1. The average age of the patients was 52.9 years with a range of 28 to 73.

Functional outcomes for the 16 patients included in this study are illustrated in Table 2. There was a statistically significant increase in g-tube use post-operatively. Conversely there was a statistically significant decrease in both sentence and word intelligibility post-operatively. In terms of subjective measures, however, despite the extent of the procedure, there were no differences in perioperative self-reported speech or MDADI score (Table 3). Flap type and patient sex did not have a statistically significant effect on G-tube dependence, postoperative word intelligibility or postoperative sentence intelligibility (Table 4).

4 | DISCUSSION

All patients in this study had advanced squamous cell carcinoma (SCC) of the tongue that was resected via total glossectomy with laryngeal preservation. The reconstructions were performed utilizing the following principles to promote functional recovery. All larynges were suspended^{3,8,9,11,12} and the superior laryngeal nerves were preserved.¹⁸ All flaps were of large volume with an average of 25 cm by 12 cm for the ALTF and 14 cm by 10 cm for the BTRFF

	Preoperative score	Postoperative score	Difference	P-value
MDADI (Global)	62.8	60.3	2.50	.535
Speech (SHI)	55.7	59.9	4.20	.285

Abbreviations: MDADI, M.D. Anderson Dysphagia Inventory; SHI, Speech Handicap Index; TGLP, total glossectomy with preservation of the larynx.

TABLE 4 Analysis of factors affecting g-tube dependence, word intelligibility, and sentence intelligibility

	G-tube dependence	Postoperative word intelligibility	Postoperative sentence intelligibility
<i>Flap</i>			
ALT	7/12 (58%)	46.3%	58.7%
RFFF	2/4 (50%)	48.5%	70.3%
P-value	.096	1.00	.599
<i>Sex</i>			
M	6/11 (55%)	46.5%	60.7%
F	3/5 (60%)	47.6%	63.4%
P-value	.480	.913	1.00

and each flap had the shape that could be altered to recreate the form of the tongue.^{8,9} We generally chose the anterolateral thigh perforator flap as our flap of choice and the vastus lateralis muscle was added if more bulk was needed. When muscle was included, motor neurotization was performed to maintain neo-tongue bulk.^{8,19} All surgical approaches were transmandibular with sparing of the suprahyoid muscular sling wherever possible. The flaps were inset with a central mound that was approximately 50% larger than desired to allow for tissue atrophy and fibrosis post-RT. The central and posterior portions of the flap were further augmented in the vertical and posterior dimensions when the mandible was brought together and plated. The goal for functional speech production was to create neo-tongue that provides palate-glossal contact during phonation (see Figures 1-5). Functional swallow could be achieved when the reconstructed tongue placed pressure against the posterior pharyngeal wall and protected the larynx during deglutition.¹⁰⁻¹² This method of reconstruction is thought to enable bolus propulsion by closure of the mandible to initiate the pharyngeal phase of swallowing.

Each patient underwent prospective objective and subjective functional and quality of life assessment pre- and postoperatively. This comprehensive assessment included diet and G-tube survey, speech intelligibility and patient reported outcome questionnaires. The lack of functional outcomes standardization makes it challenging to compare results to those in the literature.²⁰⁻²² Therefore, we chose to report on the most widely used comparable outcomes of g-tube presence and dependence for swallowing. Functional assessment of speech are even more varied in the literature with most authors reporting intelligibility through author created scales.^{13,23-25} We chose to report our speech outcomes through the objective measure

TABLE 3 Self-reported and quality of life outcomes of 16 advanced stage oral cavity squamous cell carcinoma patients treated with TGLP.

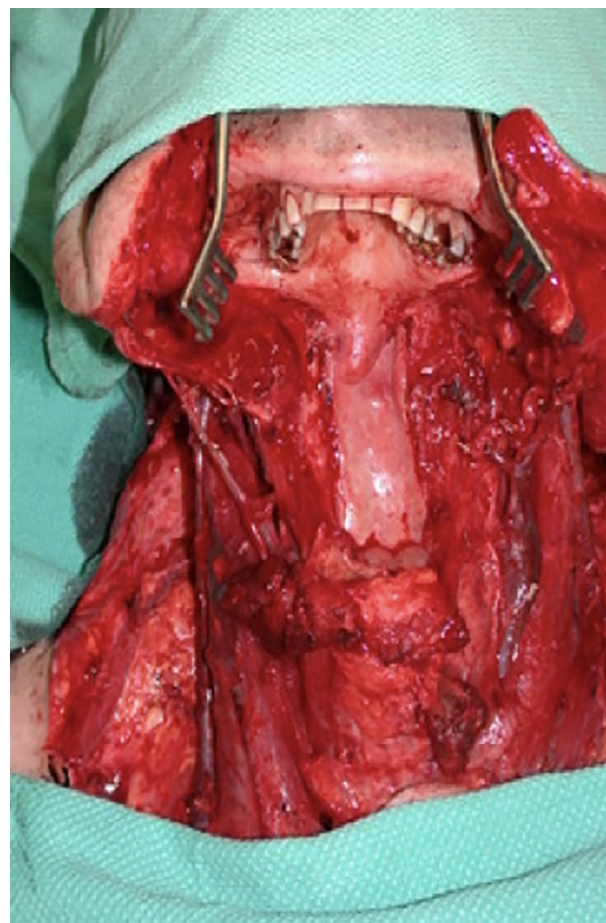


FIGURE 1 Single stage surgical tumor extirpation and defect reconstruction

of Computerized Assessment of Intelligibility of Dysarthric Speech (see methods). This test measures single word and sentence intelligibility. Single word intelligibility is a more accurate measure of speech production because it does not allow the listener to incorporate contextual clues to fill in gaps in portion of the speech that are not comprehensible.

Post-treatment, our patient cohort had a significant decrease in objective functional swallowing and speech outcomes (Table 2). Two patients (14%) were g-tube dependent before treatment and 8 patients (53%) were g-tube dependent postoperatively. Preoperative single word and sentence intelligibility were impaired and highly varied at 81.5% and 93.3%, respectively. All mean post-treatment scores decreased significantly, especially those for single word intelligibility.

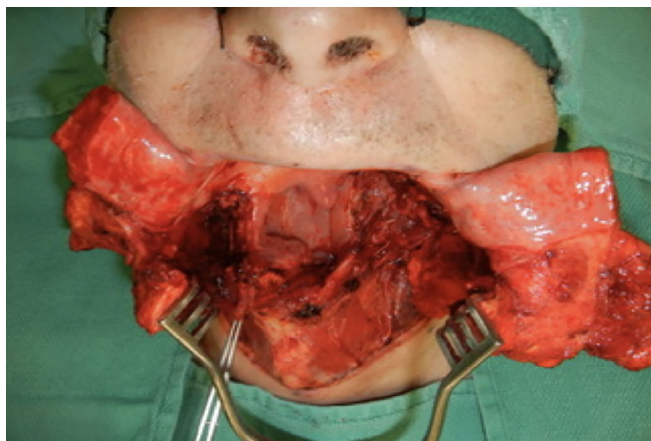


FIGURE 2 Single stage surgical tumor extirpation and defect reconstruction

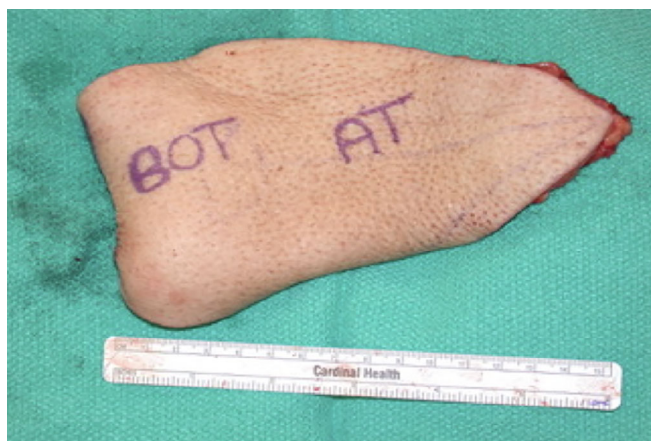


FIGURE 3 Single stage surgical tumor extirpation and defect reconstruction

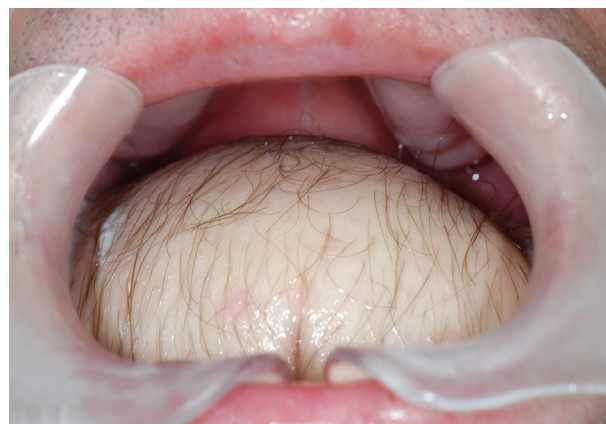

FIGURE 5 Neo-tongue reconstructed with an anterolateral thigh flap six weeks post-operatively. The reconstructed tongue bulk allows for palatal - neo-tongue contact with mandibular closure

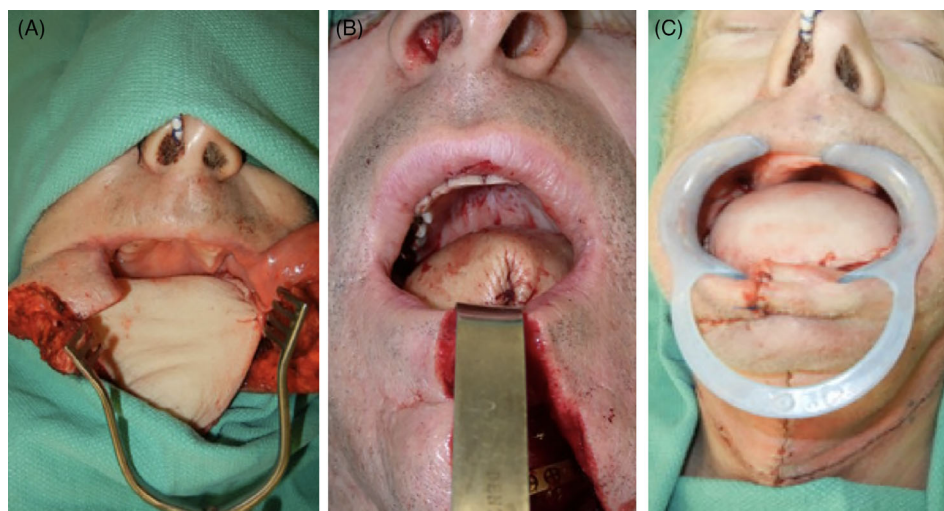


FIGURE 4 A, (left) and B, (middle) Midway through inset of neo-tongue reconstructed with an anterolateral thigh free-flap; C, (right) Completion of inset of neo-tongue

Conversely, our patient cohort, despite the extent of the procedure, yielded no differences in perioperative self-reported speech or MDADI scores (Table 3). Preoperative SHI and MDADI Total scores were 55.8 and 62.8, respectively, compared to 59.9 and 60.3 in the post-operative period. We have previously shown in a similar but earlier cohort an improved quality of life scores post-operatively. This improvement in the score was related to improved pain control, peace of mind after tumor ablation and strong social supports.²⁶ Few studies exist that have used validated quality of life measures in extensive glossectomy patients. In one of the more objective studies, it was shown that total glossectomy patients could achieve good quality of life.²⁷⁻²⁹ Our results would agree with these findings.

All our patients had access to and received some speech and swallowing therapy. We have previously shown that patients who regularly attended swallowing and speech therapy sessions had superior functional outcomes.²⁶ Other authors have also predicted

functional outcomes to be greater in motivated patients attending rehabilitation programs.^{18,30-32}

Although this study is one of the largest reported in the literature, inherent weaknesses include the small sample size and selection bias. Thus, the results need to be interpreted with caution and in the context of the individual institutions. However, this is an uncommon procedure making it difficult to obtain large numbers for study.

This, to our knowledge, is the first study to report on the objective functional, patient reported outcomes for patients undergoing TGLP. Our findings illustrate that there are significant functional deficits based on the objective outcomes after this procedure, but surprisingly the patients reported minimal change in their function and quality of life. These results further highlight the complexity of these treatment protocols and suggest that this procedure is well tolerated and potentially acceptable to the patients even though it results in significant measured functional deficits. Therefore, patients should be counseled around the objective diminished speech and swallowing functions in the perioperative period in conjunction with the stable subjective outcomes highlighted in this study.

5 | CONCLUSIONS

Total glossectomy with laryngeal sparing and free-flap reconstruction results in significant reduction in objective functional measurements, but patients report acceptable and stable functional and quality of life outcomes after treatment. This is valuable information that will help physicians counsel their patients when discussing treatment options.

AUTHOR CONTRIBUTIONS

Justin M. Pyne and Hadi Seikaly contributed to the study design, data collection, data analysis, and manuscript preparation and editing. Peter T. Dziegielewski contributed to the study design. Gabriela Constantinescu contributed to data collection and manuscript editing. Agnieszka Dzioba contributed to data collection. Daniel A. O'Connell, David W. J. Côté, Fawaz Makki, Khalid Ansari, Jeffrey Harris, Dustin Conrad, Matthew Hearn and Vincent L. Biron contributed to the study design.

ORCID

Gabriela Constantinescu  <https://orcid.org/0000-0001-7709-6547>

Vincent L. Biron  <https://orcid.org/0000-0002-7661-5277>

Hadi Seikaly  <https://orcid.org/0000-0002-8939-1364>

REFERENCES

- Campana JP, Meyers AD. The surgical management of oral cancer. *Otolaryngol Clin North Am*. 2006;39:331-348. <https://doi.org/10.1016/j.otc.2005.11.005>.
- Vartanian JG, Kowalski LP. Acceptance of major surgical procedures and quality of life among long-term survivors of advanced head and neck cancer. *Arch Otolaryngol Head Neck Surg*. 2009;135:376-379. <https://doi.org/10.1001/archoto.2009.5>.
- Seikaly H, Rieger J, Wolfaardt J, Moysa G, Harris J, Jha N. Functional outcomes after primary oropharyngeal cancer resection and reconstruction with the radial forearm free flap. *Laryngoscope*. 2003;113:897-904. <https://doi.org/10.1097/00005537-200305000-00023>.
- van Linden van den Heuvel C, van Zuuren F, Wells M, van der Laan G, Reintsema H. Paradigm shift in head and neck oncology patient management. *J Otolaryngol Head Neck Surg*. 2017;46:57. <https://doi.org/10.1186/s40463-017-0229-8>.
- Dziegielewski PT, O'Connell DA, Rieger J, Harris JR, Seikaly H. The lip-splitting mandibulotomy: aesthetic and functional outcomes. *Oral Oncol*. 2010;46:612-617. <https://doi.org/10.1016/j.oraloncology.2010.05.006>.
- Dziegielewski PT, Mlynarek AM, Dimitry J, Harris JR, Seikaly H. The mandibulotomy: friend or foe? Safety outcomes and literature review. *Laryngoscope*. 2009;119:2369-2375. <https://doi.org/10.1002/lary.20694>.
- Al-Saleh MAQ, Punithakumar K, Lagravere M, et al. Three-dimensional morphological changes of the temporomandibular joint and functional effects after mandibulotomy. *J Otolaryngol Head Neck Surg*. 2017;46:8. <https://doi.org/10.1186/s40463-017-0184-4>.
- Yun IS, Lee DW, Lee WJ, Lew DH, Choi EC, Rah DK. Correlation of neotongue volume changes with functional outcomes after long-term follow-up of total glossectomy. *J Craniofac Surg*. 2010;21:111-116. <https://doi.org/10.1097/SCS.0b013e3181c46692>.
- Sakuraba M, Asano T, Miyamoto S, et al. A new flap design for tongue reconstruction after total or subtotal glossectomy in thin patients. *J Plast Reconstr Aesthet Surg*. 2009;62:795-799. <https://doi.org/10.1016/j.bjps.2007.09.056>.
- O'Connell DA, Rieger J, Harris JR, et al. Swallowing function in patients with base of tongue cancers treated with primary surgery and reconstructed with a modified radial forearm free flap. *Arch Otolaryngol Head Neck Surg*. 2008;134:857-864. <https://doi.org/10.1001/archotol.134.8.857>.
- Kimata Y, Sakuraba M, Hishinuma S, et al. Analysis of the relations between the shape of the reconstructed tongue and postoperative functions after subtotal or total glossectomy. *Laryngoscope*. 2003;113:905-909. <https://doi.org/10.1097/00005537-200305000-00024>.
- Seikaly H, Rieger J, O'Connell D, Ansari K, Alqahtani K, Harris J. Beavertail modification of the radial forearm free flap in base of tongue reconstruction: technique and functional outcomes. *Head Neck*. 2009;31:213-219. <https://doi.org/10.1002/hed.20953>.
- Yu P, Robb GL. Reconstruction for total and near-total glossectomy defects. *Clin Plast Surg*. 2005;32:411-9-vii. <https://doi.org/10.1016/j.cps.2005.02.005>.
- Chen CY, Su CY, Hwang CF, Chuang HC, Jeng SF, Chen YC. Ablation of advanced tongue or base of tongue cancer and reconstruction with free flap: functional outcomes. *Eur J Surg Oncol*. 2006;32:353-357. <https://doi.org/10.1016/j.ejso.2005.12.010>.
- Seikaly H, Idris S, Chuka R, et al. The Alberta reconstructive technique: an occlusion-driven and digitally based jaw reconstruction. *Laryngoscope*. 2019;129(S4):S1-S14. <https://doi.org/10.1002/lary.28064>.
- Rinkel RN, Verdonck-de Leeuw IM, Van Reij EJ, Aaronson NK, Leemans R. Speech handicap index in patients with oral and pharyngeal cancer: better understanding of patients' complaints. *Head Neck*. 2008;30:868-874. <https://doi.org/10.1002/hed.20795>.
- Chen AY, Frankowshi R, Bishop-Leone J, et al. The development and validation of a dysphagia-specific quality-of-life questionnaire for patients with head and neck cancer: The M. D. Anderson Dysphagia Inventory. *Arch Otolaryngol Head Neck Surg*. 2001;127(7):870-876.
- Bova R, Cheung I, Coman W. Total glossectomy: is it justified? *ANZ J Surg*. 2004;74(3):134-138.
- O'Connell DA, Rieger J, Dziegielewski PT, et al. Effect of lingual and hypoglossal nerve reconstruction on swallowing function in head and neck surgery: prospective functional outcomes study. *J Otolaryngol Head Neck Surg*. 2009;38:246-254.

20. Mlynarek AM, Rieger JM, Harris JR, et al. Methods of functional outcomes assessment following treatment of oral and oropharyngeal cancer: review of the literature. *J Otolaryngol Head Neck Surg*. 2008; 37:2-10.
21. Rieger JM, Tang JAL, Harris J, et al. Survey of current functional outcomes assessment practices in patients with head and neck cancer: initial project of the head and neck research network. *J Otolaryngol Head Neck Surg*. 2010;39:523-531.
22. Kerr P, Myers CL, Butler J, Alessa M, Lambert P, Cooke AL. Prospective functional outcomes in sequential population based cohorts of stage III/ IV oropharyngeal carcinoma patients treated with 3D conformal vs intensity modulated radiotherapy. *J Otolaryngol Head Neck Surg*. 2015;44:17. <https://doi.org/10.1186/s40463-015-0068-4>.
23. Yanai C, Kikutani T, Adachi M, Thoren H, Suzuki M, Iizuka T. Functional outcome after total and subtotal glossectomy with free flap reconstruction. *Head Neck*. 2008;30:909-918. <https://doi.org/10.1002/hed.20804>.
24. Paydarfar JA, Freed GL, Gosselin BJ. The anterolateral thigh fold-over flap for total and subtotal glossectomy reconstruction. *Microsurgery*. 2016;36:297-302. <https://doi.org/10.1002/micr.30033>.
25. de Carvalho-Teles V, Sennes LU, Gielow I. Speech evaluation after palatal augmentation in patients undergoing glossectomy. *Arch Otolaryngol Head Neck Surg*. 2008;134:1066-1070. <https://doi.org/10.1001/archotol.134.10.1066>.
26. Dziegielewski PT, Ho ML, Rieger J, et al. Total glossectomy with laryngeal preservation and free flap reconstruction: objective functional outcomes and systematic review of the literature. *Laryngoscope*. 2013;123:140-145. <https://doi.org/10.1002/lary.23505>.
27. Ruhl CM, Gleich LL, Gluckman JL. Survival, function, and quality of life after total glossectomy. *Laryngoscope*. 1997;107:1316-1321.
28. Matsui Y, Shirota T, Yamashita Y, Ohno K. Analyses of speech intelligibility in patients after glossectomy and reconstruction with fasciocutaneous/myocutaneous flaps. *Int J Oral Maxillofac Surg*. 2009; 38:339-345. <https://doi.org/10.1016/j.ijom.2009.01.009>.
29. Dzioba A, Aalto D, Papadopoulos-Nydam G, et al. Functional and quality of life outcomes after partial glossectomy: a multi-institutional longitudinal study of the head and neck research network. *J Otolaryngol Head Neck Surg*. 2017;46:56. <https://doi.org/10.1186/s40463-017-0234-y>.
30. Vartanian JG, Magrin J, Kowalski LP. Total glossectomy in the organ preservation era. *Curr Opin Otolaryngol Head Neck Surg*. 2010;18:95-100. <https://doi.org/10.1097/MOO.0b013e3283376c3f>.
31. van Lierop AC, Basson O, Fagan JJ. Is total glossectomy for advanced carcinoma of the tongue justified? *S Afr J Surg*. 2008;46:22-25.
32. Day AMB, Doyle PC. Assessing self-reported measures of voice disability in tracheoesophageal speakers. *J Otolaryngol Head Neck Surg*. 2010;39:762-768.

How to cite this article: Pyne JM, Dziegielewski PT, Constantinescu G, et al. The Functional & Quality of Life Outcomes of Total Glossectomy with Laryngeal Preservation. *Laryngoscope Investigative Otolaryngology*. 2020;5:853-859. <https://doi.org/10.1002/lio2.435>