





ORIGINAL RESEARCH

A new landmark for the identification of the facial nerve during parotid surgery: A cadaver study

Khalid Hussain Al-Qahtani MD, MSc, FRCSc¹  | Fahad Mohammad AlQahtani MD²  |
 Mahmoud Mohammad Muqat MD³ |
 Mubarak Shaie AlQahtani MD, SBORL, ABORL, FEBORL⁴ | Ali M. Al-Qannass MD⁵ |
 Tahera Islam MD⁶  | Jabir Alharbi MD, SBORL^{1,7} | Haneen Sebah MD, SBORL¹  |
 Mohammad Alqarni MD³ | Hadi Hakami MD³

¹Department of Otolaryngology Head and Neck Surgery, College of Medicine, King Saud University, Riyadh, Saudi Arabia

²Department of Otolaryngology, Head and Neck Surgery, Prince Mohammad Bin Abdulaziz Hospital, Riyadh, Saudi Arabia

³Department of Otolaryngology, Head and Neck Surgery, King Abdulaziz Medical City, Jeddah, Saudi Arabia

⁴Department of Otolaryngology, Head and Neck Surgery, King Abdulaziz Medical City, Abha, Saudi Arabia

⁵Department of Otolaryngology, Head and Neck Surgery, Armed Forces Hospital, Khamis Mushait, Saudi Arabia

⁶College of Medicine and Research Center, King Saud University, Riyadh, Saudi Arabia

⁷Department of Otolaryngology, Head and Neck Surgery, Majmaah University, Majmaah, Saudi Arabia

Correspondence

Khalid Hussain Al-Qahtani, Department of Otolaryngology-Head & Neck Surgery, King Abdul Aziz University Hospital, King Saud University, PO Box 245, Riyadh 11411, Saudi Arabia.
 Email: kqresearch@hotmail.com

Abstract

Objective: Precise knowledge of facial nerve anatomy is crucial for parotid surgery. Although several surgical landmarks to identify the facial nerve have been described in literature, their position is variable, inconsistent, and difficult to follow in some cases. The purpose of this study was to prove that the facial nerve trunk (FNT) is located midway between the mastoid tip (MT) and osteocartilaginous junction of the external auditory canal (EAC).

Methods: A prospective study of 7 frozen cadaver specimens, of which 13 facial sides were dissected. The distances between the osteocartilaginous junction and the MT, between the FNT and the MT, and between the FNT and the osteocartilaginous junction were recorded, respectively.

Results: The distance between the osteocartilaginous junction and the MT ranged from 17 to 21 mm, with a mean of 19.5 mm (SD = ± 1.19). The mean distances between the osteocartilaginous junction and the FNT and between the MT and the FNT were 9.2 mm (± 1.58) and 10.3 mm (± 1.79), respectively.

Conclusion: The FNT was consistently located close to the midpoint between mastoid tip inferiorly and bony-cartilaginous junction of the EAC superiorly.

Level of Evidence: NA

KEYWORDS

anatomy, facial nerve, landmark, parotidectomy

1 | INTRODUCTION

Preservation of the facial nerve is an important objective of parotidectomy. Therefore, precise knowledge of its anatomy is a prerequisite for identification of its location. The facial nerve exits the

skull through the stylomastoid foramen and enters the parotid gland, where it bifurcates into the upper (cervicofacial) and lower (temporofacial) divisions. These divisions further divide to form the final major branches: temporal, zygomatic, buccal, marginal mandibular, and cervical. The portion of the nerve that extends from the

This is an open access article under the terms of the Creative Commons Attribution-NonCommercial-NoDerivs License, which permits use and distribution in any medium, provided the original work is properly cited, the use is non-commercial and no modifications or adaptations are made.

© 2020 The Authors. *Laryngoscope Investigative Otolaryngology* published by Wiley Periodicals LLC. on behalf of The Triological Society.

stylomastoid foramen to the bifurcation into the upper and lower divisions is commonly known as the facial nerve trunk (FNT).

Several approaches to facilitate the intraoperative identification and preservation of the facial nerve during parotid surgery have been reported. However, the anterograde approach, involving the identification of the FNT, is preferred by most surgeons. Several surgical landmarks have been described in literature with respect to this approach, including the tragal pointer,¹ posterior belly of the digastric muscle (PBDM),² styloid process,³ tympanomastoid suture (TMS),^{3,4} and posterior auricular artery.⁵

In our surgical experience of 10 years, we found that the FNT is located deep to the midpoint between an imaginary line joining the mastoid tip (MT) and osteocartilaginous junction of the external auditory canal (EAC), in most of our patients. The length of this imaginary line was approximately 2 cm in most patients. This technique aided the easy identification of the nerve and reduced the incidence of facial nerve paralysis and the surgical time required for parotidectomy.

Since a vast majority of our patients are of Arab ethnicity, the aims of this study were to investigate whether the FNT is located midway between the MT and the osteocartilaginous junction of the EAC on cadaveric specimens of different ethnicities, to compare this reference point with other landmarks, and to review the available literature on this topic.

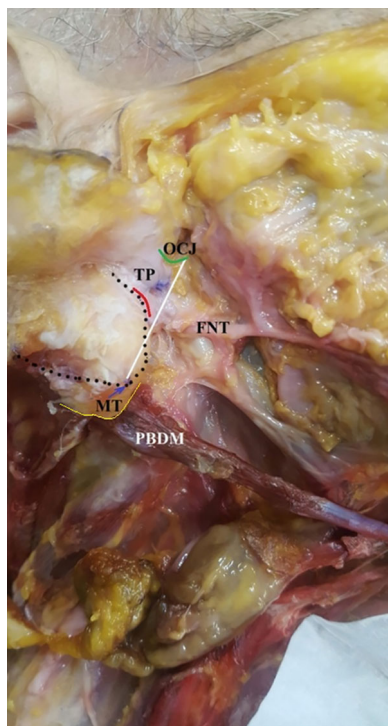


FIGURE 1 Right lateral view of a cadaver showing the facial nerve trunk (FNT) and some of its landmarks. TP, tragal pointer; MT, mastoid tip (blue arrow); PBDM, posterior belly of the digastric muscle. The black dotted line represents mastoid process. The green line represents the osteocartilaginous junction (OCJ) of the EAC. The red line represents the tympanomastoid suture. The white line represents an imaginary line drawn between the OCJ and MT. The yellow line borders the fatty tissue below mastoid process that was not dissected

2 | MATERIALS AND METHODS

Thirteen facial sides (six right and seven left) from seven Caucasian (four women, three men) cadavers were dissected in the anatomy laboratory of a university hospital. The age of the individuals ranged between 66 and 77 years, with a mean age of 71 years (the age of one cadaver was unknown). In each case, the cadaver was placed in the supine position with the head tilted slightly to the opposite side. A modified Blair's skin incision was made, beginning at the preauricular skin crease, extending vertically downward, curving under the ear lobe, and then curving downward at a natural skin crease along the sternocleidomastoid (SCM) muscle located in the neck. Skin flaps were elevated in the plane superficial to the superficial muscular aponeurotic system in the face and in the subplatysmal plane at the neck. After elevation of the flaps, the SCM was visible and located posterior to the gland. The anterior border of the SCM was dissected from the posterior border of the gland. The anterior branch of the greater auricular nerve was divided for enhanced exposure of the gland at this level. The PBDM was located deep to the SCM and was separated from the gland till its attachment at the mastoid process. Dissection continued anteriorly to separate the gland from the cartilaginous EAC, with identification of the tragal pointer and the osteocartilaginous junction of the EAC, which is essentially, the

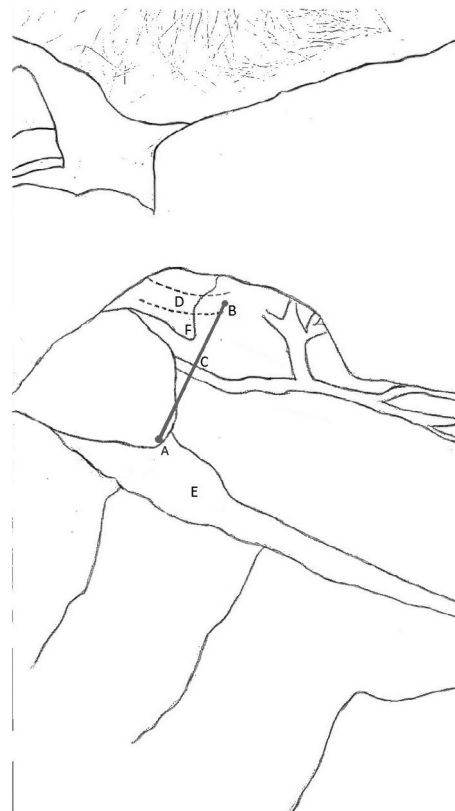


FIGURE 2 Schematic representation of the landmarks for the identification of the facial nerve in a cadaver. A, mastoid tip; B, osteocartilaginous junction of the external auditory canal; C, facial nerve trunk; D, the external auditory canal (dashed line indicates its localization); E, posterior belly of the digastric muscle; F, tragal pointer

junction of the outer cartilaginous one third of the EAC, and its inner bony two-thirds, and can be easily felt by the surgeon's finger. The TMS was exposed by sharply dissecting the overlying fascia. After identification of the FNT and its landmarks, the following measurements were made with a surgical ruler (Figure 1). A diagram of the

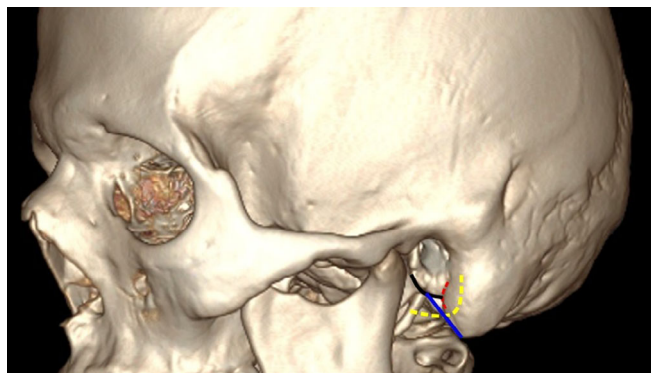


FIGURE 3 A three-dimensional CT of the skull bones showing the facial nerve trunk (yellow, dashed line). The osteocartilaginous junction (OCJ) of the external auditory meatus (black curved line), the location of the tympano-mastoid suture (red dashed line), and an imaginary line drawn from the mastoid tip (MT) to the OCJ (blue line)

TABLE 1 Distance from osteo-cartilaginous junction (OCJ) of the external auditory canal to the mastoid tip (MT), and from the facial nerve trunk (FNT) to the OCJ and the MT

Distance (mm)	OCJ to MT	OCJ to FNT	MT to FNT
Mean	19.5	9.2	10.3
Max	21	11	15
Min	17	5	8
SD	1.19	1.58	1.79

landmarks and the measurement of the distance is shown in Figures 2 and 3.

- First, we measured the distance along an imaginary line joining the antero-inferior-most aspect of the osteocartilaginous junction of the EAC and the inferior-most portion of the superficial aspect of the tip of the mastoid process, and the distances between the middle of the FNT and each of these two structures were compared, to identify whether the FNT was located at the midpoint of this imaginary line or closer to one of the two structures.
- Second, the shortest distance between the middle of the FNT and the other landmarks was measured as follows:
 - The shortest distance between the most lateral aspect of the TMS and the middle of the FNT.
 - The shortest distance between the PBDM and the middle of the FNT.
 - The shortest distance between the most anterior-inferior point of the tragal pointer and the middle of the FNT.

The measurements were repeated by two head and neck surgeons with the same surgical ruler, and their average was used for analysis. The two surgeons collected their data independently but were not blinded to each other. The differences for each measurement between the sexes and facial sides were compared using *t*-tests performed with the Statistical Package for Social Sciences (IBM Corporation, version 22.0, Armonk, NY).

3 | RESULTS

We observed that the facial nerve exited the skull through the stylomastoid foramen and bifurcated to its main divisions (superior and inferior) within the parotid gland in all cadavers. The nerve had five distal branches in all the dissected sides. The mean distance between the osteocartilaginous junction of the EAC and the MT was

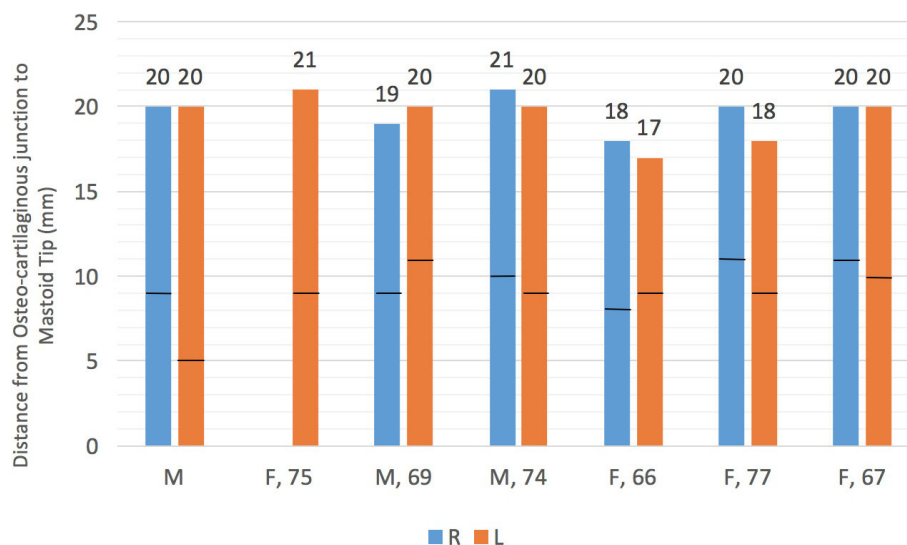


FIGURE 4 The distance from the osteocartilaginous junction of the external auditory canal (EAC) to the mastoid tip of all cadavers. The black line represents the position of the facial nerve trunk (FNT)

TABLE 2 Distances of different landmarks to the facial nerve trunk (FNT)

Distance(mm)	TP	TMS	PBDM
Mean	10.69	3.76	9.03
Max	13	6	12.5
Min	6	0.5	6
±SD	2.25	1.54	2.33

Abbreviations: PBDM, posterior belly of digastric muscle; TMS, tympano-mastoid suture; TP, tragal pointer.

(±SD) 19.50 (± 1.19) mm and ranged from 17 to 21 mm (Table 1). The facial nerve was located at the exact midpoint between the osteocartilaginous junction of the EAC and the MT in two facial sides, both of which were located on the left (Figure 4). Furthermore, it was within 0.5 mm of the midpoint in 3 sides, within 1.0 mm in 6 sides, within 1.5 mm in one side, and within 5.0 mm in the remaining side (Figure 4). The FNT was closer to the osteocartilaginous junction in 7 sides and closer to the MT in 4 sides. The average distance between the FNT and the midpoint of the imaginary line was 1.07 (±1.25) mm.

The mean distance from the osteocartilaginous junction of the EAC to the FNT was 9.20 (± 1.58) mm and that from the MT to the FNT was 10.30 (± 1.79) mm. The closest landmark to the FNT was the TMS (mean distance of 3.76 ± 1.54 mm), while the PBDM was the second closest landmark (mean distance of 9.03 ± 2.33 mm). The tragal pointer was the furthest from the nerve trunk (mean distance of 10.69 ± 2.25 mm) (Table 2). No statistically significant differences in any of the measurements were observed between the sexes or facial sides.

4 | DISCUSSION

Several anatomical landmarks for intraoperative identification of the facial nerve during parotid surgery have been described in the literature. A majority of surgeons use a combination of landmarks, in order to safely identify the nerve.¹⁻¹⁵ Some of the common landmarks are:

- The “cartilaginous pointer” or “tragal pointer”: the anterior tip of the tragus portion of the external ear cartilage. The main trunk is reported to be 1 cm deep and inferior to the pointer.
- The posterior belly of the digastric muscle and its insertion on the mastoid process, which is slightly lateral to the stylomastoid foramen.
- The tympanomastoid suture line, which can be identified by palpation. The main trunk is reported to be 6 to 8 mm from the inferiomedial end of this suture line.

However, there are a lot of controversies about the end point of this suture line.

An ideal landmark should be consistent and have a stable relationship with the nerve, facilitating its safe identification.

In this study, we found that the mean distance between the osteocartilaginous junction of the EAC and MT was 19.5 mm, with

relatively low variability (SD = ±1.19 mm). In 12 of 13 facial sides that were dissected (92.30%), the FNT was within 1.5 mm of the midpoint of an imaginary line joining the osteocartilaginous junction of the EAC and MT. Parotid surgery was performed on cadavers of European ethnicity supports our clinical observations in patients in Saudi Arabia, who are primarily of Arab ethnicity. The published literature does not highlight the importance of the midpoint between the osteocartilaginous junction of the EAC and MT as a landmark for the identification of the FNT during parotid surgery.

The TMS has been described as the most accurate and reliable landmark for localization of the facial nerve by several authors, due to its close proximity to the nerve and its invariable location.^{4,6-10,16} The TMS was determined to be the closest landmark to the FNT (mean distance: 3.76 ± 1.54 mm) in this study. This is in accordance with most published data; however, considerable variation has been reported in the literature. Rea et al¹¹ showed, in a study of 26 Caucasian cadavers, that the TMS was within a distance of 2.5 (±0.4) mm, similar to the distance reported by de Ru et al (2.7 mm).⁷ Greater variation was described by Pather and Osman¹² in their study of 40 cadavers, who reported the distance to range from 4.9 to 18.6 mm. Pather and Osman¹² and Browne¹⁷ found that the TMS is obscured by the tendon of the sternocleidomastoid muscle, which is inserted in the mastoid process from its apex to its superior border. They also argued that this landmark requires deep dissection, which is risky and unnecessary. Nishida and Matsuura⁸ reported that the use of TMS as a landmark renders the surgery more complex, because elevation of the periosteum around the ear canal and dissection of the inferior region is required to visualize the TMS. Robertson and Blake⁶ reported difficulties in identifying the “drop-off point” of the TMS to localize the FNT.

The PBDM was the second closest landmark to the FNT (mean distance of 9.03 ± 2.33 mm). However, this distance was highly variable and ranged from 6.0 to 12.5 mm. It demonstrated the highest SD among all landmarks in this study. Holt reported that the PBDM was located 9 mm from the FNT,¹³ which was similar to our observations. The considerable variability in the distance between the muscle and the nerve reflects its nature as a soft tissue structure that is susceptible to retraction during surgery. Moreover, it has been reported that the attachment of the muscle to the MT is variable,⁷ which may explain why the PBDM is not regarded as a reliable landmark for the facial nerve during parotidectomy by some authors.¹¹

The tragal pointer was the furthest landmark from the FNT in our study (mean distance of 10.69 ± 2.25 mm, ranging from 6.0 to 13.0 mm). Similar to the PBDM, the tragal pointer has been described as an unreliable landmark due to the variability in shape, size, and orientation. Moreover, it may not actually point to the nerve.^{7,11,14} In our study, considerable variations in tragal pointer shape and direction were noticed, which were consistent with previously published data.

Our study had some limitations, including its relatively small sample size (which may mask statistical differences discernible in larger samples) and the lack of comparison among different ethnicities (all cadavers were of European origin). Furthermore, the age of the dissected cadavers was far greater than the typical age of patients

undergoing parotidectomy. Moreover, the dissection of cadavers obviously differs from surgery on live patients, owing to critical changes involving tissue texture and pliability, and the environment of the laboratory, which is considerably different from that of the operating room.¹¹

The strength our study was its inclusion of fresh frozen cadavers, which provide a better representation of normal tissue than cadavers that had been preserved with formaldehyde, which may significantly alter the nature of the tissues. Moreover, variations in observations were minimized by using measurements that were made by two different surgeons using the same measurement tool.

5 | CONCLUSION

Our study showed that the osteocartilaginous junction of the EAC and MT is important surgical landmarks for facial nerve identification during parotid surgery, as the FNT is commonly found close and deep to the midpoint between these two structures. This landmark is of great value and can be used with the other existing surgical landmarks to ensure safer parotid gland-related procedures. We call this point Al Qahtani point.

ACKNOWLEDGMENT

The authors would like to thank Mr. Zubair Mumin Wahed for providing technical support.

CONFLICT OF INTEREST

The authors declare that no potential conflict of interest.

ORCID

Khalid Hussain Al-Qahtani  <https://orcid.org/0000-0002-6993-7868>

Fahad Mohammad AlQahtani  <https://orcid.org/0000-0002-0050-6189>

Tahera Islam  <https://orcid.org/0000-0001-9440-0280>

Haneen Sebah  <https://orcid.org/0000-0002-5454-8712>

BIBLIOGRAPHY

1. Beahrs OH. The surgical anatomy and technique of parotidectomy. *Surg Clin North Am.* 1977;57(3):477-493.
2. Reid AP. Surgical approach to the parotid gland. *Ear Nose Throat J.* 1989;68(2):151-154.
3. Conley J. *Salivary Glands and the Facial Nerve.* Stuttgart: George Thieme Publishers; 1975.
4. Witt RL, Weinstein GS, Rejto LK. Tympanomastoid suture and digastric muscle in cadaver and live parotidectomy. *Laryngoscope.* 2005; 115(4):574-577.
5. Liu M, Wang SJ, Benet A, Meybodi AT, Tabani H, Ei-Sayed IH. Posterior auricular artery as a novel anatomic landmark for identification of the facial nerve: a cadaveric study. *Head Neck.* 2018;40(7):1461-1465. <https://doi.org/10.1002/hed.25127>.
6. Robertson MS, Blake P. A method of using the tympanomastoid fissure to find the facial nerve at parotidectomy. *Aust N Z J Surg.* 1984; 54(4):369-373.
7. De Ru JA, Van Benthem PPG, Bleys RL, Lubsen H, Hordijk GJ. Landmarks for parotid surgery. *J Laryngol Otol.* 2001;115(2):122-125.
8. Nishada M, Matsuura H. A landmark for facial nerve identification during parotid surgery. *J Oral Maxillofac Surg.* 1993;51(4):451-453.
9. Lawson HH. Value of the tympanomastoid fissure in the exposure of the facial nerve. *Br J Surg.* 1988;75(4):309.
10. Bushey A, Queresby F, Boice JG, Landers MA, Baur DA. Utilization of the tympanomastoid fissure for intraoperative identification of the facial nerve: a cadaver study. *J Oral Maxillofac Surg.* 2011;69(9):2473-2476.
11. Rea PM, McGarry G, Shaw-Dunn J. The precision of four commonly used surgical landmarks for locating the facial nerve in anterograde parotidectomy in humans. *Ann Anat.* 2010;192(1):27-32.
12. Pather N, Osman M. Landmarks of the facial nerve: implications for parotidectomy. *Surg Radiol Anat.* 2006;28(2):170-175.
13. Holt JJ. The stylomastoid area: anatomic-histologic study and surgical approach. *Laryngoscope.* 1996;106(4):396-400.
14. Tribble WM. Symposium: management of tumors of the parotid gland. III. Management of the facial nerve. *Laryngoscope.* 1976;86(1):25-27.
15. Saha S. Identification of facial nerve during parotidectomy: a combined anatomical & surgical study. *Indian J Otolaryngol Head Neck Surg.* 2014;66(1):63-68.
16. De Ru JA, Bleys RLAW, Van Benthem PPG, Hordijk GJ. Preoperative determination of the location of parotid gland tumors by analysis of the position of the facial nerve. *J Oral Maxillofac Surg.* 2001;59(5): 525-528.
17. Browne HJ. Exposure of the facial nerve. *Br J Surg.* 1988;75(7): 724-725.

How to cite this article: Al-Qahtani KH, AlQahtani FM, Muqat MM, et al. A new landmark for the identification of the facial nerve during parotid surgery: A cadaver study. *Laryngoscope Investigative Otolaryngology.* 2020;5:689–693. <https://doi.org/10.1002/lio2.431>