




ORIGINAL RESEARCH

Electric scooter craniofacial trauma

Farhoud Faraji MD, PhD¹  | Jason H. Lee BS²  | Farshid Faraji MS³ |
 Bridget MacDonald BA² | Parisa Oviedo BS² | Emelia Stuart BS² |
 Michael Baxter MD⁴ | Caresse L. Vuong BS⁵ | Samuel H. Lance MD⁶ |
 Amanda A. Gosman MD⁶ | Edward M. Castillo PhD⁵ | David B. Hom MD¹ 

¹Department of Surgery, Division of Otolaryngology-Head and Neck Surgery, University of California, San Diego, California

²University of California San Diego School of Medicine, San Diego, California

³University of Illinois Chicago School of Medicine, Chicago, Illinois

⁴Department of Otolaryngology, Naval Medical Center San Diego, San Diego, California

⁵Department of Emergency Medicine, University of California, San Diego, California

⁶Department of Surgery, Division of Plastic Surgery, University of California, San Diego, California

Correspondence

David B. Hom, UC San Diego Department of Surgery, Division of Otolaryngology-Head and Neck Surgery, University of California, San Diego, 200 West Arbor Drive MC8895, San Diego, CA 92103.
 Email: dbhom@health.ucsd.edu

Abstract

Objective: The use of standing electronic scooters associated with micromobility applications (e-scooters) has risen nationally. The aim of this study was to obtain a detailed view of soft tissue and bony craniofacial injury associated with e-scooter-related trauma.

Methods: Single-institution retrospective case series of patients presenting to a level 1 trauma center emergency department or trauma unit with documented e-scooter-related craniofacial injury.

Results: Of 203 included patients, 188 (92.6%) patients sustained craniofacial injury. One hundred thirty-one (64.5%) had exclusively soft tissue injury, 3 (1.5%) exclusively bony injury, 51 (25.1%) both soft and bony injuries, and twenty-five (12.3%) patients sustained dental injury. Aesthetic units most frequently sustaining acute soft tissue injury were the forehead (n = 106, 34.6%), scalp (n = 36, 11.8%), chin (n = 34, 11.1%), upper lip (n = 32, 10.5%), and cheek (n = 31, 10.1%). Aesthetic subunits most often sustaining acute soft tissue injury included the brow (42, 13.7%), central forehead (39, 12.7%), lateral forehead (n = 25, 8.2%), and upper lip vermillion (n = 23, 7.5%). Craniofacial osseous fracture most often occurred in the orbit (n = 42, 24.6%) and maxilla (n = 40, 23.4%). Individual osseous segments most frequently sustaining acute fracture included the anterior maxillary sinus wall (n = 22, 12.9%), nasal bone (n = 20, 11.7%), lateral orbital wall (n = 16, 9.4%), orbital floor (n = 15, 8.8%), and zygomatic bone (13, 7.6%).

Conclusions: Our analysis demonstrates that most patients presenting to our center with craniofacial trauma sustained acute bony fracture, most often to the midface. Our data of common injuries associated with e-scooter trauma could inform implementation in the form of facial safety equipment or safety skills training for e-scooter riders.

Level of evidence: 4

KEYWORDS

craniofacial, electric, face, head, scooter, trauma

Farhoud Faraji and Jason H. Lee contributed equally to this study.

This is an open access article under the terms of the Creative Commons Attribution-NonCommercial-NoDerivs License, which permits use and distribution in any medium, provided the original work is properly cited, the use is non-commercial and no modifications or adaptations are made.

© 2020 The Authors. *Laryngoscope Investigative Otolaryngology* published by Wiley Periodicals, Inc. on behalf of The Triological Society.

1 | INTRODUCTION

Standing electronic scooters associated with micromobility smartphone applications (e-scooters) were initially introduced in September 2017 in Santa Monica, California.^{1,2} Over the subsequent years, multiple companies have joined the micromobility trend, resulting in the rapid expansion of e-scooter availability and use.³ By 2018, 38.5 million e-scooter rides had been recorded on 85 000 e-scooters in approximately 100 US cities. Southern Californian cities represented some of the densest areas of e-scooter use, including San Diego which contains thousands of e-scooters.⁴

Concurrent with the growth in e-scooter use, injuries related to their use have also increased. A dramatic rise in emergency department visits related to e-scooter use has been observed nationally. Analysis of the National Electronic Injury Surveillance System from 2014 to 2018 demonstrated a 222% increase in age-adjusted e-scooter injury incidence and a 365% increase in age-adjusted hospital admission, with the steepest rises occurring from 2017 to 2018.⁵ Multiple case series in the United States have described total body injuries associated with e-scooter-related trauma, which can range in severity from mild contusion, abrasion, and laceration to severe injury necessitating intensive care or resulting in death. These studies found craniofacial soft tissue or bony injury to occur in 26% to 58% of patients presenting with e-scooter-related trauma.⁶⁻⁹ However, the specific patterns of craniofacial injury secondary to e-scooter-related trauma remain incompletely characterized.

Given the rise in micromobility devices, e-scooters represent an emerging mode of trauma with poorly understood patterns of craniofacial injury that will likely exert additional burdens on the health care system. The high proportion of craniofacial trauma in e-scooter trauma patients necessitates a more detailed characterization of the bony and soft tissue injuries sustained in these patients. Such insights are likely to improve implementation of safety measures and the expedited evaluation and treatment for this growing trauma patient population.

2 | METHODS

We performed a retrospective case series of all patients presenting with e-scooter-related injuries from April 2018 to September 2019 to the University of California San Diego (UCSD) Medical Center Emergency or Level 1 Trauma Departments. Patients were identified by query of the UCSD electronic medical record for encounters including terms related to face and/or head trauma and the term "scooter." A database with predetermined variables was then populated via data abstraction from patient records by two independent reviewers. Exclusion criteria included nonmotorized scooter use, trauma from use of scooter as a weapon, and death prior to evaluation.

In addition to basic demographic information, data pertaining to soft tissue and bony injury were collected. Soft tissue injury information was determined from physical exam findings at presentation. The soft tissue injury was localized to the facial aesthetic subunit, and categorized into contusions, abrasions, lacerations, avulsions, burns, or injuries limited to tenderness to palpation. Bony injury information was

gathered from the radiologist report of computed tomography studies. Dental injuries were recorded if dental fracture or avulsion was documented. Baseline characteristics were analyzed using descriptive statistics. Bony and soft tissue facial injuries were categorized into quintiles and projected onto skull or face illustrations in heat map formats using Adobe Photoshop. Each soft tissue or bony injury was considered as an individual injury and the total number of each respective injury category was considered the sum of individual injuries. Injuries without adequate information documented to specify facial or bony aesthetic subunit were excluded from the heat map projections.

3 | RESULTS

In total, 206 patients presented with e-scooter-related injuries. Three patients were excluded due to nonmotorized scooter use, use of

TABLE 1 Baseline characteristics

Variable		n	Percent
Age, years	Median (IQR)	36 (27-50)	
Sex	Male	119	58.6
	Female	84	41.4
Race	White	123	60.6
	Black	9	4.4
	Other	55	27.1
	Native Hawaiian or Pacific Islander	2	1.0
	Asian	10	4.9
	Unknown	4	2.0
Ethnicity	Hispanic	28	13.8
	Non-Hispanic	175	86.2
City of residence	San Diego	76	37.4
	Other	127	62.6
State of residence	California	139	68.5
	Not California	64	31.5
Tourism/visitor status	Yes (vacation or business)	101	49.8
	No (in town)	102	50.2
Required emergency medical service involvement	Yes	129	63.5
	No	74	36.5
Scooter driver	Yes	201	99.0
	No	2	1.0
Intoxicated ^a	Yes	110	54.2
	No	93	45.8
Alcohol use at time of injury	Yes	93	45.8
	No	110	54.2

Abbreviation: IQR, interquartile range.

^aIntoxicated status was indicated if medical record contained documentation that the patient appeared intoxicated based on the examining clinician's impression.

scooter as a weapon, and death prior to medical evaluation. Of the remaining 203 patients, the median age at injury was 36 years (interquartile range [IQR]: 27-50). Seven (3.4%) patients were under 18 years old. Most patients were male (58.6%), of White race (60.6%), non-Hispanic ethnicity (86.2%), and lived in San Diego county (50.2%). One hundred thirty-nine (68.5%) patients presented by ambulance. The great majority of patients were driving the e-scooter (99.0%). Many patients were intoxicated at the time of accident (54.2%), with substances including alcohol (93, 45.8%), methamphetamines (9, 4.4%), cannabis (15, 7.4%), and opioids (7, 3.4%; Table 1).

One hundred eighty-eight (92.6%) patients presented with craniofacial injury, further categorized as follows: 131 (64.5%) were documented to sustain exclusively soft tissue injury, 3 (1.5%) exclusively bony injury, and 51 (25.1%) both soft and bony injuries. Twenty-five (12.3%) patients sustained dental injury. Patients with soft tissue injury presented most often with lacerations ($n = 121$, 59.6%), abrasions ($n = 98$, 48.3%), or contusions ($n = 75$, 36.9%). Patients rarely presented with avulsion injury (8, 2.6%) or sole tenderness to palpation without visible evidence of tissue injury (7, 2.3%). Median laceration length was 2 cm (IQR: 1.5-3.0, range: 0.1-10).

Facial soft tissue injuries categorized by aesthetic subunit are presented in Figure 1 and Table 2. In total, 306 discrete facial soft tissue injuries were documented. The aesthetic unit that most frequently sustained acute soft tissue injury was the forehead ($n = 106$, 34.6%). The scalp ($n = 36$, 11.8%), chin ($n = 34$, 11.1%), upper lip ($n = 32$, 10.5%), and cheek ($n = 31$, 10.1%) were the next most frequently injured units and showed similar rates of soft tissue injury

(Figure 1A). The aesthetic unit demonstrating a distinctly lower rate of soft tissue injury was the ear ($n = 1$, 0.3%).

Higher resolution analysis was then performed with aesthetic subunits. Some aesthetic units, which in some cases lacked adequate information in the medical record to allow for further classification into subunits, were denoted as not otherwise specified (NOS): Cheek ($n_{\text{NOS}} = 20$, 6.5% of all soft tissue injuries), eyelid ($n_{\text{NOS}} = 11$, 3.6%),

TABLE 2 Soft tissue injuries

Aesthetic unit	Aesthetic subunit	Any soft tissue injury	Percent ^a
1. Forehead	A. Central	39	12.7
	B. Lateral	25	8.2
	C. Brow	42	13.7
2. Nose	A. Dorsum	18	5.9
	B. Lateral wall	0	0.0
	C. Ala	1	0.3
	D. Tip	0	0.0
	E. Columella	0	0.0
	X. NOS ^b	6	2.0
3. Eyelid	A. Superior	6	2.0
	B. Inferior	4	1.3
	C. Lateral canthus	4	1.3
	D. Medial canthus	0	0.0
	X. NOS ^b	11	3.6
4. Cheek	A. Infraorbital	7	2.3
	B. Zygomatic	3	1.0
	C. Buccal	1	0.3
	D. Parotid-masseteric	0	0.0
	X. NOS ^b	20	6.5
5. Upper lip	A. Philtrum	7	2.3
	B. Lateral	2	0.7
	C. Vermillion	23	7.5
6. Lower lip	A. Central	0	0.0
	B. Vermillion	14	4.6
7. Chin		34	11.1
8. Ear	A. Helix	0	0.0
	B. Antihelix	0	0.0
	C. Concha	1	0.3
	D. Lobule	0	0.0
	E. Retroauricle	0	0.0
	X. NOS ^b	1	0.3
9. Scalp		36	11.8
10. Unspecified		1	0.3
Total		306	100.0

^aPercent of all soft tissue injuries.

^bNOS—not otherwise specified. Documentation did not contain adequate information to classify injury to specific aesthetic subgroup. These injuries were excluded from the soft tissue injuries heat map analysis displayed in Figure 1.

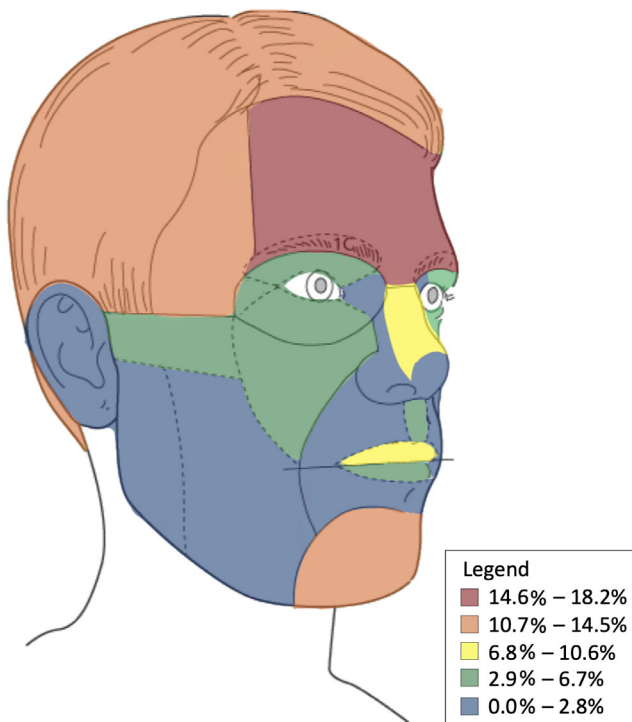


FIGURE 1 Facial soft tissue injury categorized by aesthetic subunit

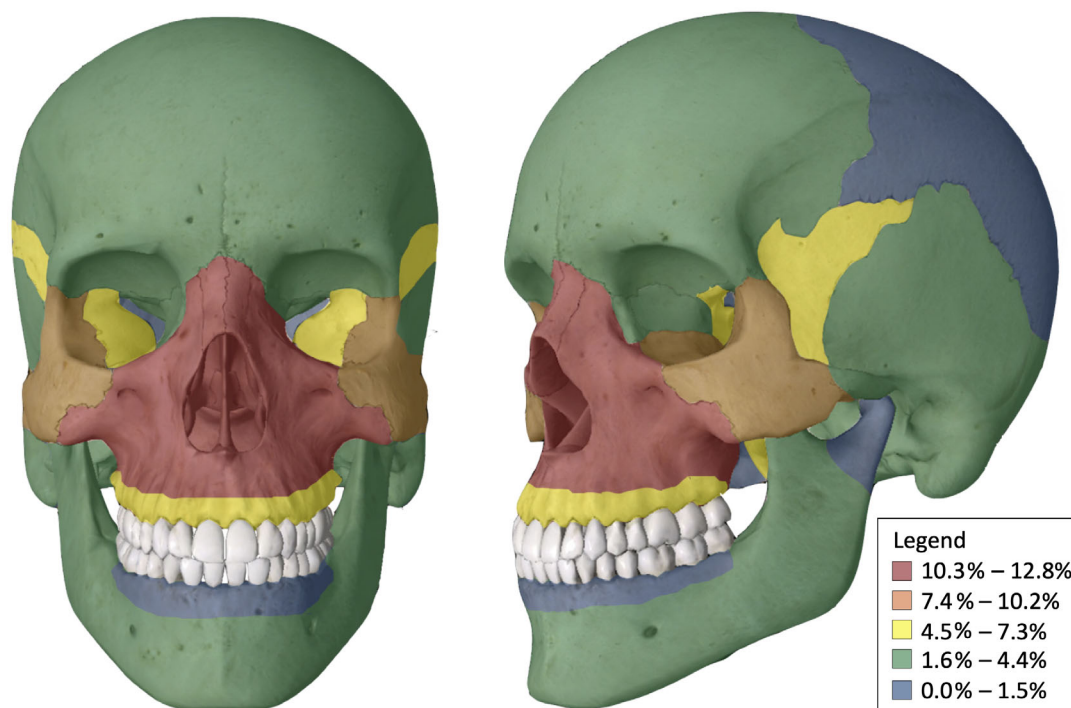


FIGURE 2 Bony craniofacial injury

nose ($n_{\text{NOS}} = 6$, 2.0%), ear ($n_{\text{NOS}} = 1$, 0.3%) represented. These unclassifiable soft tissue injuries were thus excluded from the facial soft tissue subunit heatmap analysis. The aesthetic subunits most frequently sustaining acute soft tissue injury included the brow (42, 13.7%), central forehead (39, 12.7%), lateral forehead ($n = 25$, 8.2%), and upper lip vermillion ($n = 23$, 7.5%; Figure 1B).

Bony injuries are presented in Figure 2 and Table 3. In total, 171 discrete acute craniofacial osseous fractures were documented. The structures most often fractured included the orbit ($n = 42$, 24.6%) and maxilla ($n = 40$, 23.4%), each of which comprised nearly one quarter of all discrete bony fractures. The parietal ($n = 3$, 1.8%) and occipital (2, 1.2%) bones represented the least frequently fractured bones of the head. The individual osseous segments that most frequently sustained acute fracture included the anterior maxillary sinus wall ($n = 22$, 12.9%), nasal bone ($n = 20$, 11.7%), lateral orbital wall ($n = 16$, 9.4%), orbital floor (8.8%), and zygomatic bone (13, 7.6%). The osseous segments least frequently fractured included the petrous temporal bone ($n = 1$, 0.6%), mandibular subcondyle ($n = 1$, 0.6%), mandibular condyle ($n = 2$, 1.2%), posterior maxillary wall ($n = 2$, 1.2%), and mastoid temporal bone ($n = 2$, 1.2%).

Of the 188 patients presenting with craniofacial injury, 13 patients (6.9%) presented with intracranial injury encompassing epidural, subdural, subarachnoid, and intraparenchymal hemorrhage. Of the 9 patients with sphenoid fractures, 3 (33%) sustained intracranial injury, and one of these patients developed cerebrospinal fluid leak. The remaining 10 intracranial injuries occurred in 4 patients with temporal bone fractures (2 squamous, 1 mastoid, and 1 petrous), 1 patient with zygomaticomaxillary complex fracture, and 5 patients without craniofacial osseous injury.

4 | DISCUSSION

As e-scooter use continues to increase, the literature has begun to examine the health care consequences related to this mode of transportation. This report presents a detailed view of the craniofacial soft tissue and bony injury sustained in e-scooter-related trauma. Our findings indicate that e-scooter-related craniofacial trauma occurs in a broad segment of the young adult to middle aged population, who are the most likely to ride e-scooters. And our findings recapitulate existing findings in the literature that a large portion of those who present with e-scooter-related trauma are intoxicated.

Consistent with previous reports, facial lacerations were present in over half of patients.⁷ Along with the high incidence of extremity injuries reported in the literature, our data corroborate the intuitive notion that many craniofacial injuries result from riders attempting to break their forward fall.^{6,7,10} In comparison to seated vehicles, the scooter rider maintains a relatively high center of gravity predisposing the rider toward impacts of the face and hands when falling. Several studies have cited the head and face as the frequently affected anatomical regions in e-scooter accidents, occurring in 20% to 58% of presenting patients.^{6-8,11-13} Previous work has quantified the incidence of facial involvement in e-scooter injuries. Trivedi et al focused specifically on craniofacial injuries following e-scooter accidents, outlining the categorical severity (severe vs minor) as well as location of injury (upper, middle, or lower face).⁷ Bresler et al reported type of facial injury (eg, closed head, laceration, or fracture).¹³ However, no study to our knowledge has characterized the nature of e-scooter-related craniofacial injury.

The current study builds on these works to provide a more detailed picture of the craniofacial anatomy involved in e-scooter-related

TABLE 3 Bony injuries

Site	Subsite	n	Percent ^a
Frontal sinus	Anterior table	5	2.9
	Posterior table	5	2.9
Parietal bone		3	1.8
Occipital bone		2	1.2
Temporal	Mastoid	2	1.2
	Petrous	1	0.6
	Squamous	4	2.3
Zygomatic bone		13	7.6
Maxillary bone	Anterior maxillary wall	22	12.9
	Posterior maxillary wall	2	1.2
	Maxillary sinus, NOS ^b	7	4.1
	Maxillary alveolar ridge	9	5.3
Nasal bone		20	11.7
Orbit	Floor	15	8.8
	Medial wall	5	2.9
	Lateral wall	16	9.4
	Roof	6	3.5
Mandible	Condyle	2	1.2
	Subcondyle	1	0.6
	Ramus	4	2.3
	Body	3	1.8
	Symphysis/parasymphysis	5	2.9
	Mandibular alveolar ridge	3	1.8
Sphenoid bone		9	5.3
Other facial bone fractures		7	4.1
Total		171	100.0

^aPercent of all bony injuries.

^bNOS—not otherwise specified. Documentation did not contain adequate information to classify injury to specific aesthetic subgroup. These injuries were excluded from the osseous injury heat map analysis displayed in Figure 2.

trauma. We elected to implement the facial aesthetic unit classification for localizing soft tissue trauma because it is a standardized method on which reconstructive technique is founded.¹⁴ To achieve similar technical accuracy, bony injuries were classified based on the involved craniofacial bone(s). Our findings reflect the reality that craniofacial trauma is rarely confined to specific aesthetic units or bony segments by demonstrating that injuries often involved multiple contiguous aesthetic subunits and/or bony segments.

E-scooter-related soft tissue injury manifested most often in the form of lacerations and abrasions, injuries that are likely to leave lasting aesthetic defects on the face even if they are addressed in a timely and technically appropriate manner.

In our study, the forehead was the most common soft tissue region of the face injured. In regards to facial bone injury, the midface was the most common injured site. More broadly, soft tissue injury most often involved the forehead, scalp, and chin. The relatively high

rate of soft tissue injury to the chin combined with paucity of lower face bony injury suggest that the lower face sustains lower-energy e-scooter-related trauma. This notion also applies to the upper face, with the forehead demonstrating a high rate of soft tissue injury but the frontal bones showing relatively few e-scooter-related fractures. Conversely, bony injury most often involved the nasal bone, anterior maxillary sinus, lateral orbital wall, and zygoma, indicating that the midface is the most frequent region of bony injury involved in e-scooter-related craniofacial trauma.

In looking at the demographics, over 60% of the patients who had facial injuries from e-scooters did not live in San Diego. Thus, either these out of town visitors were riding e-scooters at disproportionately higher rates than the local residents or they may be less adept to control the e-scooter and therefore more susceptible to craniofacial trauma. It remains unknown whether first-time riders were the most vulnerable to facial injuries.

As research increasingly demonstrates the risks associated with e-scooter use, the medical community can begin to identify preventable measures and advocate for improved safety surrounding these devices. Our review revealed over half of riders were intoxicated with either alcohol, or under the influence of tetrahydrocannabinol, methamphetamine, or diacetylmorphine [heroin]. These findings are corroborated by other studies and represent a dangerous and avoidable increase in risk to riders when operating e-scooters. Our findings also confirm a small percentage of riders (3.4%) were under the age of 18 as seen in previous studies, demonstrating another potentially avoidable risk. Further investigation may underscore the importance of basic precautions when riding e-scooters such as abstinence from substance use, being of the legal age (18) to ride an e-scooter, and wearing a helmet when riding. While micromobility companies and local and state governments implement measures to improve e-scooter safety, existing data suggest that riders often do not comply to company or governmental regulations regarding age limitations, protective equipment use, or intoxicated riding.⁶⁻⁸ Moreover, given the high rate of significant craniofacial injury, our study indicates that scooter riders may benefit from facial protective helmets.

This retrospective study is subject to limitations associated with the reported data including the underreporting and nonspecific reporting of clinical findings. For example, it is likely that not every simple abrasion was recorded or specified by facial aesthetic subunit, especially in the setting of more severe injury. This may explain the few cases of patients who had bony injury without soft tissue injury. Intoxication data is also incomplete, as substance use may not have been documented by provider or reported accurately by patient. In addition, blood alcohol levels or urine toxicology screens were ordered in a subset of patients, therefore this retrospective review often relied on the documented clinical impression of the examining physician.

5 | CONCLUSION

While e-scooters represent a convenient and accessible mode of transportation, they are associated with a disproportionately high

burden of craniofacial trauma, especially fractures of the midface. Our data of common injuries associated with e-scooter trauma could inform implementation in the form of facial safety equipment or safety skills training for e-scooter riders.

CONFLICT OF INTEREST

The authors declare no conflicts of interest.

ORCID

Farhoush Faraji  <https://orcid.org/0000-0001-5078-813X>

Jason H. Lee  <https://orcid.org/0000-0003-3487-1042>

David B. Hom  <https://orcid.org/0000-0002-1000-3171>

REFERENCES

1. Bird Rides Inc. Santa Monica Mobility Pilot Program; 2018.
2. Hall M. *Bird Scooters Flying Around*. Santa Monica: CA, Santa Monica Daily Press; 2018.
3. Dickey MR. *The Electric Scooter Wars of 2018*. Bay Area: California, Techcrunch; 2018.
4. Shared Micromobility in the U.S.: 2018; 2019. <https://nacto.org/shared-micromobility-2018/>
5. Namiri NK, Lui H, Tangney T, Allen IE, Cohen AJ, Breyer BN. Electric scooter injuries and hospital admissions in the United States, 2014-2018. *JAMA Surg*. 2020. <https://jamanetwork.com/journals/jamasurgery/fullarticle/2758159>
6. Trivedi TK, Liu C, ALM A, et al. Injuries associated with standing electric scooter use. *JAMA Netw Open*. 2019;2:e187381.
7. Trivedi B, Kesterke MJ, Bhattacharjee R, Weber W, Mynar K, Reddy LV. Craniofacial injuries seen with the introduction of bicycle-share electric scooters in an urban setting. *J Oral Maxillofac Surg*. 2019; 77:2292-2297.
8. Kobayashi LM, Williams E, Brown CV, et al. The e-merging e-pidemic of e-scooters. *Trauma Surg Acute Care Open*. 2019;4:e000337.
9. DiMaggio CJ, Bukur M, Wall SP, Frangos SG, Wen AY. Injuries associated with electric-powered bikes and scooters: analysis of US consumer product data. *Inj Prev*. 2019. <https://doi.org/10.1136/injuryprev-2019-043418>
10. Mayhew LJ, Bergin C. Impact of e-scooter injuries on emergency department imaging. *J Med Imaging Radiat Oncol*. 2019;63:461-466.
11. Badeau A, Carman C, Newman M, Steenblik J, Carlson M, Madsen T. Emergency department visits for electric scooter-related injuries after introduction of an urban rental program. *Am J Emerg Med*. 2019;37: 1531-1533.
12. Bekhit MNZ, Le Fevre J, Bergin CJ. Regional healthcare costs and burden of injury associated with electric scooters. *Injury*. 2020; 51: 271-277.
13. Bresler AY, Hanba C, Svider P, Carron MA, Hsueh WD, Paskhover B. Craniofacial injuries related to motorized scooter use: a rising epidemic. *Am J Otolaryngol*. 2019;40:662-666.
14. Gonzalez-Ulloa M. Restoration of the face covering by means of selected skin in regional aesthetic units. *Br J Plast Surg*. 1956;9:212-221.

How to cite this article: Faraji F, Lee JH, Faraji F, et al. Electric scooter craniofacial trauma. *Laryngoscope Investigative Otolaryngology*. 2020;5:390-395. <https://doi.org/10.1002/lio2.380>