

## Carcinoma of Vagina in Utero-Vaginal Prolapse: A Rare Presentation

Acharya S<sup>1</sup>, Uprety DK<sup>2</sup>

<sup>1</sup> Department of Obstetrics and Gynaecology, College of Medical Sciences(CMS), Bharatpur, Chitwan, Nepal

<sup>2</sup> Department of Obstetrics and Gynaecology, B.P. Koirala Institute of Health Sciences, Dharan, Nepal.

### ABSTRACT

Primary vaginal carcinoma in uterovaginal prolapse is a rare entity. We report a case of an 84-years-old lady, who presented with long standing vaginal ulcer in association with third degree uterovaginal prolapse. Incisional biopsy was taken from the ulcer. Histopathological examination showed a large cell keratinizing squamous cell carcinoma.

**Keywords:** *Squamous cell carcinoma, uterovaginal prolapse, vaginal carcinoma*

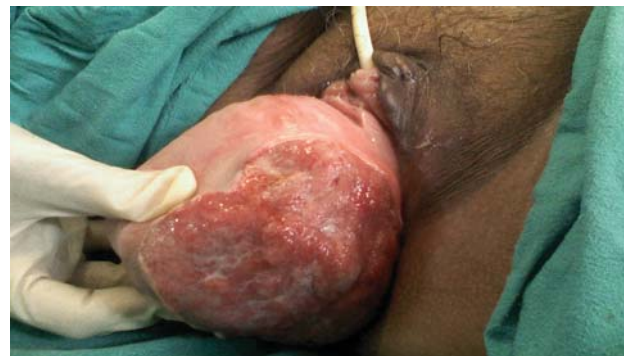### INTRODUCTION

Primary vaginal carcinoma is rare and comprises only one to two percent of all gynecologic malignancies<sup>1</sup> with its incidence peak during the sixth decade.<sup>2</sup> The development of carcinoma of vagina in the ulcerated part of the uterovaginal prolapse is a rare entity described in the English literature. Herein, we present a case of an early stage of vaginal carcinoma developed in the long standing uterovaginal prolapse with review of the related literature.

### CASE REPORT

An 84-years-old multiparous lady presented with complaints of a mass coming out per vagina for last 62 years. She had noticed an ulcer in the prolapsed part for the last 1 year, which was associated with foul smelling discharge. Patient had intermittent retention of urine for last several years, but had no history of hematuria or frequency of micturition. She gave history of constipation, but no tenesmus and blood stained stool. Patient denied any history of bleeding per vagina or other local and systemic illnesses. According to her medical records, she had noticed an ulcer of 3X3cm in

the left lateral wall of the prolapsed part one year prior to admission. That was treated with regular wound dressing, systemic antibiotics followed by repositioning of the prolapsed part. Physical examination at presentation revealed utero vaginal procidentia of 18X12 cm, which was irreducible and with keratinization of 3 cm diameter in the cervix (Figure 1).



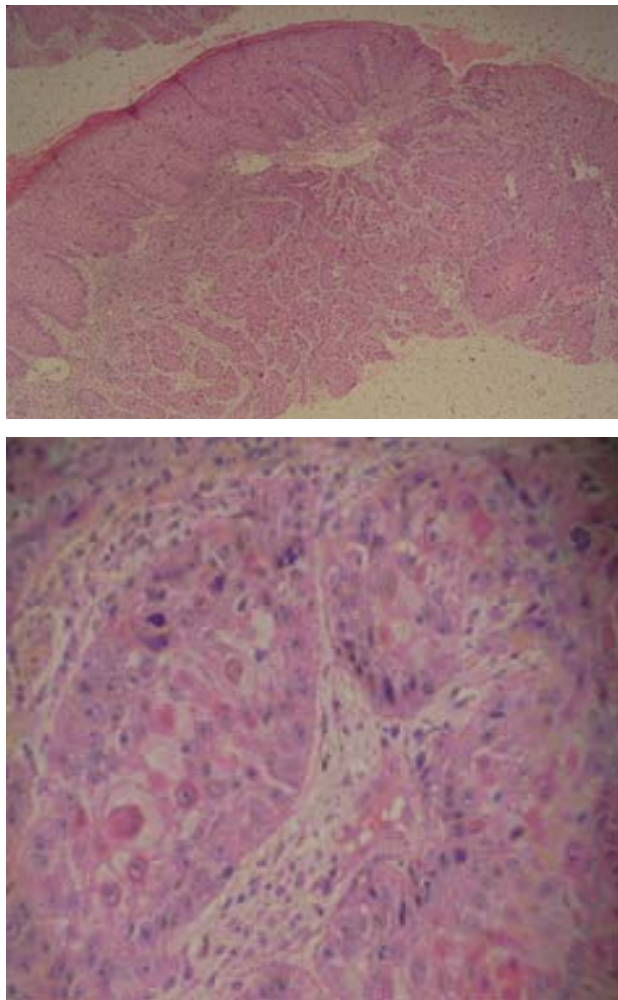
There was a non-tender ulcer of 12X10 cm in the left lateral wall of the upper and middle third of vagina

**Figure 1.** Third degree uterovaginal prolapse with malignant ulcer in the lateral vaginal wall

### Correspondence:

Dr. Sarita Acharya  
Department of Obstetrics and Gynaecology, College of Medical Sciences(CMS), Bharatpur, Chitwan, Nepal  
Post box no: 23  
E-mai: saritaacharya142@yahoo.com

yellowish green discharge. There was no active bleeding and the ulcer didn't bleed on touch. The lower margin of ulcer was 3 cm above the external os and other part of the prolapse was congested. Vulva was healthy and there was no palpable inguinal lymphadenopathy. Incisional biopsy was taken from the ulcer including part of healthy tissue. Histopathology showed large cell keratinizing squamous cell carcinoma (Figure 2).



**Figure 2.** Microscopic findings of the specimen showing vaginal carcinoma in low and high power field

She was then referred to cancer hospital for radiotherapy and further management.

## DISCUSSION

Eighty-four percent of vaginal cancers are secondary to the cancer arising from the adjacent organs, cervix (32%), endometrium (18%), colon and rectum (9%),

ovary (6%), or vulva (6%).<sup>3</sup> Primary vaginal cancers commonly develops in the upper third of the vagina. The most common histologic type of primary vaginal cancer is squamous cell carcinoma (70- 80 %) followed by adenocarcinoma.<sup>1</sup> Risk factors for developing vaginal cancer are bacterial infection, trauma especially after pessary or prolapse and human papilloma virus (HPV) exposure. Daling et al reported that the invasive vaginal cancer has a strong correlation to HPV infection and HPV DNA was detected in 60% of such patients in a population based study.<sup>4</sup> Vaginal bleeding is the most common complaint associated with vaginal cancer, though some patients may present with pelvic pain and vaginal discharge.<sup>1</sup> Less frequently, lesions involving the anterior vaginal wall may lead to dysuria, hematuria, or urgency. Alternatively, constipation may result from those of the posterior vaginal wall cancers. Primary vaginal carcinoma associated with uterovaginal prolapse is rare pathology. In presence of genital prolapse, vaginal carcinoma usually presents as an ulcerative lesion and it is believed that continued irritation as well as chronic inflammation of the exposed vagina contributes to these ulcerative lesions.<sup>5</sup> Such lesions need careful evaluation and should be subjected to biopsy under direct vision or during colposcopic examination to confirm or rule out the underlying carcinoma.

The management of vaginal cancer depends upon its prognostic factors, i.e. patient's age, location, size and extent of tumor, clinical staging and histological classification. Surgical treatment with or without radiotherapy is the optimum treatment for early stage cancer, whereas advanced stage vaginal carcinoma with or without associated genital prolapse is treated with radiotherapy alone.<sup>6</sup> Stage I lesions involving the middle and lower third of the vagina are generally best treated by radiotherapy using a combination of intracavitary and external beam therapy. Lesions at the same stage involving the apex or upper vagina are often treated similar to primary cervical tumors utilizing comparable doses and treatment fields. Early diagnosis with adequate treatment can minimize the morbidity and mortality associated with vaginal carcinoma. Five years survival is 80% if diagnosed in first stage as compared to 35–50, 35 and 20% in Stage II, III and IV respectively.<sup>7</sup> In conclusion, biopsy should be taken from a long standing ulcer in an uterovaginal prolapse as there is always a potential chance of malignancy.

## REFERENCES

1. Schorge JO, Schaffer JI, Halvorson LM, Hoffman BL, Bradshaw KD, Cunningham F G. Williams Gynecology. 1<sup>st</sup> ed. New York: Mc Graw- Hill; 2008.p 677.
2. Batista TP, Morais JA, Reis TJ, Macedo FI. A rare case of invasive vaginal carcinoma associated with vaginal prolapse. Arch Gynecol Obstet. 2009; 280:845-8.
3. Fu YS, Reagan JW. Pathology of the uterine cervix, vagina and vulva. Philadelphia: WB Saunders, 1989:193-224, 336-338.
4. Daling JR, Madeleine MM, Schwartz SM, Shera KA, Carter JJ, McKnight B, et al. A population-based study of squamous cell vaginal cancer: HPV and cofactors. Gynecol Oncol. 2002; 84:263-70.
5. Copeland LJ, Jarrell JF. Textbook of gynecology. 2<sup>nd</sup> ed. Philadelphia: WB Saunders ; 2000. p 1209-24.
6. Ghosh SB, Tripathi R, Mala YM, Khurana N. Primary invasive carcinoma of vagina with third degree uterovaginal prolapse: a case report and review of literature. Arch Gynecol Obstet. 2009; 279:91-3.
7. Gupta N, Mittal S, Dalmia S, Misra R. A rare case of primary invasive carcinoma of vagina associated with irreducible third degree uterovaginal prolapse. Arch Gynecol Obstet .2007; 276:563-64.