

Kikuchi- Fujimoto Disease of Mesenteric Lymph Nodes Mimicking Acute Appendicitis

Anne Shrestha,¹ Katie Newton,¹ Emyr Benbow,¹ Rajeev Kushwaha¹

¹Department of Surgery, Manchester Royal Infirmary, Oxford Road, Manchester, M13 9WL.

ABSTRACT

Kikuchi-Fujimoto disease, or histiocytic necrotising lymphadenopathy of unknown aetiology, is a rare, benign and self-limiting cause of lymphadenopathy often involving the cervical nodes, and rarely presenting with mesenteric lymphadenopathy. We present a 26-year-old Caucasian male, who presented with right iliac fossa pain and low grade pyrexia, mimicking acute appendicitis. He underwent a laparotomy and an extended right hemi-colectomy for a caecal mass. Histology of the specimen showed lymph nodes with extensive areas of necrosis, with abnormal architecture suggesting Kikuchi-Fujimoto lymphadenopathy. This was further confirmed by immunohistochemistry. In this context maintenance of a high index of suspicion of this condition can avoid major surgical interventions. We describe the management of our case of Kikuchi-Fujimoto's disease involving the mesenteric nodes and provide an up to date review of the pertinent literature on this subject.

Keywords: *abdominal mass; Kikuchi- Fujimoto disease; mesenteric lymphadenopathy; necrotising lymphadenitis.*

INTRODUCTION

Kikuchi-Fujimoto disease (KFD), also known as histiocytic necrotizing lymphadenitis, was first described in Japan. It is a self-limiting, benign conditioning causing regional lymphadenopathy of unknown aetiology. It presents in all races and both sexes equally with an average age of presentation between 20-30 years. The cardinal symptoms are of that of a flu, which includes fever, myalgia, headaches, sore throats; less common symptoms include abdominal pain, weight loss and night sweats. Majority of the cases present with cervical lymphadenopathy and involvement of the mesenteric lymph nodes is uncommon. Here, we describe a case of KFD with presentation mimicking acute appendicitis and put forward an up to date review of literature relevant to the management of KFD.

CASE REPORT

A 26-year-old Caucasian male was admitted via the accident and emergency department, with right iliac fossa (RIF) pain and pyrexia. He had abdominal pain around the umbilical region for 3 days, which then migrated to the RIF; this was associated with anorexia and nausea, but no vomiting. The patient did not have any past medical, family or drug history. He was haemodynamically stable but had pyrexia of 37.9°C. Abdominal examination revealed mild tenderness over the RIF, but no guarding or rebound tenderness. The white cell count (WCC) was 10.2 but the C-reactive protein (CRP) was raised to 125mg/L (0 – 6 mg/L).

On overnight observation, the symptoms failed to resolve, therefore operative intervention was

Correspondence: Dr. Anne Shrestha, Department of Surgery, Manchester Royal Infirmary, Oxford Road, Manchester, M13 9WL. Email: shrestha.anne@doctors.net.uk, Phone: +447708112407.

considered necessary. Under general anaesthesia, abdominal palpation revealed an ill-defined mass in the RIF, which was accessed through an oblique muscle-cutting incision. A hard, irregular mass was present in the caecum, which had perforated with minimal contamination. The appendix appeared normal. There were multiple enlarged lymph nodes in the mesentery extending up to the origin of the superior mesenteric artery. Rest of the colon, small intestine and liver were normal. A radical right hemicolectomy was performed which included all palpable enlarged lymph nodes in the mesocolon. The postoperative course was uneventful and the patient was discharged on 10th postoperative day.

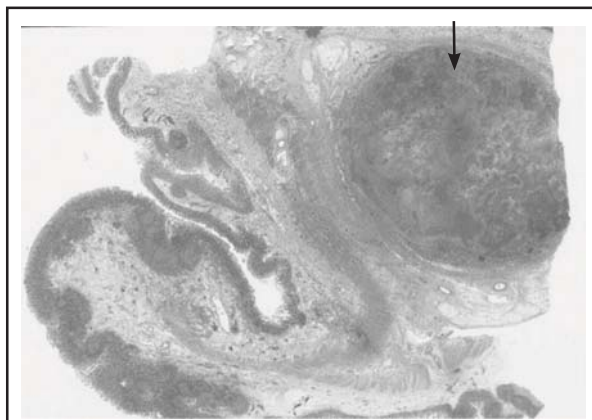


Figure 1. Section of ileocaecal region showing a lymph node on the mesentery (arrowed) involved with KFD.

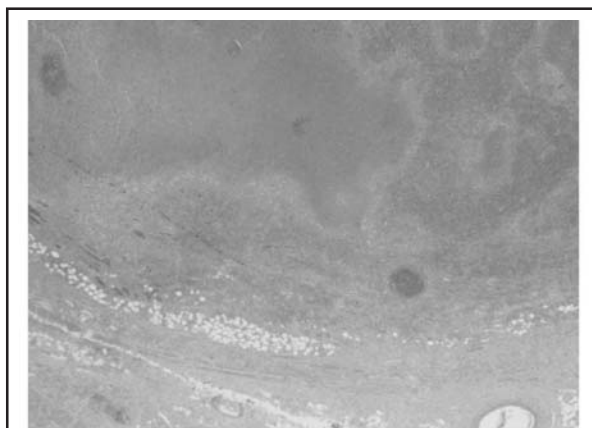


Figure 2. Section of a lymph node showing geographic areas of necrosis.




Figure 3. Section showing areas of granuloma with giant cells and necrosis.

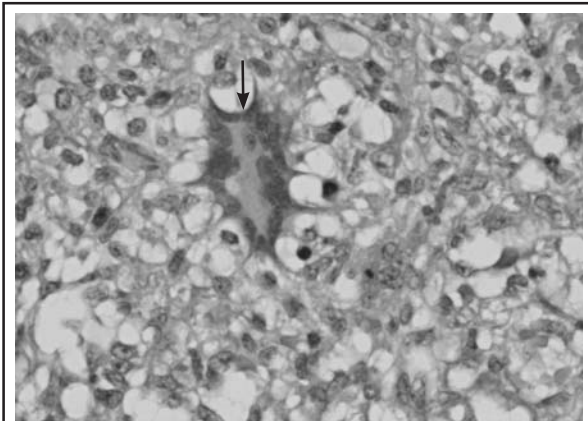


Figure 4. Section showing a multinucleated giant cell (arrowed).

Macroscopic examination of the resected specimen showed an oedematous ileocaecal valve with an oblong mass in the adjacent mesentery measuring 6.6cm x 4.0cm x 3.0cm and composed of large but discrete lymph nodes. Microscopy showed lymphoid tissue with extensive "geographic" areas of necrosis, obliterating their normal architecture. There was presence of narrow bands of macrophages at the margin giving granulomatous appearance. Elsewhere in the areas showing early necrosis, lymphoid follicles were replaced by apoptotic debris. Such are features suggestive of KFD. Staining for bacteria and fungi were negative. However the Epstein- Barr Virus (EBV) stain was positive and so was the serology for EBV. A review of the patients six weeks following the surgery was unremarkable and hence was discharged from our care.

DISCUSSION

In 1972, Kikuchi and Fujimoto, independently, described necrotising cervical lymphadenitis with

focal proliferation of reticular cells accompanied by numerous histiocytes and extensive nuclear debris. This condition is being increasingly recognised as an important cause of lymphadenopathy worldwide.^{1,2} It occurs commonly in young adults aged 20-30, with localised lymphadenopathy associated with leukopenia and fever, which is usually self- limiting.³

Previously, KFD was reported to affect more women than men and predominantly seen in East-Asian patients. Lately, more cases have been reported suggesting that the actual ratio of male to female is 1:1, with no racial predilection.^{3,4} Although the actual aetiology of this condition is unknown, KFD is seen in association with variety of neoplastic, infectious and autoimmune conditions. Pathogens that are thought to cause KFD are Human Herpes Viruses 6 and 8, Herpes Simplex Virus, Adenovirus, Parvovirus B19, Epstein Barr Virus, Cytomegalovirus, Varicella Zoster virus, Dengue Virus, *M. azulgia*, *Yersinia* sp. and protozoa.² The clinical presentation and laboratory findings seen in KFD overlap notable with lymphoma, both Hodgkin's and non-Hodgkin's lymphomas, where foci of necrosis may be present within lymph nodes.¹⁸ There have been many reports of KFD occurring in conjunction with systemic lupus erythematosus (SLE). SLE too can have lymphadenitis characterised by prominent foci of necrosis. Differential diagnoses also include sarcoidosis, plasmacytoid T-cell leukaemia, Kawasaki disease, tuberculosis and nodal metastases from adenocarcinoma.

Symptoms and signs can vary widely and this condition can easily be misdiagnosed. Cardinal symptoms are usually that of a flu; 30-50% of patients present with fever, night sweats, headache, arthralgia, myalgia, sore throat; other less frequent symptoms include weight loss, nausea, vomiting, abdominal pain.^{5,6} Cervical lymphadenopathy is a common presentation, which involves posterior cervical triangle lymph nodes in 80% of patients, which is usually unilateral.⁷ Less commonly affected lymph nodes are the axillary, mediastinal, coeliac, mesenteric, and inguinal lymph nodes, which are painless or minimally tender.⁸ Systemic symptoms are as a result of extranodal disease and signs include rash, hepatosplenomegaly, and neurological signs.⁵

The involvement of the mesenteric lymph nodes as occurred in our case is uncommon. It can sometimes be difficult to come to a diagnosis clinically and as a result patients have taken an operative route, as in our case. Laparotomy was performed in 11 cases^{9,-17,24,25}; majority for possible appendicitis.

Investigating patients with possible KFD can be challenging. Blood tests are usually non-specific

and inconclusive. Occasionally, there may be slight thrombocytopenia, neutropenia with lymphocytosis and elevation of erythrocyte sedimentation rate (ESR) or CRP. Computerised tomography and magnetic resonance scans do not show characteristic features of specific lymphadenopathies, but may mimic lymphoma and other nodal diseases with necrosis including metastasis and tuberculosis. Miller et al. had looked into cross-sectional imaging of KFD using CT and MR scans which showed that small clustered lymph nodes, which may be characteristic of this condition.¹⁹ For definite confirmation of the diagnosis, a histopathological examination of the lymph node is imperative. Fine needle aspiration cytology (FNAC) has been shown to be a useful method in diagnosing KFD, although the overall diagnostic accuracy of FNAC has been estimated to be 56.3% and may lead to misdiagnosis. Therefore excision lymph node biopsy is recommended if diagnosis is unclear.²⁰ A full blood test including immunological screen, chest x-ray, ultrasound scan of the abdomen or CT scan may help to exclude other conditions.

Microscopic examination of the lymph node shows uneven paracortical areas of coagulative necrosis with karyorrhectic debris. There is distortion of the nodal architecture and large numbers of different types of histiocytes at the margin of the necrotic areas. Thrombosed vessels are seen around the areas of necrosis. The karyorrhectic foci are formed by histiocytes and plasmacytoid cells and lymphocytes. A common finding is the absence of neutrophils and plasma cells.²¹ Immunohistochemical study shows a predominance of T cells, both CD8⁺ and CD4⁺, and some B cells.

KFD is usually self-limiting with spontaneous resolution of symptoms with recovery within 1 to 4 months. There is no specific treatment of KFD; however, symptom control with analgesics is adequate in majority of cases. Severe cases may require treatment with steroids and immunosuppressants.²² Recurrence of the disease has been reported in approximately 4% of cases.⁴ Mortality is rare, but can occur due to cardiac, hepatic or respiratory failure.²³

In summary, KFD involving the mesenteric lymph nodes is a rare condition and may mimic acute appendicitis, where preoperative diagnosis can be challenging and in a case like ours, there are no alternatives to laparotomy and resection of the affected intestine in order to establish the diagnosis and exclusion of a malignant lesion.

REFERENCES

1. Kikuchi M. Lymphadenitis showing focal reticulum cell hyperplasia with nuclear debris and phagocytes: a clinicopathological study. *Acta Hematol Jpn.* 1972;35:379-80.
2. Dorfman RF, Berry GJ. Kikuchi's histiocytic necrotizing lymphadenitis: An analysis of 108 cases with emphasis on differential diagnosis. *Semin Diag Pathol.* 1988;5:329-45.
3. Lin HC, Su CY, Huang CC *et al.* Kikuchi's disease: a review and analysis of 61 cases. *Otolaryngol Head Neck Surg.* 2003;128:650-53.
4. Kuo T. Kikuchi's disease (histiocytic necrotizing lymphadenitis): a clinicopathologic study of 79 cases with an analysis of histologic subtypes, immunohistology, and DNA ploidy. *Am J Surg Pathol.* 1995;19:798-809.
5. Fitzsimmons PR, Akpan A, Michael B. Kikuchi-Fukimoto disease as a rare cause of fever of unknown origin in septuagenarian. *Age and aging.* Oxford. 2008;37(2):233-4.
6. Bosch X, Guilabert A, Miquel R *et al.* E enigmatic Kikuchi-Fujimoto disease: a comprehensive review. *Am J Clin Pathol.* 2004;122:14-52.
7. Garcia CE, Girdhar-Gopal HV, Dorfman DM. Kiku-chi-Fujimoto disease of the neck, Update. *Ann Otol Rhinol Laryngol.* 1993;102:11-5.
8. Turner RR, Martin J, Dorfman RF. Necrotizing lymphadenitis: a study of 30 cases. *Am J Surg Pathol.* 1983;7:115-23.
9. Min KW, Jang KS, Jang HS *et al.* Kikuchi's disease of the mesenteric lymph nodes presenting as acute appendicitis. *The Korean J of Pathology.* 2007;41:44-6.
10. McLoughlin J, Creagh T, Taylor A *et al.* Kikuchi's disease simulating acute appendicitis. *Br J Surg.* 1988;75:1206.
11. Rudin C, Wernli R, Rutishauser M, Ohnacker H. Mesenteriac histiocytic necrotizing lymphadenitis. *Helv Paediatr Acta.* 1987 Jun;42(1):35-40.
12. Yabe H, Sinzato I, Hashimoto K. Necrotizing lymphadenitis presenting as mesenteric lymphadenopathy. *Rinsho Ketsueki.* 1999 Aug;40(8):658-62.
13. Forouhar F, Rustagi T, Lamea L. Eosinophilic venulitis of colon presenting as ileocecal mass. *Ann Clin Lab Sci.* 2011;41(4):373-8.
14. Suda H, Itoh S, Saigusa Y, Hirahata K, Nemoto Y, Sato K *et al.* A case of histiocytic necrotizing lymphadenitis showing focal lymph nodes swelling in the abdomen. *Nihon Shokakibyo Gakkai Zasshi.* 2007 Apr;104(4):579-83.
15. González-Ballester D, Blanco-Fernández G, Tejero-García M. Kikuchi-Fujimoto, abdominal tumour as atypical location. *Rev Esp Enferm Dig.* 2010 Jul;102(7):455-7.
16. Zhang MJ, Xiao L, Zhu YH, Jiang JJ, Jiang MS, He W. Lymph node uptake of 18F-fluorodeoxyglucose detected with positron emission tomography/computed tomography mimicking malignant lymphoma in a patient with Kikuchi disease. *Clin Lymphoma Myeloma Leuk.* 2010 Dec;10(6):477-9.
17. R Vijayaraghavan, R Chandrashekar, Saraswathi A, CS Belagavi. Kikuchi-Fujimoto's disease involving mesenteric nodes: a report and review of literature. Available from: URL:<http://casereports.bmj.com/content/2011/bcr.10.2011.4945.full.pdf+html>
18. Dorfman RF, Warnke R. Lymphadenopathy simulating the malignant lymphomas. *Hum Pathol.* 1974;5:519-50.
19. Miller WT Jr, Perez-Jafee LA. Cross-sectional imaging of Kikuchi disease. *J Comput Assist Tomogr.* 1999 Jul-Aug;23(4):548-51.
20. Tong TR, Chan OW, Lee KC. Diagnosing Kikuchi disease on fine needle aspiration biopsy: a retrospective study of 44 cases diagnosed by cytology and 8 by histopathology. *Acta Cytol.* 2001 Nov-Dec;45(6):953-7.
21. Blanco Fernandez G, Esteban Dura E, Blesa Sanchez E. Kikuchi-Fukimoto disease in the inguinal region. *An Eso Pediatr.* 2002;56(2):193-4.
22. Mannarà GM, Boccato P, Rinaldo A, La Rosa F, Ferlito A. Histiocytic necrotizing lymphadenitis (Kikuchi-Fujimoto disease) diagnosed by fine needle aspiration biopsy. *ORL J Otorhinolaryngol Relat Spec.* 1999 Nov-Dec;61(6):367-71.
23. Chan JK, Wong KC, Ng CS. A fatal case of multicentric Kikuchi's histiocytic necrotizing lymphadenitis. *Cancer.* 1989;63:1856-62.
24. Van Rij S, Wright DM. Kikuchi-Fujimoto's disease mimicking acute appendicitis. *ANZ J Surg.* 2010 Oct;80(10):760-1
25. Kita Y, Kikuchi M *et al.* A case of Kikuchi's disease with abdominal manifestations. *Surgery.* 1997 Nov;122(5):962-3.