

Endoscopic dacryocystorhinostomy: our experience and literature review

Dacriocistorrinostomia endoscópica: nossa experiência e revisão de literatura

Francis Vinícius Fontes de Lima¹, Mariane Barreto Brandão Martins¹, Eduardo Passos Fiel de Jesus², Arlete Cristina Granizo Santos², Valéria Maria Prado Barreto², Ronaldo Carvalho Santos Júnior³

ABSTRACT

Objective: To present our experience in endoscopic dacryocystorhinostomy, discussing the results with those found in the literature. **Methods:** The material in this study consisted of sixteen surgeries performed in twelve patients followed between 2009 to 2011. We analyzed gender, age at surgery, etiology of dacryocystitis, clinical features, number of surgeries required to repair, follow-up. **Results:** There was a predominance of females compared to males (5:1) aged between 8 and 71 years, mean 35.2 years. With regard to etiology, eight were classified as idiopathic, three, posttraumatic, and one, iatrogenic. Patients were followed on average over the period of six months, with improvement of symptoms. Only two patients had persistence of epiphora, one being reoperated successfully by external approach. **Conclusion:** Endoscopic endonasal surgery should be considered in patients with lacrimal obstruction, due to its high success rate, besides being safe procedure with less morbidity and give better cosmetic results.

Keywords: Dacryocystorhinostomy/methods; Dacryocystitis; Natural orifice endoscopic surgery; Lacrimal apparatus; Lacrimal apparatus diseases

RESUMO

Objetivo: Apresentar nossa experiência em dacriocistorrinostomia endoscópica, discutindo os resultados com os encontrados na literatura. **Métodos:** O material desse estudo consistiu de 16 dacriocistorrinostomias realizadas em 12 pacientes acompanhados no período de 2009 a 2011. Analisamos sexo, idade no momento da cirurgia, etiologia da dacriocistite, quadro clínico, número de cirurgias necessárias para a correção, seguimento pós-operatório. **Resultados:** Houve predomínio do sexo feminino em relação ao masculino (5:1) com idades entre 8 e 71 anos, com média de 35,2 anos. Com relação à etiologia, oito foram classificados como idiopáticos; três, pós-traumáticos e um iatrogênico. Os pacientes foram acompanhados em média durante o período de seis meses, com melhora dos sintomas. Apenas dois pacientes evoluíram com permanência de epífora, sendo um deles reoperado com êxito por via externa. **Conclusão:** A cirurgia endoscópica endonasal deve ser considerada nos pacientes com obstrução das vias lacrimais, devido ao seu alto índice de sucesso, além de ser um procedimento seguro, com menor morbidade e proporcionar melhor resultado estético.

Descritores: Dacriocistorrinostomia/métodos; Dacriocistite; Cirurgia endoscópica por orifício natural; Aparelho lacrimal; Doenças do aparelho lacrimal

¹ Physician, trainee at the Otorhinolaryngology Service, University Hospital of the Sergipe Federal University (UFS), Aracaju/SE, Brazil.

² Preceptor at the Otorhinolaryngology Service, University Hospital of the Sergipe Federal University (UFS), Aracaju/SE, Brazil.

³ Head of the Otorhinolaryngology Service, University Hospital of the Sergipe Federal University (UFS), Aracaju/SE, Brazil.

Work conducted at the Otorhinolaryngology Service, Federal University of Sergipe (UFS), Aracaju/SE, Brazil.

The authors declare no conflict of interest.

Received for publication: 18/7/2012 - Accepted for publication: 6/1/2013

INTRODUCTION

The first reference to endonasal surgery of the lacrimal sac was by an otorhinolaryngologist — Caldwell, in 1893. However, dacryocystorhinostomy (DCR) started to be performed by ophthalmologists since the technique using the external route was described by Toti in 1904. The endonasal route then practically fell into disuse until Heermann (1958), Prades (1970) and Rouvier (1981) described the use of a microscope for endonasal surgery, and endoscopic DCR was only described in 1988^(1,2).

Partial or complete obstruction of the lacrimal system produces constant or intermittent tearing called epiphora. This is a condition both ophthalmologists and otorhinolaryngologists encounter in clinical practice. There are several causes of obstruction, such as trauma, infections, neoplasms, or systemic diseases, although the vast majority of cases is due to idiopathic inflammation⁽³⁾.

Patients most commonly present with ocular complaints, such as epiphora, recurrent infections of the lacrimal sac, chronic and persistent drainage of purulent secretion through the lacrimal puncta, and cutaneous fistula⁽⁴⁾.

The aim of this work is to present our experience with endoscopic dacryocystorhinostomy at the Otorhinolaryngology Service of the University Hospital of the Federal University of Sergipe (UFS), comparing and discussing our results with those found in the literature and assessing its effectiveness.

METHODS

This was a historical cohort study based on retrospective review of the medical charts of 12 patients submitted to endoscopic DCR. The study subjects were admitted to the Otorhinolaryngology Service of the University Hospital of UFS between December 2009 and November 2011. Of the 12 patients studied, four underwent bilateral surgery, totalling 16 procedures. The study was approved by Ethics Committee for Research on Human Beings of UFS under protocol number 0205.0.107.000-11 and participants gave their Free and Informed Consent. Study variables included sex, age at surgery, aetiology of dacryocystitis, clinical presentation, number of procedures needed for correction, and postoperative follow-up.

Inclusion criteria were lower lacrimal sac obstruction diagnosed in our service, with a lacrimal sac of normal or increased size.

Exclusion criteria were upper obstruction (puncta, superior, inferior or common canaliculi), functional obstruction (patent lacrimal system, but with lacrimal pump failure), and acute obstruction.

Patients were seen at the Ophthalmology Service, where they underwent the Jones test (primary and secondary), the fluorescein test, and the Schirmer test.

All patients were evaluated with nasal endoscopy and CT scan of the paranasal sinuses.

Dacryotomography, scintigraphy, and dacryocystography are useful to demonstrate the level of the obstruction⁽⁵⁾. In our study, however, we performed only a CT scan to rule out sinonasal conditions that could be causing the chronic dacryocystitis.

The surgical procedure was similar in all patients. All procedures were performed by the same surgeon under general anaesthesia, providing greater comfort to the patient and allowing

us to perform additional procedures if necessary. Topical vasoconstriction of the nasal cavity was done with a solution of 2% lidocaine with epinephrine 1:2000. A 4mm, 0 degree endoscope (Hopkins-Karl Storz) was used in the procedure. The lacrimal sac was located according to anatomical criteria, based on the projection of the lacrimal sac at the inner corner of the orbit, using a bayonet forceps (Figure 1).

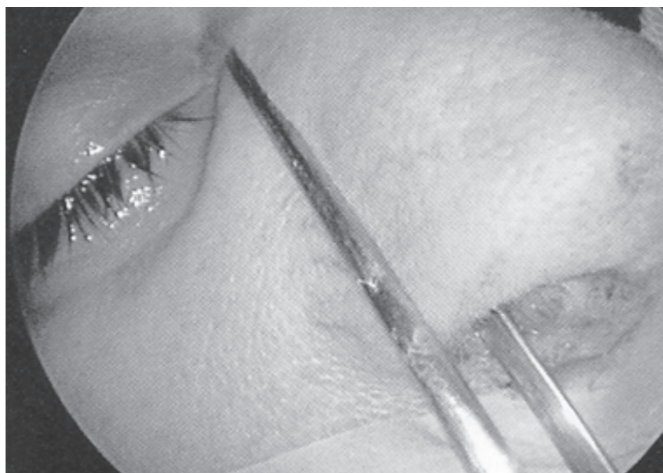


Figure 1: Projection of the lacrimal sac in the inner corner of the orbit with a bayonet forceps.

A mucosal flap was created endoscopically, with its posterior base adjacent to the middle nasal concha using a sickle knife, an electrocautery, and an aspirator-detacher. The flap was positioned posteriorly during the procedure, protecting the anterior insertion of the middle nasal concha from possible trauma. After exposing the lacrimal bone and the frontal process of the maxilla, we created an anterior window to expose the width of the lacrimal sac. The osteotomy was made with a diamond bur.

The lacrimal sac was identified using a probe (Bowman), which entered the sac through the canaliculus, pushing it medially. The entire medial wall of the lacrimal sac was removed. Finally, we repositioned the previously-made mucosal flap, covering the posterior region of lacrimal sac's opening in order to promote healing by primary intention, thus avoiding bone exposure and reducing granuloma formation and restenosis of the dacryocystorhinostomy site.

A nylon 0 suture was passed through the superior and inferior canaliculi to the nasal cavity and fixed with a knot to maintain the orifice between the lacrimal system and the nasal cavity.

Postoperative pain was successfully managed with intravenous non-steroidal anti-inflammatory and analgesic agents, as endoscopic surgery causes mild pain.

Postoperative medication included oral antibiotics for 14 days, corticosteroid nasal spray during the first month, and weekly washing with saline for six months. Systemic corticosteroids were administered only in the immediate postoperative period.

Cases were followed-up for a period ranging from four months to one year.

RESULTS

Most patients were female (5 females, 1 male), with a mean age of 35.2 years (range, 8 to 71 years).

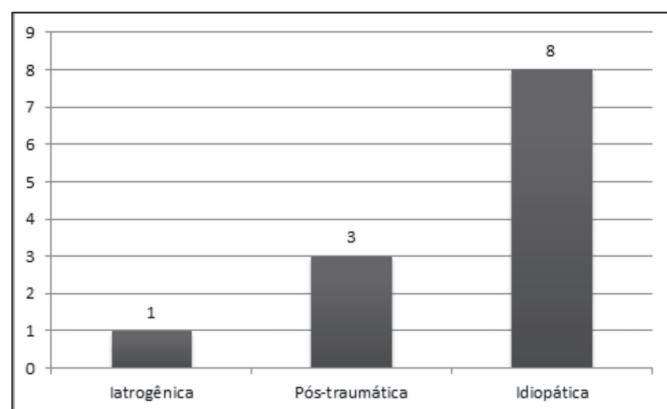


Figure 2: Aetiologies of dacryocystitis.

Figure 2 shows the aetiologies of dacryocystitis in the study subjects.

With regard to clinical presentation, epiphora was present in all patients. Purulent secretion was present in five patients, who also had dilatation of the lacrimal sac.

Total remission of symptoms was achieved in 87.5% of procedures (14 procedures in 10 patients). Only one patient, whose dacryocystitis was unilateral, reported only partial improvement and persisted with some degree of tearing, although the lacrimal system was patent on washing. However, one patient with unilateral dacryocystitis of post-traumatic aetiology with multiple facial fractures showed a persistence of symptoms and was successfully reoperated using the external route. This patient probably had involvement of the canaliculi which had not been detected in the initial assessment for endonasal surgery. There were no intraoperative complications. The patient showed partial improvement of symptoms and claimed to be satisfied with the postoperative result, not wishing a new intervention.

Patients were followed-up for 6 months on average, always with endoscopic control. Removal of crusts and intranasal synechiae was done 10 and 30 days after surgery. The nylon suture was removed 30 days after surgery. Subsequently, patients underwent monthly nasal endoscopy until complete healing and clinical improvement.

DISCUSSION

Nasolacrimal duct obstruction can have different aetiologies. Idiopathic obstruction is the most common; others include infectious, post-surgical, and traumatic obstruction. In our study, 62.5% of cases were idiopathic, in agreement with the literature. Obstruction of the lacrimal system can occur at any point along its path, being classified for surgical purposes as pre-saccul (obstruction of puncta, superior, inferior, and/or common canaliculi); saccul; or post-saccul (nasolacrimal duct). Thus, knowing the anatomy of the lacrimal system is essential to understand the conditions affecting the system and for diagnostic and therapeutic procedures⁽⁶⁾.

Suspected obstruction can be confirmed by several tests, such as the Jones test (primary and secondary), the fluorescein test, and the Schirmer test. In daily practice, however, the most used tests are dacryoscintigraphy, dacryocystography and dacryotomography, which help predict the surgical prognosis depending on the contrast pattern of the lacrimal sac^(6,7).

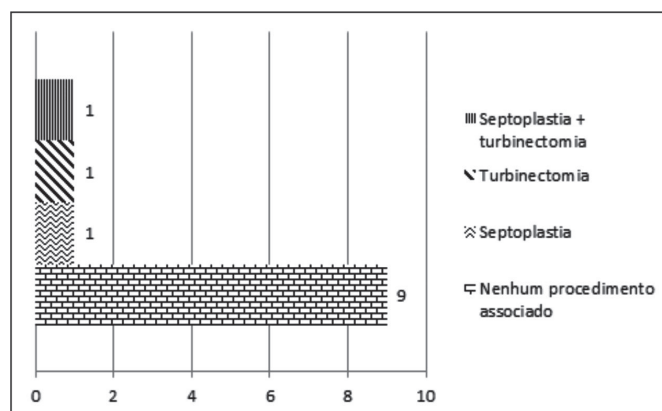


Figure 3: Number of patients requiring an associated surgical procedure during endoscopic dacryocystorhinostomy.

Dacryocystorhinostomy has been the treatment of choice for cases of distal obstruction of the lacrimal system (below the common canaliculus). The procedure consists in creating a communication between the lacrimal sac and the nasal cavity, allowing drainage of tears and therefore relieving symptoms^(6,7).

The traditional treatment of nasolacrimal duct obstruction is external dacryocystorhinostomy, often performed by ophthalmologists. However, technological innovations and less invasive procedures on the lacrimal system have been developed, with reduced morbidity and improved results^(6,7).

The endonasal approach was first described by Caldwell in 1893, but it was forgotten for decades due to the limited capacity to visualise and assess the sinonasal anatomy. The introduction of microscopes and endoscopic techniques, associated with the close relationship of the lacrimal system and the nasal cavity, made endonasal surgical treatment of lower lacrimal disorders very popular among otorhinolaryngologists^(2,7,8). Currently, endoscopic dacryocystorhinostomy is a well-established technique in the treatment of nasolacrimal duct and sac obstruction⁽⁸⁻¹⁰⁾, and it is essential for otorhinolaryngologists to master the technique. The procedure can also be used in situations such as nasal conditions (septal deviation, polyps, adhesions and synechiae, narrow nasal cavity, and fractures) which could make surgery more difficult⁽¹¹⁾.

Careful preoperative evaluation is needed for a good result, including a medical history to assess the clinical picture (epiphora, dilation of the lacrimal sac, purulent discharge, ocular pain); preoperative nasal endoscopy to determine the diagnosis and to identify factors that could potentially hinder surgery (sinusitis, septal deviation, synechiae); and computed tomography of the paranasal sinuses to assess the overall condition of the nasal cavity and paranasal sinuses and thus plan the surgical procedure.

The aim of dacryocystorhinostomy is to provide adequate drainage of tear flow toward the intranasal region. This can be achieved efficiently through the external or endonasal route⁽¹²⁾. With the endonasal approach it is easier to correct conditions that might compromise the outcome, such as septal deviation and synechiae; the method therefore adapts very well to endonasal anatomical changes. In our study, only 3 patients required an associated surgical procedure (Figure 3).

The endoscopic technique has been increasingly used. It has a number of advantages compared to the external technique: optimal visualisation of the surgical field during the whole procedure; less surgical trauma leading to a lower rate of postoperative complications; no skin incisions; no scar retraction due to external dissection; and preservation of the palpebral

Table 1**Comparison of the success rates of endoscopic DCR in different studies.**

Authors	Year	Number of eyes	Success rate(%)
Yang et al. ⁽¹⁷⁾	1998	150	90
Cokkeser et al. ⁽⁷⁾	2000	51	88,2
Sham et al. ⁽¹⁸⁾	2000	17	88
Araujo Filho et al. ⁽²⁾	2004	17	82,3
Küpper et al. ⁽⁶⁾	2004	32	79,12
Ben Simon et al. ⁽¹⁹⁾	2005	176	76,7
Lima et al.	2012	16	87,5

ligaments and structures of the medial corner of the orbit, thus maintaining the physiological mechanisms of the lacrimal pump⁽¹³⁻¹⁵⁾.

According to Cokkeser, dacryocystorhinostomy is successful in 70% to 95%⁽⁷⁾ of cases, depending on a number of factors. This is consistent with findings in our study, where a success rate of 87.5% was achieved (Table 1). Although the Toti technique, in experienced hands, has a similar success rate (up to 90%)⁽¹⁶⁾, dacryocystorhinostomy has the advantage of being less invasive and providing better cosmetic results, as it does not involve skin incisions. We believe that even higher success rates can be achieved with the endoscopic technique, but the number of cases seen in our service is relatively small.

CONCLUSION

Our study found a high success rate for endoscopic DCR, in accordance with the literature. Although Toti technique shows similar results, endoscopic endonasal surgery should be considered in patients with obstruction of the lacrimal system due to its high success rate and the fact that it is a safe procedure, associated with lower morbidity and better aesthetic results.

REFERENCES

- Rice DH. Endoscopic intranasal dacryocystorhinostomy: a cadaver study. *Am J Rhinol.* 1988;2(3):127-8.
- Araujo Filho BC, Voegels RL, Butugan O, Pinheiro Neto CD, Lessa MM. Dacriocistorrinostomia endoscópica. *Rev Bras Otorrinolaringol.* 2005;71(6):721-5.
- Ilgit ET, Onal B, Coskun B. Interventional radiology in the lacrimal drainage system. *Eur J Radiol.* 2005;55(3):331-9. Review.
- Lunardelli P, Aoki L, Jervasio AC, Zagui RM, Matayoshi S. Implante de ducto nasolacrimal de poliuretano: relato de caso. *Arq Bras Oftalmol.* 2008;71(1):110-4.
- Iturralde PP, Reis FO, Oliveira RA, Cahali M, Voegels RL. Resultados da técnica cirúrgica endoscópica endonasal para dacriocistorrinostomia. *Rev Bras Otorrinolaringol.* 2001;67(4 Pt 1):527-9.
- Küpper DS, Demarco RC, Resende R, Anselmo-Lima WT, Valera FC, Moribe I. Dacriocistorrinostomia endoscópica nasal: resultados e vantagens sobre a abordagem externa. *Rev Bras Otorrinolaringol.* 2005;71(3):356-60.
- Cokkeser Y, Evereklioglu C, Er H. Comparative external versus endoscopic dacryocystorhinostomy: results in 115 patients (130 eyes). *Otolaryngol Head Neck Surg.* 2000;123(4):488-91.
- Cunningham MJ, Woog JJ. Endonasal endoscopic dacryocystorhinostomy in children. *Arch Otolaryngol Head Neck Surg.* 1998;124(3):328-33.
- Onerci M. Dacryocystorhinostomy. Diagnosis and treatment of nasolacrimal canal obstructions. *Rhinology.* 2002;40(2):49-65. Review.
- Barnes EA, Abou-Rayyah Y, Rose GE. Pediatric dacryocystorhinostomy for nasolacrimal duct obstruction. *Ophthalmology.* 2001;108(9):1562-4. *Comment in Ophthalmology.* 2002;109(9):1587-8; *author reply 1588.*
- Knijnik D. Analisando a dacriocistorrinostomia endoscópica: dificuldades e soluções. *Arq Bras Oftalmol.* 2007;70(3):391-4.
- Metson R. Endoscopic surgery for lacrimal obstruction. *Otolaryngol Head Neck Surg.* 1991;104(4):473-9.
- Schauss F, Weber R, Draf W, Keerl R. Surgery of the lacrimal system. *Acta Otorhinolaryngol Belg.* 1996;50(2):143-6. Review.
- Ricardo LA, Nakanishi M, Fava AS. Estudo da anatomia endoscópica da fossa lacrimal guiado por transiluminação. *Braz J Otorhinolaryngol.* 2010;76(1):34-39.
- Voegels RL, Cahali M, Matayoshi S, Butugan O, Miniti A. Dacriocistorrinostomia endonasal. *Braz J Otorhinolaryngol.* 1999;65(1):44-7.
- Dresner SC, Klussman KG, Meyer DR, Linberg JV. Outpatient dacryocystorhinostomy. *Ophthalmic Surg.* 1991;22(4):222-4. *Comment in Ophthalmic Surg.* 1991;22(8):481.
- Yang MW, Hardman-Lea S. Endoscopic inferior dacryocystorhinostomy. *Clin Otolaryngol Allied Sci.* 1998;23(2):152-7. *Comment in Clin Otolaryngol Allied Sci.* 1999;24(1):80-1.
- Sham CL, van Hasselt CA. Endoscopic terminal dacryocystorhinostomy. *Laryngoscope.* 2000;110(6):1045-9.
- Ben Simon GJ, Joseph J, Lee S, Schwarcz RM, McCann JD, Goldberg RA. External versus endoscopic dacryocystorhinostomy for acquired nasolacrimal duct obstruction in a tertiary referral center. *Ophthalmology.* 2005;112(8):1463-8.

Corresponding author:

Francis Vinícius Fontes de Lima¹
Alameda B, 303, Edf. Geranium – Grageru, Aracaju (SE), Brazil.
CEP: 49027-400. Fax: (79) 3211-4576.
E-mail: francisvinicius@hotmail.com.