

Head positioning for anterior circulation aneurysms microsurgery

Posicionamento da cabeça para microcirurgias de aneurismas da circulação anterior

Feres Chaddad-Neto^{1,2,3}, Hugo Leonardo Doria-Netto^{2,3,4}, José Maria de Campos-Filho^{2,3}, Eduardo Santamaria Carvalho Ribas⁵, Guilherme Carvalho Ribas^{6,7}, Evandro de Oliveira^{2,8}

ABSTRACT

Objective: To study the ideal patient's head positioning for the anterior circulation aneurysms microsurgery. **Method:** We divided the study in two parts. Firstly, 10 fresh cadaveric heads were positioned and dissected in order to ideally expose the anterior circulation aneurysm sites. Afterwards, 110 patients were submitted to anterior circulation aneurysms microsurgery. During the surgery, the patient's head was positioned accordingly to the aneurysm location and the results from the cadaveric study. The effectiveness of the position was noted. **Results:** We could determine mainly two patterns for head positioning for the anterior circulation aneurysms. **Conclusion:** The best surgical exposure is related to specific head positions. The proper angle of microscopic view may minimize neurovascular injury and brain retraction.

Keywords: cerebral aneurysm, head positioning, anatomical landmarks, anterior circulation arteries, microsurgery.

RESUMO

Objetivo: Estudar o posicionamento da cabeça para a cirurgia de aneurismas cerebrais da circulação anterior. **Método:** Dividimos o estudo em duas partes. Inicialmente, dez cabeças de cadáveres frescos foram posicionadas e dissecadas de modo a expor, de maneira ideal, os principais sítios de aneurismas na circulação anterior do cérebro. Posteriormente, 110 pacientes foram submetidos a microcirurgia para clipagem de aneurismas cerebrais da circulação anterior. Durante as cirurgias, as cabeças foram posicionadas de acordo com a localização específica de cada aneurisma e o resultado obtido no estudo dos cadáveres. Cada paciente teve sua posição avaliada quanto a sua eficácia. **Resultados:** Obtivemos basicamente dois padrões de posicionamento da cabeça para cirurgias de aneurismas cerebrais da circulação anterior. **Conclusão:** A melhor exposição cirúrgica está relacionada à posição específica da cabeça para cada localização aneurismática. O ângulo de visão microscópica adequado minimiza lesões neurovasculares e a excessiva retração cerebral.

Palavras-chave: aneurisma cerebral, posicionamento da cabeça, reparos anatômicos, artérias da circulação anterior, microcirurgia.

Aneurysms of the internal carotid artery and its branches are approached in their vast majority by the classic pterional craniotomy, using transylvian and subfrontal routes¹. The neurosurgeon's visualization of deep arterial and nervous structures can be influenced importantly by the patient's head position^{2,3}, which should provide the temporal and frontal lobes to be ideally side-by-side and avoid them to overlap. It also affects the exposure of the anterior clinoid process and the view along the orbital roof^{2,4,5}.

In 1976, Yasargil described the positioning of the head for aneurysms of the anterior circulation but did not report the reason for each angle degree of rotation and extension⁶. Several authors have also published their experiences with anterior circulation aneurysms, but with different degrees of rotation and head tilt^{7,8}. The pterional craniotomy is used for most of these aneurysms, but a correction of the patient's head position by moving the operating table is often required during surgery, a maneuver that should be avoided

¹Departamento de Neurocirurgia Vascular, Universidade Federal de São Paulo, São Paulo SP, Brazil;

²Laboratório de Microcirurgia, Instituto de Ciências Neurológicas, Real e Benemérita Associação Portuguesa de Beneficência, São Paulo SP, Brazil;

³Departamento de Neurocirurgia Vascular, Sociedade Brasileira de Neurocirurgia, São Paulo SP, Brazil;

⁴Departamento de Neurocirurgia Vascular, Hospital Brigadeiro, São Paulo SP, Brazil;

⁵Departamento de Neurocirurgia, Hospital das Clínicas, Faculdade de Medicina, Universidade de São Paulo, São Paulo SP, Brazil;

⁶Departamento de Cirurgia – LIM02, Faculdade de Medicina, Universidade de São Paulo, São Paulo SP, Brazil;

⁷Hospital Beneficência Portuguesa, São Paulo SP, Brazil;

⁸Departamento de Neurologia, Faculdade de Ciências Médicas, Universidade Estadual de Campinas, Campinas SP, Brazil.

Correspondence: Hugo Leonardo Dória-Netto; Praça Amadeu Amaral, 27 - 5º andar; 01327-010 São Paulo SP, Brazil; E-mail: hldoria@hotmail.com

Conflict of interest: There is no conflict of interest to declare.

Received 04 February 2014; Received in final form 04 July 2014; Accepted 24 July 2014.

as much as possible. The determination of the optimal placement of the head can optimize the better exposure of important vascular and neural structures, provide less brain retraction, and lead to safer surgeries.

Our objective is to determine the best patient's head positioning for the better exposure and clipping of the most common aneurysms of the internal carotid artery and its branches.

METHOD

The study was conducted in two parts:

First part – anatomic study on cadaveric specimens

Ten fresh cadaveric heads without evidence of previous neurological lesions were dissected at the Death Verification Institute of the University of Sao Paulo Medical School, according to ethical issues previously determined. A three-pin Mayfield device was used to hold the heads in a dissection table and a VasconcelosDF900[®] microscope was utilized. All dissections were carried out until identification of the internal carotid artery (ICA) and its branches, of the anterior clinoid process (ACP) and of the optic nerves (ON) (Figure 1).

In each of the 20 dissected sylvian fissures, the heads were placed at the ideal rotation and extension for the best microsurgical exposure for each common site of aneurysms of the anterior circulation: ophthalmic (OphS), posterior communicating (PCoS), and anterior choroidal (AChaS) segments of the ICA, ICA bifurcation, anterior communicating artery (ACoS) and middle cerebral artery (MCAS). The best positioning was the one considered to promote a microsurgical view perpendicular to each given aneurysm and parallel to its parental artery (Figure 2).

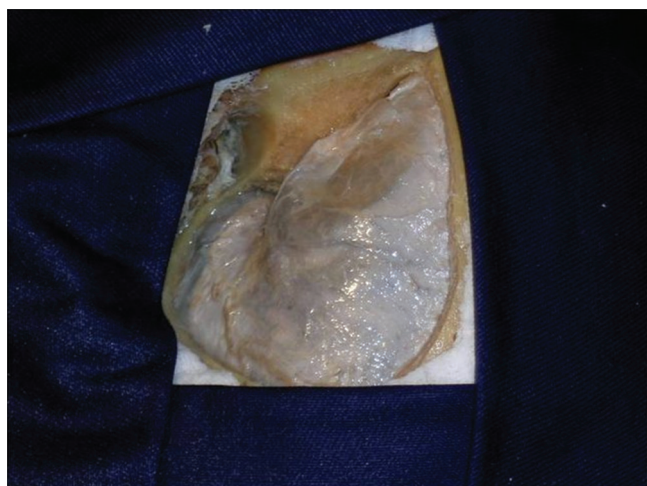

Figure 1. This picture presents a left pterional craniotomy in a cadaveric head impregnated with 10% formaldehyde.

Second part – clinical study

All patients admitted between January 2006 to December 2010 at the Department of Neurosurgery of Universidade Estadual de Campinas (UNICAMP) with unruptured cerebral aneurysm referred to surgical treatment by our neurosurgical staff were enrolled in this study. Patients who refused to participate were excluded.

The study has been approved by the UNICAMP ethics committee and has therefore been performed in accordance with the ethical standards laid down in the 1964 Declaration of Helsinki and its later amendments.

All persons gave their informed consent prior to their inclusion in the study.

Every patient was submitted to brain angiography study which confirmed the exact site of the aneurysm.

This study was done prospectively and was approved by our ethical committee.

For surgery, these patients were placed in dorsal position on a Mizuho operating table, and their heads were held by a Sugita device with 3 pins (Figure 3).

Depending on the location of the aneurysm, the patient's head was positioned accordingly to the amount of rotation and extension established in the first part of our study, which provided the best microsurgical exposure for each particular aneurysm site. If the neurosurgeon's angle of view to see the main artery and the neck of the aneurysm, and to perform its clipping, was appropriate without any change in the position of the operating table, the positioning of the head was considered as "appropriate". If any correction in the position of operating table had to be made, the positioning of the head was regarded as "inappropriate". Corrections in extension were made by lifting the table, and corrections in rotation were made by rotating the table. All patients were operated by the senior author. The microsurgery started always with the operative table at 50 cm above the floor level. The surgeon was seated on a Mizuho operative chair. The microscope used was a Zeiss S88 positioned at 25 cm distance from operative field (focus on 250 mm).

Exploratory data analysis was performed (mean, standard deviation, frequency, bar chart). A 95% confidence interval (Student t) was calculated for the means of the variables.

The confidence level considered in the analysis was 95%.

Statistical Software: XLSTAT 2012 for Windows.

Evaluation of the head's position

To evaluate the accurate position of the heads of the cadavers and patients, pictures were taken using a Canon Rebel XP EOS 350[®] Digital Camera with a Canon Macro EF[®] 100mm 1:2.8usm lens and a Canon Macro Ring Lite MR-14 EX[®] flash, mounted on a tripod with a geometric protractor device. The camera was positioned 120 cm behind the head and its screen

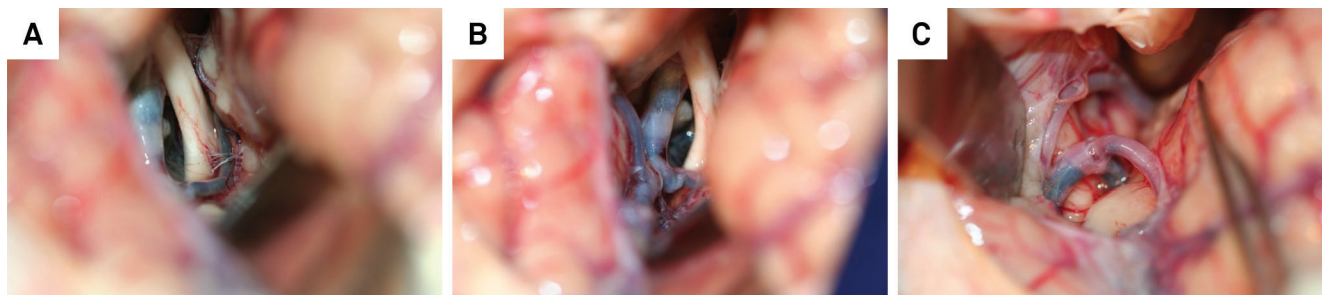

Figure 2. (A) This picture, from a fresh cadaveric study, shows a perfect microsurgical vision of optic nerve, supraclinoid ICA, PComm, ICA bifurcation and the entire A1 above optic nerve. this is a perfect microsurgical view to approach AComm complex aneurysms. the head was positioned in 13 degrees extention and with 7 degrees rotation. (B) This picture, from a fresh cadaveric specimen, shows a microsurgical wide vision of ICA bifurcation, exposing the entire ICA, the bifurcation zone and its main braches M1 and A1. this microscopic view is perfect for performing an ICA bifurcation aneurysm clipping. The head was positioned in a great extention of 15 degrees and a small rotation of 5 degrees. (C) This picture evidantiates a wide exposition of the entire M1 and MCA bifurcation. The microsurgical vision is perfect for performing a MCA aneurysm clipping, once we had specifically positioned the head in great extention and small rotation in a fresh cadaveric head.

displayed an orthogonal set of lines (Cartesian coordinates) (Figure 4).

First, two control pictures were taken with the patient's head in neutral position (without any rotation or extension - Figure 5). The picture taken from behind of the head was centered at the meeting point of the coronal and sagittal sutures (Bregma craniometric point), and the vertical screen line (Cartesian y-axis) was aligned to the sagittal line (connecting the Nasion to the Bregma); the protractor geometric device showed 0° of rotation in this picture (Figure 6).

The picture of the head's lateral view was centered at 2 cm right ahead of the tragus, and the camera was angled in order to align the vertical screen line with the zygomatic arch of the head; the protractor geometric device showed the extension angle of the head in neutral position.

After, the head was positioned as desired for the procedure and two other pictures were taken, from the same positions, centered at the same anatomic landmarks as the control

pictures, but changing the angle of the camera to re-align the vertical screen line (cartesian y-axis) with the anatomic lines already described. The protractor geometric device showed the new angles of the camera, and this data was noted (Figure 7).

The difference between the angles of both pictures taken from behind (control and after positioning) was regarded as the rotation angle of the head, and the difference between the angles of both pictures taken from lateral was regarded as the extension angle (Figure 8).

In every procedure, attention was noted to the position of fixed anatomic landmarks, in order to further correlate the relationships between external and internal anatomic landmarks. The external landmarks were represented by the superior orbital margin and by the malar eminence, and the internal landmarks by the anterior clinoid process, the optic nerve and the supraclinoid portion of internal carotid artery.

All surgeries were registered in video and photographed.

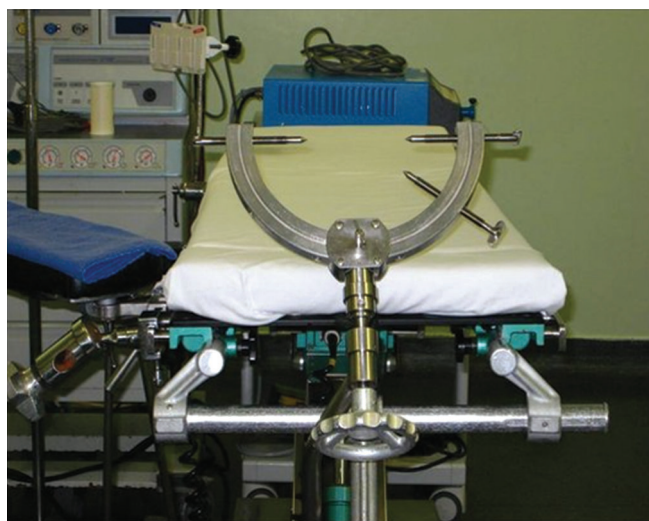

Figure 3. Mizuho neurosurgical table with the head support Sugita device.

RESULTS

First part – Anatomic study on cadaveric specimens

Ten cadaveric heads had their 20 cerebral hemispheres and 20 sylvian fissures dissected. As mentioned, they were




Figure 4. (A) This picture shows the camera supported by a tripod aligned to the floor plane. (B) The leveling device attached to the tripod.

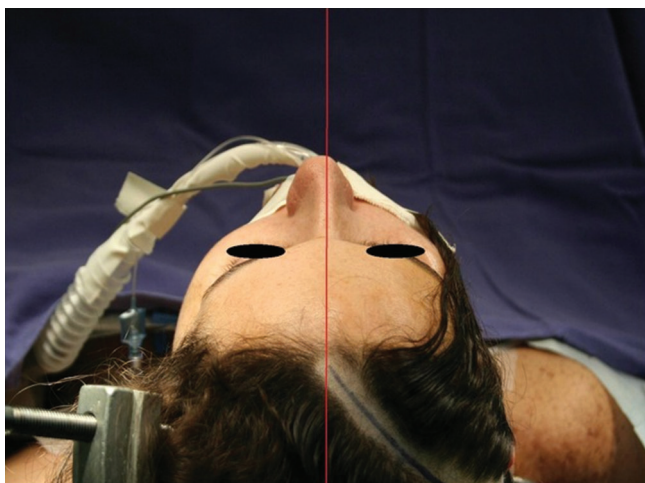


Figure 5. This picture shows the head in neutral position as a control parameter and in order to graduate the head's rotation angle, the abscissa "Y" axis on the camera screen was leveled with an imaginary sagittal-nasium line taken as the parameter for the median longitudinal center of the head.

positioned in order to promote the best microsurgical exposure for each common site of aneurysms of the anterior circulation.

The best exposure of the site where aneurysms usually arise along the ophthalmic segment of ICA was provided by a mean rotation of 15 degrees (range, 13-18) and by a mean extension of 1.5 degrees (range, 0-3). The posterior communicating artery site was better visualized with a mean rotation of 14.15 degrees (range, 10-18) and a mean extension of 4 degrees (range, 2-7). For the anterior choroidal artery site, the mean rotation was 13.05 degrees (range, 9-20) and the mean extension was 2.5 degrees (range, 1-6).

The better visualization of the ICA bifurcation site was provided by a mean rotation of 8 degrees (range, 6-10) and by a mean extension of 15 degrees (range, 9-20). For the anterior communicating artery site, a mean rotation of 7.05 degrees (range, 3-11) and a mean extension of 15 degrees (range, 12-17) were required. The middle cerebral artery site was

better exposed by a mean rotation of 7 degrees (range, 6-10) and by a mean extension of 14 degrees (range, 12-15) (Table 1).

Second part – Clinical study

110 patients (47 males and 63 females), with mean age of 53.2 years (between 18 and 74 years old), were enrolled to our study. They were all diagnosed harboring cerebral aneurysms, and all were referred to neurosurgical clipping by our staff (Table 2).

Patients were grouped as follows: 20 patients with an ophthalmic segment of ICA aneurysm, 20 with a posterior communicating segment aneurysm, 10 with a anterior choroidal segment, 20 with a ICA bifurcation aneurysm, 20 with a anterior communicating artery aneurysm and 20 with a middle cerebral artery aneurysm.

All our patients were operated through a traditional pterional craniotomy by the first author and all microsurgery time were performed by the senior author (Figure 9).

The position of the patient's head was initially set accordingly to the results of first part of our study (cadaveric study) for each aneurysm site. The evaluation if the positioning of the head was appropriate was noted in all cases as presented in Table 3.

Of the 20 patients with an ophthalmic segment of ICA aneurysm, 14 (70%) had a positioning of the head regarded as "appropriate", and in 6 (30%) the position of the table had to be corrected only along one axis (Figure 10).

Seventeen (85%) of the 20 patients with a posterior communicating segment of ICA aneurysm had an appropriate positioning, in two (10%) the position was inappropriate along only one axis, and in 1 (5%) it was inappropriate along both axis.

Most patients with an anterior choroidal segment of ICA aneurysm had an appropriate positioning (8 pts, 80%), one (10%) needed to have the table lifted during surgery, and one (10%) had its position inappropriate along both axis.

Most patients with an ICA bifurcation aneurysm (15 pts, 75%) had an appropriate head positioning. In one procedure (1 pt, 5%) the height of the operating table had to be changed,

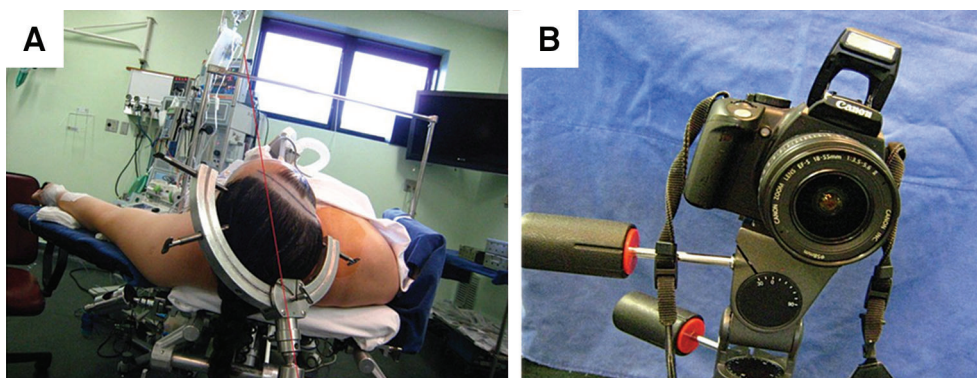


Figure 6. (A) This picture shows the head's rotation angle. (B) This picture shows the tripod angles for the camera's realignment obtained by a geometric protractor attached to the support.

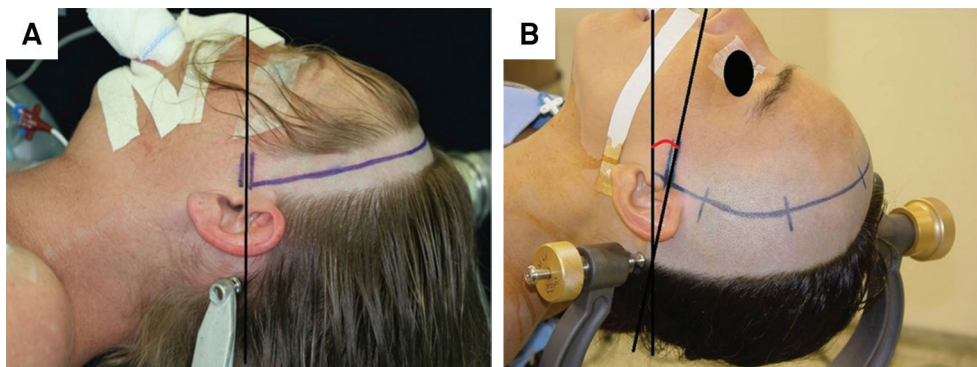


Figure 7. (A) This picture shows a head with the superior orbital margin and the malar eminence leveled in the same plane as an example of neutral extension. (B) This picture shows a head with the malar eminence positioned above the superior orbital margin as an example of extended position. The lines took as parameters to measure extended degree.

and in 4 procedures (4 pts, 20%) the table rotation was adjusted.

Thirteen patients (65%) with an aneurysm located at the anterior communicating segment of ACA were positioned appropriately, 3 patients (15%) had an inappropriate extension, and 4 patients (20%) had an inappropriate rotation.

Of the patients with a MCA aneurysm, 18 (90%) had an appropriate positioning, one patient (5%) needed an extension correction and one patient (5%) needed a rotation adjustment (Table 3).

Analyzing external and internal anatomic landmarks

External landmarks can be used as guides to extend the patient's head properly, and neutral extension corresponds to have the superior orbital margin at the same level of the malar eminence.

The best extension for the MCA, ACoS of ACA, and ICA bifurcation aneurysms is achieved when the malar eminence is at the highest level in relation to the rest of the patient's face.

In neutral extension, the anterior clinoid process was positioned perpendicularly to the ground plane and provided a wide vision of the lateral and superior walls of the ICA, allowed an easy drilling of the ACP's basal and lateral portions, and facilitated the exposure of aneurysms located at

the ophthalmic, posterior communicating and anterior choroidal segments of ICA.

There was a posterior inclination of the ACP after 10 degrees of extension, deepening of the ICA and of the optic nerves, with the ACP covering the neurosurgeon's microscopic angle of view. This position has not favored the approach to the aneurysms at the ophthalmic, posterior communicating and anterior choroidal ICA segments. This position was ideal for MCA, ACoS of ACA, and ICA bifurcation aneurysms.

With 15 degrees rotation, the ACP was perpendicular to the ground. This provides a better exposure of the lateral ICA wall, therefore, it is the ideal position to access the ophthalmic, PCoS and AChaS of ICA aneurysms. A slight rotation exposes the lateral ICA wall hardly. Hence, no rotation was appropriate to approach MCA, ACoS of ACA, and ICA bifurcation aneurysms.

DISCUSSION

Microsurgery for cerebral aneurysm always pose a potential risk for the patient. Joining a great knowledge of the neuro-vascular anatomy and experience, the surgeon may offer a safer and more effective treatment when an appropriate surgical technique is applied. In this direction, the

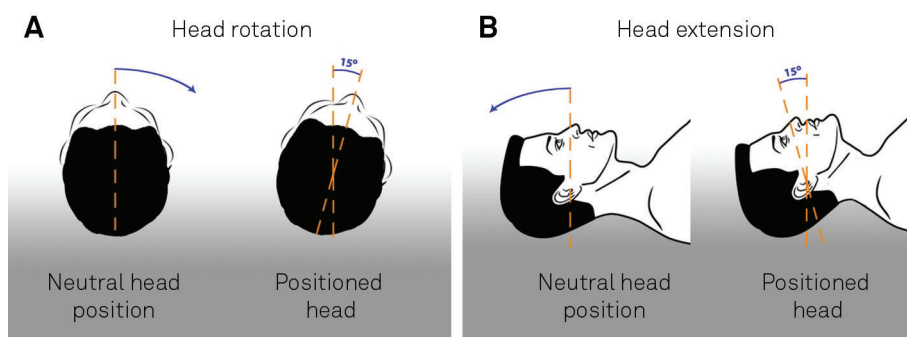
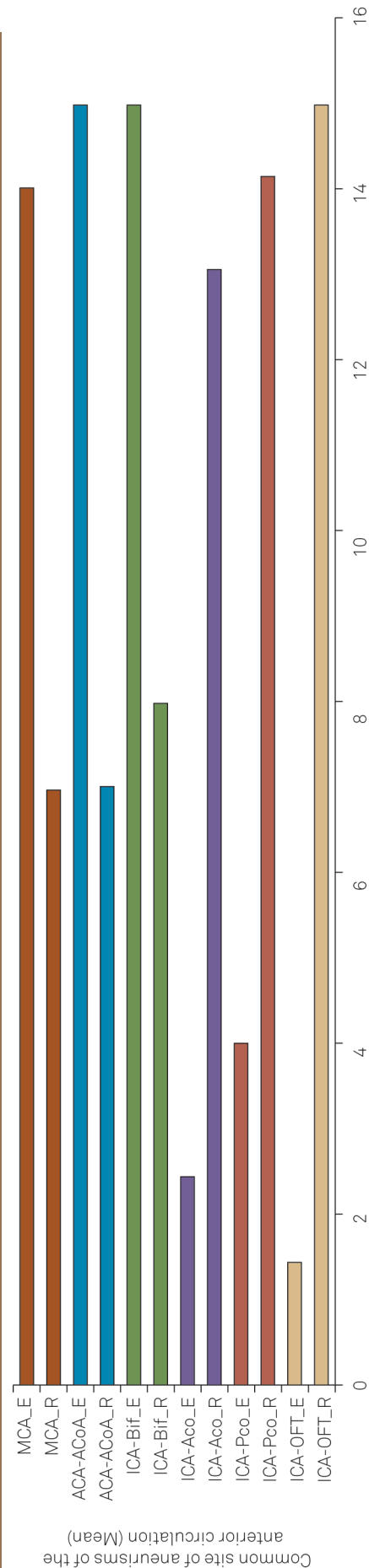


Figure 8. (A) Schematic draw showing the rotation of the head. (B) Drawing which shows the extension of the head.

Table 1. Rotation and extension for the best microsurgical exposure for each common site of aneurisms of the anterior circulation.

Specimen	ICA, OFT segment		ICA, PCo segment		ICA, ACo segment		ICA bifurcation		ACA, ACoA segment		MCA	
	Rotation	Extension	Rotation	Extension	Rotation	Extension	Rotation	Extension	Rotation	Extension	Rotation	Extension
1	16	2	13	4	20	3	10	15	3	16	10	13
2	17	3	12	6	17	4	11	14	4	17	8	13
3	13	2	15	5	12	4	7	14	4	20	7	12
4	12	2	16	5	11	5	6	12	5	19	9	17
5	10	1	14	7	11	6	7	17	4	19	9	17
6	18	1	12	3	10	1	9	20	6	12	8	14
7	15	0	16	3	15	1	9	19	6	12	4	14
8	16	1	18	4	14	2	10	19	9	13	5	13
9	14	3	17	4	9	2	6	9	10	13	5	15
10	14	0	10	2	12	1	7	11	11	12	7	15
11	15	2	12	3	13	2	7	10	8	16	7	15
12	16	1	14	3	13	3	8	13	10	15	4	16
13	17	1	13	3	12	1	9	14	11	14	6	12
14	15	3	15	4	19	1	10	16	7	14	6	10
15	15	2	15	4	18	2	6	16	7	15	9	12
16	18	1	16	6	10	2	6	17	8	13	7	15
17	13	2	12	6	10	3	7	18	8	12	7	14
18	14	0	13	3	11	2	7	18	6	15	8	14
19	16	2	12	3	12	3	8	15	5	17	8	15
20	16	1	18	2	12	2	10	13	9	16	6	14
Mean	15.00	1.50	14.15	4.00	13.05	2.50	8.00	15.00	7.05	15.00	7.00	14.00
Std Deviation	2.00	0.95	2.23	1.41	3.17	1.40	1.62	3.09	2.46	2.49	1.69	1.75
Lower CI on mean (95%)	14.06	1.06	13.11	3.34	11.57	1.85	7.24	13.55	5.90	13.83	6.21	13.18
Upper CI on mean (95%)	15.94	1.94	15.19	4.66	14.53	3.15	8.76	16.45	8.20	16.17	7.79	14.82



Std: Standard; CI: Confidence Interval; R: Rotation; E: Extension; ICA: Internal Carotid Artery; MCA: Middle Cerebral Artery; ACA: Anterior Cerebral Artery; ACoA: Anterior Communicating Artery; Pco: Posterior Communicating Artery; OFT: Optalmic segment of ICA; ICA-Bif: Internal Carotid Artery – Bifurcation Segment; ICA-Aco: Internal Carotid Artery – Anterior Choroidal Artery Segment.

Table 2. 110 patients harboring cerebral aneurysms.

Segments	Patients (male:female)
ICA, OFT segment	20 (9:11)
ICA,Acha segment	10 (4:6)
ICA, PCo segment	20 (9:11)
ICA bifurcation	20 (7:13)
ACA, ACoA segment	20 (9:11)
MCA	20 (7: 13)
TOTAL	110 (45:65)
Mean Age	53.2 (55:52)

ICA: Internal Carotid Artery; OFT: Ophthalmic Segment; Acha: Anterior Choroidal Artery; Pco: Posterior Communicating Artery; ACA: Anterior Cerebral Artery; ACoA: Anterior Communicating Artery, MCA: Middle Cerebral Artery.

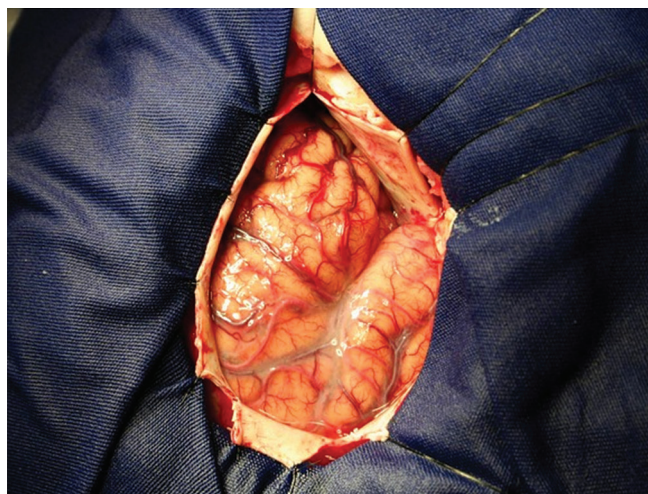


Figure 9. This picture shows a pterional craniotomy taking account to the extremely flattend orbital roof and perfect exposition of sylvian fissure in the middle of the surgical field.

adequate positioning of the patient's head allows a better exposure of the important neuro-vascular structures and facilitates the visualization of the aneurysm's neck and its main related arteries. A straight forward approach with less brain retraction and less manipulation of nearby structures also improves the procedure success.

This study led us to propose a set of positions that guides the neurosurgeon to place the patient's head according to the aneurysm location, which provided an appropriate exposure of the important structures in most of the studied cases (77.2%). The head position proposed for anterior communicating segment of ACA aneurysm was associated with the lower rate of success, but it was still suitable for most aneurysms at this location (65%). We also observed that the identification of anatomical fixed landmarks are extremely important because they can be used as reliable references for proper head positioning and as starting points for the recognition of nearby structures.

Aneurysms of the ophthalmic segment of ICA

The approach for microsurgical clipping of the ophthalmic segment of ICA aneurysms differs extremely from the usual approach for the aneurysms of the distal segments of the ICA. It is usually accomplished through a pterional craniotomy associated to partial resection of the orbit's roof and intradural anterior clinoidectomy for exposure of the ICA clinoid segment^{1,2,5,6}. Since these aneurysms present an intimate relationship with the skull base, head extension should be avoided in order to maintain the ICA in the most superficial position as possible and not to hide the aneurysm neck^{7,9,10}. Increasing

Table 3. Evaluation in the positioning of the head in the study.

Segments		Appropriate rotation and extension	Appropriate rotation and inappropriate extension	Inappropriate rotation and appropriate extension	Inappropriate rotation and extension	
ICA, Oph segment (20 pts)		14 pts (70%)	3 pts (15%)	3 pts (15%)	0 pts (0%)	
ICA, PCo segment (20 pts)		17 pts (85%)	1 pt (5%)	1 pt (5%)	1 pt (5%)	
ICA, ACha segment (10 pts)		8 pts (80%)	1 pt (10%)	0 pts (0%)	1 pt (10%)	
ICA bifurcation (20 pts)		15 pts (75%)	1 pt (5%)	4 pts (20%)	0 pts (0%)	
ACA, ACoA segment (20 pts)		13 pts (65%)	3 pts (15%)	4 pts (20%)	0 pts (0%)	
MCA (20 pts)		18 pts (90%)	1 pt (5%)	1 pt (5%)	0 pts (0%)	
TOTAL (110 pts)		85 pts (77.2%)	10 pts (9.1%)	13 pts (11.8%)	2 pts (1.8%)	
	Oo Ophthalmic Segment of ICA (20pts)	p Post. Comm. Segment of ICA (20 pts)	Choroidal Segment of ICA (10pts)	Ant. Comm. Artery (20pts)	ICA Bifurcation (20 pts)	Middle Cerebral Artery (20 pts)
App. R/E	14 pts (70%)	17 pts (85%)	8 pts (80%)	13 pts (65%)	15 pts (75%)	18 pts (90%)
App. R / Inapp. E	3 pts (15%)	1 pt (5%)	1 pt (10%)	3 pts (15%)	1 pt (5%)	1 pt (5%)
Inapp. R / App. E	3 pts (15%)	1 pt (5%)	0 pt (0%)	4 pts (20%)	4 pts (20%)	1 pt (5%)
Inapp. R/E	0 pt (0%)	1 pt (5%)	1 pt(10%)	0 pt (0%)	0 pt (0%)	0 pt (0%)

App: Appropriated; Inapp: Inappropriated; R: Rotation; E: Extention; ICA: Internal Carotid Artery; MCA: Middle Cerebral Artery; ACA: Anterior Cerebral Artery; ACoA: Anterior Communicating Artery; PCo: Posterior Communicating Artery; Oph: Ophthalmic segment of ICA; ACha: Anterior Choroidal Artery Segment (pts) Patients.

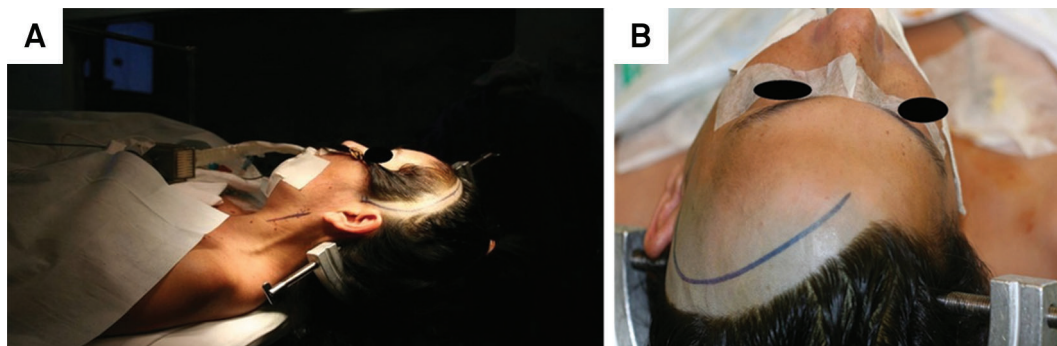


Figure 10. (A) Head positioning for pterional craniotomy in a patient with ICA ophthalmic segment. Note the neck preparation for arterial proximal control of internal carotid artery at the cervical segment. (B) This picture shows an extended head with the malar eminence positioned above the superior orbital margin.

head extension places the ACP deeper in the surgeon's view, hindering the anterior clinoidectomy and the aneurysm neck.

Surgical removal of the ACP, of the smaller wing of the sphenoid bone and of the orbital roof requires contra-lateral rotation of the head. Hence, the ACP is placed perpendicular to the ground and the exposure of its base and lateral wall facilitates its "drilling". The final result offers the surgeon a perpendicular view of the aneurysm neck.

Aneurysms of the posterior communicating and anterior choroidal segments of ICA

Maintaining the head without extension avoids the orbital roof and the ACP to obstruct the view of the proximal segment of the ICA, where the posterior communicating and anterior choroidal arteries origins are found. In addition, a neutral head extension places the ICA more superficially.

A further slight head rotation allows a better view of the emergence of the PCo artery. The more the aneurysm is projected sideways, the smaller degree of rotation is required. When these aneurysms point posteriorly the head's rotation should be greater. Excessive rotation tends to reduce the spaces between the PCo artery, the tentorium free edge and the oculomotor nerve, making the identification and dissection of the arterial origin and the aneurysm's neck more difficult.

Aneurysms of the ICA bifurcation

These aneurysms have intimate relationship with the basal surface of the frontal lobe and the anterior perforated substance. Therefore it requires an extension of at least 15 degrees. Contra-lateral rotation should be discreet, and frontal lobe retraction during the dissection should be avoided once there are arachnoids adhesions between the aneurysm and the brain^{1,2,5}.

Aneurysms of MCA

The head rotation should be short, around 5 to 10 degrees. Rotation above 10 degrees deepens the proximal

portion of the SF, making the dissection of the quiasmatic, carotid and M1 cisterns more difficult. Head extension, however, should be significant (about 15 degrees) since it places the SF more superficial to the surgeon. Extension beyond 20 degrees must be avoided because it brings the orbital roof towards the surgeon's angle of view.

Anterior communicating complex aneurysms

The anterior communicating artery complex includes the anterior cerebral artery, the anterior communicating artery and the Heubner's recurrent artery^{5,6,10}. These aneurysms are among the most complex lesions faced by neurosurgeons⁸. The multiple configuration of the region's vascular anatomy, the relationships of these aneurysms with important perforating vessels, and their variable directions are responsible for their complexity^{5,11,12}.

For a better identification of the contralateral A2, the patient should be positioned with a slight rotation, between 5 and 10 degrees.

The degree of extension depends on the aneurysm's projection. If the aneurysm is projected anteriorly and inferiorly, a pterional craniotomy requires a head extension limited to 10 to 15 degrees. When it projects superiorly and posteriorly, into the interhemispheric fissure, the best approach is through a lateral subfrontal corridor, with an extension up to 20 degrees. Since the superior orbital margin then frequently decreases the surgeon's microscopic angle of vision and of clipping, a fronto-orbital-zygomatic craniotomy may be particularly helpful in these cases.

We conclude that the correct position of the patient's head can lead to a better approach and exposure of the aneurysm neck, enhancing also the visualization of its related arteries. We strongly believe that appropriate head positioning is the first step for a safe and effective aneurysm clipping.

For didactic reasons we combined the most common sites of aneurysms into two groups, and propose a head positioning for each one. According to our findings:

First group

Aneurysms located at the ophthalmic, posterior communicating and anterior choroidal segments of ICA are more properly approached with the head in neutral extension and with 15 degrees of rotation.

Second Group

MCA, anterior communicating segment of ACA, and ICA bifurcation aneurysms can more properly be approached with the head at 15 degrees of extension and with minimal rotation.

Acknowledgements

The authors kindly thank the Death Verification Institute of the University of São Paulo Medical School and all patients admitted at the Department of Neurosurgery of the Universidade Estadual de Campinas (UNICAMP) who were operated and essentially contributed to this study.

References

1. Chaddad Neto F, Campos-Filho JM, Doria-Netto HL, Faria MH, Ribas GC, Oliveira E. The pterional craniotomy: step by step. *Arq Neuropsiquiatr* 2012;70:727-32.
2. Chaddad-Neto F, Doria-Netto HL, Campos-Filho JM, Reghin-Neto M, Oliveira E. Pretemporal Craniotomy. *Arq Neuropsiquiatr* 2014;72(2):145-51.
3. Chaddad-Neto F, Doria-Netto HL, Campos-Filho JM, Reghin-Neto M, Rethon-Jr, AL, Oliveira E. The far-lateral craniotomy: tips and tricks. *Arq Neuropsiquiatr* 2014;72(9):699-705.
4. Gibo H, Lenkey C, Rhoton AL, Jr. Microsurgical anatomy of the supraclinoid portion of the internal carotid artery. *J Neurosurg* 1981;55:560-74.
5. Rhoton AL, Jr., Saeki N, Perlmutter D, Zeal A. Microsurgical anatomy of common aneurysm sites. *Clin Neurosurg* 1979;26:248-306.
6. Yasargil MG. *Microneurosurgery* Thieme, Stuttgart 1987.
7. Ferreira MAT, Tedeschi H, Wen HT, de Oliveira E. Posterior circulation aneurysms: guideline to management. *Oper Tech Neurosurg* 2000;3:169-78.
8. Fujitsu K, Kuwabara T. Zygomatic approach for lesions in the interpeduncular cistern. *J Neurosurg* 1985;62:340-3.
9. Drake CG. Bleeding aneurysms of the basilar artery. Direct surgical management in four cases. *J Neurosurg* 1961;18:230-8.
10. Rhoton AL, Jr. Anatomy of saccular aneurysms. *Surg Neurol* 1980;14:59-66.
11. Drake CG. The surgical treatment of aneurysms of the basilar artery. *J Neurosurg* 1968;29:436-46.
12. Rosner SS, Rhoton AL Jr., Ono M, Barry M. Microsurgical anatomy of the anterior perforating arteries. *J Neurosurg* 1984;61:468-85.