

# Endoscopic release of the tarsal tunnel: a suggested surgical approach

MARCELO JOSÉ CORTEZ BEZERRA<sup>1</sup>, JOSÉ ALBERTO DIAS LEITE<sup>2</sup>,  
JOSÉ ESTRELA NETO<sup>3</sup>, SILVIA ROMERO<sup>4</sup>,

## SUMMARY

To establish to portals in cadavers, using anatomical delimitation points and geometrical lines, which allows the access to the tarsal tunnel by the video-endoscopic technique and the comparison between the proximal-distal direction approach with the reverse one. This trial has included 18 cadavers and 36 ankles were studied. Starting with the biportal endoscopic technique, initially described and modified in this trial through geometrical lines and anatomical points delimitation, the tarsal tunnel was released in left ankles with the insertion of instruments using proximal-distal direction and the opposite to the right ankles. There were, in the right ankles, complete section of flexor retinaculum

in 15 cases (83,3%) and partial section in 3 cases (16,67%). In the left ankles there were complete section of flexor retinaculum in 16 (88,89%) and partial section in 2 cases (11,11%). The average operative time was 19,44 minutes for the right limb and 18,33 minutes for the left limb. No damage to neurovascular structures has been observed in any case. According to the suggested technique, the total section of flexors retinaculum was obtained in all the cases after learning curve period without lesion of anatomical structures in the tarsal tunnel, no matter the direction chosen in the access way.

**Keywords:** Tarsal tunnel syndrome/surgery; Endoscopy.

## INTRODUCTION

Tarsal Tunnel Syndrome is the term used to designate the compression of the posterior tibial nerve within the tunnel or of one of its terminal branches leaving the tunnel. This syndrome is due to a neurogenic cause and affects the area supplied by the tibial nerve. The tibial nerve has three branches: the medial plantar nerve, the medial lateral nerve, and the medial calcaneus nerve. The osteofibrous tunnel is posterior to the medial maleolus, its floor being formed by the medial talar surface, the *sus-tentaculum tali*, and the medial wall of the calcaneus. It is covered by the flexor retinaculum that is posteriorly continuous to the superficial and deep aponeurosis of the leg. The base of the flexor retinaculum corresponds to the upper margin of the abductor hallucis muscle. The most often sites of compression are anatomically related to the pathway established by the surrounding inelastic elements<sup>(1,5,7)</sup>.

The etiology can be related to tumors or masses within the tunnel, metabolic abnormalities, trauma, foot and ankle deformities, and idiopathic causes. The tarsal tunnel syndrome manifests itself in different signs and symptoms, thus making early diagnosis difficult<sup>(1)</sup>. When clinical treatment fails, both open and videoendoscopic surgery can be carried out. Open surgery techniques have been described by Lam<sup>(6)</sup>, and the videoendoscopic technique has been recently recommended by Day e Nappes<sup>(3,4)</sup>. In their study, the authors emphasize the lower morbidity associated with the endoscopic technique. However, the anatomic points and geometric lines accurately defining the portals have not been described, in contrast with those accurately

described for the biportal route for the carpal<sup>(2)</sup> or cubital tunnel<sup>(9)</sup> release.

The present study aims to standardize the biportal route for tarsal tunnel release by defining the anatomic points and geometric lines, as well as by confirming the opening of the flexor retinaculum in cadavers when the proximal-distal or reverse approach was carried out with endoscopic instrumentation.

## METHODS

The present study evaluated 18 (eighteen) formol-untreated human cadavers with a total of 36 (thirty-six) ankles. They were provided by the Forensic Medicine Institute of the Ceará State in accordance with the regulation for research in humans of the National Council of Health - Ministry of Health (CNS's Resolution of October 10, 1996). The study was approved by the Committee of Ethics and Research of the Hospital Complex of the UFC (COMEPE). The present study was carried from January 2001 to August 2001. Fifteen male (83.3%) and three (16.6%) female cadavers were studied. The apparent age ranged from 20 to 45 years, with a mean apparent age of 27.5 years. As for the race, the following results were found: White: 7 (38.8%); Mulatto: 8 (44.4%); Black: 3 (16.6%).

The surgical instrumentation used in the present study was that used for endoscopic surgery of carpal tunnel (Dyonics®, USA) and consisted of an arthroscope optics with an angular lens of 30°, slotted cannula, trocar, palpador, and probe with reverse cutting blade (Figure 1).

Study carried out at the Strictu-Sensu Postgraduate Program of the Department of Surgery of the Medicine School of the Federal University of Ceará (DC/FM/UFC).

- 1- Member of the SBOT and Master in Surgery Student
- 2 - Professor of the Postgraduate Program
- 3 - Adjunct Professor and Master in Surgery
- 4 - Grant researcher

Mail address:  
Rua Carlos Vasconcelos, 389, Ap.1004, Meireles  
ZIP Code: 60.115.170  
Fortaleza - Ceará - Brasil  
E-mail-cantocortez@uol.com.br

Received on October 5, 2004 and approved on November 29, 2004.

The following instruments were also used: voltage stabilizer, light source, camera and a 14-inch TV screen, dermatographic pens, blade handles #3, scalpel blade # 15, dissecting scissors, straight scissors, Adson forceps with serrated tips, needle carrier, Farabeuf retractor, and autostatic mini-retractor.

Preliminary studies of morphometry and morphology of the tarsal tunnel were carried out by using anatomic specimens from male and female adults at the Morphology Department of the UFC. This preliminary study allowed us to define the standard anatomic points (PRA) 1 to 5. The standard anatomic point # 1 (PRA1) corresponds to the center of the medial malleolus (CMM). The standard anatomic point # 2 (PRA2) is formed by a straight line extending from PRA1 to the calcaneus tendon (TC), with which it forms a right angle when intersecting it, a point in the center of this line corresponds to the proximal portal. The standard anatomic point # 3 (PRA3) corresponds to a straight line extending from PRA1 to the insertion of the calcaneus tendon (ITC). The standard anatomic point # 4 (PRA4) is formed by a straight line extending from the center of the first metatarsus (C1°M) to the ITC. The standard anatomic point # 5 (PRA5) is a straight line parallel to the tibia that crosses PRA1.

The bisectrix formed by PRA3 and PRA5 corresponds to the distal portal when it crosses the right line formed by PRA4. The standard anatomic points and their crossings define the proximal and the distal portal (Figure 2). Once the proximal and distal portals were determined, the endoscopic procedure was initiated.

A skin incision (1 cm) was carried out in the proximal portal in the left ankle, the flexor retinaculum is immediately below the subcutaneous tissue that is slightly drawn with a forceps and a transversal incision is made to give access to the surgical instrumentation. The distal portal was then addressed when an elliptical incision (2 cm) was carried out to give access to the abductor cannal (where the flexor retinaculum is continued by the plantar aponeurosis). The latter should be released so as to decompress the branches of the posterior tibial nerve.

A slotted cannula containing the trocar is inserted into the tarsal tunnel (proximal to distal insertion). Following trocar removal, the optics is positioned within the tunnel through the distal portal. With the groove of the slotted cannula turned to the skin, the transverse fibers of the flexor retinaculum are displayed on the TV screen. Using the probe inserted into the proximal probe, one can palpate this structure. With the help of the probe with reverse cutting blade, the flexor retinaculum is cut (distal to proximal course). Release was clearly confirmed when subcutaneous tissue was seen on the cannula groove. The trocar then is repositioned within the cannula and both were removed.

A elliptical incision (2 cm) was carried out in the distal portal in the right ankle and followed by a careful dissection of the tarsal tunnel so as

to disclose the neurovascular elements in the abductor canal. A slotted cannula and the trocar were positioned within the tarsal tunnel (distal to proximal course) so as to reach the proximal portal when the trocar was removed and the optics was inserted into the proximal portal while the probe was inserted into the distal portal.

With the groove of the slotted cannula turned to the medial face of the foot, the transversal fibers of the flexor retinaculum were identified and cut with the help of the probe with reverse cutting blade (proximal to distal course) (Figure 3). The trocar was repositioned within the slotted cannula and both were removed.

## RESULTS

The results obtained in the present study are shown in the tables and the corresponding graphs as follows: according to sex (Table 1, Graph 1), race (Table 2, Graph 2), complete or partial flexor retinaculum release I (Tables 3 and 4; Graphs 3 and 4), presence or absence of complications (vascular and/or neurological lesion) and surgery duration (Table 5, Graph 5). The right ankle was always compared to the left ankle.

No significant difference was found in the flexor retinaculum release between the right and the left ankle for a significance level of 0.05 and p value of 0.52 following surgery (Wald statistics).

No complication was seen in any ankle following surgery. The t-Student test did not show significant differences in the mean surgery duration between the right and the left ankle for a p value of 0.71 and significance levels of 5% and 1%.

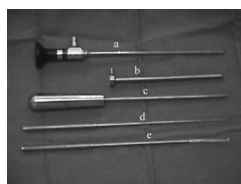
## DISCUSSION

The tarsal tunnel contains elements that can be compressed (posterior tibial nerve and its branches), with clinical impact <sup>(1,8)</sup>.

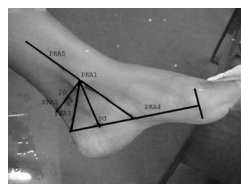
Day e Napples<sup>(3,4)</sup> successfully showed endoscopic decompression of the tarsal tunnel. They identified the proximal and the distal portal by palpating the anatomic elements under eversion and dorsiflexion of the foot. In contrast with these authors, we determined the access to the tarsal tunnel by identifying the proximal and the distal portal with the help of geometric lines extending from previously defined anatomic points and their intersections. Therefore, we used a mathematical model to define the

proximal and distal portal and not the palpation of anatomic structures. This model can be useful in patients who have restricted motility of the foot for any reason, making the use of the technique easier.

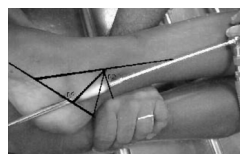
No significant statistical difference was found in the flexor retinaculum release between the proximal-distal ac-



**Figure 1 - Endoscopic Instruments:** a) arthroscope optics, b) slotted cannula, c) trocar, d) palpador, e) probe with reverse cutting blade



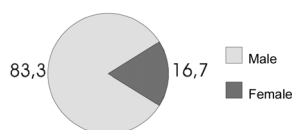
**Figure 2 - Standard Anatomic Points ( PRA1, PRA2, PRA3, PRA4 e PRA5 ). Proximal Portal (pp) and Distal Portal (pd) .**



**Figura 3 - Distal- Proximal positioning of the slotted cannula**

Sex	Number of cases	Percentage
Male	15	83,3
Female	3	16,6
Total	18	100,00

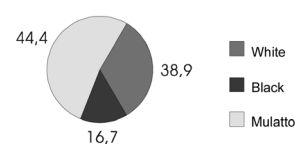
**Table 1 - Number of cases according to sex**



**Graph 1 - Percentage of cases according to sex**

Race	Number of cases	Percentage
White	7	38,8
Black	3	16,6
Mulatto	8	44,4
Total	18	100,00

**Table 2 - Number of cases according to race**



**Graph 2 - Percentage of cases according to the race**

Flexor Retinaculum Section	Right	%	Left	%
Complete	15	83,3	16	88,89
Partial	3	16,67	2	11,11
Total	18	100,00	18	100,00

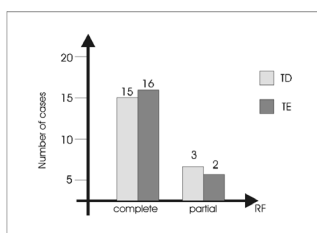
**Table 3 - Number of cases according to flexor retinaculum section per ankle**

Caso	1	2	3	4	5	6	7	8	9	10	11	12	13	14	15	16	17	18
RF																		
TD	P	P	P	C	C	C	C	C	C	C	C	C	C	C	C	C	C	C
TE	P	C	P	C	C	C	C	C	C	C	C	C	C	C	C	C	C	C

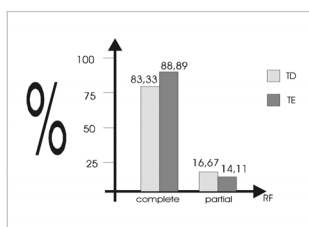
**Table 4 - Flexor retinaculum section according to case and ankle (complete or partial)**

Caso	1	2	3	4	5	6	7	8	9	10	11	12	13	14	15	16	17	18
TD	30	30	25	25	20	15	20	15	20	15	20	15	15	15	15	20	15	15
TE	30	25	20	25	20	20	15	15	15	20	15	15	15	15	15	15	15	15

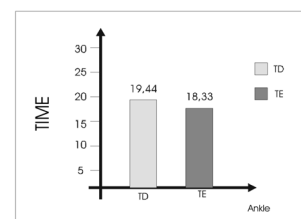
**Table 5 - Surgery duration in minutes per case and ankle**



**Graph 3 - Number of cases of flexor retinaculum section according to the ankle**



**Graph 4 - Section of the flexor retinaculum (FR) per ankle - Percentage of cases**



**Graph 5 - Mean surgery duration per ankle**

cess (right ankle) and the distal-proximal (left ankle) access to the tarsal tunnel. Partial release was obtained in right and left ankles at first. This is probably due to the learning curve of the authors. However, the distal access was easier, as compared to the proximal access. This difference can be due to postmortem rigidity. Damage to neurovascular elements associated with the endoscopic technique did not occurred in any ankle in the present study, a finding consistent with that reported by Day and Naples<sup>(3,4)</sup>. The lack of adhesions between the flexor retinaculum and surrounding tissues was due to the fact that all cadavers were young, as well as to the absence of previous diseases in the studied area, thus corroborating the total absence of neurological and/or vascular injury.

No statistically significant difference was found in the mean surgery duration with higher values in the first cases and shorter values in later cases, probably a result of familiarization with the method.

The present study allowed us to clinically use this technique in patients with tarsal tunnel syndrome who also had Hansen's disease, a prevalent illness in our country.

A larger clinical study comparing the open surgery with the endoscopic technique can elucidate the advantages and disadvantages of each technique.

## CONCLUSIONS

1. Portals determined by anatomic points and geometric lines gave access to the tarsal tunnel for endoscopic surgery. Complete section of the flexor retinaculum was obtained in all cases following learning and familiarization with the method.

2. The use of proximal-to-distal and distal-to-proximal portals did not adversely affect the final outcome.

## REFERENCES

- Bailie DS, Kelikian AS. Tarsal tunnel syndrome: diagnosis, surgical technique and functional outcome. *Foot Ankle Int* 19:65-72, 1998.
- Chow JC. Endoscopic release of the carpal tunnel ligament: a new technique for carpal tunnel syndrom. *J Arthroscopy* 5:19,1989.
- Day FN, Naples JJ. Endoscopic tarsal tunnel release: Update 96. *J Foot Ankle Surg* 35:225-229, 1996.
- Day FN, Naples JJ. Tarsal tunnel syndrome: An endoscopic approach with 4 to 28 month follow-up. *J Foot Ankle Surg* 33:244-248, 1994.
- Gardner E, Osburn WA. *Anatomia do corpo humano*. 2.ed. São Paulo: Atheneu. 293-294, 400, 1980.
- Lam SJS. Tarsal tunnel syndrome. *J. Bone joint Surg* 49B:87-92, 1967.
- Lau JT, Daniels TR. Tarsal tunnel syndrome: a review of the literature. *Foot Ankle Int* 20:201-209, 1999.
- Oh SJ, Meyer RD. Entrapment neuropathies of the tibial (posterior tibial) nerve. *Neurol Clin* 17:593-615, 1999.
- Sampaio ACD. Bases anatômicas e cirúrgicas da liberação endoscópica do túnel cubital: sistematização das estruturas internas. [Dissertação]. Fortaleza: Universidade Federal do Ceará- Departamento de Cirurgia da Faculdade de Medicina, 1997.