



REVISTA BRASILEIRA DE REUMATOLOGIA

www.reumatologia.com.br



Case report

IgA nephropathy and polymyositis: a rare association

Thiago Bitar Moraes Barros^a, Fernando Henrique Carlos de Souza^a,
Denise Maria Avancini Costa Malheiros^b, Mauricio Levy-Neto^a, Samuel Katsuyuki Shinjo^{a,*}

^aService of Rheumatology, Hospital das Clínicas, Medicine Faculty, Universidade de São Paulo, São Paulo, SP, Brazil

^bService of Pathology, Hospital das Clínicas, Medicine Faculty, Universidade de São Paulo, São Paulo, SP, Brazil

ARTICLE INFO

Article history:

Received on 30 November 2012

Accepted on 30 November 2012

Keywords:

Inflammatory myopathy
IgA nephropathy
Polymyositis
Case report

ABSTRACT

Polymyositis is a systemic and idiopathic inflammatory myopathy that, besides muscle manifestation, may occur with respiratory involvement, gastrointestinal tract and rarely renal involvement. In this latter, there are only two cases of IgA nephropathy, but both in dermatomyositis. On the other hand, we reported, for the first time, a case of IgA nephropathy in polymyositis.

© 2014 Sociedade Brasileira de Reumatologia. Published by Elsevier Editora Ltda.
All rights reserved.

Nefropatia por IgA e polimiosite: uma rara associação

RESUMO

A polimiosite é uma miopatia inflamatória idiopática sistêmica que, além da manifestação muscular, pode eventualmente cursar com acometimento respiratório, do trato gastrointestinal e, raramente, renal. Neste último caso, há descrição de apenas dois casos de nefropatia por IgA em pacientes com miopatia, ambos em dermatomiosite. Em contrapartida, relatamos pela primeira vez esta rara associação em polimiosite.

© 2014 Sociedade Brasileira de Reumatologia. Publicado por Elsevier Editora Ltda.
Todos os direitos reservados.

Palavras-chave:

Miopatia inflamatória
Nefropatia por IgA
Polimiosite
Relato de caso

Introduction

Polymyositis is classified within the spectrum of idiopathic inflammatory myopathies, together with dermatomyositis. It is clinically characterized by progressive proximal muscle weakness of the limbs, leading to high morbidity and functional disability.

Among the extramuscular manifestations found, the most common are the respiratory and gastrointestinal involvement respiratory and of gastrointestinal tract involvement.^{1,2} Renal involvement in polymyositis is uncommon, with rare descriptions of nephropathy associated with acute tubular necrosis secondary to rhabdomyolysis and chronic glomerulonephritis.³⁻⁹

IgA nephropathy is a primary glomerulonephritis characterized by IgA deposits in the mesangial area of glomeruli.

* Corresponding author.

E-mail: samuel.shinjo@gmail.com (S.K. Shinjo).

0482-5004/\$ - see front matter. © 2014 Sociedade Brasileira de Reumatologia. Published by Elsevier Editora Ltda. All rights reserved.

<http://dx.doi.org/10.1016/j.rbre.2012.11.001>

Approximately one-third of patients with this type of renal manifestation progresses to chronic renal failure after 20-25 years of disease.¹⁰ Among the systemic diseases, IgA nephropathy is most commonly associated with Henoch-Schönlein purpura.¹¹ However, its association with idiopathic inflammatory myopathies is extremely rare, with only two cases described, both in dermatomyositis,^{12,13} which motivated us to present this case.

Clinical case

Male patient, 35 years-old, white, trader, born in São Paulo. Previously healthy, presented six months ago with progressive proximal muscle weakness of all four limbs without apparent cause and without constitutional symptoms. When the patient came to our hospital service, the physical examination showed grade III proximal muscle strength in all four limbs without skin lesions and/or involvement of other organs, such as lung or kidney. Laboratory tests showed serum creatine kinase (CK) = 3,545 IU/L (normal range: 24-204 IU/L), aldolase = 33 IU/L (reference value: $7.5 < \text{IU/L}$), antinuclear factor and anti-Jo-1 negative, C-reactive protein = $7.8 \mu\text{g/mL}$ (reference value: $< 5 \mu\text{g/mL}$), erythrocyte sedimentation rate = 17 mm/1st hour (reference value: $< 10 \text{ mm/1st hour}$), electroneuromyography suggestive of proximal inflammatory myopathy of all limbs without evidence of associated neuropathy. The muscle biopsy (biceps brachii) revealed the presence of an endomysial and perimysial inflammatory infiltrate and also necrosis of the muscle fibers and macrophage invasion, thus suggesting inflammatory myopathy. During the clinical investigation, neoplastic and metabolic causes were ruled out.

With the presumptive diagnosis of polymyositis, according to the criteria of Bohan and Peter,¹⁴ corticosteroids (prednisone 0.5 mg/kg/day) and methotrexate (maximum dose 20 mg/week) were initiated. After six months of treatment, the patient developed acute lung injury secondary to pneumopathy requiring endotracheal intubation and mechanical ventilation for three weeks. Infection and/or disease activity were discarded. In face of the possibility of lung disease secondary to methotrexate, this medication was discontinued, and the prednisone dose was optimized. The patient developed progressive pulmonary improvement without sequelae. Subsequently, as a steroid sparing drug, azathioprine was introduced (maximum dose of 3 mg/kg/day). Due to the stability of the disease and to the pulmonary improvement, the dose of prednisone (which at that time was 0.2 mg/kg/day) was gradually reduced. However, with no apparent cause the patient began to show macroscopic hematuria, edema of lower limbs (2+/4+) without hemodynamic and pressure repercussion. The laboratory examination showed: urinalysis with pyuria (> 100 leukocytes/field), hematuria (> 100 erythrocytes/field), moderate erythrocyte dysmorphism and lipid casts; $24\text{h-proteinuria} = 1.76 \text{ g}$, serum albumin = 3.6 g/dL , serum creatinine = 0.9 mg/dL and negative urine culture. There was no sign of clinical-laboratorial activity of PM at that time.

We decided then to perform a renal biopsy which showed 14 glomeruli with diffuse segmental endocapillary cell proliferation. One glomerulus showed one cellular crescent and two fibroblastic crescents. Moreover, the glomerulus exhib-

ited mild tubulointerstitial change, focal tubular atrophy and interstitial fibrosis. An interlobular artery showed intimal fibrosis. Immunofluorescence showed diffuse deposits of only IgA in the mesangial region and in the peripheral capillary wall of the glomerulus (fig. 1), suggestive of IgA nephropathy.

The dose of prednisone (0.2 mg/kg/day) was maintained, azathioprine was discontinued, and monthly cyclophosphamide (0.75 mg/m^2 , IV) was initiated for 12 months; with the patient achieving complete remission of the renal disease. Subsequently, as a maintenance drug, azathioprine was reintroduced (maximum dose of 2.5 mg/kg/day). Currently, the patient denotes stability, both from the point of view of polymyositis as of nephropathy, and without corticosteroid therapy.

Discussion

To our knowledge, this is the first case in the literature that reports an IgA nephropathy in idiopathic inflammatory myopathy, particularly polymyositis.

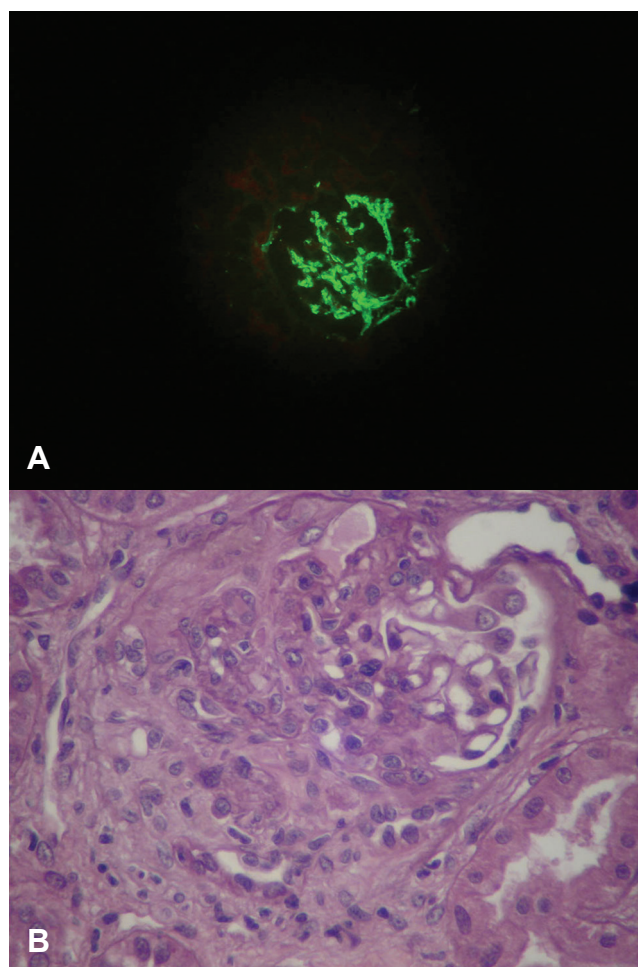


Fig. 1 – Renal biopsy
(A) Optical microscopy. A glomerulus with diffuse proliferative glomerulonephritis. PAS staining,
(B) Immunofluorescence demonstrating diffuse IgA deposit in mesangial region and the peripheral capillary wall of the glomerulus.

Renal involvement in idiopathic inflammatory myopathy is uncommon, including acute tubular necrosis and glomerulonephritis.³⁻⁹ In the latter case, Takizawa *et al.*⁴ demonstrated by renal biopsy in a series of 21 cases of dermatomyositis/polymyositis, that the presence of nephritis was associated with membranous and proliferative mesangial glomerulonephritis, respectively, in polymyositis and dermatomyositis.

The relationship between IgA nephropathy and idiopathic inflammatory myopathies is extremely rare. To date, there are only two case reports, both occurring in dermatomyositis.^{12,13} Civilibal *et al.*¹³ reported a case of newly diagnosed juvenile dermatomyositis, with hematuria and nephrotic proteinuria in course, without loss of kidney function. A percutaneous renal biopsy allowed the diagnosis of IgA nephropathy. There was a favourable response both from the point of view of inflammatory myopathy as of nephropathy, with the maintenance of methotrexate associated with oral corticosteroids. On the other hand, Yen *et al.*¹² described a young woman who developed IgA nephropathy after 1.5 years of an established diagnosis of dermatomyositis while using both azathioprine and corticosteroids.

Unlike these two cases, in the present trial we present a male patient with confirmed diagnosis of polymyositis. However, like the case reported by Yen *et al.*,¹² the patient had been using corticosteroids and immunosuppressive medication, when evolved with renal dysfunction after 1.5 years, being subsequently diagnosed with IgA nephropathy.

The association between dermatomyositis and IgA nephropathy is plausible, since both diseases share the involvement of humoral immunity (immunocomplexes).^{3,15} On the other hand, the relationship with polymyositis is remote, because in the latter case there is a predominance of cellular immunity. Thus, in the present clinical case, we strongly suggest the existence of two distinct morbidities.

In short, to our knowledge, we reported for the first time a case of IgA nephropathy in a patient with polymyositis.

Conflicts of interest

The authors declare no conflicts of interest.

REFERENCES

1. Marie I, Hachulla E, Cherin P, Dominique S, Hatron PY, Devulder B *et al.* Interstitial lung disease in polymyositis and dermatomyositis. *Arthritis Rheum.* 2002;47:614-22.
2. de Merieux P, Verity MA, Clements PJ, Paulus HE. Esophageal abnormalities and dysphagia in polymyositis and dermatomyositis. *Arthritis Rheum.* 1983;26:961-8.
3. Yen TH, Lai PC, Chen CC, Hsueh S, Huang JY. Renal involvement in patient with polymyositis and dermatomyositis. *Int J Clin Pract.* 2005;59:188-93.
4. Takizawa Y, Kanda H, Sato K, Kawahata K, Yamaguchi A, Uozaki H *et al.* Polymyositis associated with focal mesangial proliferative glomerulonephritis with depositions of immune complexes. *Clin Rheumatol.* 2007;26:792-6.
5. Dyck RF, Katz A, Gordon DA, Johnson M, Shainhouse Z, Cardella CJ *et al.* Glomerulonephritis associated with polymyositis. *J Rheumatol.* 1979;6:336-44.
6. Pirovino M, Neff MS, Sharon E. Myoglobulinuria and acute renal failure with acute polymyositis. *NY State J Med.* 1979;79:764-7.
7. Tsunemi M, Ishimura E, Tsumura K, Shoji S, Sugimura T, Nishizawa Y *et al.* A case of crescentic glomerulonephritis associated with polymyositis. *Nephron.* 1993;64:488-9.
8. Valenzuela OF, Reiser IW, Porush JG. Idiopathic polymyositis and glomerulonephritis. *J Nephrol.* 2001;14:120-4.
9. Makino H, Hirata K, Matsuda M, Amano T, Ota Z. Membranous nephropathy developing during the course of dermatomyositis. *J Rheumatol.* 1994;21:1377-8.
10. D'Amico G. Natural history of idiopathic IgA nephropathy: role of clinical and histological prognostic factors. *Am J Kidney Dis.* 2000;36:227-37.
11. Sanders JT, Wyatt RJ. IgA nephropathy and Henoch-Schönlein purpura nephritis. *Curr Opin Pediatr* 2008;20:163-70.
12. Yen TH, Huang JY, Chen CY. Unexpected IgA nephropathy during the treatment of a young woman with idiopathic dermatomyositis: case report and review of the literature. *J Nephrol.* 2003;16:148-53.
13. Civilibal M, Selcuk Duru N, Ozagari A, Durali K, Elevli M. Immunoglobulin A nephropathy associated with juvenile dermatomyositis. *Pediatr Nephrol.* 2009;24:2073-5.
14. Bohan A, Peter JB. Polymyositis and dermatomyositis. *N Engl J Med.* 1975;292:344-7.
15. Yen TH, Huang JY, Chen CY. Unexpected IgA nephropathy during the treatment of a young lady with idiopathic dermatomyositis. Case report and review of the literature. *J Nephrol.* 2002;16:148-53.