

Isolated necrotizing granulomatous vasculitis of the uterine cervix associated with human papillomavirus infection

Nilton Salles Rosa Neto¹, Fernando Henrique Carlos de Souza¹, Christina Shiang², Luís Balthazar Saldanha³, Samuel Katsuyuki Shinjo⁴, Ari Stiel Radu Halpern⁴

ABSTRACT

Single organ vasculitis (SOV), or isolated vasculitis, has been described in several organs and it can be an accidental finding. We report a case of isolated necrotizing granulomatous vasculitis of the uterine cervix in a middle-aged woman, previously healthy, and sexually active, and whose human papillomavirus (HPV) DNA hybrid capture assay was positive. Systemic involvement was not detected and, since the lesion was completely removed, we opted for a clinical follow-up. The literature has very few reports on the isolated involvement of the female genital tract, and some had concomitant lesions that could be caused by the HPV, indicati

Keywords: single-organ vasculitis, necrotizing granulomatous vasculitis, human papillomavirus.

INTRODUCTION

Systemic vasculitis involves multiple organs leading to a variety of signs and symptoms. However, primary single-organ vasculitis may or may not have clinical manifestations and, in some cases, excision of the lesion may be curative. It is believed that its etiopathogenesis is less complex than that of systemic vasculitis, and the study of this entity can help understanding the mechanism behind the development of those lesions.^{1,2}

Single-organ vasculitis (SOV) is divided in uni- or multifocal. It is usually an accidental finding during the investigation of other processes, such as inflammatory, neoplastic, or infectious. Although it is localized, it might represent the initial manifestation of a systemic disorder; therefore, the possible involvement of other sites should be investigated, and routine clinical and radiological follow-up should be maintained.¹

The histological patterns seen in SOV vary, *i.e.*, granulomatous and non-granulomatous, and affecting

small, medium, or large-caliber vessels. Currently, calling those lesions localized Wegener's granulomatosis (WG) or polyarteritis nodosa (PAN) is avoided, since they are well-defined clinical entities.¹

Single-organ vasculitis can affect several tissues and organs. However, it rarely affects the female genital tract, and when it does, it may affect the myometrium, ovaries, Fallopian tubes, parametrium, and, more commonly, the uterine cervix.³⁻¹⁰ A review of 120,000 surgical samples (hysterectomies or amputations of the uterine cervix) revealed 46 cases of gynecological vasculitis (0.04%), 30 of which were in the uterine cervix. The surgical indication in those cases was due to gynecological complaints, such as bleeding, pelvic masses, and changes in the smear of the uterine cervix (Papanicolau test).⁶ Most histological findings included fibrinoid necrosis; some showed giant cells; and only one described the presence of caseous granuloma. Among those 46 cases, one patient had a diagnosis of PAN while, on follow-up for a mean of three

Received on 01/19/2009. Approved on 07/17/2009. We declare no conflict of interest.

1. Rheumatology Resident at the Hospital das Clínicas of the Medical School of Universidade de São Paulo (HC-FMUSP).

2. Assistant Pathologist of the Pathology Department of HC-FMUSP.

3. Pathology Professor of the Medical School of the Universidade de São Paulo (FMUSP). Assistant Physician of the Pathology Department of HC-FMUSP.

4. Collaborator Rheumatology Professor of FMUSP. Assistant Physician of the Rheumatology Department of HC-FMUSP.

Correspondence to: Dr. Ari Stiel Radu Halpern. Disciplina de Reumatologia, FMUSP. Av. Dr. Arnaldo, 455, 3º andar, sala 3133, CEP 01246-903, Cerqueira César – São Paulo, SP. Tel: 55 11 3061-7492/ Fax: 55 11 3061-7490. E-mail: ari@artrite.com.br

years, three other patients developed systemic symptoms, i.e., one case of giant cell arteritis (GCA) and two of PAN.⁶

It has been postulated that, in cases of SOV of the genital tract, some gynecological comorbidities, such as cervicitis, intraepithelial neoplasia, or carcinoma, may have a role in the pathogenesis of the inflammation of the blood vessel.¹

Thus we report a case of unifocal SOV of the female genital tract, probably triggered by the human papillomavirus (HPV), and we review the literature on the subject.

CASE REPORT

This is a 49 years old white female, divorced, from São Paulo, SP, Brazil, previously healthy, and sexually active. Initially, she was evaluated on a basic health unit where, during routine Papanicolaou test, a high degree intraepithelial lesion (cervical intraepithelial neoplasia – CIN – II and III) was observed on the uterine cervix. She was referred to our service for directed colposcopy and biopsy, and complementary evaluation of sexually transmitted diseases. She had negative serologies for HIV, syphilis, and hepatitis B and C, and *Chlamydia* and *Neisseria* were negative both in the urethra and vagina. The anatomopathological exam (AP) showed chronic active cervicitis, and HPV DNA hybrid capture was positive (a multidetector probe for 13 oncogenic viruses, without discriminating the specific type, was used). Conization of the uterine cervix was indicated. Anatomopathological exam of the surgical specimen showed chronic cervicitis with immature squamous metaplasia and necrotizing granulomatous vasculitis (Figures 1 and 2). The patient was, then, referred for

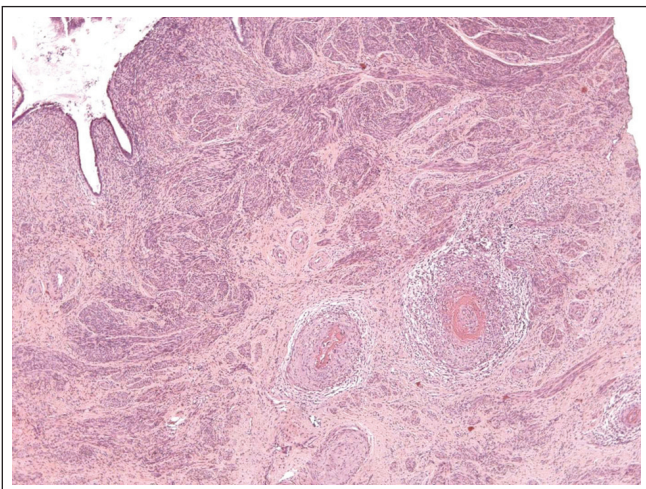


Figure 1. Histology of the uterine cervix showing an inflammatory infiltrate affecting the arteries. Hematoxylin-eosin stain, 50x.

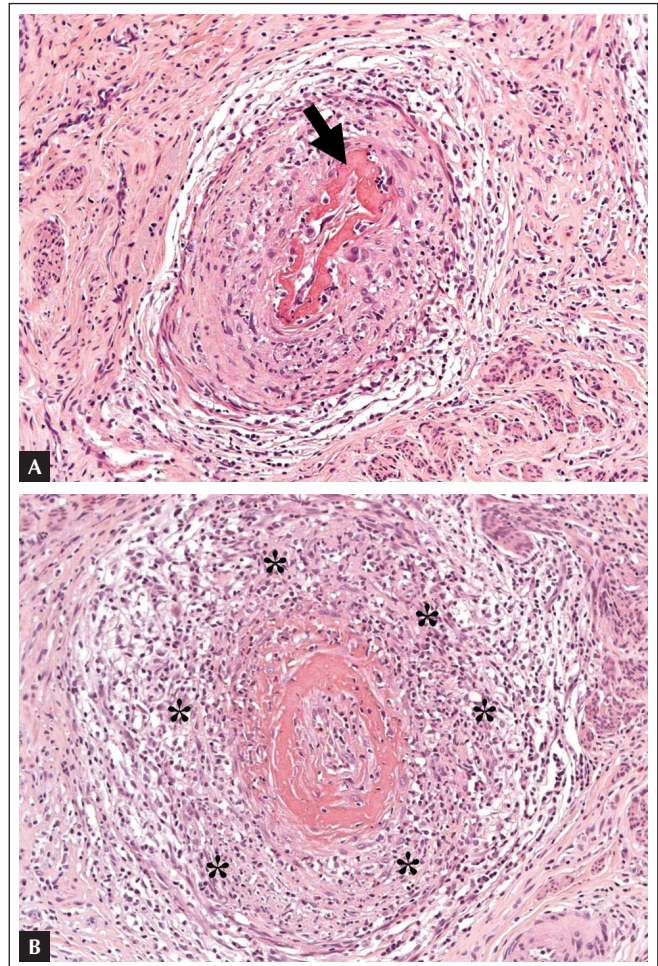


Figure 2. Necrotizing vasculitis of an artery of the uterine cervix. a) Fibrinoid necrosis (around the lumen – arrow); b) mixed transmural inflammatory infiltrate with partial destruction of the arterial wall (the entire arterial circumference is represented by a granulomatous process – *). Hematoxylin-eosin staining, 200x.

rheumatologic evaluation due to the possibility of a localized form of systemic vasculitis.

The patient denied respiratory or urinary symptoms, paresthesia, skin and ocular lesions, and constitutional symptoms. Complementary laboratorial exams revealed normal inflammatory tests, negative antineutrophil cytoplasmic antibodies (ANCA), fine speckled and dense anti-nuclear factor (ANF) at 1/160, presence of anti-Ro (SSA) autoantibodies by ELISA, and normal complement levels. Urine analysis did not show any changes, and CT scan of the chest and sinuses, as well as postoperative transvaginal ultrasound, were normal. Due to the absence of systemic manifestations and complete removal of the lesion, it was decided to follow-up the patient without specific therapy.

DISCUSSION

This is a report on the association of unifocal SOV with a pattern of granulomatous vasculitis and negative ANCA, and HPV infection. The results of routine cytology and the first biopsy motivated the surgical excision of the uterine cervix. Only the AP exam revealed the presence of vasculitis. The investigation did not show systemic involvement and ruled out other infections and neoplasias, corroborating the diagnosis of SOV, probably secondary to HPV infection.

Human papillomavirus is a family of viruses that infects mucous membranes and the skin. Approximately 70 non-oncogenic and 30 oncogenic types, classified according to the distribution of nucleic acids in the viral genome, have been identified. Koilocytosis, *i.e.*, perinuclear vacuolization associated with nuclear atypia, is the pathognomonic HPV lesion in the cell. Only one third of the women with HPV infection in which DNA was detected presented known cytopathologic changes.^{11,12} On the other hand, reports on the direct association of HPV and granulomatous or necrotizing lesions are not found in the literature.

Single organ necrotizing vasculitis was initially described in 1951 by Plaut, *apud* Ganesan *et al.*, who reported 88 cases of incidental vasculitis in the appendix. The histopathological finding of systemic and localized types is undistinguishable. However, in systemic disease, even when it affects only one organ, involvement of other organs or changes in inflammatory tests and, in some cases, the presence of ANCA, is expected. Localized WG, especially of the respiratory tract, with or without the presence of ANCA, can evolve with systemic involvement or chronicity of the lesion, including focal lesions, and, therefore, immunosuppressors are necessary for the clinical control of the condition.⁵

The histological lesion of SOV tends to show changes in the small vessels, limited to the involved organ, with little inflammatory infiltrate. Involvement of the retina, central nervous system, breasts, gallbladder, stomach, small bowel, appendix, bladder, and prostate, among others, has been reported. The few cases of involvement of the female genital tract reported affected the ovaries, Fallopian tubes, uterus, and uterine cervix.¹

A recent review⁴ proposed the division in two types:

a) PAN-like, in which isolated necrotizing vasculitis, with intra- and perivascular inflammatory infiltrated and fibrinous necrosis of a large portion of or the entire vascular wall, but affecting only a segment of the artery and, most often, affecting only one artery, is seen; and

b) GCA-like, with identification of giant cells, lymphocytes, and macrophages, affecting small and medium-caliber vessels.

Among the cases classified as PAN-like, 16 were related to intraepithelial cervical neoplasia, six to cervical cancer, and three to chronic cervicitis.⁴ However, a direct relationship between the presence of HPV and the development of vasculitis was not mentioned, despite the suggestion of the etiopathogenic role of chronic inflammation or neoplasia.

In the present case, unifocal SOV of the female genital tract, a rare case, probably triggered by the presence of HPV, was seen. The presence of ANF and anti-Ro was not relevant in the present case.

Due to the possibility that systemic vasculitis develop in response to infectious stimuli, it is interesting to note, as in the case described here, the possible role of HPV infection as a trigger factor of isolated necrotizing granulomatous vasculitis of the uterine cervix. The identification of HPV, even in cases without suggestive cytological lesions, could help explain the etiopathogenesis of isolated vasculitis of the genital tract.

REFERÊNCIAS

REFERENCES

- Hernandez-Rodriguez J, Molloy ES, Hoffman GS. Single-organ vasculitis. *Curr Opin Rheumatol* 2008; 20(1):40-6.
- Quinet RJ, Zakem JM, McCain M. Localized versus systemic vasculitis: diagnosis and management. *Curr Rheumatol Rep* 2003; 5(2):93-9.
- Pilch H, Schäffer U, Günzel S *et al.* (A)symptomatic necrotizing arteritis of the female genital tract. *Eur J Obstet Gynecol Reprod Biol* 2000; 91(2):191-6.
- Hoppé E, de Ybarlucéa LR, Collet J, Dupont J, Fabiani B, Puéchal X. Isolated vasculitis of the female genital tract: a case series and review of literature. *Virchows Arch* 2007; 451(6):1083-9.
- Burke AP, Virmani R. Localized vasculitis. *Semin Diagn Pathol* 2001; 18(1):59-66.
- Ganesan R, Ferryman SR, Meier L, Rollason TP. Vasculitis of the female genital tract with clinicopathologic correlation: a study of 46 cases with follow-up. *Int J Gynecol Pathol* 2000; 19(3):258-65.
- Abu-Farsakh H, Mody D, Brown RW, Truong LD. Isolated vasculitis involving the female genital tract: clinicopathologic spectrum and phenotyping of inflammatory cells. *Mod Pathol* 1994; 7(5):610-5.
- Woywodt A, Schneider W, Morack G, Kettritz R, Goebel U. Necrotizing small-vessel vasculitis confined to the uterine cervix. *Semin Arthritis Rheum* 2000; 29(6):368-72.
- Patel RK, Carrick K. Giant cell arteritis of the female genital tract: report of a case and review of the literature. *South Med J* 2005; 98(4):469-71.
- Marrogi AJ, Gersell DJ, Kraus FT. Localized asymptomatic giant cell arteritis of the female genital tract. *Int J Gynecol Pathol* 1991; 10(1):51-8.
- Long HJ 3rd, Laack NN, Gostout BS. Prevention, diagnosis, and treatment of cervical cancer. *Mayo Clin Proc* 2007; 82(12):1566-74.
- Schiffman M, Castle PE, Jeronimo J, Rodriguez AC, Wacholder S. Human papillomavirus and cervical cancer. *Lancet* 2007; 370(9590):890-907.