

## Mycosis fungoides: epidemiologic study of 17 cases and evaluation of PUVA photochemotherapy\*

### *Micose fungóide: estudo epidemiológico de 17 casos e avaliação da resposta terapêutica à PUVA\**

Ida Duarte<sup>1</sup>

Roberta Buense<sup>2</sup>

Simone Aoki<sup>3</sup>

**Abstract:** BACKGROUND - PUVA photochemotherapy is indicated to treat mycosis fungoides, either as monotherapy in the earlier stages of the disease or in combination with other drugs in more advanced stages of evolution. OBJECTIVES - To evaluate PUVA photochemotherapy response in patients with mycosis fungoides.

METHODS - From January 1996 to November 2003, 17 patients with a diagnosis of mycosis fungoides were seen in the Dermatological Phototherapy Division of Santa Casa de São Paulo, Brazil. PUVA treatment was carried out as monotherapy at early stages of evolution and in combination with other treatments in more advanced cases of mycosis fungoides. The treatment response was evaluated regarding cutaneous clinical and histological improvement.

RESULTS - Fourteen of 16 patients improved after PUVA. The rate of improvement in skin after treatment related to the initial stage of disease presented as follows: five patients (one in stage IA and four in IB) had total control (cure of lesions); four (all IB) had major regression (improvement of 70%-99%); two (IIB and IVA) had moderated improvement (50%-69%); three (IA, IB, IIA) had mild regression (less than 50%); two (IB, IIB) were unaltered. Only one patient had to discontinue treatment due to intense burning.

CONCLUSION - Eighty-seven percent patients responded to PUVA therapy, and 56% presented total control or significant improvement of lesions. The effectiveness of treatment resulted in regression of lesions mainly in early stage cases. PUVA photochemotherapy was a successful and safe treatment, making it a good choice for patients with mycosis fungoides.

Keywords: Lymphoma, T-Cell, cutaneous; Mycosis fungoides; PUVA therapy

**Resumo:** FUNDAMENTOS - A fotoquimioterapia com PUVA é indicada para tratamento da micose fungóide, empregada como monoterapia em estágios precoces ou combinada a outras drogas nos estágios mais avançados da doença.

OBJETIVOS - Avaliação da resposta terapêutica à fotoquimioterapia PUVA em pacientes com micose fungóide.

MÉTODOS - Entre janeiro de 1996 e novembro de 2003 avaliaram-se 17 pacientes com micose fungóide no setor de Fototerapia da Clínica Dermatológica da Santa Casa de São Paulo. A terapia com PUVA foi realizada como monoterapia nos estágios iniciais ou como coadjuvante nos estágios avançados da doença. Avaliou-se o resultado do tratamento quanto ao aspecto clínico das lesões e parâmetros histológicos após tratamento.

RESULTADOS - Quatorze de 16 pacientes responderam à fotoquimioterapia. Relacionando o estadiamento da doença à resposta terapêutica obteve-se o seguinte: cinco pacientes (um em estágio IA e quatro em IB) com controle total (cura das lesões); quatro (todos IB) com melhora intensa (controle de 70-99%); dois (IIB e IVA) com melhora moderada (de 50 a 69%); três (IA, IB, IIA) com melhora discreta (menos 50%); dois (IB, IIB) inalterados (sem resposta). Um paciente teve de descontinuar o tratamento por apresentar intenso ardor.

CONCLUSÃO - Houve resposta à terapia PUVA em 87% dos pacientes, com controle total ou melhora intensa da doença em 56% dos casos. Sua efetividade permitiu regressão das lesões cutâneas, principalmente nos casos precoces. A fotoquimioterapia com PUVA mostrou ser tratamento seguro e efetivo, devendo ser considerado em pacientes com micose fungóide.

Palavras-chave: Linfoma de células T cutâneo; Micose fungóide; Terapia PUVA

Received on August 08, 2005.

Approved by the Consultative Council and accepted for publication on January 16, 2006.

\* Work done at Clínica de Dermatologia da Santa Casa de São Paulo - São Paulo (SP), Brazil.

Conflict of interests: None

<sup>1</sup> Adjunct Professor of the Faculdade de Ciências Médicas da Santa Casa de São Paulo. Head of the Allergy and Phototherapy Division, Dermatology Clinic, Santa Casa de Misericórdia de São Paulo - São Paulo (SP), Brazil.

<sup>2</sup> Graduate student in Dermatology from the Universidade de São Paulo. Dermatologist, volunteer at the Allergy and Phototherapy Division, Dermatology Clinic, Santa Casa de Misericórdia de São Paulo - São Paulo (SP), Brazil.

<sup>3</sup> Trainee at the Dermatology Clinic, Santa Casa de Misericórdia de São Paulo - São Paulo (SP), Brazil.

## INTRODUCTION

Skin T cells are a dynamic population of lymphocytes with distinct surface cell markers. The malignant process of epidermotropic T cells results in the condition generally defined as cutaneous T cell lymphoma (CTCL). Therefore, CTCL represents a lymphoproliferative disease that originates from malignant T cell clones due to changes in their apoptosis process.<sup>1,2</sup>

It is a non-Hodgkin lymphoma with various clinical manifestations, which are frequently difficult to differentiate from one another. There is a possibility of one form developing into another.<sup>3,4</sup>

Major variants of CTCL are grouped as: I) mycosis fungoides and its various subdivisions; II) non-mycosis fungoides CTCL; III) lymphoproliferative immunodeficiency disorder. Thus, mycosis fungoides is defined as a subdivision of CTCL.<sup>5,6</sup>

Neoplastic cells of mycosis fungoides correspond to clones of memory T cells that migrate to the superficial dermis and epidermis, which favors the use of skin-oriented therapies.<sup>7-15</sup>

The treatment of CTCL is still controversial, and various therapeutic methods are proposed to approach it, without an actual consensus on the best treatment to be used. Data from the literature show that successful treatment depends directly on the development phase in which the disease is, besides each patient's individual response. The earlier the therapeutic approach, the better the prognosis.<sup>7</sup>

Among the most acclaimed methods are topical chemotherapy (with nitrogen mustard or carmustine), systemic chemotherapy, topical corticosteroids, radiotherapy, biological immunomodulators (interferon-alpha, interferon-gamma and interleukin 2) and allogenic bone marrow transplant. New therapeutic approaches are in an experimental phase, as for example immunotoxins (denileukin diftitox, said to be selective against neoplastic T cells), more potent immunomodulating cytokins (recombinant IL-12 to exacerbate innate anti-tumor immune mechanisms), immunotherapy using dendritic cells adhered to tumor antigens, immunization with synthetic peptides or DNA plasmids that express a variable region of T-cell beta receptor and, in the future, genetic and protein transduction to correct intracellular defects of neoplastic T cells.<sup>8,9</sup>

Finally, worth of mention is photochemotherapy with PUVA, the object of the present study. The method consists of irradiation of the skin with ultraviolet A rays that is associated with the oral use of psoralen, thus having a phototoxic effect on the skin. PUVA acts mainly as an antiproliferative agent on T lymphocytes (TL).

The present study aims to: 1) characterize the group of patients with mycosis fungoides according to

sex, color and disease staging; 2) evaluate therapeutic response with photochemotherapy (PUVA) on these patients, in the various stages of this skin condition.

## MATERIAL AND METHODS

Seventeen patients with mycosis fungoides were seen at the Dermatology Clinic of Santa Casa de Misericórdia de São Paulo from January 1996 to November 2003. The diagnosis of mycosis fungoides was made by means of clinical and pathological examination.

All patients were referred to the Hematology Division for staging. To that end, the TNM (tumor-node-metastasis system) method was used and adjusted to the CTCL specific parameters. Both local and systemic clinical aspects and grading of the lesion, considering body surface affected and lymph nodes involved, peripheral and visceral blood were taken into consideration (Chart 1).

Treating with photochemotherapy was indicated after staging. PUVA as monotherapy was indicated for patients in initial stages. For more advanced stages, photochemotherapy was prescribed only as adjuvant treatment, as an attempt to improve patients' quality of life.

Photochemotherapy is an association of UVA radiation and phototoxic effects of psoralen given orally, aiming to produce an immunosuppressant effect on the skin. The specifications of the components of this treatment method are as follows:

UVA radiation characteristics: Type A ultraviolet radiation consists of light beams with wavelength ranging from 320 to 400nm. The source of beams are special lamps placed in a one-square-meter cabin, in which the patient is positioned in supine, and eyes protected by radiation filtering glasses in order to avoid eye lesions. The power of the UVA radiation is directly proportional to exposure time and measurement in Joules/cm<sup>2</sup>. Exposure time varies according to patient phototype, individual response to treatment and number of photochemotherapy sessions performed previously.

Psoralen characteristics: the substance utilized in the present study was 8-metoxipsoralen (8-MOP) in a concentration of 0.6mg/kg, prescribed as syrup, given orally, 60 minutes before each phototherapy session. The aim was to boost UVA-ray uptake by the skin, due to its phototoxic effects. All patients were submitted to two or three weekly sessions, according to intensity of the clinical picture.

Treatment results with photochemotherapy were assessed according to clinical parameters of the aspect of skin lesions (macroscopic improvement of infiltrative process, disappearance of erythema, absence of new lesions). In cases with total clinical remission of lesions a new pathological examination

**CHART 1: Staging of mycosis fungoides**

<b>SKIN</b>			
T1 – Patches, papules or plaques < 10% skin surface.			
T2 – Patches, papules or plaques > 10% skin surface.			
T3 – Tumors			
T4 – Erythroderma			
<b>LYMPH NODES</b>			
N0 – no palpable lymph nodes/negative histology			
N1 – palpable peripheral lymph nodes			
(N1o – no histological examination / N1n – negative histology / N1r – reactional histology / N1d – dermopathic lymphadenitis)			
N2 – no palpable peripheral lymph nodes / positive histology			
N3 – palpable peripheral lymph node / positive histology			
<b>INVOLVED INTERNAL ORGANS</b>			
M0 - negative			
M1 - positive (metastasis)			
<b>BLOOD</b>			
B0 – < 5% atypical circulating cells			
B1 – > 5% atypical circulating cells			
<b>STAGING</b>			
Ia -	T1	N0	M0
Ib -	T2	N0	M0
IIa -	T1/2	N1	M0
IIb -	T3	N0/1	M0
III -	T4	N0/1	M0
IVa -	T1/4	N2/3	M0
IVb -	T1/4	N0/3	M1

Source: Cerroni L, Gatter K, Kerl H. An illustrated guide to skin lymphoma. 2nd ed. Massachusetts: Blackwell; 2005, p.10.

of the cutaneous region previously affected was performed. If histological changes compatible to mycosis fungoides had disappeared, the disease was considered under control.

All patients were followed up for a maximum period of 12 months, when they were assessed regarding:

- a) time necessary to begin improvement of skin lesions;
- b) minimum number of sessions to observe signs of therapeutic response;
- c) intensity of therapeutic response: the total number of photochemotherapy sessions performed.

Patients were classified according to progression of skin condition after treatment as:

- 1) unaltered (if there were no changes in skin lesions);
- 2) with mild regression (if there was at least 50% of clinical improvement).
- 3) with moderate improvement (if there was at least 50% to 69% of clinical improvement).
- 4) with major regression (if there was at least

70% a 99% of clinical improvement).

5) with total control of disease (if there was 100% of clinical improvement of skin lesions, in addition to pathological examination with no evidence of the tumor).

The correlation between the therapeutic response and initial staging of mycosis fungoides was also assessed.

## RESULTS

The characteristics of the 17 patients selected for the study are as follows. There were 10 female and seven male patients, therefore with 59% predominance of women over 41% of men (Graph 1).

White was the most prevailing color, representing 76% (13) of patients. There were also three mulatto patients (18%) and one black patient (6%) (Graph 2).

The age of patients treated ranged between 31 and 80 years: mean of 56.6 years.

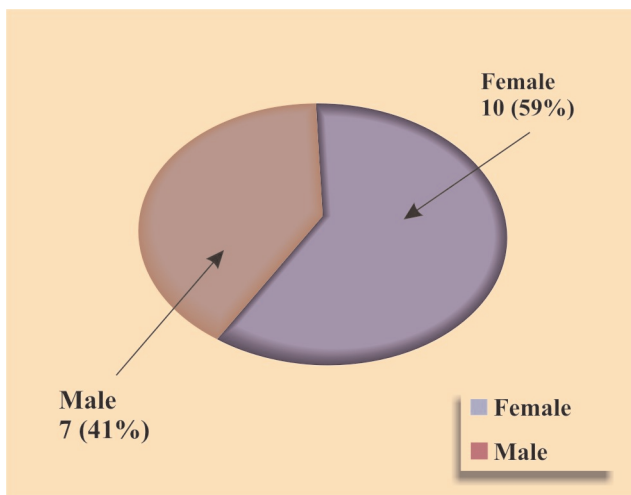
Patients were submitted to disease staging at the beginning of treatment, according to the TNM method, with the following distribution: two patients (12%) were classified as IA; 11 (64%) as IB; one (6%) as IIA; two (12%) as IIB; and one (6%) as IVA (Graph 3).

Treatment time until the beginning of lesion improvement ranged from one to six months. There was also 70% (12 out of 17 patients) who reached initial response in up to two months of treatment.

The minimum number of sessions until the beginning of improvement ranged between three and 50 sessions, with a mean of 16 sessions.

The total number of phototherapy sessions ranged between 13 and 136, with a mean of 57 ses-

**GRAPH 1: Distribution of 17 patients diagnosed as mycosis fungoides per sex (Dermatology Clinic of Santa Casa de São Paulo; 1996-2003)**



sions.

Sixteen patients were followed up during the 12-month period established. Total treatment time ranged from two to 12 months, with a mean of seven months. One patient withdrew treatment due to intolerance to the side effect of intense burning after PUVA applications. The remaining 16 patients ended the study as follows (Graph 4):

- five patients evolved to total disease control, translated by total macroscopic remission of lesions and microscopic assessment, by a pathological examination free of cell changes in the site previously registered as with neoplastic changes;
- four attained major regression;
- two attained moderate improvement;
- three had mild regression;
- two patients remained with unaltered skin lesions.

Treatment results were analyzed according to the initial stage of each patient at the time of diagnosis (Table 1).

Considering the five patients who attained "total control" of the disease, one was IA stage, and four stage IB, that is, all had initial stage disease.

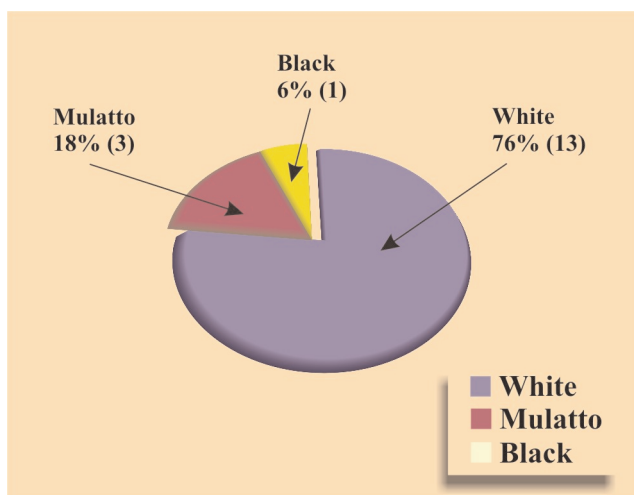
All four patients with "major regression" were stage IB, also with localized disease, in an initial phase.

Regarding the two patients with "moderate improvement", one was stage IIB, and one stage IVA (disseminated disease).

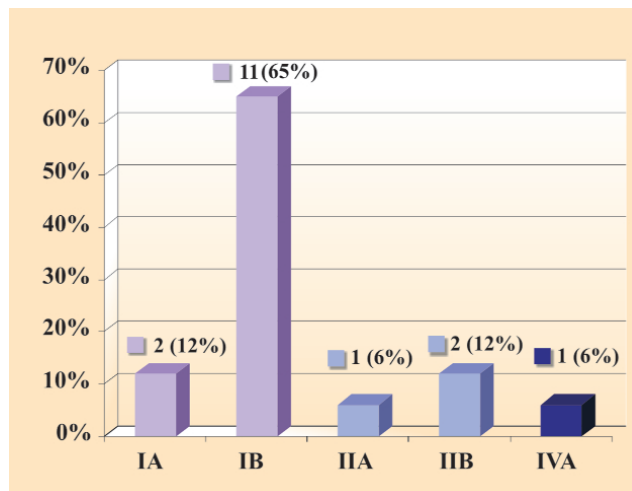
The three patients with "mild regression" were stage IA, IB and IIA, that is, both patients in an initial phase and in an already invasive form of the disease.

As to the two unaltered patients, one was stage IB, and the other was IIB.

**GRAPH 2:** Distribution of 17 patients diagnosed as mycosis fungoides per race (Dermatology Clinic of Santa Casa de São Paulo; 1996-2003)



**GRAPH 3:** Distribution of 17 patients diagnosed as mycosis fungoides per initial staging (Dermatology Clinic of Santa Casa de São Paulo; 1996-2003)



## DISCUSSION

Mycosis fungoides is a type of primary skin lymphoma more common in the general population, totaling 39% of skin lymphomas. An incidence of 0.5 cases/100000 individuals/year was described, and the mean age of patients affected was approximately 56 years.<sup>10,11</sup> Therefore, mycosis fungoides is considered a rare disease in the population, and that is probably the reason for being difficult to epidemiologically characterize this specific non-Hodgkin lymphoma. In 1999, Weinstock et al. published a study showing an incidence of 0.36 cases/100000 individuals/year, between 1973 and 1992. The authors concluded that the incidence rate has been stable throughout the years and that the mortality rate has decreased.<sup>12,13</sup> Another Spanish study, by Morales Suarez-Varela et al., published in 2000, suggested that the incidence of mycosis fungoides cases has grown throughout the years, although the authors considered that the data could represent an mistake, given the concomitant improvement of diagnostic techniques. Few risk factors were identified, but an association with industrial exposure, especially to oils was noticed. A higher risk for developing mycosis fungoides was observed for men and black individuals.<sup>14</sup> A Tunisian study verified prevailing female gender.<sup>11</sup>

In the present study, there were 59% of women, therefore a slight dominance of the gender.

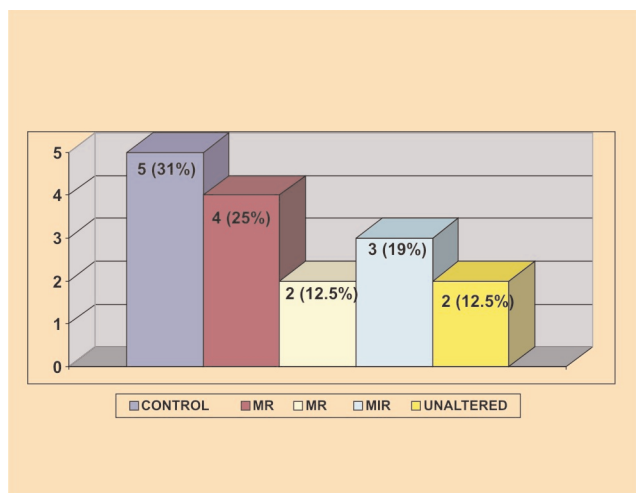
Seventy-six per cent of patients were white, different from what was observed in the literature.

The mean age of patients, at the time of the mycosis fungoides diagnosis was 56.6 years, similar to the findings in the literature.

As to the disease stage at the time of diagnosis,



**GRAPH 4:** Distribution of 16 patients diagnosed as mycosis fungoides per final result of treatment with PUVA chemotherapy (Dermatology Clinic of Santa Casa de São Paulo; 1996-2003)



**Control:** total control of skin lesions, with no histological evidence in skin;

**MR:** major regression (70% - 99% of clinical improvement);

**MR:** moderate improvement (50% - 69 % clinical improvement);

**MIR:** mild regression (< 50% clinical improvement);

**Unaltered:** no regression of skin lesions.

of the 17 patients studied,<sup>13</sup> (76%) were at stages IA and IB of mycosis fungoides; three (18%) between stages IIA and IIB; one (6%) had an invasive form of the disease (stage IVA), characterized by the variant called Sézary syndrome.

The nine (53%) patients with a totally controlled disease or improvement of a minimum of 70% of lesions were initially stages IA and IB, representing 69% of the category. The other four patients fit into stages IIA, IIB and IVA, but, although having a more

severe form of the disease, 75% of them (three patients) had a moderate to mild improvement with treatment. Based on the cases of the present study, patients in initial stages of the disease were more frequent and were exactly those who benefited from photochemotherapy. The results of the present research, like those reported in the literature, make us believe that the therapeutic efficacy of photochemotherapy with PUVA for mycosis fungoides cases depends mainly on the initial stage of the disease; however, even in more advanced cases, this therapeutic option proved to be useful to reduce symptoms of patients studied.

Of the total 16 patients who completed treatment, 14 (87%) had some therapeutic response, with some level of benefit when submitted to photochemotherapy. Of the 17 patients studied, one had intense side effects, with a feeling of burning on lesions, enough to prevent him from continuing treatment.

The mechanisms of action of PUVA therapy have been well studied and defined in the literature. The efficacy of the treatment would be linked both to the direct phototoxic power to destroy neoplastic cells and the capacity of changing the production of cytokines, that is, an immunomodulatory capacity of indirect effects to fight neoplastic cells.

The immunomodulatory action of PUVA therapy is related to its capacity to act on inflammatory cytokines, on monocytes and neoplastic T cells. It has been proven that CD4+ cells treated with PUVA produce cytokines of IFN-gamma and IL-2 type Th1 cells, which, in turn, activate cytotoxic CD8+ T lymphocytes, with direct antitumoral action. The same CD4+ cells simultaneously would stimulate monocytes to produce cytokines, such as IL-8, and to transform themselves into efficient cells that present antitumor antigen to cytotoxic CD8+ lymphocytes. Finally, cytotoxic CD8+ T lymphocytes would be responsible for

**TABLE 1:** Comparison of 16 patients diagnosed as mycosis fungoides, per initial staging of disease and result of PUVA treatment (Dermatology Clinic of Santa Casa de São Paulo; 1996-2003)

Staging Result	IA	IB	IIA	IIB	IVA	Total
C	1	4	-	-	-	5
MR	-	4	-	-	-	4
MI	-	-	-	1	1	2
MIR	1	1	1	-	-	3
Unaltered	-	1	-	1	-	2
<b>Total</b>	<b>2</b>	<b>10</b>	<b>1</b>	<b>2</b>	<b>1</b>	<b>16</b>

C: total control (complete regression of skin lesions, with no histological evidence in skin)

MR: major regression (70% - 99% of clinical improvement);

MR: moderate improvement (50% - 69 % clinical improvement);

MIR: mild regression (< 50% clinical improvement);

Unaltered (no regression of skin lesions)

lysis of neoplastic cells due to the release of Th2 cytokines. Despite all that, the exact molecular mechanism by which photochemotherapy would act on these cellular events has not as yet been elucidated.<sup>11,16,20</sup>

PUVA therapy has proven effective not only in the sense of total neoplastic control or even prolonged disease remission, but in its capacity to offer relevant improvement in quality of life of patients treated. Improvement in the aspect of skin lesions, and the low rate of secondary skin infections was provided to these patients, consequently favoring recovery of their self-esteem and general well-being.<sup>21</sup> A good level of treatment compliance, due to easy administration, good cost/benefit ratio and few side effects during treatment were verified. Still to be considered is the enormous advantage of being able to restart treatment whenever necessary, given its low

toxicity. Its topical action on the neoplastic lesion also allows the association with other therapeutic or systemic methods, if necessary, not interacting with them in a deleterious fashion. For all these reasons, PUVA therapy was considered a good therapeutic option for cases of mycosis fungoides reported in the literature, and confirmed by the present study.

## CONCLUSIONS

PUVA treatment was effective for 87% of patients, of which 56% with total control or significant improvement of the disease. Effectiveness was greater in the initial stages of the disease. Photochemotherapy has proved to be safe and effective, with good patient compliance, and therefore should be considered for individuals with mycosis fungoides. □

## REFERENCES

1. Heald PW, Yan SL, Edelson RL, Tigelaar R, Picker LJ. Skin selective lymphocyte homing mechanisms in the pathogenesis of leukemic cutaneous T-cell lymphoma. *J Invest Dermatol.* 1993; 101:222-7.
2. Nickeloff BJ, Griffiths C. Intraepidermal but not dermal T-lymphocytes are positive for a cell-cycle associated antigen Ki-67 in mycosis fungoides. *Am J Pathol.* 1990; 136:261-3.
3. Clendenning WE. Mycosis fungoides-relationship to malignant cutaneous reticulosis and the Sézary syndrome. *Arch Dermatol.* 1964; 89:785-9.
4. Schein P. NIH Conference: Clinical features of cutaneous T cell lymphoma. *Ann Intern Med.* 1975; 83:534-52.
5. Kim YH, Jensen RA, Watanabe GL, Vanglese A, Hoppe RT. Clinical stage IA (limited plaque) mycosis fungoides: A long-term outcome analysis. *Arch Dermatol.* 1996;132:1309-13.
6. Kikuchi A. Parapsoriasis en plaques: Its potential for progression to malignant lymphoma. *J Am Acad Dermatol.* 1993;29:419-22.
7. Apisarnthanarax N, Talpur R, Duvic M. Treatment of cutaneous T cell lymphoma: current status and future directions. *Am J Clin Dermatol.* 2002; 3:193-215.
8. Vonderheid EC. Treatment planning in cutaneous T cell lymphoma. *Dermatol Ther.* 2003; 16: 276-82.
9. Lain T, Talpur R, Duvic M. Long term control of mycosis fungoides with topical bexarotene. *Int J Dermatol.* 2003; 42:238-41.
10. Weinstock MA, Horn JW. Mycosis fungoides in the United States: increasing incidence and descriptive epidemiology. *JAMA.* 1988; 260:42-6.
11. Faza B, Goucha S, Zermoni R, Zegloui S, Zghal M, Kennou H, et al. Mycosis fungoides: study of a series of Tunisian cases. *Tunis Med.* 2002;80:40-5.
12. Weinstock MA, Reyner JF. The changing survival of patients with mycosis fungoides: a population-based assessment of trends in the United States. *Cancer.* 1999;85:208-12.
13. Weinstock MA, Gardstein B. Twenty-year trends in the reported incidence of mycosis fungoides and associated mortality. *Am J Public Health.* 1999;89:1240-4.
14. Morales S, Varela MM. Mycosis fungoides: review of epidemiological observations. *Dermatology.* 2000; 201:21-8.
15. Epstein EH, Levin DL, Croft JD, Lutzner MA. Mycosis fungoides - survival, prognostic features, response to therapy and autopsy findings. *Medicine (Baltimore).* 1972;51:61-72.
16. Tran D, Kwok YK, Goh CL. A retrospective review of PUVA therapy at the National Skin Center of Singapore. *Photodermatol Photoimmunol Photomed.* 2001;17:164-7.
17. Tokura Y, Seo N, Yagi H, Takigawa M. Photoactivational cytokine-modulatory action of 8-methoxypsoralen plus ultraviolet A in lymphocytes, monocytes, and cutaneous T cell lymphoma cells. *Ann NY Acad Sci.* 2001;941:185-93.
18. Yoo EK, Rook AH, Elinitras R, Gasparro FF, Vowels BR. Apoptosis induction by ultraviolet light A and Photochemotherapy in cutaneous T-cell Lymphoma: Relevance to mechanism of therapeutic action. *J Invest Dermatol.* 1996;107:235-41.
19. Gathers RC, Scherschun L, Maleck F, Fivenson DP, Lin HW. Narrowband UVB phototherapy for early stage mycosis fungoides. *J Am Acad Dermatol.* 2002; 47:191-7.
20. Connors JM, Hsi ED, Foss FM. Lymphoma of the skin. *Hematology (Am Soc Hematol Educ Program).* 2002; 263-82.
21. Chiarion-Sileni V, Bononi A, Forrora CW, Sorroni M, Alaibac M, Ferrazi E, et al. Phase II trial of interferon- $\alpha$ -2a plus psoralen with ultraviolet light A in patients with cutaneous T-cell lymphoma. *Cancer.* 2002;95:569-75.

## MAILING ADDRESS:

Ida Duarte

Rua Diana, 820 / 151

05019-000 - São Paulo - SP

E-mail: idaduarte@terra.com.br