

## Action of hyperbaric oxygenation in the rat skin flap<sup>I</sup>

Fabricio Valandro Rech<sup>I</sup>, Anna Luiza Negrini Fagundes<sup>II</sup>, Ricardo Santos Simões<sup>III</sup>, Rinaldo Florencio-Silva<sup>IV</sup>, Gisela Rodrigues da Silva Sasso<sup>V</sup>, Murched Omar Taha<sup>VI</sup>, Djalma José Fagundes<sup>VI</sup>

DOI: <http://dx.doi.org/10.1590/S0102-865020150040000001>

<sup>I</sup>Fellow Master degree, Postgraduate Program in Interdisciplinary Surgical Science, Paulista School of Medicine (EPM), Federal University of Sao Paulo (UNIFESP), Brazil. Acquisition of data, technical procedures, manuscript preparation.

<sup>II</sup>Resident, Pediatric Intensive Medicine, Pediatric Department, UNIFESP, Sao Paulo-SP, Brazil. Technical procedures, acquisition of data.

<sup>III</sup>Fellow PhD degree, Postgraduate Program in Morphology, Department of Morphology and Genetic, UNIFESP, Sao Paulo-SP, Brazil. Interpretation of data, manuscript writing.

<sup>IV</sup>Fellow PhD degree, Postgraduate Program in Morphology, Department of Morphology and Genetic, UNIFESP, Sao Paulo-SP, Brazil. Histopathologic examinations, acquisition of data, critical revision.

<sup>V</sup>Fellow PhD degree, Postgraduate Program in Morphology, Department of Morphology and Genetic, UNIFESP, Sao Paulo-SP, Brazil. Acquisition of data, critical revision.

<sup>VI</sup>PhD, Associate Professor, Operative Technique and Experimental Surgery Division, Department of Surgery, UNIFESP, Sao Paulo-SP, Brazil. Conception, design, intellectual and scientific content of the study; critical revision

---

### ABSTRACT

**PURPOSE:** To evaluate the morphology, necrotic area and collagen content in skin flaps of rats subjected to hyperbaric oxygenation (HBO).

**METHODS:** Forty adult rats were divided into four groups: GEC - epilated; GE/HBO – epilated subjected to HBO; GER – epilated submitted to skin flap (2 cm in width /8 cm length in the dorsal area) and GER/HBO - epilated, subjected to skin flap and HBO. HBO (2.4 ATA) was performed for two hours during seven consecutive days. In the eighth day, the rats were anesthetized and the skin flaps were removed and separated into three portions, relative to pedicle fixation. The material fixed in 10% formalin was processed for paraffin embedding; sections were stained by H.E and subjected to picrosirius-red method. The slides examined under light microscopy for evaluation of the collagen content in polarized light microscope and ImageLab<sup>®</sup> software (Bio-Rad).

**RESULTS:** The data showed larger area of necrosis and lower levels of collagen in the three regions of the GER group, whereas in the GER/HBO group the collagen content was similar to the GEC and GE/HBO groups.

**CONCLUSION:** Hyperbaric oxygenation reduced the area of necrosis and preserved the morphology and collagen content in skin flaps of rats.

**Key words:** Skin. Hyperbaric Oxygenation. Collagen. Wound Healing. Rats.

---

## Introduction

Advances in plastic surgery techniques have enabled the reconstruction of large defects caused by injury, among which we highlight the use of random skin flaps. However, the limiting factor for the use of skin flaps is the unpredictability of its distal vascularization, which can lead to irreversible microcirculation, followed by partial or complete necrosis of the flaps and making wound more susceptible to infection. Therefore, improving the viability of random flaps, especially in its distal end, has been an important goal for the success of this technique<sup>1</sup>.

Molecular oxygen seems to play a central role in the wound healing process. The hyperoxia caused by hyperbaric oxygenation (HBO) is responsible to increase tissue tolerance to ischemia, and improve biological defense mechanisms against free radicals, as well as the capacity of tissues to withstand ischemia<sup>2</sup>. In addition, HBO has a protective effect on the microcirculation, possibly by counteracting the deleterious effects caused by leukocytes activation on the vascular endothelium. This ability can prevent the action of neutrophils and stimulate angiogenesis, as well as cell proliferation and collagen synthesis.

Rocha *et al.*<sup>3</sup> noted that HBO is related to the decrease in the area of necrosis in skin wounds. In addition, the expression of VEGF in the flaps showed no significant differences between the study groups, suggesting that oxygen diffusion through the interstitial space (HBO) may be a factor in the decrease of apoptosis<sup>4</sup>.

The effects of HBO improving the survival of a random skin flap are well known. Thus, in this study, our aim was to investigate the role of HBO on the necrosis area and collagen fibers content in a random rat's skin flaps from a modified McFarlane flap design<sup>5</sup>.

## Methods

The Ethics Committee of the Federal University of Sao Paulo (UNIFESP), under the number 431182, approved the experimental protocol.

Forty rats (*Rattus norvegicus albinus*), weighing between 280 and 320g, were kept in the lab facility of the Department of Regional Integrated University of Erechim (URI). The animals were housed in individual cages and maintained in an environmentally controlled laboratory (12-h light/dark cycle at 25°C), with access to food and water *ad libitum*.

After an adaptation period, the animals were randomized into four groups: GEC (n = 10) animals underwent epilation;

GE/HBO (n = 10) animals underwent epilation and subjected to HBO; GER (n = 10) animals underwent epilation and subjected to skin flaps; GER/OHB (n = 10) animals underwent epilation and subjected to skin flaps and HBO.

### *Anesthetic procedure and analgesia*

After six and four hours of fasting for solid and liquid diets, respectively, the animals received intramuscular injection of acepromazine (5 mg/Kg). After ten minutes, the rats received a combined intramuscular injection of ketamine (50 mg/Kg) and xylazine (10 mg/Kg). The animals received aspirin (100 mg/Kg) diluted in water until the day of euthanasia, without antibiotic prophylaxis.

### *Operative procedures*

After anesthesia, the animals were epilated on dorsal area under antiseptic condition (0.2% chlorhexidine gluconate as antiseptic solution). A rectangular cutaneous area comprising 2 cm in width /8 cm length (in proportion 1x4) was bounded with permanent pen marker. On the limits of the bounded skin area, an incision made on the three edges of the bounded area using a scalpel blade (n° 15), maintaining the continuity of the flap by its cranial portion, according to the standardized model of McFarlane<sup>1</sup>. The flap was composed of epidermis, dermis, adipose tissue and *panniculus carnosus* (skeletal muscle), which raised and maintained fixed only by its pedicle (cephalic portion of the rectangle). The flap repositioned in its original bed and sutured with interrupted stitches of 4-0 nylon monofilament.

### *Hyperbaric chamber*

The animals were placed in the hyperbaric chamber in accordance with their group. The hyperbaric oxygenation (HBO) was carried out in an appropriate chamber for animal experimentation, developed by the team involved in this research<sup>6</sup>. Before final pressurization, oxygen injected into the chamber for 5 min displaced the environment air inside the camera and allowed a 100% atmosphere of oxygen. The oxygen pressure increased at constant rate to attain the pressure of 2.4 ATA (Absolute atmospheres).

### *Procedure of hyperbaric oxygenation*

Hyperbaric oxygenation was performed in the subgroups GE/HBO and ER/HBO, daily. Ten animals, in individual stalls

for each section, stayed under continuous oxygen flow. Each daily section lasted two hours during seven consecutive days, always performed at the same hour<sup>6</sup>.

The animals of GEC and GER groups were placed in the hyperbaric chamber, but were not subjected to hyperbaric oxygenation procedure.

#### *Postoperative follow up*

The clinical conditions of all animals were daily observed during the postoperative period. The wounds were daily examined to identify signs of inflammation, discharge, dehiscence or infection.

#### *Photographic documentation procedure*

Pictures of the dorsal area of the animals were taken at a standardized distance on the seventh postoperative day by a digital camera (Sony DSC - F717). The pictures were used in order to assess the areas of necrosis of skin flaps, as well to support the description of the macroscopic appearance of the flap and the surrounding area.

#### *Procedure of incisional biopsies*

On the eighth postoperative day, the animals were anesthetized by ketamine (50 mg/Kg) and xylazine (10 mg/Kg). After carefully positioning the rats in the operating board, incisional biopsies of 1cm x 1cm, were collected at the proximal, middle and distal area of the flap. Then, the areas were defined as follows: Area A - proximal; Area B - middle, located between the proximal and distal areas; Area C - distal to the pedicle implantation and area D – fragment withdrawn outside flap located at a distance of two centimeters from the suture line (area D - control fragment). The samples were immediately immersed in fixative solution and submitted to standard histological processing.

#### *Euthanasia*

After collection of incisional biopsies, still under anesthesia, the animals were euthanized by anesthetic depth. All the biological material was discarded in accordance with the current facilities rules (CEUA – Ethics Committee on Animal Use) of the URI.

#### *Histological processing*

Skin samples were fixed in 10% formaldehyde for 12 hours and then processed for paraffin embedding. Sections (5 µm thick) were stained with hematoxylin-eosin (H.E) or to the picrosirius red method.

#### *Evaluation criteria of the necrosis area*

The software Image-Pro Plus® (Media Cybernetics Products - CA - USA) captured the pictures taken on the eighth postoperative day. The area of necrosis was defined by dark color and the formation of scabs. Based on the difference of color the software calculated the percentage of necrotic area in each animal. The results were presented as mean and standard deviation.

#### *Morphological evaluation criteria*

The evaluation of the slides was performed at the Department of Histology, UNIFESP/EPM. Images were captured through a high-resolution camera, (AxioCam-MCR, Carl Zeiss) adapted to a light microscope under objective set at 40X and transmitted to a computer equipped with a Windows 8 program. The quantification of collagen was carried out in the slides subjected to the picrosirius red method and subsequently analyzed through polarized light microscopy (Carl Zeiss). The evaluation was determined by quantitative method (%) and the ImageLab® (Bio-Rad) software was used for the analysis of digital images.

#### *Evaluation of slides stained with hematoxylin and eosin (HE)*

All slides were evaluated by the same researcher, under a Carl Zeiss microscope with objectives ranging magnification from 4X to 40X. The parameters used for microscopic evaluation were based on the criteria described by d'Acampora *et al.*<sup>7</sup>, and by a well-established numerical value we added to the obtained data. These numerical values ranged from 0 to 3, depending on the degree of injury, which are detailed below (Chart 1).

**CHART 1** - Criterion and value to classify the degree of skin injury (modified from d'Acampora *et al.*<sup>7)</sup>.

|    |  |
|----|--|
| a. | Presence (1) or not of edema (0)   |
| b. | Presence (1) or not of vascular proliferation (0)  |
| c. | Presence (1) or not of vascular congestion (0)   |
| d. | Presence or absence of neutrophilic infiltrate, when absent (0), mild (1), moderate (2) or severe (3)            |
| e. | Presence or absence of macrophages, when absent (0), mild (1), moderate (2) or severe (3)                        |
| f. | Presence or not of lymphocytic infiltrate, classifying it, when absent (0), mild (1), moderate (2) or severe (3) |
| g. | Presence (1) or not the fibrosis (0)   |
| h. | Presence (1) or not of granulation tissue (0)  |
| i. | Presence (1) or not of fibroblast proliferation (0)  |
| j. | Presence (1) or not of body granuloma (0)  |

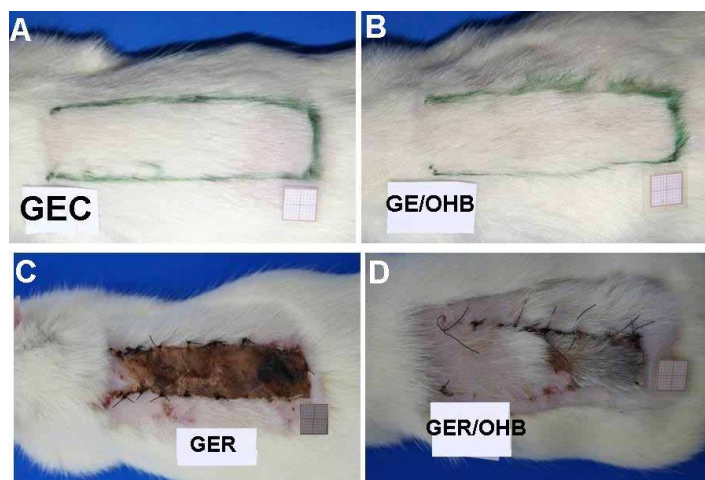
### Statistical study

Data were subjected to analysis of variance (ANOVA) complemented by the Kruskal-Wallis test. Statistical significance was considered at  $p < 0.05$ .

### Results

#### Macroscopic evaluation

The GEC and GE/HBO groups presented areas of filled skin, which was difficult to demarcate the epilated area (Figures 1A and B), whereas the ER group presented necrosis (fibrin crust) in the area of the flap (Figure 1C). We also noted lower crust in the area where hyperbaric oxygenation was made (Figure 1D). Quantitative evidence of necrosis (%) is shown in Table 1.



**FIGURE 1** - Photographs showing the flap areas in all groups of study. Note a significant increase in tissue viability in the group subjected to skin flap and hyperbaric oxygenation (GER/HBO), as well as an extensive area of necrosis in the GER group.

**TABLE 1** - Percentage (%) of the area of necrosis of all groups.

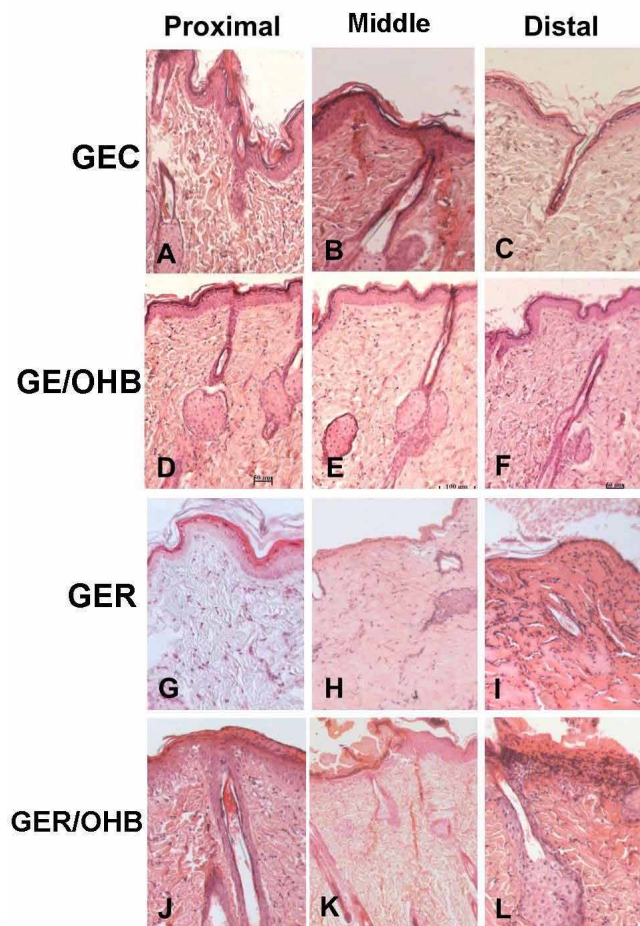
| Region   | GEC     | GE/HBO  | GER                    | GER/HBO               |
|----------|---------|---------|------------------------|-----------------------|
| Proximal | 0.0±0.0 | 0.0±0.0 | 24.6±10.6 <sup>c</sup> | 5.6±1.6 <sup>d</sup>  |
| Middle   | 0.0±0.0 | 0.0±0.0 | 84.5±5.9 <sup>b</sup>  | 7.5±3.7 <sup>d</sup>  |
| Distal   | 0.0±0.0 | 0.0±0.0 | 98.5±3.7 <sup>a</sup>  | 15.4±2.5 <sup>c</sup> |

\*a>b>c>d;  $p < 0.05$

#### Microscopic evaluation

The EC and GE/HBO groups presented the same cutaneous microarchitecture, which was formed by a keratinized stratified squamous epithelium and a dermis consisting of connective tissue (Figure 2A to C). It should be noted that the dermis of the GE/HBO group evidenced a greater amount of fur (Figure 2D to F). On the other hand, the groups subjected to skin flaps (GER and GER/HBO) presented in the third proximal region of the skin, the same microarchitecture of the GEC and GE/HBO groups (Figure 2G to J). However, the middle third region of the skin in the GER group evidenced a thinner cutaneous area with scarce hair follicles, whereas in the distal third region it was observed the presence of a fibrin-leukocyte crust and the dermis presenting denatured collagen, as well as leukocyte infiltrate (Figure 2H and I). Meanwhile, the skin of the GR/HBO group was similar to the GEC group, except in the distal third region, where we noticed a small area with leukocyte crust and a dermis presenting denatured collagen (Figure 2K and L). The data obtained from the evaluation of histological lesions are shown in Table 2 and the content of collagen in Table 3.





**FIGURE 2** - Photomicrographs showing skin transverse sections of rats from all groups of study. Note the skin of GER group (**H** and **I**) when compared with the GER/HBO group (**K** and **L**). Also, observe the presence of a greater amount of hair follicles in groups subjected to hyperbaric oxygenation (GE/HBO) HE x100.

**TABLE 2** - Means and standard deviations of the data obtained from the histopathological lesions observed in the proximal third region of the skin flaps of the animals in all groups of study.

| Region   | GEC     | GE/HBO  | GER                   | GER/HBO              |
|----------|---------|---------|-----------------------|----------------------|
| Proximal | 0.0±0.0 | 0.0±0.0 | 8.6±1.2 <sup>a</sup>  | 2.4±0.6 <sup>c</sup> |
| Middle   | 0.0±0.0 | 0.0±0.0 | 11.5±2.7 <sup>a</sup> | 4.4±1.5 <sup>b</sup> |
| Distal   | 0.0±0.0 | 0.0±0.0 | 14.8±5.3 <sup>a</sup> | 8.1±3.7 <sup>a</sup> |

\*a>b>c; p<0.05

**TABLE 3** - Means and standard deviations of the data obtained from the percentage of collagen (%), in the dermis of rats from all groups of study.

| Region   | GEC                    | GE/HBO                 | GER                    | GER/HBO                |
|----------|------------------------|------------------------|------------------------|------------------------|
| Proximal | 85.2±15.3 <sup>a</sup> | 86.7±16.3 <sup>a</sup> | 78.5±12.5 <sup>a</sup> | 85.3±12.4 <sup>a</sup> |
| Middle   | 84.4±12.3 <sup>a</sup> | 86.5±14.2 <sup>a</sup> | 55.5±12.6 <sup>b</sup> | 81.5±16.7 <sup>a</sup> |
| Distal   | 81.4±10.5 <sup>a</sup> | 82.6±17.8 <sup>a</sup> | 32.8±12.5 <sup>c</sup> | 72.2±16.7 <sup>a</sup> |

\*a>b>c; p<0.05

## Discussion

Hyperbaric oxygenation therapy (HBOT) has been widely used in clinical practice, especially in plastic surgery and skin grafts for the treatment of chronic wounds. Furthermore, studies have shown that HBOT preconditioning provides satisfactory results in animal models of stroke<sup>8</sup>, spinal cord injury<sup>9</sup>, as well as in stem cell transplantation<sup>10</sup> and skin flaps<sup>11</sup>. In China, hyperbaric oxygenation therapy has been widely applied in the treatment of related hypoxia/ischemia diseases, including decompression sickness, carbon monoxide poisoning, and diabetic foot ulcer, among others<sup>12</sup>.

Our study showed that the histological aspects of skin of animals submitted only to HBO (GE/HBO) was similar to the control group (GEC), except for the presence of numerous hair follicles in the E/HBO group, which indicate that HBO has trophic effects and stimulates hair growth in the skin. Moreover, the skin flaps of the animals subjected to HBO (GER/HBO) presented a smaller area of necrosis than the ones not submitted to its intervention, suggesting a favorable action of HBO in the skin viability. Actually, these data were expected, since others studies report that HBO improves skin grafts, whereas other authors have shown that HBO preconditioning improves this capacity<sup>11-13</sup>.

The contribution of this study was to assess skin flaps in three (proximal, middle and distal) regions in relation to the vascular pedicle, as well as an evaluation of collagen content. As one would expect all regions showed histological changes. However, the caudal region of the vascular pedicle (distal) showed the greatest histological changes, which was more pronounced in the group not subjected to HBO (GER). It should be mentioned, that all regions presented attenuation of histopathological changes with the application of HBO. Despite the beneficial effects of the treatment of wounds or skin flaps with HBO have been well described<sup>14-15</sup>, early studies did not emphasize detailed regions as did in our study.

Regarding collagen content, it was observed a marked decrease in the middle and caudal regions of the GER group, while the hyperbaric oxygenation inhibited it, since the concentration in the three areas of group ER/HBO showed no significant differences, compared to controls (GEC and GE/HBO). Lv *et al.*<sup>16</sup> reported that treatment with HBO counteracted fibrous adhesions, as it inhibited inflammation and collagen deposition, preventing epidural scar adhesion in rat. Collagen fibers is an extracellular matrix constituent of the dermis and is synthesized by fibroblasts, while inflammatory processes related to the enzymatic action of metalloproteinases and collagenase inhibit it<sup>17</sup>.

In our study, we believe that hyperbaric oxygenation preserved the collagen fibers in the regions investigated due to inhibition of the inflammatory process. Numerous studies report that the improvement patchwork undergoing HBO is due to the significant increase in vascular angiogenesis, since it enhances the production of vascular endothelial growth factor (VEGF), which helps to provide nutrients to the cells, blockage of enzyme activation and the decrease in the collagen metabolism<sup>4,18</sup>.

Despite that, there has been controversy about the angiogenic properties of HBO. In skin wounds, HBO is related to the improvement of breaking strength of lesions and angiogenesis stimulation<sup>19-20</sup>. It is believed that the HBO angiogenesis properties are due to increased oxygen tension that may persist for several hours after HBO<sup>14,21</sup>. However, some authors suggest that the high rate of oxygen increases the production of free radicals, which could increase necrosis<sup>15</sup>, whereas others suggest that treatment with HBO causes peripheral arteriolar vasoconstriction<sup>19</sup>.

It should be mentioned that, hyperbaric oxygenation has some unwanted side effects such as barotrauma of the middle ear, which is observed in more than 2% of patients; it can be prevented or at least minimized by the insertion of tympanostomy tubes, and claustrophobia. Other rare side effects are related to pulmonary dyspnea, cough and sore inspiration<sup>22</sup>. Despite these side effects, it is believed that hyperbaric oxygenation leads to beneficial hemodynamic effects<sup>23-24</sup>.

## Conclusion

Hyperbaric oxygenation reduced the area of necrosis and preserved the morphology and collagen of the skin flaps in rats.

## References

1. Suartz CV, Gaiba S, França JP, Aloise AC, Ferreira LM. Adipose-derived stem cells (ADSC) in the viability of random skin flap in rats. *Acta Cir Bras.* 2014;29(Supl 2):6-9. doi.org/10.1590/S0102-86502014001400002.
2. Bhutani S, Vishwanath G. Hyperbaric oxygen and wound healing. *Indian J Plast Surg.* 2012;45(2):316-24. doi: 10.4103/0970-0358.101309.
3. Rocha FP, Fagundes DJ, Pires JA, Rocha FST. Effects of hyperbaric oxygenation and N-acetylcysteine on the survival of random-pattern skin flaps in rats. *Rev Bras Cir Plast.* 2011;26(4):555-60. doi.org/10.1590/S1983-51752011000400003.
4. Rocha FP, Fagundes DJ, Pires JA, Rocha FST. Does hyperbaric oxygenation have a protective effect on random skin flaps? An immunohistochemical study of cellular apoptosis and vascular endothelial growth factor. *Rev Bras Cir Plast.* 2013;28(2):183-90. doi.org/10.1590/S1983-51752013000200002.
5. McFarlane RM, Deyoung G, Henry RA. The design of a pedicle flap in the rat to study necrosis and its prevention. *Plast Reconstr Surg.* 1965;35:177-82. PMID: 14264468.
6. Rech FV, Fagundes DJ, Hermanson R, Rivoire HC, Fagundes AL. A proposal of multiplace hyperbaric chamber for animal experimentation and veterinary use. *Acta Cir Bras.* 2008; 23(4):384-90. doi.org/10.1590/S0102-86502008000400014.
7. D'Acampora AJ, Vieira DSC, Silva MT, Farias DC, Tramonte R. Morphological analysis of three wound-cleaning processes on potentially contaminated wounds in rats. *Acta Cir Bras.* 2006;21(5):332-40. doi.org/10.1590/S0102-86502006000500011.
8. Cheng O, Ostrowski RP, Wu B, Liu W, Chen C, Zhang JH. Cyclooxygenase-2 mediates hyperbaric oxygen preconditioning in the rat model of transient global cerebral ischemia. *Stroke.* 2011;42:484-90. doi: 10.1161/STROKEAHA.110.604421.
9. Dong H, Xiong L, Zhu Z, Chen S, Hou L, Sakabe T. Preconditioning with hyperbaric oxygen and hyperoxia induces tolerance against spinal cord ischemia in rabbits. *Anesthesiology.* 2002;96:907-12. PMID: 11964598.
10. Wang L, Zhao S, Mao H, Zhou L, Wang ZJ, Wang HX. Autologous bone marrow stem cell transplantation for the treatment of type 2 diabetes mellitus. *Chin Med J* 2011;124:3622-8. PMID: 22340214.
11. Kang N, Hai Y, Liang F, Gao CJ, Liu XH. Preconditioned hyperbaric oxygenation protects skin flap grafts in rats against ischemia/reperfusion injury. *Mol Med Rep.* 2014;9(6):2124-30. doi: 10.3892/mmr.2014.2064.
12. Zhou YY, Liu W, Yang YJ, Lu GD. Use of hyperbaric oxygen on flaps and grafts in China: analysis of studies in the past 20 years. *Undersea Hyperb Med.* 2014;41(3):209-16. PMID: 24984315.
13. Qi Z1, Gao CJ, Wang YB, Ma XM, Zhao L, Liu FJ, Liu XH, Sun XJ, Wang XJ. Effects of hyperbaric oxygen preconditioning on ischemia-reperfusion inflammation and skin flap survival. *Chin Med J.* 2013;126(20):3904-9. PMID: 24157154.
14. Zhang T, Gong W, Yang S, Zhang K, Yin D, Xu P, Jia T. Efficacy of hyperbaric oxygen on survival of random pattern skin flap in diabetic rats. *Undersea Hyperb Med.* 2007;34:335-9. PMID: 18019084.
15. Rocha FP, Fagundes DJ, Pires JA, da Rocha FS. Effects of hyperbaric oxygen and N-acetylcysteine in survival of random pattern skin flaps in rats. *Indian J Plast Surg.* 2012;45(3):453-8. doi: 10.4103/0970-0358.105941.
16. Lv P, Zhao J, Su W, Liang X, Zhang K. An experimental novel study: hyperbaric oxygen treatment on reduction of epidural fibrosis via down-regulation of collagen deposition, IL-6, and TGF-β1. *Eur J Orthop Surg Traumatol.* 2014 Jul 17. [Epub ahead of print]. doi: 10.1007/s00590-014-1509-x.
17. Marcos-Garcés V, Molina Aguilar P, Bea Serrano C, García Bustos V, Benavent Seguí J, Ferrández Izquierdo A, Ruiz-Saurí A. Age-related dermal collagen changes during development, maturation and ageing-a morphometric and comparative study. *J Anat.* 2014;225(1):98-108. doi: 10.1111/joa.12186.
18. Daniel RA, Cardoso VK, Góis Jr E, Parra RS, Garcia SB, Rocha JJ, Féres O. Effect of hyperbaric oxygen therapy on the intestinal ischemia reperfusion injury. *Acta Cir Bras.* 2011;26(6):463-9. doi.org/10.1590/S0102-86502011000600010.
19. Ulkür E, Yüksel F, Açikel C, Celiköz B. Effect of hyperbaric oxygen on pedicle flaps with compromised circulation. *Microsurgery.* 2002;22(1):16-20. doi: 10.1002/micr.22004.
20. Richards L, Lineaweaver WC, Stile F, Zhang J, Zhang F. Effect of hyperbaric oxygen therapy on the tubed pedicle flap survival in a rat model. *Ann Plast Surg.* 2003;50:51-6. PMID: 12545109.
21. Ulkür E, Karagoz H, Ergun O, Celiköz B, Yildirim S, Yildirim S. The effect of hyperbaric oxygen therapy on the delay procedure. *Plast Reconstr Surg.* 2007;119:86-94. doi: 10.1097/01.prs.0000244829.68008.21.
22. Camporesi EM. Side effects of hyperbaric oxygen therapy. *Undersea*

- Hyperb Med. 2014;41(3):253-7. PMID: 24984321.
23. Pedoto A, Nandi J, Yang ZJ, Wang J, Bosco G, Oler A, Hakim TS, Camporesi EM. Beneficial effect of hyperbaric oxygen pretreatment on lipopolysaccharide-induced shock in rats. Clin Exp Pharmacol Physiol. 2003;30(7):482-8. doi: 10.1046/j.1440-1681.2003.03865.x.
24. Camporesi EM, Bosco G. Mechanisms of action of hyperbaric oxygen therapy. Undersea Hyperb Med. 2014;41(3):247-52. PMID: 24984320.
- 

**Correspondence:**

Djalma José Fagundes  
Rua Camé, 244/33  
03121-020 São Paulo – SP Brasil  
Tel.: (55 11)6604-3186  
Fax: (55 11)6604-3147  
djfagundes.dcir@epm.br

Received: Dec 19, 2014

Review: Feb 20, 2015

Accepted: Mar 18, 2015

Conflict of interest: none

Financial source: none

<sup>1</sup>Research performed at Interdisciplinary Surgery Science Postgraduate Program, Operative Technique and Experimental Surgery Division, Department of Surgery, Federal University of Sao Paulo (UNIFESP), Brazil and Department of Regional Integrated University of high Uruguai and Missions, Erechim (URI).