

Peroneal nerve reconstruction by using glycerol-preserved veins. Histological and functional assessment in rats¹

Armando dos Santos Cunha^I, Marcio Paulino Costa^{II}, Ciro Ferreira Da Silva^{III}

^IFellow PhD degree, Posgraduate Program in Medicine (Surgical Clinic), USP, Sao Paulo, Brazil. Main author, designed the research, surgical procedures, analyzed the data, manuscript writing.

^{II}Assistant Professor, Department of Plastic Surgery, Faculty of Medicine, USP, Sao Paulo, Brazil. Interpretation of data, critical revision.

^{III}Full Professor, Department of Cell Biology and Development, Institute of Biomedical Sciences, USP, Sao Paulo, Brazil. Histological analysis, critical revision.

ABSTRACT

PURPOSE: To compare the degree of neural regeneration in rats upon interposition of autologous nerve graft, autogenous vein, glycerol-preserved autogenous vein, and glycerol-preserved allogeneic vein using qualitative and quantitative histological analyses as well as functional assessments.

METHODS: Peroneal nerves were reconstructed differently in four groups of animals. Functional assessments were performed pre- and postoperatively for a period of six weeks. After six weeks, the animals were sacrificed and histological evaluations were performed.

RESULTS: Histological patterns of autogenous veins without preservation showed pronounced neoangiogenesis and extensive axonal rarefaction, as confirmed by axonal counting and functional assessments. Glycerol-preserved veins had results similar to the control.

CONCLUSIONS: Glycerol-preserved autogenous or allogeneic veins showed similar results to autograft results. The autogenous vein (without preservation in glycerol) presented histological and functional outcomes statistically lower than other groups.

Key words: Peroneal Nerve. Peripheral Nerves/surgery. Nerve Regeneration. Reconstructive Surgical Procedures. Glycerol. Blood Vessels. Transplantation, Homologous. Rats.

Introduction

Nerve injuries lead to functional deficits. It is possible to perform primary nerve suture according to the severity and extent of the area involved. The described procedure of neural repair confers the best histological and functional outcomes, followed by autograft^{1,2}. Autografts are capable of guiding axonal growth and connecting the proximal and distal ends of the stump. This property decreases the tension on the suture line, which is responsible for inhibiting nerve regeneration¹. However, some limitations exist concerning the use of autograft: (1) It always induces donor area morbidity and (2) Extensive neural tissue loss demands a large amount of autologous tissue that sometimes is unavailable². Tubing chambers are an alternative to autograft, and the main advantage of this procedure is decreased morbidity of the donor area².

These chambers combine the proximal and distal stumps, which enable the axons to regenerate within them². The tubes provide mechanical support, thus decreasing the tension between the stumps and the amount of sutured material, an effect that reduces also the scarring response³. An additional advantage of this technique is the possibility to experimentally manipulate the neural microenvironment to administer drugs that potentially stimulate regeneration³.

Several materials can be employed as tubing chambers, including vessels³. Experimental and clinical studies have assessed the chemotactic activity that vessels exert on the distal neural stump, even upon preservation⁴. Venous grafts could be employed as tubing chambers for neural reconstruction as an alternative to reduce donor area sequelae, although with some restrictions: (1) The main advantages are observed in lesions smaller than 10 mm, (2) Inverted venous grafts seem to provide better results, and (3) Surgical times remain extensive because it requires dissection of the vessels³.

To reduce the surgical time and morbidity, venous grafts could be alternatively collected from cadavers that serve as donors. The vessels might be preserved in glycerol without compromising their structure, thus allowing their use in vascular microsurgery. Moreover, they are able to decrease graft immunogenicity⁵.

The aim of this study was to assess the degree of neural repair in rats that underwent autograft and glycerol-preserved vein repair of injuries with 5 mm loss of peroneal nerve. We used qualitative and quantitative histological analyses as well as functional assessments to conduct our study.

Methods

Twenty four Lewis rats, age eight weeks and weighing between 200g and 300g were used in this study. For the surgical procedure, the animals were intraperitoneally injected and anesthetized using sodium pentobarbital (50 mg/kg). For microsurgery, 5 mm long defects in the peroneal nerve of the right paw of the rats were induced within 5 mm from its sciatic nerve origin. The rats were divided into 4 groups (n = 6 per group), according to the repair performed (Table 1). In Group A (control), correction was accomplished by suturing the removed nerve segment, while maintaining the original orientation with separated epineural stitches of Mononylon 10-0 thread (functioning as an autogenous graft).

TABLE 1 - Characterization of the experimental groups by classifying the animals according to the treatment without changing the size of the defect (5 mm), study period, and operated nerve.

GROUP	DEFECT	TREATMENT	TIME OF SACRIFICE	NERVE
A n = 6	5 mm	Autograft (control)	6 weeks	peroneal
B n = 6	5 mm	Autogenous vein (10 mm)	6 weeks	peroneal
C n = 6	5 mm	Autogenous vein + glycerol (10 mm)	6 weeks	peroneal
D n = 6	5 mm	Allogeneic Vein + glycerol (10 mm)	6 weeks	peroneal

In the animals from Groups B, C and D, a segment of autologous right external jugular vein was interposed. The vein was harvested after trichotomy of the anterior cervical portion, incision in the paramedian cervical area, and isolation of the external jugular vein with a 10 mm long resection, while maintaining connected distal and proximal stumps. In these groups, the jugular vein was anchored in position using U stitches using Mononylon 10-0 thread and sutured at each end as follows: from the outside to the inside of the vein, crossing the epineurium in the stump of the nerve and returning to the vein from the inside to the outside, as the vein should cover 2.5 mm of the nerve stump. The second end was fixed with the same procedure (Figure 1).

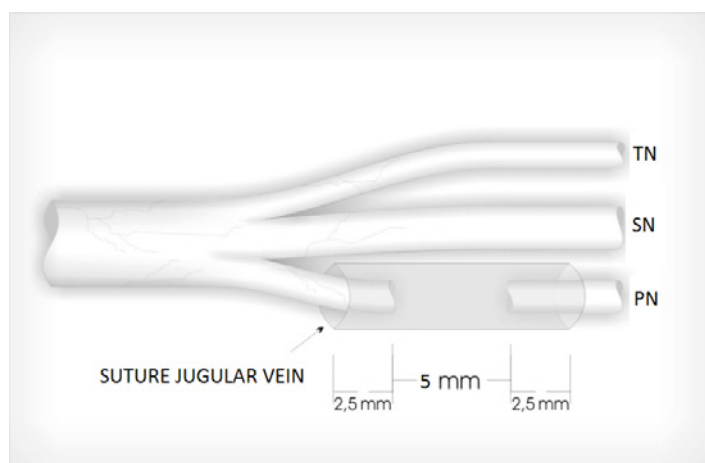


FIGURE 1 - Representation of reconstruction using veins and its positioning in the peroneal nerve. TN: Tibial Nerve. SN: Sural Nerve. PN: Peroneal Nerve.

In Group B, the vein was used for reconstruction without any previous treatment. In Group C, the vein was collected seven days before the procedure and stored in an identified single tube containing 20 ml 50% glycerol for the first 24h and 98% glycerol for the remaining six days. The vein was always maintained at 4°C³. On the grafting day, the veins were transferred to a saline solution for 30 min before neural reconstruction. In the Group D Lewis rats, the veins used were harvested from six Sprague Dawley rats and stored as described above for Group C.

The closure was performed by suturing the muscle and skin planes using non-absorbable surgical thread. The animals received water and food *ad libitum* and were sacrificed 6 weeks after surgery for qualitative and quantitative histological assessments of the regenerated myelinated axons. Functional recovery evaluation was performed using a technique that analyzes the impression of the hind legs of the rats while they are walking (walking track analysis) during a pre- and postoperative period of three and six weeks.

Qualitative histological assessments

Histological assessments were performed in the middle portion fragment of the interposed segment. Samples were analyzed after fixation in 2% glutaraldehyde and 1% osmium tetroxide solution, and embedded in pure benzoyl peroxide 1% resin and hydroxyethylmethacrylate. Cross-sectional cuts (2-μm thick) were stained using 1% toluidine blue. The general structure of the regenerated nerve was analyzed in all sections, identifying the organizational pattern of neural tissue within the neural and venous grafts, the degree of myelination and axonal reorganization, the arrangement of epiperineural connective tissue and fibroblasts,

the escape of axonal fibers outside the epineurium boundaries, and the tissue reaction³.

Quantitative histological assessments

Histological assessments were performed using light microscopy. Slides were photographed with a digital camera (Nikon model Coolpix E955) and the acquired pictures were transferred to the computer using Sigma Scan Pro 5.0 cell counting-specific software. Histological sections underwent computerized scanning for manual counts of myelinated axons.

Functional assessments

The degree of functional recovery associated with neural regeneration was assessed by studying the walking pattern of rats during the pre- and postoperative periods (immediate, three weeks, and six weeks [at the time of sacrifice]) and analyzing their hind leg footprints (walking track analyses)⁶ (Figure 2). These data were collected to calculate the peroneal nerve functional index (PFI)⁶ of each animal and further statistical analysis ($p < 0.05$).




FIGURE 2 - Measurements and scheme used to calculate the peroneal nerve functional index.

Results

During the six weeks of the study, all animals remained healthy, with no infection of the surgical wound or neurodystrophic plantar ulcers. At the time of sacrifice, upon macroscopic analyses, the grafts examined from Group A (autograft) were intact without visible neuromas. Groups B (autogenous vein), C (autogenous vein + glycerol), and D (allogeneic vein + glycerol) presented similar patterns when observed macroscopically, with poor adherence between veins and adjacent tissues, and an external thin layer of fibrous tissue surrounding the veins. No neuromas or vein collapse

were observed in these groups.

Qualitative histological assessments

In Group A (autograft), microscopic analyses showed the presence of large amounts of fibers with variable diameters, some of which were myelinated, dispersed throughout the neural stroma and sometimes grouped in small fascicles. The tissue reaction around the graft was higher when compared to the groups that used veins. Regenerated fiber escape was detected outside the epineurium boundaries in all animals (Figure 3).

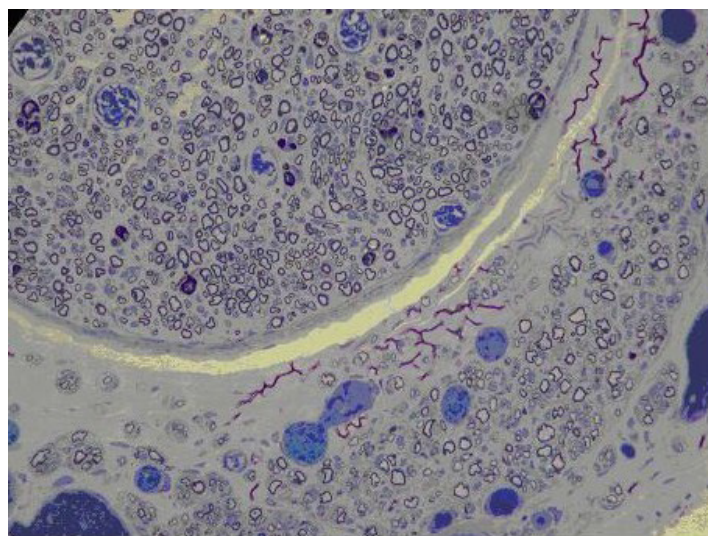


FIGURE 3 - Photomicrograph of Group A (autograft) nerve showing the escape of regenerated fibers outside the epineurium boundaries of the autograft (200x magnification).

In the Group B animals (autogenous vein), less perineural tissue reaction and axonal escape was observed when compared to Group A. In the interior, the presence of tissue with a pattern of neural stroma was observed, with large numbers of myelinated axons of various diameters. Some were grouped in minifascicles of varying sizes with areas of low axonal density in the neoformed stroma, only formed by connective tissue (Figure 4). The veins were circular; thus, it was possible to discriminate the neoformed neural stroma from the vessel wall structure. Pronounced neoangiogenesis was observed within the regenerated nerve, an effect not detected in Group A (Figure 5).

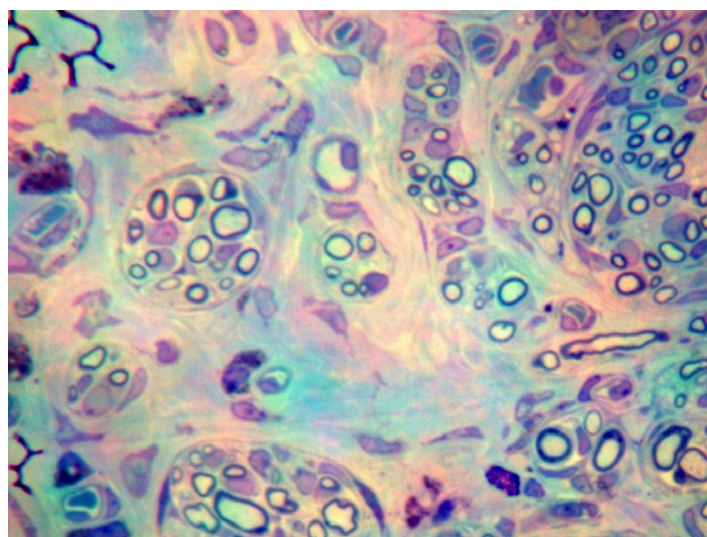


FIGURE 4 - Photomicrograph of Group B (autogenous vein) regenerated nerve in an area with low concentration of axons and large amount of connective tissue between fascicles (400x magnification).

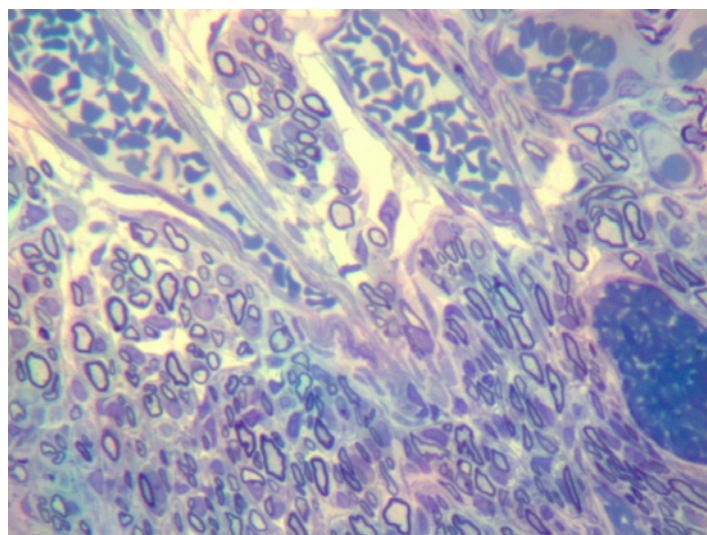


FIGURE 5 - Image from Group B (autogenous vein) showing large numbers of homogeneously distributed myelinated axons, with variable diameters. Within the minifascicles, many neoformed vessels were detected (400x magnification).

Similar histological patterns were observed in Groups C (autogenous vein + glycerol) and D (allogeneic vein + glycerol). In the 12 animals, veins were circular with a single fascicle, thus it was possible to distinguish the neoformed neural stroma from the structure of the vessel wall. They contained a pattern of neural stroma in their interior tissue, with large numbers of myelinated axons of different diameters, grouped in minifascicles of varying sizes, heterogeneously distributed, and with connective tissue between them. In the neural tissue, lesser neoangiogenesis was observed than that in Group B (autogenous vein). Similar to Group

B (autogenous vein), lesser perineural tissue reaction, and axonal escape were detected than that in Group A (Figures 6 and 7).

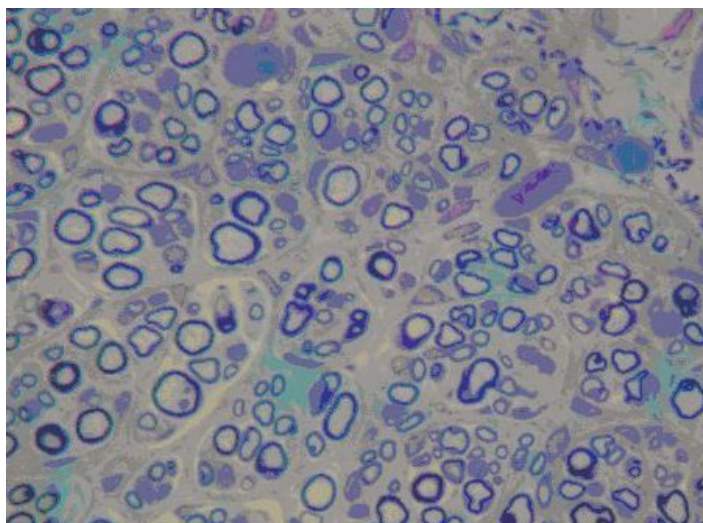


FIGURE 6 - Group C (autogenous vein + glycerol) rats had large numbers of homogeneously distributed myelinated axons of variable diameters in the autograft (400x magnification).

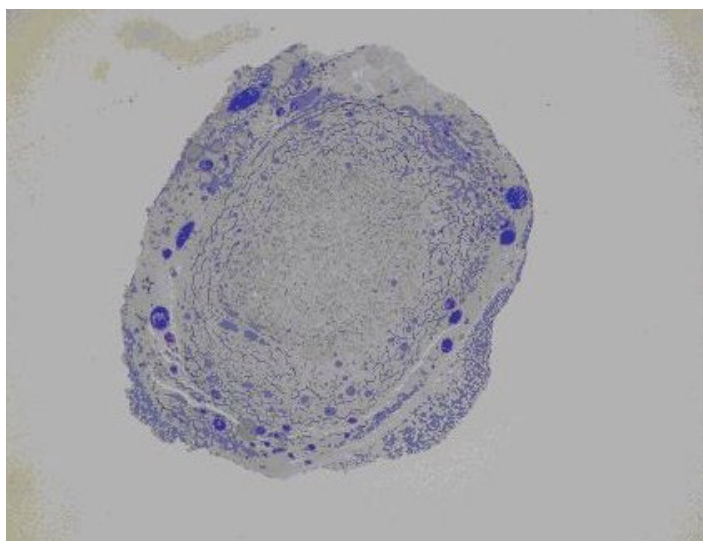


FIGURE 7 - Histological section of the middle portion of the regenerated nerve six weeks after surgery shows a single fascicle in a Group D animal (allogeneic vein + glycerol). Low perineural tissue reaction is also observed (50x magnification).

There were no differences in fiber diameter or degree of myelination in Groups A (autograft), B (autogenous vein), C (autogenous vein + glycerol), and D (allogeneic vein + glycerol).

Quantitative histological assessments

The results of the axonal counting are shown in the following graph (Figure 8):

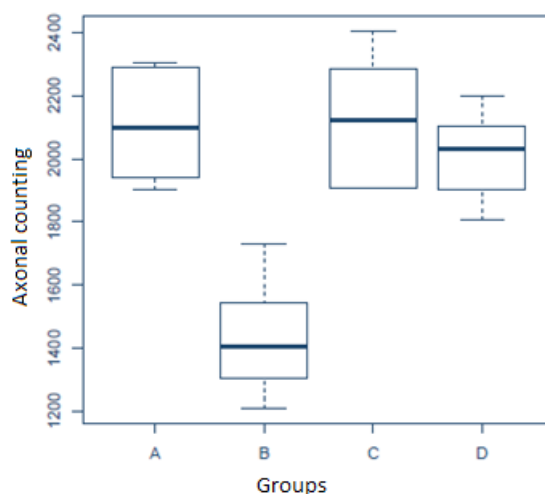


FIGURE 8 - Graph showing axonal counting by groups. Group A is the control; B, autogenous vein; C, autogenous vein + glycerol; and D, allogeneic vein + glycerol.

Statistical analyses were performed using one-way analysis of variance (ANOVA). Groups C (autogenous vein + glycerol) and D (allogeneic vein + glycerol) had axonal counts that were statistically similar to that in Group A (control). However, Group B (autogenous vein) has significantly lower counts when compared to the other groups.

Functional assessments

Peroneal nerve functional index (PFI) average values in the pre- and postoperative period (immediate, three and six weeks) for each group are presented below (Figure 9).

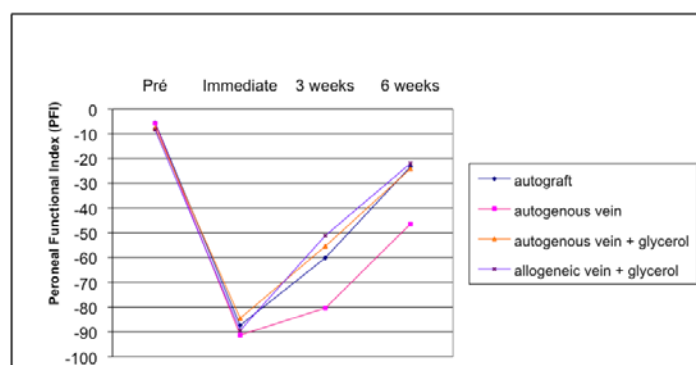


FIGURE 9 - Average peroneal nerve functional index (PFI) profiles from each group during the study period and immediately before surgery, three and six postoperative weeks.

Statistical analyses were performed by comparing the PFI of the groups with repeated measures analysis of variance. The results showed no statistically significant differences in the PFI among the four groups, during the pre- and immediate postoperative period ($p < 0.05$). However, after three and six weeks,

Group B (autogenous vein) animals had a statistically significant lower PFI average compared to the other groups ($p < 0.05$).

Discussion

Neural injury due to trauma or large tumor resections often leads to important esthetic or functional deficits. However, nervous system plasticity allows mechanisms of compensation, including neuronal cell body maintenance, axonal regeneration by axonal sprouting, as well as the establishment of functional synapses that allow recovery of some sensory function. Manipulation of any of these neural regeneration phases might improve the recovery ability in patients⁷.

Autograft is a commonly used procedure in cases of peripheral nerve injury with mass loss, and in cases where the extent of the defect prevents a direct approximation of the stumps⁸.

However, there are factors that lead us to seek a new conduit for axonal growth. First, removal of autologous material for grafting always produces morbidity of the donor area. Second, pronounced defects require removal of extensive portions of autogenous tissue that is often not feasible. Additionally, using artificial material or tissue banks typically saves the time involved in removing autologous materials. Finally, the results obtained after using autografts are not completely satisfactory⁹.

An ideal tube should be inert, flexible, and able to inhibit the scarring process and facilitate healing and neural regeneration⁹. Interposition of tubular conductors as a bridge between the stumps of the sectioned nerves has provided encouraging experimental and clinical results. In small defects repair, in which the distance between the stumps does not disrupt the chemotactic and chemotropic attraction exerted by the distal stump on the axonal growth cone, this procedure provides similar results to those obtained with autografts¹⁰.

There are many advantages of the tubing procedure over traditional grafts. It provides adequate coaptation of the 2 stumps with less handling trauma. It enables better containment of the growing fibers within the tube, thus, isolating the repair site from surrounding inflammatory reactions. The tubing procedure guides the growth of fibers towards the distal stump, thereby allowing a local concentration of neurotrophic factors. Finally, it decreases neuroma formation and the escape of fibers outside the conductor and enables the distribution of substances that enhance regeneration⁹.

Several authors have reported that positive results using vein grafts for nerve reconstruction, rendering this procedure comparable to nerve autograft due to the difficulty of scar tissue

invasion within the venous conductor^{11,12}.

Clinical studies showed that vein grafts are efficient for reconstruction of sensitive nerves with defects less than 3 cm^{12,13}. Endothelial cell growth factor (or angiogenic factor) is similar to that found in Schwann cells, and is considered a factor that favors injured nerve regeneration¹². In contrast, other groups showed that contact of the regenerating axons with the endothelium would lead to connective tissue formation within the vein¹⁴.

Allogeneic grafts might be an alternative for the repair of extensive loss of neural tissue. However, allogeneic nerve graft is quite antigenic and is rejected upon suspension of immunosuppressive therapy³.

Glycerol preservation of materials is widely performed^{3,5,15,16}. High glycerol concentrations (above 85%) provoke rapid dehydration of the biological sample. Taking this into account, glycerol preservation protocols prove more efficient if the sample is initially exposed to low concentrations (around 50%)¹⁶. Thus, we used an initial preservation in 50% glycerol for the first 24h.

Rat is a well-established experimental model for the study of peripheral nerves⁶. Moreover, the functional recovery of injured sciatic nerve and its motor branches can be assessed using the "walking track analysis." This is a non-invasive test commonly used before and after surgery^{3,9}.

The experimental groups were divided into Group A (autograft), in which the autograft is considered the treatment of choice for neural defect repair presenting mass loss⁸. Group B (autogenous vein) included rats in which the vein was used as alternative to treat neural injury, similar to clinical practice¹³. Group C (autogenous vein + glycerol) included animals in which the vein was preserved in glycerol in an effort to decrease the cellularity and maintain the extracellular matrix in direct contact with the regenerating axons¹⁶. Finally, in Group D (allogeneic vein + glycerol) rats, the use of glycerol-preserved allogeneic veins was to show that this material could be employed for tubing procedures and transplantations because of the decreased immune response induced by glycerol.

The preserved vein diminishes the surgical time used for autogenous material removal and presents the advantages of the tubing procedure. Specifically, it reduces the scarring process around the graft, prevents neuroma formation and escape of fibers, and enables a higher number of axons to regenerate and reach the target organs^{3,14}. These effects improve functional recovery. Therefore, this method might open a new perspective for materials preserved in tissue banks to be employed for peripheral nerve reconstruction.

Macroscopically, neuroma formation was not observed in rats subjected to autograft, as described in the literature¹⁷. Although previously described in reconstructions using several materials with the tubing procedure², collapses were not detected in the veins of animals from Groups B (autogenous vein), C (autogenous vein + glycerol), and D (allogeneic vein + glycerol).

The absence of vein collapse is a known effect. During the initial phase of peripheral nerve injury, extravasation of blood from epineural and endoneural vessels of the proximal stump of the nerve was observed. This leads to a hematoma within the vein. Within the first seven days, the phagocytes that absorb blood cells, maintaining the fibrin substrate as vein tube support, invade the hematoma. In this initial phase, no axonal growth within the vein was detected¹⁸.

From a histomorphological point of view, no major differences were observed among Groups A (autograft), C (autogenous vein + glycerol), and D (allogeneic vein + glycerol), which is consistent with the findings in other studies³.

According to the histological assessments, Group B (autogenous vein) presented a different pattern from the other groups. The vessel wall was intact upon neuroregeneration¹⁸. Although a high number of myelinated cells were seen, with a similar distribution to the other groups, we observed regions with lower axonal density and the presence of extensive areas of connective tissue, as well as pronounced neoangiogenesis.

A study in which a venous conductor was filled with autogenous fresh muscle had better results compared to tubes filled with axons¹⁹. It is believed that the presence of muscle cells within the venous conductors would decrease the incidence of vessel collapse. However, in Groups B (autogenous vein), C (autogenous vein + glycerol), and D (allogeneic vein + glycerol), we observed no cases of vessel collapse in the 18 animals, suggesting the initial phase of the hematoma is likely responsible for this finding¹⁸.

The use of autologous vein grafts as neural tube or coverage of suture lines correlates to the formation of connective tissue and reduction in axonal regeneration. Therefore, the contact between endothelial cells and neural tissue could produce scar tissue before neuroregeneration occurs¹⁴. This might explain the areas of lower axonal density filled by connective tissue observed in the histological sections of Group B (autogenous vein).

To avoid endothelial cell contact with neural tissue, several studies have experimented with the use of an inverted vein, comparing this procedure to the traditional vein graft and nerve graft³. Collagen and laminin were also shown to promote peripheral nerve regeneration². Venous *adventitia* is a rich source of collagen, whereas the *tunica media* is rich in laminin. By reversing

the normal orientation of the vein, axons are more exposed to the existing collagen in the *adventitia*, as well as properly isolated from the endothelium³.

Glycerol-preserved vessels have been described for vascular microsurgery, but not for neural reconstruction. Allogeneic vein graft rejection is detected histologically by assessing mononuclear cell infiltration. This effect depends on the degree of histocompatibility and the *tunica media* thickness that contains immunogenic muscle cells²⁰. Glycerol preservation of the vein leads to the loss of cellular components, and therefore loss of the *intima* (endothelial cells) as well as the muscle cells of the *tunica media*. However, preservation of the biomechanical characteristics of the rat blood vessels is maintained, such as the resistance and structure of the extracellular matrix formed by collagen and laminin¹⁶.

The loss of the *intima* should be considered a positive event for neuroregeneration because it might lead to less scarring within the vein, observed in Groups C (autogenous vein + glycerol) and D (allogeneic vein + glycerol). These findings differed from Group B (autogenous vein), although the integrity of the veins with the *intima* was maintained.

The absence of muscle cells in the preserved veins decreases the immune response against the graft¹⁶. In keeping with this notion, autologous grafts of glycerol-preserved veins showed less rejection, as mononuclear cell infiltration was not observed. This finding enables the use of transplanted veins, as observed in Group D (allogeneic vein + glycerol).

A lower number of axons in Group B (autogenous vein) correlated with the qualitative results reporting areas of higher axonal rarefaction.

Regarding functional assessments and considering significant values with $p < 0.05$, PFI average during the preoperative and immediate postoperative period in the four groups analyzed showed no statistically significant differences. This leads to a homogeneous walking pattern in the pre- and immediate postoperative period, as all rats were subjected to the same neural injury.

Three and six weeks after surgery, the PFI average in Group B (autogenous vein) was significantly lower than that in the other groups, although no statistically significant differences were observed among them. These data correlate to a low axonal density assessed by qualitative and quantitative histology. From a functional point of view, Groups C (autogenous vein + glycerol) and D (allogeneic vein + glycerol) showed similar results as that in the control Group A (autograft).

Taken together, our data suggest the use of fresh

autogenous vein tubes (without treatment) that might contribute to guiding the fibers toward the target organs, although several factors might prevent neuroregeneration and functional recovery.

Neural regeneration is a complex process. Further investigations are required to better understand the mechanisms involved in this process. Research improvements have been observed, such as using tissue bank materials, and these were shown to be appropriate, cheaper, widely available, and able to confer optimal functional results, as well as decrease the surgical time and avoid the maximum sequelae of donor areas.

Conclusions

Glycerol-preserved autogenous or allogeneic veins showed similar results to autograft results. The autogenous vein (without preservation in glycerol) presented histological and functional outcomes statistically lower than other groups.

References

1. Spector JG, Lee P, Derby A, Friedrich GE, Neises G, Roufa DG. Rabbit facial nerve regeneration in ngf-containing silastic tubes. *Laryngoscope*. 1993;103:548-58.
2. Brunelli GA, Vigasio A, Brunelli GR. Different conduits in peripheral nerve surgery. *Microsurgery*. 1994;15:176-8.
3. Cunha AS, Lemos SPS, Silva CS, Barros TEP, Costa MP, Ferreira MC. The use of glycerol-treated venous graft in damaged nerves repair: an experimental study in rats. *Acta Ortop Bras*. 2007;15:210-3.
4. Walton RL, Brown RE, Matory WE, Borah GL, Dolph JL. Autogenous vein graft repair of digital nerve defects in the finger: a retrospective clinical study. *Plast Reconstr Surg*. 1989;84:944-52.
5. Wolff KD, Walter G, Zimmer C. Nerve reconstruction with glycerol-preserved allogenic grafts in the rat. *Microsurgery*. 1993;14:315-22.
6. Bain JR, Mackinnon SE, Hunter DA. Functional evaluation of complete sciatic, peroneal, and posterior tibial lesions in the rat. *Plast Reconstr Surg*. 1989;83:129-36.
7. Wong BJB, Crumley RL. Nerve wound healing. An overview. *Otolaryngol Clin N Am*. 1995;28:881-95.
8. Terzis JK, Faibisoff B, Williams HB. The nerve gap: suture under tension vs. nerve graft. *Plast Reconstr Surg*. 1975;56:166-70.
9. Costa MP, Cunha AS, Silva CF, Barros Filho TEP, Ferreira MC. Use of polyglycolic acid tube associated with FK506 in regeneration of peripheral nerves. *Acta Ortop Bras*. 2006;14:25-9.
10. Hentz VR, Rosen JM, Xiao SJ, McGill KC, Abraham G. A comparison of suture and tubulization nerve repair technique in a primate. *J Hand Surg*. 1991;16:251-61.
11. Chiu DTW, Lovelace RE, Yu L. Comparative electrophysiologic evaluation of nerve grafts and autogenous vein grafts as nerve conduits: an experimental study. *J Reconstr Microsurg*. 1988;4:303-10.
12. Smith MS, Browne JD. The effect of endothelial cell growth factor on peripheral nerve regeneration. *Otolaryngol Head Neck Surg*. 1998;118:178-82.
13. Tang JB, Gu YQ, Song YS. Repair of digital nerve defect, with autogenous vein graft during flexor tendon surgery in zone 2. *J Hand Surg*. 1993;18:449-53.
14. Heijke GC, Klopper PJ, Dutrieux RP. Vein graft conduits versus conventional suturing in peripheral nerve reconstruction. *Microsurgery*. 1993;14:584-8.
15. Lemos SPS, Hayashi I, Cunha AS, Da Silva CF, Barros TEP, Costa MP, Ferreira MC. Glycerol-preserved allogeneous nerve: an experimental study with rats. *Acta Ortop Bras*. 2008;16:133-7.
16. Wolff KD, Dienemann D. Vessel preservation with glycerol: an experimental study in rats. *J Oral Maxillofac Surg*. 1990;48:914-8.
18. Tseng CY, Hu G, Ambron RT, Chiu DTW. Histologic analysis of Schwann cell migration and peripheral nerve regeneration in the autogenous venous nerve conduit (AVNC). *J Reconstr Microsurg*. 2003;19:331-9.
19. Brunelli GA, Battiston B, Vigasio A, Brunel IGR, Marocolo D. Briding nerve defects with combined skeletal muscle and vein conduits. *Microsurgery*. 1993;14:247-51.
20. Vischjager M, Gulik TMV, Kromhout JG, Marle JV, Pfaffendorff M, Pieter Klopper PJ, Jacobs MJHM. Morphology and function of preserved microvascular arterial grafts: an experimental study in rats. *Ann Vasc Surg*. 1997;11:284-91.

Correspondence:

Armando dos Santos Cunha
SHCSW lotes 3/4/5 sala 243 (Centro Clínico Sudoeste)
70673-416 Brasília - DF Brasil
Tel./Fax: (55 61)3234-6576
armandocunha@hotmail.com

Received: September 18, 2012

Review: November 19, 2012

Accepted: December 20, 2012

Conflict of interest: none

Financial source: none

¹Research performed at Laboratory of Microsurgery, Department of Plastic Surgery, Faculty of Medicine, Sao Paulo University (USP), Brazil. Part of PhD degree thesis, Postgraduate Program in Medicine (Surgical Clinic), USP. Tutor: Marcio Paulino Costa.