

The role of N-acetyl-cysteine in the lung remote injury after hepatic ischemia and reperfusion in rabbits¹

O papel da N-acetil-cisteína nas lesões pulmonares provocadas à distância pela isquemia e reperfusão hepática em coelhos

Angela Potter de Castro^I, Miguel Angelo Martins de Castro Junior^{II}, Susi Lauz^{III}, Emilio Facin^{IV}, Manuel de Jesus Simões^V, Djalma José Fagundes^{VI}

^IMSc, Medical Veterinary, Surgery and Veterinary Pathology/Pharmacology, FURG. Fellow PhD degree, Postgraduate Program in Experimental Surgery, UNIFESP, Sao Paulo, Brazil. Main author. Responsible for conception, design, intellectual and scientific content of the study.

^{II}MSc, Associate Professor, FURG, Rio Grande, Brazil. Surgical procedures, manuscript writing.

^{III}PhD, Associate Professor of Surgery, FURG, Rio Grande, Brazil. Acquisition and interpretation of data, critical revision.

^{IV}Graduate student, Scientific Initiation Program, FURG, Rio Grande, Brazil. Surgical procedures, manuscript writing.

^VPhD, Associate Professor, Histology and Structural Biology Division, Department of Morphology, UNIFESP, Sao Paulo, Brazil. Interpretation of data, histopathological analysis.

^{VI}PhD, Associate Professor, Operative Technique and Experimental Surgery Division, Department of Surgery, UNIFESP, Sao Paulo, Brazil. Tutor. Responsible for conception and critical revision of the study.

ABSTRACT

PURPOSE: To study the lesions in the lung of rabbits caused by ischemia/reperfusion hepatic (I/R) after the use of N-acetyl-cysteine (NAC).

METHODS: Twenty-four rabbits distributed in two groups: control group GI (n = 12) 5% glucose solution and experiment group GII (n = 12) NAC. The animals were pre-anesthetized with 1% acepromazine maleate and anesthetized with ketamine 10% and 2% xylazine intramuscularly. The GI and GII were given glucose solution intravenously or NAC 15min before occlusion of the hepatic pedicle (30 min). After the period of reperfusion of 24h (n = 6) or 48h (n = 6), liver and lung samples were collected for histology and immunohistochemistry to assess the impairment of cell.

RESULTS: The animals of GII and GII-24h-48h showed parenchyma liver close to normal, when using NAC. The GII and GII-24h-48h showed lower thickness of alveolar cells that GI and GI-24h-48h. The expression of caspase 3 in lung cells GII presented smaller value compared to the GI group.

CONCLUSION: N-acetyl-cysteine administered 15min prior to the injury ischemia/reperfusion had a significant protective role by minimizing lung injury and apoptotic morphology in the period observed.

Key words: Acetylcysteine. Lung. Reperfusion. Ischemia. Liver. Rabbits.

RESUMO

OBJETIVO: Estudar as lesões no fígado e no pulmão de coelhos, provocadas pela isquemia/reperfusão hepática (I/R) moduladas pelo uso da N-acetil-cisteína (NAC).

MÉTODOS: Vinte e quatro coelhos distribuídos em dois grupos: Grupo controle GI (n=12) solução de glicose 5% e Grupo experimento GII (n=12) NAC. Os animais foram pré-anestesiados com maleato de acepromazina 1% e anestesiados com cloridrato de quetamina 10% e xilazina 2% via intramuscular. Os grupos GI e GII receberam solução glicosada ou NAC respectivamente via endovenosa 15min antes da oclusão do pedículo hepático (30 min). Após iniciou-se o período de reperfusão por 24h (n=6) ou 48h (n=6), terminada a reperfusão, amostras do fígado e pulmão foram coletadas para a histologia e imunoistoquímica para avaliar o comprometimento celular.

RESULTADOS: Os animais do grupo GII-24h e GII-48h apresentaram arquitetura do parênquima hepático próximo do normal, quando se utilizou NAC. Os grupos GII-24h e GII-48h apresentaram menor espessura das células alveolares que os grupos GI-24h e GI-48h. A expressão da caspase 3 nas células pulmonares do grupo GII, apresentou valor menor comparada ao grupo GI.

CONCLUSÃO: A N-acetil-cisteína administrada 15min prévios a lesão da isquemia/reperfusão teve um papel protetor significativo minimizando as lesões morfológicas e apoptóticas pulmonares nos períodos observados.

Descritores: Acetilcisteína. Pulmão. Reperfusão. Isquemia. Fígado. Coelhos.

Introduction

Ischemia is the interruption of blood flow, consequently the supply of oxygen and nutrients to a tissue or organ. This condition may be reversible or not, depending on the metabolic characteristics of the tissue involved and the environment¹.

During the interruption of blood supply to a tissue cell hypoxia occurs, initiating a sequence of biochemical events such as the interruption of the respiratory chain, the consumption, degradation of nucleotide triphosphate, mobilization of calcium from intracellular stores, loss of function of membrane and activation-dependent enzymes calico²⁻⁴.

There is evidence that tissue injury is not limited to ischemia, but extends to the process of reperfusion, and this may be defined as the damage that occurs in specific tissue by restoring blood flow after a period of ischemia⁵. Among the highlights are the injuries necrosis and apoptosis, and the determining factor is the intensity of damage^{5,6}.

Thus, reperfusion damage may extend to organs located at a distance, due to a systemic inflammatory response in which inflammatory mediators are produced and released into circulation^{4,7}.

Ischemia/reperfusion(I/R)play an important role in hepatic resections, liver transplants and in hemorrhagic shock^{8,9}.

The lung is most affected organ by the distance I/R liver injury. Evidenced by significant morphological changes such as perivascular edema, intravascular platelet aggregation and increased tumor necrosis factor alpha (TNF) in bronchoalveolar lavage, and appears to systemic inflammation also known as hepatopulmonary syndrome¹⁰.

Because of the systemic inflammatory response, the I/R injury liver induces the production of reactive oxygen species (ROS) whose distance deleterious effects may be more deleterious than local effects^{11,12}.

The ROS play a key role in lung injury resulted from reperfused tissues. These relate to the injury of the alveolar-capillary membrane and consequent transudation that contribute to acute respiratory distress syndrome (ARDS)³.

The main cause of cell injury is oxidizing substances produced by the cells previously ischemic or activated leukocytes¹¹. Many injuries are developed during the tissue reperfusion resulted from reoxygenation. Researches of mechanisms to protect the damage of I/R considers the use of substances antioxidantes^{13,14}. Among these, glutathione (GSH) is considered effective in ischemia stage^{15,16}. GSH is synthesized by the liver in two ways, catalyzed by γ -glutamyl cysteine synthetase and glutathione

synthetase, distributed through the bloodstream to all tissues. An important exogenous source of glutathione is represented by NAC¹⁷.

NAC is a molecule that shows a link thiol (sulfur) bound to the amino acid L-cysteine. However, is not present in the diet and should be obtained through dietary supplements. This substance has been used in the treatment of pulmonary diseases, as an antidote for poisoning by paracetamol in heavy metal poisoning, diseases of the immune system, and studies with apoptose¹⁸.

The antioxidant activity of NAC occurs directly by convert hydrogen peroxide into less reactive compounds and/or indirectly, when induce the biosynthesis of GSH (reduced glutathione)¹⁸.

Was observed at literature that the effects of NAC range from 15 to 6 minutes to ischemia and periods of 2 to 4 hours of reperfusion. At our literature review was not observed periods over than 4 hours to reperfusion. Thus, it was pertinent to study the NAC as a protective agent on the I/R liver injury and on the remote damage to the lung parenchyma by morphological analysis in after longer times of reperfusion (24 and 48 hours) in a rabbit experimental model.

Methods

The research project was approved by the Ethics Committee of Federal University of Sao Paulo, ratified by the Federal University of Rio Grande This study follows the standards of animal research, recommended by the Brazilian College of Animal Experimentation, an institution affiliated of International Council for Laboratory Animal Science.

We used 24 rabbits (N = 24), albino, New Zealand (*Oryctolagus cuniculus*), males, four months, average weight 3Kg from Federal University of Pelotas.

The animals were evaluated randomly into two groups: the control group GI (n = 12) received 5% glucose solution and the experimental group GII (n = 12) received NAC, administered intravenously (IV) 15 min before ischemia. The animals were pre-anesthetized with acepromazine maleate 1% dose of 2mg. Kg⁻¹ and then anesthetized with a combination of ketamine at a dose of 10% 35mg.Kg⁻¹ and 2% xylazine at a dose of 5mg.kg⁻¹ intramuscularly (IM). We performed a transverse incision of 4 cm in the right upper quadrant and identified the portal triad (hepatic artery, portal vein and biliary ducts) and the vena cava. Fifteen minutes before clamping the hepatic pedicle was injected intravenously 1mL.Kg⁻¹ glucose solution 5% in the control group. In the Experimental group was injected in the same period the NAC at a dose of 150 mg.Kg⁻¹, diluted in 5% glucose solution.

Then was proceed the hepatic ischemia for 30 minutes. After, the clamp was removed and the synthesis of the abdominal wall was performed with sutures. After it was started in the reperfusion time of 24 hours (n = 6) or 48 (n = 6). The animals received analgesia with Dipyrone Sodium 500mg dose of 0.3 mL.Kg⁻¹ at the end of operative procedure intravenously and after 6 hours of procedure. Antimicrobial prophylaxis was performed in all animals at a dose of 1g cephalothin 20mg.Kg⁻¹. After reperfusion, animals were anesthetized and submitted to thoracotomy to remove a fragment of liver and lung.

Samples of liver and lung were processed for hematoxylin eosin staining and immunohistochemistry. Twenty random fields were chosen in each section of each animal and set relevant points of each group. There has been a qualitative and / or quantitative sign of liver or lung lesions.

The liver was analyzed for the presence or absence of congestion of central lobular vein, the portal space and vasodilation, while the lung was evaluated: thickening of alveolar septa, leukocyte infiltration, hemorrhage, edema and the presence of macrophages in the septa.

For lesions absent or present in up to two fields, given the value zero (0), for the presence of mild lesions from 3 to 8 fields set itself the value of a (+), presence of moderate injuries from 9 to 14 fields assigned the value two (++) and for the accentuated presence of injuries from 15 to 20 fields assigned the value three (+++), counting procedure was performed by a software (Image Lab), where they obtained images of 10 fields in each slide. For this we used high-resolution camera AxionCam RLX™ (Carl Zeiss) light microscope adapted Axiolab™ (Carl Zeiss) and Pentium 4™ with Axiovision™ program REL 4.2 (Carl Zeiss).

Lungs fragments were processed for immunohistochemical labeling of caspase 3 and its expression as a measure of lung cell apoptosis using the avidin-biotin-peroxidase (ABC). The immunohistochemical expression of caspase 3 was identified and quantified by computer program (program AxioVision Rel® 4.2 - Carl Zeiss) and adopted as positivity the appearance of brown color in the core, at region of the boundary cell or the cell cytoplasm. The rate of apoptosis and cell proliferation was calculated using the percentage of labeled cells per 1000 cells counted in twenty random fields and presentation of such measures as mean and standard deviation.

Statistical analysis was prepared by PGS Medical Statistics (Sao Paulo, Brazil). To assess the apoptosis and cell proliferation between groups was used the test of analysis of variance (ANOVA) test and multiple comparison Student-Newman Keuls test for comparing two columns, we adopted the

significance level of 0.05 ($\alpha \leq 5\%$) and levels (p) below this value were considered significant.

Results

TABLE 1 - Qualitative analysis of liver damage tissue or cell signs found in the slides stained with HE.

| | Central lobular vein Congestion | Portal Space | Vasodilation |
|----------------|------------------------------------|--------------|--------------|
| CONTROL | | | |
| 24 | +++ | +++ | +++ |
| 48 | ++ | ++ | ++ |
| NAC | | | |
| 24 | + | + | + |
| 48 | + | + | + |

TABLE 2 - Qualitative analysis of lung damage tissue or cell signs found in the slides stained with HE.

| | Alveolar septal thickening | Leukocyte infiltration | Hemorrhage | Edema |
|----------------|----------------------------------|---------------------------|------------|-------|
| CONTROL | | | | |
| 24 | +++ | +++ | +++ | +++ |
| 48 | ++ | ++ | ++ | ++ |
| NAC | | | | |
| 24 | ++ | ++ | + | + |
| 48 | ++ | + | + | + |

TABLE 3 - Distribution of the mean \pm standard deviation of the alveoli thickness (mM) in the lung parenchyma for each animal in each group reading of 1000 cells counted in 20 random fields in the slides stained by immunohistochemistry. ANOVA Test ($p < 0.05$).

| Animals n° | 1 | 2 | 3 | 4 | 5 | 6 | Mean \pm sd |
|----------------|-----|-----|-----|------|-----|-----|-------------------|
| CONTROL | | | | | | | |
| 24h | 8.5 | 7.8 | 6.9 | 8.9 | 7.4 | 8.6 | 8.01 \pm 0.87* |
| 48h | 5.2 | 5.4 | 6.1 | 5.2 | 4.2 | 4.2 | 5.05 \pm 0.73** |
| NAC | | | | | | | |
| 24h | 5.7 | 3.5 | 3.8 | 3.7 | 4.1 | 3.2 | 4.00 \pm 0.88 |
| 48h | 2.7 | 2.5 | 3.2 | 2.57 | 3.2 | 3.7 | 2.97 \pm 0.46 |

*24 GC > 24 GE ($p \leq 0.001$): significant.

**48 GC > 48 GE ($p \leq 0.001$): significant.

TABLE 4 - Distribution of the mean \pm standard deviation of the expression of caspase 3 (apoptosis) in lung parenchyma for each animal in each group of 1000 cells counted in 20 random fields in the slides stained by immunohistochemistry. ANOV/ Test ($p<0.05$).

| Animals n° | 1 | 2 | 3 | 4 | 5 | 6 | Mean \pm sd |
|----------------|------|------|------|------|------|------|-------------------|
| CONTROL | | | | | | | |
| 24h | 24.9 | 32.5 | 35.4 | 45.8 | 32.6 | 36.7 | 34.65 \pm 8.65* |
| 48h | 10.2 | 11.4 | 12.3 | 11.7 | 10.5 | 9.3 | 10.9 \pm 1.10 |
| NAC | | | | | | | |
| 24h | 18.1 | 17.1 | 12.3 | 14.1 | 16.1 | 12.1 | 14.96 \pm 2.51 |
| 48h | 7.8 | 8.0 | 9.2 | 8.2 | 8.5 | 9.1 | 8.46 \pm 0.57 |

*24 GC > 24 GE ($p \leq 0.001$)

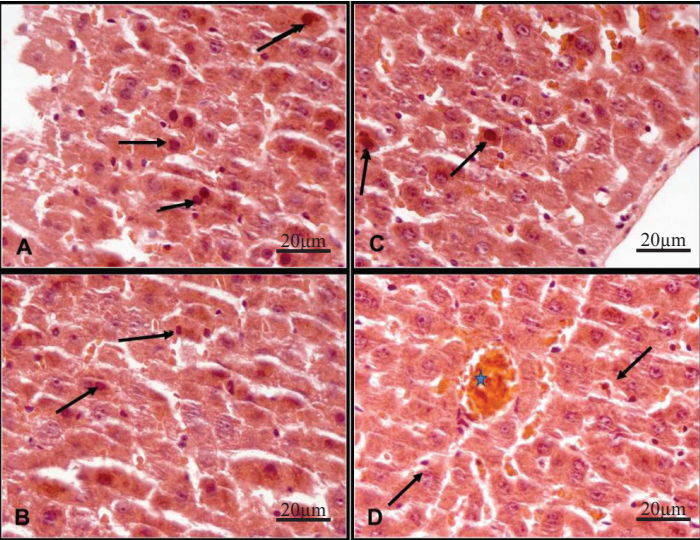


FIGURE 1 - Animals in the control group 24 hours (A) and control group 48 hours (B) showed heterochromatic nuclei of hepatocytes (black arrows). Animals in Group NAC 24 hours (C) and 48 hours (D) showed some heterochromatic nuclei of hepatocytes (black arrows). Note lobular vein center congested at group 48 hours (D) (star). (HE-400 X).

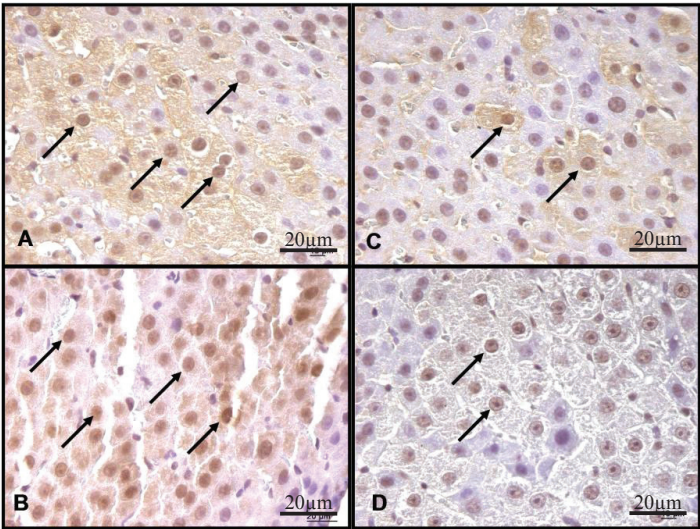


FIGURE 2 - Animals in the control group 24 hours (A) and control group 48 hours (B) show hepatocytes reactivity to caspase 3. Animals Group NAC 24 hours (C) and control group 48 hours (D) show some hepatocytes reactivity to caspase 3. (HE-400 X).

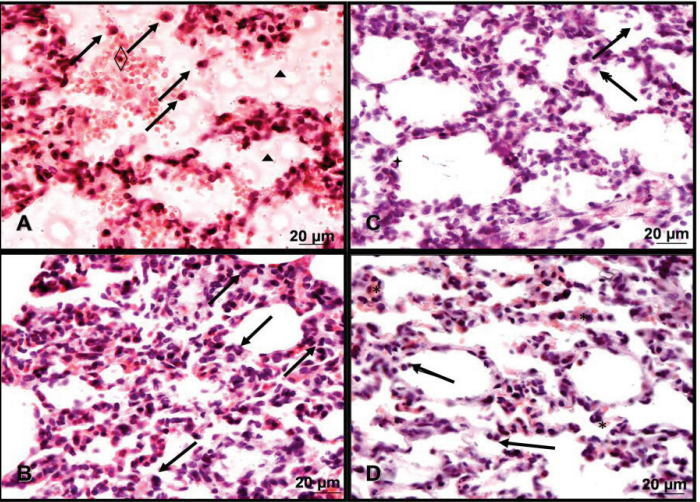


FIGURE 3 - Animals in the control group 24 hours (A) showed red blood cells (◊), macrophages (black arrows) and exsudates (◻) and control group 48 hours (B) macrophages (black arrows). Animals Group NAC 24 hours (C) show macrophages (black arrows) and leukocytes within the alveolar septa (◻) and animals of Group NAC 48 hours (D) alveoli with thickened walls and less congested with macrophages (black arrows). (HE-400 X).

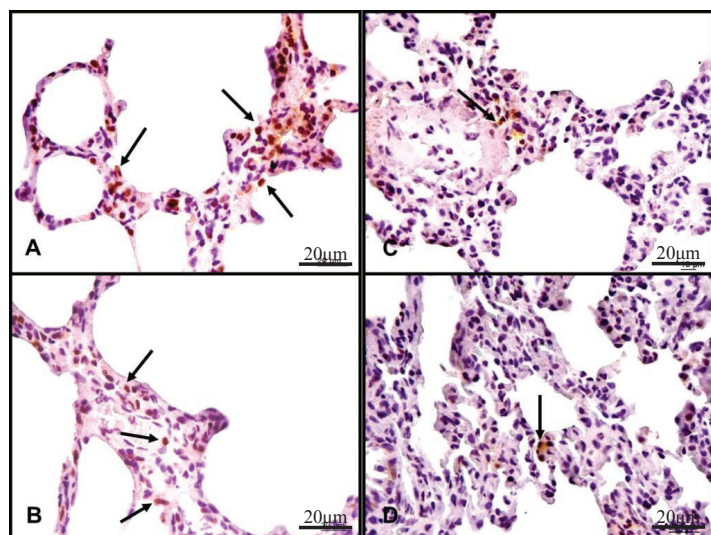


FIGURE 4 - Animals in the control group 24 hours (A) and 48 hours (B) have higher concentrations of thickened alveolar and reactive cells to caspase 3 (black arrows) indicative of apoptosis compared to NAC group 24 h (C) and 48 (D) (HE -400X).

Discussion

Hepatic ischemia is a frequent event today either in trauma surgery or liver transplantation. The evaluation of the phenomenon of I/R has been reported in animal models, but there are restrictions when transposing the results to humans.

The rabbit a rodent to be larger and easier handling was considered appropriate for this research⁹⁻²¹. To these factors is associated with ease of anesthesia protocol, which provided adequate hypnosis and analgesia, an anesthetic for up to 60 minutes.

Among the different experimental models of injury I/R liver stands out the Pringle maneuver, this allows the study of ischemic injury in the affected organ or organs at a distance²⁰. The changes of ischemia may be evolving into molecular or biochemical histological changes, which in turn, can range from discrete morphological lesions to necrosis. Thus, the choice of the ischemia duration is crucial for the experiment is that depending on time can lead to changes irreversible⁴⁻⁵.

In order to make the proposed objective in this study we chose the ischemic time of thirty minutes in order to mimic a condition that is encountered in clinical practice and to serve as a reliable and reproducible model.

For the period of reperfusion was chosen by a time of 48 hours long considered when comparing to previous studies, because in short periods is well-known how tecidual injury occurs^{4,22,23}.

Substances have been used in order to minimize injuries from I/R including the NAC to be a mucolytic drug which is used in lung diseases, paracetamol poisoning, and application in organs and tissues subjected to ischemia and reperfusion. Its pharmacological effects include suppression of the production of tumor necrosis factor alpha, inhibit platelet aggregation, modulation of cell activation inflammatory¹⁸.

Thus, the hypothesis that NAC acts directly protecting the cell damage may be considered, because the properties attributed to the antioxidant NAC and inhibition of inflammatory processes of lung cells are described in studies at different times of reperfusion and with application prior or during ischemia hepatic^{22,24-26}.

The use of NAC 15 minutes before starting the ischemia is based on the biodistribution of drug in plasma and tissues²⁷. Thus its offer directly into the bloodstream are loosely based on reports suggesting that this dose and time prior to application, are suitable for tissue concentrations sufficient to minimize or eliminate the effects of biochemical and structural repercussions on the parenchyma pulmonar²⁷⁻²⁹.

Lung function depends directly on the cell membrane integrity of the alveolar-capillary network of the lung, whose structure is particularly sensitive to factors related to I/R, as the decrease in cellular energy levels and the action of EROs³⁰.

As described in Table 2, the groups subjected to I/R liver without prior administration of NAC, and a period of 24 hours of reperfusion, showed pathological changes in lung parenchyma (alveolar septal thickening, leukocyte infiltration, hemorrhage and pulmonary edema) in quantity higher than the group that received NAC prior to ischemia (Figure 3, A and C). The same finding was found in animals subjected to reperfusion for 48 hours without prior administration of NAC (Figure 3, B and D). Than concluded that NAC decreased lung lesions observed in microscopic HE staining.

In view of theoretical knowledge about the mechanism of action of ischemia and reperfusion can be inferred that there was a stronger action of ROS in the control group, since it is known that they cause direct cellular injury and stimulate the production of inflammatory mediators, thus may have contributed to the increased capillary permeability and the appearance of pulmonary edema. The swelling may have been the result of dysfunction of vascular endothelium mediated primarily by the release of ROS and an imbalance between vasodilators and vasoconstrictors. Literature reports that rats subjected to liver ischemia for a period of 30min and previous administration of NAC was an attenuation of the injuries I/R in the assessment of optical microscopy³¹.

The evaluation of the thickness of the pulmonary alveoli

is a morphological parameter that is involved in reactive processes to a lung injury. This increased thickness may be due to fluid extravasation into the interstitial space or an increase of cellular elements. In the control group, according to table 3, the thickness of the alveoli was significantly higher than the rates displayed by animals in the NAC group, they did so both in the evaluation of 24h as 48h.

At table 4, was observed lower lesions at lung parenchyma in the groups received NAC, this result may be related to antioxidant effect.

Concluded that the lesions were produced at a distance in response to the period from I/R and probably by oxidizing substances derived from reactive oxygen species, since they were inhibited by NAC.

Considering the theoretical and experimental findings and to provide more substantial support that oxygen free radicals may be involved in the mechanism of cellular injury after lung distance hepatic ischemia and reperfusion, we assessed cell apoptosis by immunohistochemical expression of caspase 3. Since the expression of caspase 3 is related to the implementation phase of the process and therefore irreversible, appeared to be a good indicator of their assessment of the damage²⁶.

NAC is one of the antioxidants that have shown promise in preventing and decreasing the deleterious effects of reactive oxygen species. Thus, NAC demonstrated to be an interesting substance, in studying the development of new solutions for organ preservation with a higher antioxidant potential and effectiveness (Figure 4).

New experimental works, with new techniques of application of NAC, are necessary to prove its actual effectiveness in different organs during reperfusion injury especially in distant lesions in other organs and systems.

Conclusions

The previous application of N-acetyl-cysteine protects the lung morphological changes caused by hepatic ischemia reperfusion after periods of 24 and 48 hours. The NAC promotes a decreased expression of caspase 3 in lung tissue resulting from injury caused by the distance hepatic ischemia for prolonged periods of 24 and 48 hours after reperfusion.

References

1. Cazarin M, Saridakis HO. Ação dos antioxidantes na lesão por isquemia e reperfusão. *Interbio*. 2007;1(1):27-33.
2. McCord JM. The superoxide free radical: its biochemistry and

- pathophysiology. *Surgery*. 1983;94(3):412-4.
3. McCord JM. Oxygen-derived free radicals in post ischemic tissue injury. *New Engl J Med*. 1985;312(8):159-60.
4. Galhardo MA, Quireze Jr. C, Navarro PGR, Morello RJ, Simões MJ, Souza EFM. Liver and lung late alterations following hepatic reperfusion associated to ischemic preconditioning or N-acetylcysteine. *Microsurgery*. 2007;27(4):295-9.
5. Miranda LEC, Viaro F, Ceneviva R, Évora PRB. As bases experimentais da lesão por isquemia e reperfusão do fígado. *Revisão. Acta Cir Bras*. 2004;19(1):3-12.
6. Ribeiro ME, Yoshida WB. Lesões intestinais de isquemia e reperfusão: fisiopatologia e modelos experimentais. *J Vasc Br*. 2005;4(2):183-94.
7. Horiguchi T, Harada Y. The effect of protease inhibitor on reperfusion injury after unilateral pulmonary ischemia. *Transplantation*. 1993;55(4):254-8.
8. Tapuria N, Kumar Y, Habib MM, Abu Amara M, Seifalian AM, Davidson BR. Remote ischemic preconditioning: a novel protective method from ischemia reperfusion injury-a review. *J Surg Res*. 2008;150(2):304-30.
9. McKay A, Cassidy D, Sutherland F, Dixon E. Clinical results of N-acetylcysteine after major hepatic surgery: a review. *J Hepatobiliary Pancreat Surg*. 2008;15(5):473-8.
10. Ota S, Nakamura K, Yazawa T, Kawaguchi Y, Baba Y, Kitaoka R, Morimura N, Goto T, Yamada Y, Kurahashi K. High tidal volume ventilation induces lung injury after hepatic ischemia-reperfusion. *Am J Physiol Lung Cell Mol Physiol*. 2007;292(3):L625-31.
11. Esme H, Fidan H, Koken T, Solak O. Effect of lung ischemia-reperfusion on oxidative stress parameters of remote tissues. *Eur J Cardiothorac Surg*. 2006;29(3):294-8.
12. Ben-Abraham R, Guttman M, Flaishon R, Marouani N, Niv D, Weinbroum AA. Mesenteric artery clamping/unclamping-induced acute lung injury is attenuated by N-methyl-D-aspartate antagonist dextromethorphan. *Lung*. 2006;184(6):309-17.
13. Pacheco EG, Ramalho FS, Ramalho LNZ, Zucoloto S, Castro e Silva Jr, O Oliveira AF. Efeitos do pré-condicionamento hepático em ratos cirróticos, submetidos à isquemia e reperfusão hepática resultados preliminares. *Acta Cir Bras*. 2001;16(1):41-3.
14. Sener G, Tosun O, Sehirli AO, Kaçmaz A, Arbak S, Ersoy Y, Ayanoglu-Dülger G. Melatonin and N-acetylcysteine have beneficial effects during hepatic ischemia and reperfusion. *Life Sci*. 2003;72(24):2707-72.
15. Hogg N, Singh RJ, Kalyanaraman B. The role of glutathione in the transport and catabolism of nitric oxide. *FESB*. 1996;382(6):223-8.
16. Walker WM, Kinter MT, Roberts RJ, Spitz DR. Nitric oxide-induced cytotoxicity: involvement of cellular resistance to oxidative stress and the role of glutathione in protection. *Pediatr Res*. 1995;37(1):41-9.
17. Deneke SM. Thiol-based antioxidants. *Curr Top Cell Regul*. 2000;36:151-80.
18. Lakari E. Expression of oxidant and antioxidant enzymes in human lung and interstitial lung diseases. Academic Dissertation of the Faculty of Medicine, University of Oulu, Finland. Disponível em: <http://herkules.oulu.fi/isbn9514266625/html/x494.html>. Acessado em 14.12.2010.
19. Matute-Bello G, Frevert CW, Martin TR. Animal models of acute lung injury. *Am J Physiol Lung Cell Mol Physiol*. 2008;295(3):L379-99.
20. Kallas E, Schnaider TB, Juliano Y, Novo NF, Kallas IE, Engelman MFB, Kallas AC, Castro LF. Modelo de anestesia em coelhos para procedimentos no tórax. *Acta Cir Bras*. 2001;16(2):91-6.
21. Bonetti E, Fantoni DT, Auler Jr JOC. Avaliação da anestesia com baixo fluxo de gases, comparando ventilação com pressão

- controlada a ventilação com tempo controlado - pressão limitada e fluxo constante de gases. Modelo experimental em coelhos. *Rev Bras Anesthesiol.* 2003;53(1):25-38.
22. Weinbroum AA, Rudick V, Ben-Abraham R, Karchevski E. N-acetyl-L-cysteine for preventing lung reperfusion injury after liver ischemia-reperfusion: a possible dual protective mechanism in a dose-response study. *Transplantation.* 2000;69(5):853-9.
 23. Glantzounis GK, Rocks AS, Sheth H, Knight I, Salacinski HJ, Davidson BR, Winyard PG, Seifalian AM. Formation and role of plasma S-nitrosothiols in liver ischemia-reperfusion injury. *Free Radic Biol Med.* 2007;42(6):882-92.
 24. Demiralay R, Gürsan N, Erdem H. The effects of erdosteine, N-acetylcysteine, and vitamin E on nicotine-induced apoptosis of pulmonary cells. *Toxicology.* 2006;219(2):197-207.
 25. Chuang IC, Liu DD, Kao SJ, Chen HI. N-acetylcysteine attenuates the acute lung injury caused by phorbol myristate acetate in isolated rat lungs. *Pulm Pharmacol.* 2007;20(6):726-33.
 26. San-Miguel B, Alvarez M, Culebras JM, González-Gallego J, Tuñón MJ. N-acetyl-cysteine protects liver from apoptotic death in animal model of fulminant hepatic failure. *Apoptosis.* 2006;11(11):1945-57.
 27. Arfsten DP, Johnson EW, Wilfong ER, Jung AE, Bobb AJ. Distribution of radio-labeled N-Acetyl-L-Cysteine in Sprague-Dawley rats and its effect on glutathione metabolism following single and repeat dosing by oral gavage. *Cutan Ocul Toxicol.* 2007;26(2):113-34.
 28. Geudens N, Van De Wauwer C, Neyrinck AP, Timmermans L, Vanhooren HM, Vanaudenaerde BM, Verleden GM, Verbeken E, Lerut T, Van Raemdonck DE. N-acetyl cysteine pre-treatment attenuates inflammatory changes in the warm ischemic murine lung. *J Heart Lung Transplant.* 2007;26(12):1326-32.
 29. Rega FR, Wuyts WA, Vanaudenaerde BM, Jannis NC, Neyrinck AP, Verleden GM, Lerut TE, Van Raemdonck DE. Nebulized N-acetyl cysteine protects the pulmonary graft inside the non-heart-beating donor. *J Heart Lung Transplant.* 2005;24(9):1369-77.
 30. Cardoso JJD. Efeito da ventilação na isquemia-reperfusão pulmonar em ratos [Tese Doutorado]. São Paulo: Universidade Federal de São Paulo, Escola Paulista de Medicina; 1998.
 31. Salim CS, Montero EFS, Simões MJ, Abrahão MS, Ramalho CEB, Fagundes DF. Efeito da N-Acetilcisteína no pulmão após isquemia hepática em ratos. *Acta Cir Bras.* 2002;17(3):177-80.

Correspondence:

Angela Pötter de Castro
Rua Moron, 469
96200-450 Rio Grande - RS Brasil
angelapotterc@hotmail.com

Received: August 09, 2011

Review: October 10, 2011

Accepted: November 14, 2011

Conflict of interest: none

Financial source: none

¹Research performed at Department of Morphology, Laboratory of Histology and Structural Biology, Laboratory of Experimental Surgery and Operative Technique, Federal University of Sao Paulo (UNIFESP) and Laboratory Surgical Technique, Federal University of Rio Grande (FURG). Part of PhD thesis. Tutor: Djalma José Fagundes.