REV BRAS ORTOP. 2015;50(3):324–330

RBO REVISTA BRASILEIRA DE ORTOPEDIA

www.rbo.org.br

Original Article

Low-term results from non-conventional partial arthroplasty for treating rotator cuff arthroplasthy☆

Antônio Carlos Tenor Júnior, José Alano Benevides de Lima, Iúri Tomaz de Vasconcelos, Miguel Pereira da Costa, Rômulo Brasil Filho, Fabiano Rebouças Ribeiro*

Orthopedics and Traumatology Service, Hospital do Servidor Público Estadual de São Paulo, São Paulo, SP, Brazil

ARTICLE INFO

Article history:
Received 29 January 2014
Accepted 5 June 2014
Available online 23 April 2015

Keywords:
Replacement arthroplasty
Shoulder
Rotator cuff

ABSTRACT

Objective: To evaluate the evolution of the functional results from CTA® hemiarthroplasty for surgically treating degenerative arthroplathy of the rotator cuff, with a mean follow-up of 5.4 years.

Methods: Eighteen patients who underwent CTA® partial arthroplasty to treat degenerative arthroplathy of the rotator cuff between April 2007 and June 2009 were reevaluated, with minimum and mean follow-ups of 4.6 years and 5.4 years, respectively. Pre and postoperative parameters for functionality and patient satisfaction were used (functional scale of the University of California in Los Angeles, UCLA). All the patients underwent prior conservative treatment for 6 months and underwent surgical treatment because of the absence of satisfactory results. Patients were excluded if they presented any of the following: previous shoulder surgery; pseudoparalysis; insufficiency of the coracoacromial arch (type 2 B in Seebauer's classification); neurological lesions; or insufficiency of the deltoid muscle and the subscapularis muscle.

Results: With a mean follow-up of 5.4 years, 14 patients considered that they were satisfied with the surgery (78%); the mean range of joint motion for active elevation improved from 55.8° before the operation to 82.0° after the operation; the mean external rotation improved from 18.9° before the operation to 27.3° after the operation; and the mean medial rotation remained at the level of the third lumbar vertebra. The mean UCLA score after the mean follow-up of 5.4 years was 23.94 and this was an improvement in comparison with the preoperative mean and the mean 1 year after the operation.

Conclusion: The functional results from CTA® hemiarthroplasty for treating rotator cuff arthroplasty in selected patients remained satisfactory after a mean follow-up of 5.4 years.

© 2014 Sociedade Brasileira de Ortopedia e Traumatologia. Published by Elsevier Editora Ltda. All rights reserved.

☆ Work developed in the Shoulder and Elbow Group, State Public Servants' Hospital, São Paulo, SP, Brazil.

* *Corresponding author.*
E-mail: actenorjr@hotmail.com (A.C. Tenor Júnior).

http://dx.doi.org/10.1016/j.rboe.2015.04.006

2255-4971/© 2014 Sociedade Brasileira de Ortopedia e Traumatologia. Published by Elsevier Editora Ltda. All rights reserved.

Resultados em longo prazo da artroplastia parcial não convencional para o tratamento da artroplastia do manguito rotador

Palavras-chave:
Artroplastia de substituição
Ombro
Manguito rotador

RESUMO

Objetivo: Avaliar a evolução do resultado funcional da hemiartroplastia CTA® no tratamento cirúrgico da artropatia degenerativa do manguito rotador com um seguimento médio de 5,4 anos.

Métodos: Foram reavaliados 18 pacientes submetidos à artroplastia parcial CTA® para o tratamento da artropatia degenerativa do manguito rotador entre abril de 2007 e junho de 2009, com seguimento mínimo e médio de 4,6 anos e 5,4 anos, respectivamente. Foram usados parâmetros pré e pós-operatórios de funcionalidade e satisfação dos pacientes (escala funcional da Universidade da Califórnia em Los Angeles [UCLA]). Todos os pacientes fizeram tratamento conservador prévio por seis meses e foram submetidos ao tratamento cirúrgico na ausência de resultado satisfatório. Foram excluídos pacientes com cirurgia prévia no ombro, pseudoparalisia, insuficiência do arco coracoacromial (tipo 2 B da classificação de Seebauer), lesão neurológica ou insuficiência do músculo deltoide e do músculo subescapular.

Resultados: Com um seguimento médio de 5,4 anos, 14 pacientes se consideravam satisfeitos com a cirurgia (78%). A amplitude de movimento articular melhorou na elevação ativa média e variou de 55,8° no pré-operatório para 82° no pós-operatório. A rotação externa média melhorou de em média 18,9° no pré-operatório para 27,3° no pós-operatório. A média da rotação medial manteve-se no nível da terceira vértebra lombar. O escore UCLA médio, após seguimento médio de 5,4 anos, foi de 23,94 e melhorou em comparação com as médias pré-operatória e do primeiro ano pós-operatório.

Conclusão: Os resultados funcionais da hemiartroplastia CTA® no tratamento da artroplastia do manguito rotador em pacientes selecionados mantiveram-se satisfatórios após um seguimento médio de 5,4 anos.

© 2014 Sociedade Brasileira de Ortopedia e Traumatologia. Publicado por Elsevier Editora Ltda. Todos os direitos reservados.

Introduction

The first author to describe the clinical findings from arthropathy of the rotator cuff was Robert Adams, in 1857. In 1981, Halverson et al.[1] described the "Milwaukee shoulder", in which crystals of calcium phosphate such as hydroxyapatite were involved in a cellular reaction with release of collagenases and joint destruction. However, Neer was the first to use the term "arthropathy of the rotator cuff", in 1977, in a study published in 1983.[2] Neer believed that extensive injury to the rotator cuff was the cause of the arthropathy and presented the hypothesis that this pathological condition might be the result of mechanical factors such as anterosuperior instability, and nutritional factors such as loss of the closed joint space, with impairment of nutrient diffusion to the joint surface. Interruption of the bone circulation that is provided by the rotator cuff also contributes toward the metabolic loss at the humeral head. The final result from these mechanical and metabolic alterations, in association with osteopenia through disuse of the glenohumeral joint due to pain, consists of collapse of the glenohumeral joint.[1–4]

More recently, in 1997, Collins and Harryman[5] produced a synthesis from the two theories and formulated the hypothesis that cranial migration of the humeral head, resulting from loss of the stability that the rotator cuff provides, leads to abnormal glenohumeral contact and formation of debris in the joint. Thus, an inflammatory cascade caused by the calcium phosphate crystals that are released is developed.

The incidence of rotator cuff injuries increases with age. They are relatively rare before the age of 40 years, become more frequent in the fifth and sixth decades of life and continue to increase in the seventh decade and beyond. Many cases do not present symptoms and approximately 50% of all individuals over the age of 80 years may have asymptomatic rotator cuff injuries.[6,7]

Arthropathy of the rotator cuff mainly affects elderly women on their dominant side and it triggers chronic symptoms such as progressive pain, which worsens at night and with activities that require use of the shoulder. Other symptoms include weakness and difficulty in raining the arm, and these give rise to functional limitation. Physical examination reveals signs of extensive injury to the rotator cuff, such as atrophy of the supraspinatus and infraspinatus muscles.[2,8–10]

Radiographs show glenohumeral arthrosis, with cranial displacement of the humeral head, which may give rise to abnormal contact between this and the coracoacromial arch and thus lead to "rounding" of the greater tubercle ("femoralization") and to concave erosion of the coracoacromial arch ("acetabulization"). Using radiographs in anteroposterior (AP) view, Hamada et al.[11] described the natural evolution of extensive rotator cuff injuries, with the development of

degenerative arthropathy, and proposed a classification system consisting of five evolutionary stages. However, these do not guide the therapy.

Seebauer[12] developed a biomechanical, functional and morphological classification system that presents therapeutic relevance and assesses the integrity of the anterior stabilizers of the shoulder and coracoacromial arch, the presence of dynamic stability and the upward migration of the humeral head. Additional examinations, such as computed tomography and magnetic resonance imaging, are not necessary for diagnosing arthropathy of the rotator cuff, but they help in making preoperative assessments to analyze the bone stock and the conditions of the rotator cuff, such as fatty degeneration.[12–14]

Treatments for arthropathy of the rotator cuff should be started using non-surgical methods, such as modification of activities, use of analgesic and/or anti-inflammatory medications and use of subacromial corticosteroid infiltration.[6,15]

Surgical treatment is indicated for patients who do not respond to conservative treatment. Procedures such as arthroplasty to resect the humeral head and glenohumeral arthrodesis are considered to be salvage methods, to be used in patients presenting multiple surgical failures, deficiency of the deltoid muscle and infection. Arthroscopy for debridement, tenotomy of the biceps and tuberculoplasty can be performed, particularly in elderly patients and those with low functional demands. Conventional total arthroplasty of the shoulder is now contraindicated in patients presenting arthropathy of the rotator cuff because of the high rate of loosening of the glenoid component. The current alternative arthroplasty options for arthroplasty of the rotator cuff are non-conventional (CTA®) partial arthroplasty and use of a reverse prosthesis.[3,16–18]

CTA® partial arthroplasty presents greater lateral extent with coverage of the tubercle and produces better contact and connection with the coracoacromial arch (Figs. 1 and 2). Reverse prostheses are based on the concepts of Gramont et al.,[19] involving moving the center of rotation medially and distally, with gains in deltoid muscle function. This principle

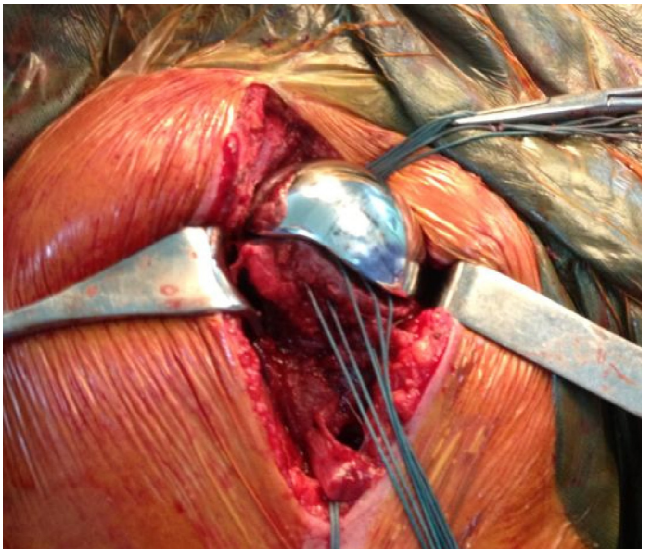

Fig. 1 – CTA prosthesis with its lateral extent, shown on intraoperative photo taken by the author.

Fig. 2 – CTA prosthesis shown on postoperative radiograph produced by the author.

improved the stability of the implant and the range of motion. Nonetheless, despite the good results from reverse prostheses, this is a technically more complex procedure with higher complication rates (5% to 33%). CTA® hemiarthroplasty presents good results in selected patients, with lower incidence of complications than that of reverse prostheses.[3,20–24]

Patients who are candidates for CTA® hemiarthroplasty need to be free from pseudoparalysis, present a coracoacromial arch that maintains the relative kinematics of the shoulder joint, without anterosuperior escape (Seebauer types IA, IB and IIA), absence of previous surgery involving resection of the coracoacromial arch, functioning motor (intact deltoid) and sufficient subscapular muscle.[3,25–28]

The objective of this study was to evaluate the evolution of the functional results from CTA® partial arthroplasty for surgically treating degenerative arthropathy of the rotator cuff, after a mean follow-up of 5.4 years.

Methods

Between December 2006 and June 2009, 23 shoulders of 23 patients underwent CTA® partial arthroplasty to treat arthropathy of the rotator cuff. During a mean follow-up of 1.6 years, there were improvements in the clinical parameters and UCLA score, as described in the paper by Brasil Filho et al.[14] These patients were evaluated prospectively in the present study after a mean follow-up of 5.4 years.

Among the 23 patients who were included in the first study, three were excluded from the present study because they had died in the meantime and two because they were lost from the follow-up. Thus, 18 patients remained in the study (Table 1). Among these, there was one patient who evolved with late postoperative infection and required surgery to remove the prosthesis.

All the patients were operated by the same surgical team (from the Shoulder and Elbow Group of the State of São Paulo

Table 1 – Patient data.

Patient	Sex	Time since op (years)	Age	Side	UCLA before op	UCLA one year after op	UCLA final evaluation	Elev/ext rot/med rot before op	Elev/ext rot/med rot after op
1	M	6.7	86	D	1+2+1+3+0=7	10+4+1+3+0=18	10+4+2+2+0=18	30/10/L2	40/10/L2
2	M	6.6	69	D	2+2+2+3+0=9	8+4+3+3+5=23	10+10+5+4+5=34	80/40/L3	120/50/L2
3	M	6.5	79	ND	2+4+3+3+0=12	8+6+3+3+5=25	8+8+4+3+5=28	54/0/T11	130/10/T8
4	F	6.0	89	D	2+4+3+2+0=11	8+6+3+3+5=22	8+6+3+3+5=25	40/10/L1	56/10/L1
5	F	5.8	67	ND	2+2+1+3+0=8	10+6+2+3+5=26	10+8+2+2+5=27	50/20/T12	70/40/T11
6	F	5.7	88	D	2+2+0+3+0=7	8+6+2+4+0=20	8+6+3+3+0=20	68/24/T12	80/30/T12
7	F	5.5	77	D	2+4+1+2+0=9	8+4+1+3+5=21	10+4+0+2+5=21	12/10/L5	20/20/L3
8	F	5.4	81	D	2+2+2+3+0=9	8+8+3+4+5=28	8+6+3+3+5=25	60/40/L1	110/44/L1
9	F	5.2	73	D	2+2+1+3+0=8	4+4+3+3+0=14	2+4+3+3+0=12	62/10/L1	90/20/L2
10	F	5.1	84	D	2+2+2+2+0=8	4+6+3+2+0=25	6+4+3+4+0=17	60/20/T11	70/20/T10
11	F	5.0	78	D	2+4+3+2+0=11	6+8+5+4+5=28	6+8+5+4+5=28	70/20/L2	120/36/L2
12	F	4.9	72	ND	2+2+0+2+0=6	8+4+2+3+5=22	8+8+3+4+5=28	56/40/L3	70/44/L2
13	F	4.7	70	ND	2+4+3+2+0=11	8+6+2+3+5=24	8+6+2+3+5=24	50/16/L1	60/30/T12
14	F	4.6	74	D	2+2+2+3+0=9	4+4+3+4+5=20	8+8+5+4+5=30	60/10/T10	110/20/T8
15	F	4.6	83	D	2+2+1+3+0=8	6+4+2+3+5=18	6+4+3+3 +5 =21	52/10/Trochanter	70/26/Sacrum
16	F	4.6	81	D	2+4+3+2+0=11	8+8+4+4+5=29	8+6+4+4+5=27	70/10/T10	120/22/T8
17	F	5.2	87	D	1+2+3+3+0=9	6+4+3+3+5=21	6+4+3+3+5=21	40/20/L3	60/30/L3
18	F	6.0	66	ND	2+2+2+3+0=9	8+4+3+4+5=24	8+6+2+4+5=25	90/30/L5	80/30/L5

M, male; F, female; D, dominant side; ND, non-dominant side; Elev, elevation; ext rot, external rotation; med rot, medial rotation; op, operation; UCLA, University of California, Los Angeles.

Public Servants' Hospital). A deltopectoral access route was used.

The length of postoperative follow-up ranged from 4.6 to 6.7 years, with a mean of 5.4. The mean age was 78 years. The dominant limb was affected in 13 patients (72.2%).

The Seebauer classification was used.[12] In stage IA, the head is centered in the glenoid; in IB, the head migrates medially and the glenohumeral space becomes pinched; in IIA, the humeral head migrates superiorly, but is stabilized by the coracoacromial arch, which remains intact; and in IIB, the humeral head migrates anterosuperiorly, due to insufficiency of the coracoacromial arch.

Among the 18 patients included in this study, three were classified before the operation as Seebauer lA, seven as lB and eight as llA.

The inclusion criteria were that the patients needed to be symptomatic and classified as Seebauer lA, lB and llA, who did not improve with conservative treatment over a minimum of six months. The exclusion criteria were situations in which the patients improved through clinical treatment or presented previous surgery or neurological lesions in the limb affected, arthropathy classified as Seebauer llB or insufficiency of the deltoid muscle and subscapularis muscle.

In evaluating the results, the functional scale of the University of California in Los Angeles (UCLA) was used, as modified by Ellman and Kay.[29] To evaluate satisfaction, the Neer criteria were used. To measure the range of motion, the method of the American Academy of Orthopedic Surgeons was used. To compare the UCLA score and range-of-motion results, the nonparametric Friedman test was used.[27–30]

The statistical significance of the differences in means between the quantitative variables was ascertained by means of the paired Student's *t* test and the differences in variance were ascertained by means of analysis of variance (ANOVA). The normality of the variables was tests using the Shapiro–Wilk test. All of the analyses were performed using a significance level of 5%. Results with *p*-values <0.05 were considered to be statistically significant. Two-tailed optional hypotheses were always envisaged.

The information gathered formed a database that was developed using the Excel® software for Windows and the statistical analysis was performed using the Stata® 11 SE and SPSS® 16.0 software.

Results

After a mean follow-up of 5.4 years, 14 patients considered that they were satisfied with the surgery (78%). Among the four who were dissatisfied, three complained about their lack of gain in range of motion, although they reported having achieved an improvement in pain in relation to before the operation. For one patient, the dissatisfaction was due mainly to pain (Fig. 3).

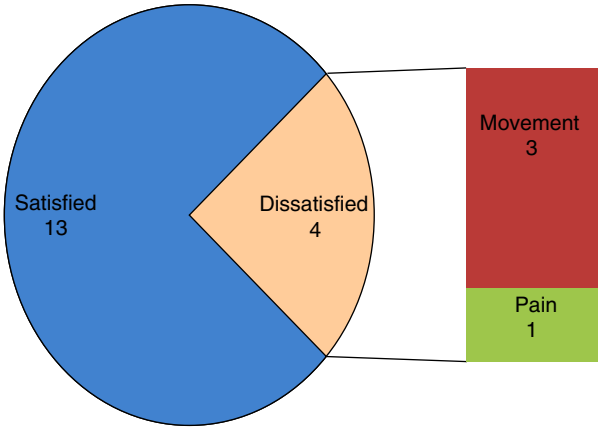

Fig. 3 – Patient distribution according to satisfaction level after the operation.

Table 2 – P values for the variables of the UCLA score, compared between before the operation, after one year of follow-up and at final evaluation.

Variables	Before operation		One year afterwards		Final evaluation		p
	Mean (SP)	Min–Max	Mean (SP)	Min–Max	Mean (SP)	Min–Max	
Pain	1.89 (0.32)	1–2	7.22 (1.83)	4–10	7.67 (1.97)	2–10	<0.001
Function	2.67 (0.97)	2–4	5.33 (1.53)	4–8	6.11 (1.88)	4–10	<0.001
Active flexion	1.83 (1.04)	0–3	2.67 (0.97)	1–5	3.06 (1.26)	0–5	<0.001
Flexion force	2.61 (0.50)	2–3	3.28 (0.57)	2–4	3.22 (0.73)	2–4	0003
Satisfaction	0.00 (0.00)	0–0	3.89 (2.14)	0–5	3.89 (2.14)	0–5	<0.001
UCLA score	9.00 (1.64)	6–12	22.39 (4.23)	14–29	23.94 (5.30)	12–34	<0.001

In relation to the range of motion after a mean follow-up of 5.4 years, there was an improvement in the mean active elevation, which went from 55.8° before the operation to 82° after the operation. The mean external rotation improved from 18.9° before the operation to 27.3° after the operation (Fig. 4). The mean medial rotation remained at the level of the third lumbar vertebra.

The mean UCLA score after the mean follow-up of 5.4 years was 23.94 and this was a significant improvement in comparison with the preoperative mean of nine ($p < 0.001$). A small improvement was observed in relation to the mean after the first postoperative year (22.39), but without statistical significance. The mean pain level was 7.67, with a range from 2 to 10; function was 6.11, ranging from 4 to 10; active flexion was 3.06, ranging from 0 to 5; anterior flexion force was 3.22, ranging from 2 to 4; and satisfaction was 3.89, ranging from zero to 5. There were statistically significant improvements in all the criteria for assessing the UCLA score (Table 2 and Fig. 5).

There were significant improvements between the pre and postoperative evaluations, both at one year after the operation and at the end of the follow-up. However, there was no statistically significant change between the two postoperative evaluations, performed at means of one and 5.4 years after the operation (Table 3).

Discussion

CTA® partial arthroplasty for treating arthropathy of the rotator cuff is a relatively recent procedure, with few studies available in the literature, especially with long-term follow-ups.[3,31,32]

Vitotsky et al.[13] conducted a study with a mean follow-up of 32 months and minimum of two years, on 60 patients who underwent CTA® partial arthroplasty, including Seebauer IA, IB and IIA patients. They obtained satisfactory results in 89% of the cases, with mean improvements of 22° in external rotation and 60° in flexion. In our sample, after a minimum follow-up of 4.6 years and mean of 5.4 years, among 18 CTA® partial arthroplasty procedures in 18 patients, the mean satisfaction rate obtained was 78%, with a mean improvement in elevation from 55.8° to 82° and in external rotation from 18.9° to 27.3°. Just as in our study, Vitotsky et al.[13] did not include Seebauer IIB patients.

Over a mean follow-up of 3.7 years, Goldberg et al.[18] obtained a satisfaction rate of 78%, with mean improvements of 33° in elevation and 23° in external rotation through using conventional hemiarthroplasty. The patients with a minimum elevation of 90° achieved the best results. In our study, patients with elevations of less than 90° were excluded.

In a study with a mean follow-up of 28.2 months on 15 cases of hemiarthroplasty, Zuckerman et al.[26] obtained mean improvements of 17° in elevation and 14° in lateral rotation.

Fig. 4 – Comparison of the mean angles of elevation and external rotation from before to after the operation.

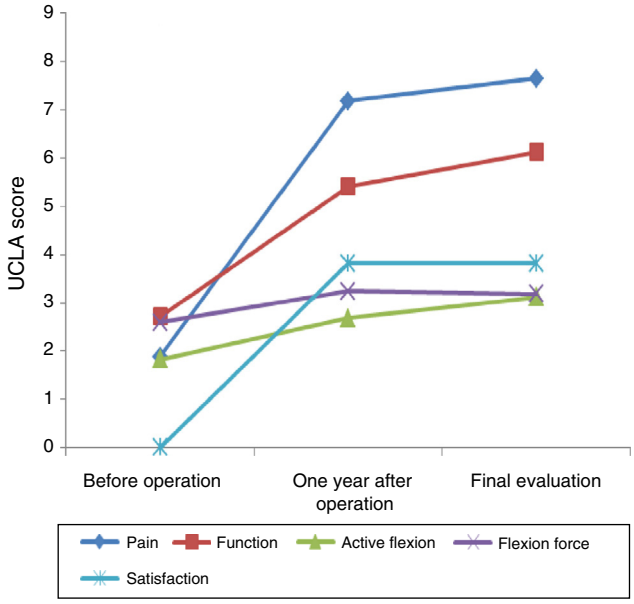

Fig. 5 – Comparison of the UCLA scores before the operation, one year afterwards and at the final evaluation.

Table 3 – P values for the variables of the UCLA score over separate times.

	Pain	Function	Active flexion	Flexion force	Satisfaction	UCLA score
Before operation vs. one year after operation	$p<0.001$	$p<0.001$	$p<0.002$	$p<0.002$	$p<0.001$	$p<0.001$
Before operation vs. final evaluation	$p<0.001$	$p<0.001$	$p<0.003$	$p<0.005$	$p<0.001$	$p<0.001$
One years after operation vs. final evaluation	$p=0.157$	$p=0.448$	$p=0.207$	$p=1.00$	$p=1.00$	$p=0.303$

The satisfaction rate among the patients was 87% and the UCLA score improved from 11 to 22 points.

Checchia et al.[33] followed up 11 patients who underwent hemiarthroplasty to treat arthropathy of the rotator cuff, for a mean of 69 months. They obtained a pain improvement rate of 81.8%, satisfactory results in 54% and a mean UCLA score of 22.7 points. These authors observed that certain factors were associated with unsatisfactory evolution, such as previous surgery on the shoulder with impairment of the coracoacromial arch and previous injury of the deltoid muscle. In our sample, patients with previous shoulder surgery and those classified as Seebauer IIB were excluded.

In our study, patients whose main preoperative symptom was limitation of movements presented unsatisfactory results after the surgery, such that three of the four dissatisfied patients reported this complaint. This finding is in conformity with the study by Nam et al.[34]

The UCLA functional score, which assesses pain, function, active flexion, anterior flexion force and satisfaction, improved from poor (mean of nine points) before the operation, to reasonable after follow-ups of one year and 5.4 years (means of 22.39 and 23.94 points, respectively), which confirmed that hemiarthroplasty was a good option for surgically treating arthropathy of the rotator cuff in selected patients. There was a statistically significant improvement in UCLA, in relation to before the operation, while the difference between the mean postoperative times of one year and 5.4 years was small and non-significant. This can be understood as maintenance of the positive results from the prosthesis over this postoperative period.

Since this is a surgical procedure indicated for elderly patients, one of the factors that caused difficulty in carrying out the present study was in relation to making long-term reevaluations on all the patients, because of deaths and loss of follow-up.

Conclusion

The functional results from non-conventional CTA® partial arthroplasty for treating arthropathy of the rotator cuff in selected patients remained satisfactory after a mean follow-up of 5.4 years.

Conflicts of interest

The authors declare no conflicts of interest.

REFERENCES

1. Halverson PB, Cheung HS, McCarty DJ, Garancis J, Mandel N. Milwaukee shoulder: association of microspheroids containing hydroxyapatite crystals, active collagenase, and neutral protease with rotator cuff defects II. Synovial fluid studies. Arthritis Rheum. 1981;24(3):474–83.
2. Neer CS 2nd, Craig EV, Fukuda H. Cuff-tear arthropathy. J Bone Joint Surg Am. 1983;65(9):1232–44.
3. Rockwood CA, Matsen FA, editors. The shoulder. 6th ed. Philadelphia: Saunders/Elsevier; 2009.
4. Cofield RH, Parvizi J, Hoffmeyer PJ, Lanzer WL, Ilstrup DM, Rowland CM. Surgical repair of chronic rotator cuff tears. A prospective long-term study. J Bone Joint Surg Am. 2001;83(1):71–7.
5. Collins DN, Harryman DT 2nd. Arthroplasty for arthritis and rotator cuff deficiency. Orthop Clin N Am. 1997;28(2): 225–39.
6. Bokor DJ, Hawkins RJ, Huckell GH, Angelo RL, Schickendantz MS. Results of nonoperative management of full-thickness tears of the rotator cuff. Clin Orthop Relat Res. 1993;(294):103–10.
7. Zumstein MA, Jost B, Hempel J, Hodler J, Gerber C. The clinical and structural long-term results of open repair of massive tears of the rotator cuff. J Bone Joint Surg Am. 2008;90(11):2423–31.
8. Ecklund KJ, Lee TQ, Tibone J, Gupta R. Rotator cuff tear arthropathy. J Am Acad Orthop Surg. 2007;15(6):340–9.
9. Zeman CA, Arcand MA, Cantrell JS, Skedros JG, Burkhead WZ Jr. The rotator cuff-deficient arthritic shoulder: diagnosis and surgical management. J Am Acad Orthop Surg. 1998;6(6):337–48.
10. Jensen KL, Williams GR Jr, Russell IJ, Rockwood CA Jr. Rotator cuff tear arthroplasthy. J Bone Joint Surg Am. 1999;81(9):1312–24.
11. Hamada K, Fukuda H, Mikasa M, Kobayashi Y. Roentgenographic findings in massive rotator cuff tears: a long-term observation. Clin Orthop Relat Res. 1990;(254): 92–6.
12. Seebauer L. Biomecanical classification of cuff tear arthropaty [abstract]. In: Global shoulder society meeting. 2003. p. 17–9.
13. Visotsky JL, Basamania C, Seebauer L, Rockwood CA Jr, Jensen KL. Cuff tear arthroplasthy: pathogenesis, classification, and algorithm for treatment. J Bone Joint Surg Am. 2004; 86(Suppl 2):35–40.
14. Brasil Filho R, Ribeiro FR, Tenor Junior AC, Filardi Filho CS, Costa GBL, Storti TM, et al. Resultados do tratamento cirúrgico da artroplastia degenerativa do manguito rotador utilizando hemiartroplastia CTA®. Rev Bras Ortop. 2012;47(1):66–72.
15. Zvijac JE, Levy HJ, Lemak LJ. Arthroscopic subacromial decompression in the treatment of full thickness rotator cuff tears: a 3- to 6-year follow-up. Arthroscopy. 1994;10(5):518–23.
16. Arntz CT, Matsen FA 3rd, Jackins S. Surgical management of complex irreparable rotator cuff deficiency. J Arthroplasty. 1991;6(4):363–70.
17. Franklin JL, Barrett WP, Jackins SE, Matsen FA 3rd. Glenoid loosening in total shoulder arthroplasty: association with rotator cuff deficiency. J Arthroplasty. 1988;3(1):39–46.
18. Goldberg SS, Bell JE, Kim HJ, Bak SF, Levine WN, Bigliani LU. Hemiarthroplasty for the rotator cuff-deficient shoulder. J Bone Joint Surg Am. 2008;90(3):554–9.
19. Grammont P, Trouilloud P, Laffay JP, Deries X. Concept study and realization of a new total shoulder prosthesis. Rheumatologie. 1987;39:407–18 [French].

20. Sirveaux F, Favard L, Oudet D, Huquet D, Walch G, Molé D. Grammont inverted total shoulder arthroplasty in the treatment of glenohumeral osteoarthritis with massive rupture of the cuff Results of a multicentre study of 80 shoulders. J Bone Joint Surg Br. 2004;86(3):388–95.
21. Young SW, Everts NM, Ball CM, Astley TM, Poon PC. The SMR reverse shoulder prosthesis in the treatment of cuff-deficient shoulder conditions. J Shoulder Elbow Surg. 2009;18(4):622–6.
22. Boileau P, Watkinson DJ, Hatzidakis AM, Balg F. Grammont reverse prosthesis: design, rationale, and biomechanics. J Shoulder Elbow Surg. 2005;14(Suppl 1):147S–61S.
23. Werner CM, Steinmann PA, Gilbart M, Gerber C. Treatment of painful pseudoparesis due to irreparable rotator cuff dysfunction with the Delta III reverse-ball-and-socket total shoulder prosthesis. J Bone Joint Surg Am. 2005;87(7):1476–86.
24. Frankle M, Siegal S, Pupello D, Saleem A, Mighell M, Vasey M. The Reverse Shoulder Prosthesis for glenarthritis associated with severe rotator cuff deficiency: a minimum two-year follow-up study of sixty patients. J Bone Joint Surg Am. 2005;87(8):1697–705.
25. Sanchez-Sotelo J, Cofield RH, Rowland CM. Shoulder hemiarthroplasty for glenohumeral arthritis associated with severe rotator cuff deficiency. J Bone Joint Surg Am. 2001;83(12):1814–22.
26. Zuckerman JD, Scott AJ, Gallagher MA. Hemiarthroplasty for cuff tear arthropathy. J Shoulder Elbow Surg. 2000;9(3):169–72.
27. Hawkins RJ, Bokor DJ. Clinical evaluation of shoulder problems. In: Rockwood CA, Matsen FA, editors. The shoulder. 2nd ed. Saint Louis: Saunders; 1998. p. 164–98.
28. Vieira S. Bioestatística: tópicos avançados. 3rd ed. Rio de Janeiro: Elsevier; 2010.
29. Ellman H, Kay SP. Arthroscopic subacromial decompression for chronic impingement. Two- to five-year results. J Bone Joint Surg Br. 1991;73(3):395–8.
30. Neer CS 2nd, Watson KC, Stanton FJ. Recent experience in total shoulder replacement. J Bone Joint Surg Am. 1982;64(3):319–37.
31. Trail I. Early results with a specific hemiarthroplasty for cuff tear arthropathy. Pers Commun. 2007.
32. Basamania C. Hemiarthroplasty for cuff tear arthroplasthy. In: Zuckermann JD, editor. Advanced reconstruction: shoulder. Rosemont: American Academy of Orthopaedic Surgeons; 2007. p. 567–78.
33. Checchia SL, Santos PD, Miyazaki NA, Fregoneze M, Silva LA, Leite FSF, et al. Avaliação dos resultados da artroplastia parcial de ombro para tratamento da artroplastia por lesão do manguito rotador. Rev Bras Ortop. 2008;43(6): 232–9.
34. Nam D, Maak TG, Raphael BS, Kepler CK, Cross MB, Warren RF. Rotator cuff tear arthropathy: evaluation, diagnosis, and treatment: AAOS exhibit selection. J Bone Joint Surg Am. 2012;94(6):e34.