



## Original Article

# Bilateral developmental dysplasia of the hip treated with open reduction and Salter osteotomy: analysis on the radiographic results<sup>☆,☆☆</sup>

Anastácio Kotzias Neto<sup>\*</sup>, Adriana Ferraz, Franco Bayer Foresti, Rafael Barreiros Hoffmann

Hospital Infantil Joana de Gusmão, Florianópolis, SC, Brazil

## ARTICLE INFO

### Article history:

Received 10 March 2013

Accepted 10 October 2013

Available online 5 April 2014

### Keywords:

Hip dislocation,  
congenital/pathology  
Hip dislocation, congenital/etiology  
Hip dislocation, congenital/surgery  
Hip dislocation, congenital/therapy

## ABSTRACT

**Objectives:** to evaluate the radiographic results from patients with bilateral developmental dysplasia of the hip (DDH) who underwent surgical treatment by means of open reduction and Salter osteotomy, with or without associated femoral shortening as described by Ombrédanne.

**Methods:** this was a retrospective descriptive study in which 21 patients with bilateral DDH (42 hips) were analyzed. They were treated at Hospital Infantil Joana de Gusmão (HIJG), with operations between August 1997 and October 2009. To evaluate the radiographic results, the acetabular index and the Wiberg center-edge angle were measured, and the Severin and Kalamchi-MacEwen classifications were used. Descriptive and parametric statistical analyses were used to evaluate the data.

**Results:** we did not observe any statistically significant difference in analyzing the radiographic parameters, making comparisons regarding the side affected, the order of the procedures and whether femoral shortening was performed, although there was a significant difference between them from before to after the operation.

**Conclusion:** open reduction in association with iliac osteotomy as described by Salter presented significant improvements in the radiographic parameters analyzed, comparing the pre- and postoperative values. This improvement occurred independently of whether Ombrédanne femoral shortening was performed. The most prevalent complication in the study group was avascular necrosis of the femoral head.

© 2014 Sociedade Brasileira de Ortopedia e Traumatologia. Published by Elsevier Editora Ltda. All rights reserved.

## Displasia do desenvolvimento do quadril bilateral tratada com redução cruenta e osteotomia de Salter: análise dos resultados radiográficos

## RESUMO

**Objetivos:** avaliar os resultados radiográficos de pacientes portadores de displasia do desenvolvimento do quadril (DDQ) bilateral, submetidos ao tratamento cirúrgico por meio da

### Palavras-chave:

Luxação congênita de quadril/  
patologia

<sup>☆</sup> Please cite this article as: Kotzias Neto A, Ferraz A, Bayer Foresti F, Barreiros Hoffmann R. Displasia do desenvolvimento do quadril bilateral tratada com redução cruenta e osteotomia de Salter: análise dos resultados radiográficos. Rev Bras Ortop. 2014;49:350-358.

<sup>☆☆</sup> Work performed at the Orthopedics and Traumatology Service, Hospital Infantil Joana de Gusmão, Florianópolis, SC, Brazil.

<sup>\*</sup> Corresponding author.

E-mail: [akotzias@kotzias.com.br](mailto:akotzias@kotzias.com.br) (A. Kotzias Neto).

Luxação congênita de  
quadril/etiologia  
Luxação congênita de  
quadril/cirurgia  
Luxação congênita de  
quadril/terapia

redução cruenta e osteotomia de Salter associada ou não ao encurtamento femoral descrito por Ombrédanne.

**Métodos:** trata-se de estudo descritivo retrospectivo com análise de 21 pacientes com DDQ bilateral (42 quadris), tratados no Hospital Infantil Joana de Gusmão (HIJG) e operados entre agosto de 1997 e outubro de 2009. Para avaliação dos resultados radiográficos, foram medidos o índice acetabular e o ângulo *center-edge* (CÊ) de Wiberg e usadas as classificações de Severin e de Kalamchi e MacEwen. Análises estatísticas descritivas e paramétricas foram usadas para avaliação dos dados.

**Resultados:** não observamos diferença estatisticamente significativa na análise dos parâmetros radiográficos comparando-os quanto ao lado acometido, à ordem dos procedimentos e à feitura de encurtamento femoral ou não, embora exista diferença significativa entre eles nos períodos pré e pós-operatório.

**Conclusão:** redução cruenta associada à osteotomia do íliaco descrita por Salter apresentou melhoria significativa dos parâmetros radiográficos analisados na comparação dos valores pré e pós-operatórios. Essa melhoria ocorreu independentemente da feitura ou não do encurtamento femoral de Ombrédanne. A complicação mais prevalente no grupo estudado foi a necrose avascular da cabeça femoral.

© 2014 Sociedade Brasileira de Ortopedia e Traumatologia. Publicado por Elsevier Editora Ltda. Todos os direitos reservados.

## Introduction

Developmental dysplasia of the hip (DDH) comprises a spectrum of abnormalities during the development of this joint that vary according to the patient's age and go from self-limiting defects without long-term consequences to dislocation that may lead to permanent deficiency.<sup>1</sup> In cases in which dislocation of the hip occurs, the acetabulum presents a deficiency in its anterosuperior aspect and is shown to be thick, shallow and oblique.<sup>2</sup> The etiology is multifactorial, with genetic, hormonal and environmental causes, but it is believed that the primary cause is restriction of the movements of the fetus or hyperelasticity of the joint capsule of the hip.<sup>3</sup>

The incidence of DDH with dislocation is around one in every thousand live births. It is more prevalent in children with pelvic presentation, females and children with a positive family history (12% to 33%).<sup>3-6</sup>

The prognosis for DDH is directly linked to early diagnosis, which enables treatment that is more effective and less aggressive toward the patient.<sup>7</sup> However, a considerable number of cases are diagnosed after the child starts to walk.<sup>8</sup> The treatment has the aim of recovering joint congruence and stability, so as to promote its physiological development. When instituted within the first days of life, a high success rate and reduced complication rate are achieved. As the child grows, the anatomical alterations increase, which makes the treatment more difficult.<sup>9,10</sup> In smaller children, the treatment begins with closed reduction by means of a Pavlik harness, which is effective in up to 95% of the cases.<sup>3</sup> After the age of six months, the harness loses its efficacy and the recommended treatment becomes closed reduction with plaster-cast immobilization. In children over the age of 18 months, the treatment varies from closed reduction with plaster-cast immobilization to open reduction in association with osteotomy. The treatment described by Salter is the preferred procedure and it may or may not be used in association with the femoral shortening described by Ombrédanne.<sup>3,11-13</sup>

The importance of early identification and adequate treatment for this disease is to prevent its sequelae, such as deformity of the femoral head, anteversion of the femoral neck, valgus thigh and dysplastic acetabulum, which evolve to hip arthrosis.<sup>14,15</sup>

The objective of this study was to evaluate the radiographic results from patients who underwent surgical treatment for bilateral dislocation, with open reduction combined with Salter's osteotomy, in association with Ombrédanne's femoral shortening when necessary.

## Material and methods

This was a retrospective descriptive study. The medical files of all the patients with DDH attended at the Joana de Gusmão Children's Hospital (HIJG) between August 1997 and October 2009 were reviewed. Treatment was provided for 296 patients: 70 (23.65%) using Pavlik's harness, 93 (31.42%) with closed reduction that was maintained using a plaster case from the pelvis to the foot, 21 (7.09%) with open reduction alone and 112 (37.84%) with open reduction in association with osteotomy. Among the osteotomy cases, 11 patients (9.82%) underwent the Dega procedure, four (3.57%) Pemberton, two (1.79%) Chiari, two (1.79%) Steel, one (0.89%) Kalamchi and one (0.89%) Shelf. Among the remaining 91 patients (81.25%), the Salter procedure was used. In the present study, only the cases with bilateral involvement treated by means of open reduction and Salter's osteotomy, with or without Ombrédanne's femoral shortening, were analyzed.

We analyzed 21 patients with bilateral DDH (42 hips operated). Of these, 19 (90.5%) were female and two (9.5%) were male. The mean age at the time of diagnosis was 2.3 years; the earliest was at the age of one month and the latest was at 4.6 years. The mean length of follow-up was 5.8 years, with a range from two years to 13 years and nine months.

The length of postoperative immobilization was six weeks. The patients were treated by two surgeons. In two cases (9.5%), there was previous treatment using Pavlik and closed

**Table 1 – Acetabular index (AI) values before and after the operation (in degrees) in relation to the side affected.**

Patient	Preoperative AI		AI six weeks after operation		Late postoperative AI	
	Right side	Left side	Right side	Left side	Right side	Left side
1	47	44	26	30	18	20
2	30	45	26	28	9	14
3	35	40	15	10	16	10
4	42	42	19	22	27	12
5	35	42	36	26	40	18
6	33	38	19	18	11	12
7	40	38	26	16	12	10
8	40	40	18	18	20	22
9	38	40	26	25	30	19
10	40	42	21	16	20	21
11	38	34	23	17	12	18
12	50	45	10	20	10	8
13	31	31	27	23	19	18
14	37	50	23	18	16	25
15	37	32	20	17	23	20
16	32	33	18	16	17	16
17	41	45	32	26	21	23
18	36	29	32	23	24	23
19	35	40	18	20	22	21
20	25	24	18	16	21	11
21	34	46	27	32	23	15
Mean	36.9	39	22.8	20.8	19.6	16.9
	SD 5.6	SD 6.5	SD 6.2	DP 5.5	DP 7.3	DP 5.0
	38		21.8 <sup>a</sup>		18.2 <sup>b</sup>	
	SD 6.1 (p = 0.2)		SD 5.9 (p = 0.16)		SD 6.3 (p = 0.16)	

AI, acetabular index; SD, standard deviation.

<sup>a</sup> Significant difference between preoperative AI and AI of six weeks after operation ( $p < 0.000001$ ).

<sup>b</sup> Significant difference between preoperative AI and late postoperative AI ( $p = 0.001$ ).

reduction. The other patients (90.5%) had not previously undergone any type of treatment.

In one patient, the osteosynthesis material was not removed because of technical difficulties. In all the others, the material was removed. The mean length of time after the operation for this procedure to be performed was 21.5 months for the left side and 22.45 months for the right side.

To evaluate the radiographic results, we used the acetabular index (AI), the center-edge angle (CÉ) of Wiberg,<sup>16</sup> the classification of Severin<sup>17</sup> and the type of avascular necrosis of the femoral head, according to the classification of Kalamchi and MacEwen.<sup>18</sup> The statistical analysis was performed in descriptive and analytical form by means of the chi-square, paired Wilcoxon, Student's *t* and paired Student's *t* methods, with the aim of establishing whether statistical significance existed between the parameters evaluated. We used the Sesatnet software<sup>19</sup> to analyze the data and the significance level was found to be 0.05.

This study was approved by the Research Ethics Committee (CEP-HIJG) and was registered under protocol 027/2011.

## Results

The mean preoperative AI was 38° (±6.1°): the right side presented a mean of 36.9° (±5.6°) and the left side, 39° (±6.5°). There was no statistical difference in relation to this finding, which indicated that the sample was homogenous (Table 1).

The mean AI six weeks after the operation was 21.8° (±5.9°) among the 42 hips. The mean for the right side was 22.8° (±6.2°) and for the left side, 20.8° (±5.5°). There was no significant difference (Table 1). The general mean for the late postoperative AI was 18.2° (±6.3°): for the right side, 19.6° (±7.3°) and for the left side, 16.9° (±5.0°). There was no statistically significant difference, but there was a significant difference in comparing the preoperative AI with the AI six week after the operation and with the late postoperative AI (Table 1).

The degree of femoral head necrosis was evaluated. There was no necrosis in eight patients, while two were affected bilaterally and eleven presented unilateral necrosis. Out of the 42 hips operated, 27 did not present necrosis (64.29%), type 1 necrosis occurred in three patients (7.4%), type 2 in five (11.9%), type 3 in four (9.52%) and type 4 in three (7.14%). In relation to the side affected, we did not find any statistically significant difference (Table 2) (Figs. 1A–C and 2A–C).

In relation to the CÉ of Wiberg,<sup>16</sup> the mean postoperative value was 19.4° (±11.6°): for the right side, 18.1° (±11.7°), and for the left side, 19.7° (±12.3°). There was no significant difference between the sides (Table 2).

Out of the total number of hips, according to the classification of Severin<sup>17</sup> (Table 2), 28 (66.67%) presented good and excellent results (Severin 1 and 2), 10 (23.81%) regular (Severin 3), four (9.52%) poor (Severin 4 and 5) and none of the cases was classified as Severin 6. In comparing the sides, we did not find any statistically significant difference.

**Table 2 – Evaluation of postoperative parameters, with comparison between the sides.**

Patient	Kalamchi and MacEwen classification <sup>18</sup> for avascular necrosis of the femoral head		Center-edge angle (CĒ) of Wiberg <sup>16</sup> (in degrees)		Severin classification <sup>17</sup>	
	Right side <sup>a</sup>	Left side <sup>a</sup>	Right side	Left side	Right side <sup>b</sup>	Left side <sup>b</sup>
1	–	–	18	22	1B	1A
2	–	–	37	28	1A	1A
3	–	2	17	12	1B	3
4	1	–	20	18	1B	2A
5	3	–	<0	11	4B	3
6	–	–	31	40	1A	1A
7	2	–	34	40	1A	2A
8	2	–	13	8	3	3
9	2	–	<0	16	4B	3
10	–	–	15	24	2B	1A
11	–	4	32	40	1A	2A
12	4	2	35	17	2B	2B
13	–	–	19	19	1A	1A
14	–	–	15	16	2B	1B
15	–	3	10	0	3	4A
16	–	–	10	30	3	1A
17	3	3	19	10	1A	3
18	–	1	18	8	1B	3
19	–	4	33	<0	2A	5
20	–	–	16	30	1B	1A
21	1	–	8	24	3	1A
Mean			18.1	19.7		
			SD 11.7	SD 12.3		
			19.4			
			SD 11.6 (p =0.41)			

SD, standard deviation.

<sup>a</sup> Non-significant difference between the sides affected (p=0.18).

<sup>b</sup> Non-significant difference between the sides affected (p=0.08).

The hips dealt with in the first surgical procedure presented results similar to those dealt with in the second procedure, since there was no statistical difference in relation to the AI six weeks after the operation, late postoperative AI, Wiberg CĒ (p=0.28), degree of avascular necrosis of the femoral head and Severin classification (p=0.09). The patients' mean age at the time of the first surgical procedure was 3.7 years (1.9 to 6.8 years) and at the time of the second surgical procedure, 4.3 years (2.5 to eight years), with a mean interval of 7.2 months (3 to 15 months) between the interventions (Table 3 and Fig. 3A–C).

Another criterion analyzed was in relation to the patients who required femoral shortening. The femoral osteotomy described by Ombrédanne<sup>12</sup> was performed on 13 patients (24 hips; 57.14%). There was no statistically significant difference in any of the criteria analyzed: AI six weeks after the operation (p=0.25), late postoperative AI (p=0.06), avascular necrosis of the femoral head (p=0.08), Wiberg CĒ (p=0.18) and Severin classification (p=0.39).

Surgical revision was necessary for four hips (9.52%) and the patients did not present postoperative infection.

## Discussion

The treatment for DDH has the basic premise of attaining stable concentric reduction of the hip into the functional

weight-bearing position. Instability of the reduction originates from poor positioning of the acetabulum in the anterior and lateral directions. Open reduction in association with Salter's osteotomy of the iliac bone in order to redirect the acetabulum is today a classical treatment method.<sup>20</sup>

In the literature, we found few studies showing results from patients who were treated for bilateral DDH at a late stage, who underwent surgical treatment by means of open reduction and Salter's osteotomy, with or without associated femoral shortening as described by Ombrédanne.

Many authors have recommended that open reduction in association with osteotomy of the innominate bone for correction of acetabular dysplasia should be performed on children at a minimum age of 18 months<sup>21</sup> and that the technique described by Salter<sup>22</sup> should be applied to patients at a maximum age of six years. Several studies have clinically and radiographically evaluated the pre- and postoperative conditions of children with DDH who underwent open reduction and Salter's osteotomy,<sup>2,11,20,21,23–34</sup> but none of them used samples consisting only of patients affected bilaterally.

In the present study, 21 patients with bilateral DDH with a mean interval of 7.2 months between the procedures were evaluated. The variation in the time between the procedures was due to the recovery of mobility in the hip that was operated first.

Prado et al.<sup>21</sup> studied 32 patients (42 hips, i.e., 10 bilateral cases) who all underwent open reduction and Salter's

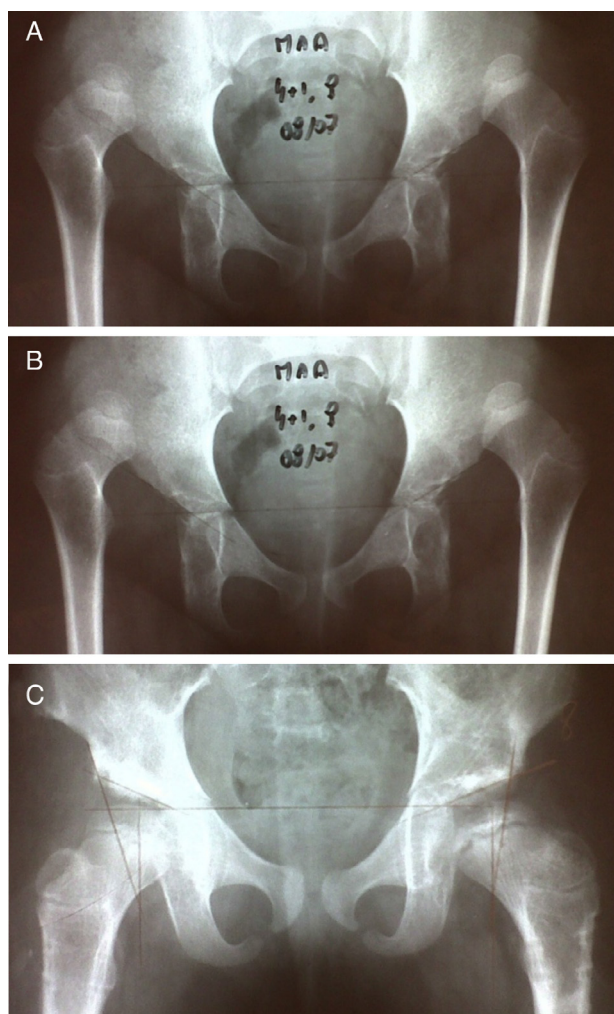
**Table 3 – Evaluation of postoperative parameters in relation to the side affected earlier and later on.**

Patient	Age (in months)		AI six weeks after operation (in degrees)		Late postoperative AI (in degrees)		Kalamchi and MacEwen classification <sup>18</sup> for avascular necrosis of the femoral head <sup>a</sup>		Center-edge angle (CE) of Wiberg <sup>16</sup> (in degrees)		Severin classification <sup>17</sup> <sup>b</sup>	
	1st S	2nd S	1st S	2nd S	1st S	2nd S	1st S	2nd S	1st S	2nd S	1st S	2nd S
1	42	46	26	30	18	20	–	–	18	22	1B	1A
2	27	33	26	28	9	14	–	–	37	28	1A	1A
3	59	65	15	10	16	10	–	2	17	12	1B	3
4	31	35	22	19	12	27	–	1	18	20	2	1B
5	82	86	36	26	40	18	3	–	<0	11	4B	3
6	23	30	18	19	12	11	–	–	40	31	1A	1A
7	31	39	26	16	12	10	2	–	34	40	1A	2A
8	28	38	18	18	20	22	2	–	13	8	3	3
9	43	46	26	25	30	19	2	–	<0	16	4B	3
10	45	52	21	16	20	21	–	–	15	24	2B	1A
11	40	44	23	17	12	18	–	4	32	40	1A	2A
12	81	96	20	10	8	10	2	4	17	35	2B	2B
13	35	40	27	23	19	18	–	–	19	19	1A	1A
14	48	54	23	18	16	25	–	–	15	16	2B	1B
15	57	64	17	20	20	23	3	–	0	10	4A	3
16	35	42	16	18	16	17	–	–	30	10	1A	3
17	23	33	32	26	21	23	3	3	19	10	1A	3
18	60	71	32	23	24	23	–	1	18	8	1B	3
19	66	79	18	20	22	21	–	4	33	<0	2A	5
20	35	41	18	16	21	11	–	–	16	30	1B	1A
21	35	43	27	32	23	15	1	–	8	24	3	1A
Mean	44.1	51.3	23.2	20.4	18.6	17.9			21.2	20.7		
	SD 17.4	SD 18.6	SD 5.7	SD 5.9	SD 7.3	SD 5.3			DP 10.7	DP 10.8		
	47.7		21.8		18.2				20.9			
	SD 18.2		SD 5.9 (p = 0.1)		SD 6.3 (p = 0.39)				SD 10.7 (p = 0.28)			

S, surgery; AI, acetabular index; SD, standard deviation.

<sup>a</sup> Non-significant difference in relation to the earliness of the intervention (p = 0.7).<sup>b</sup> Non-significant difference in relation to the earliness of the intervention (p = 0.09).





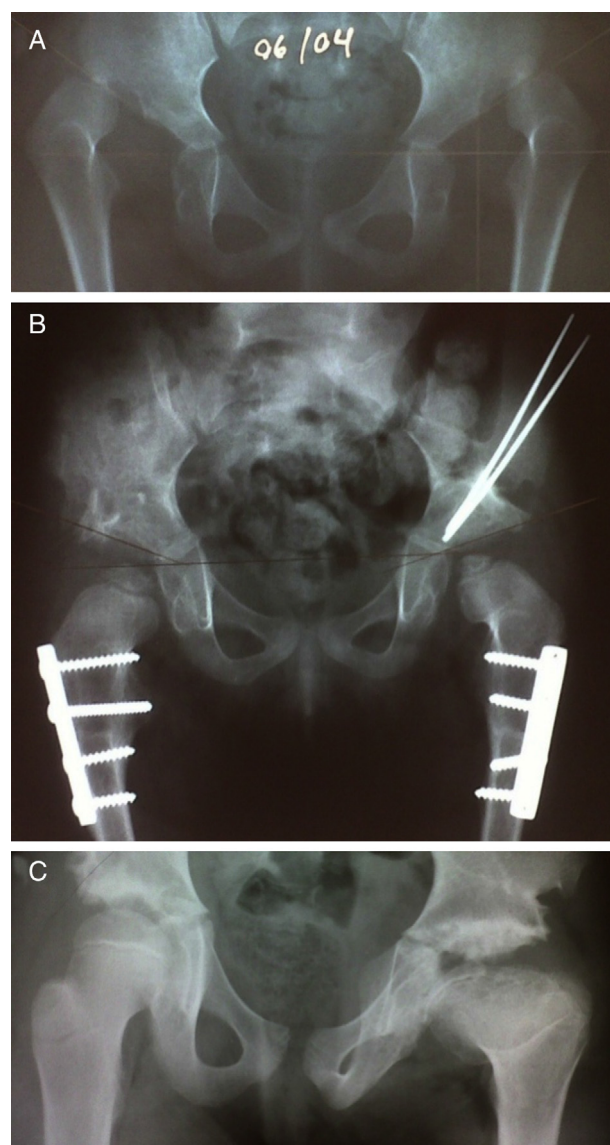
**Fig. 1 – Female patient aged four years and one month: preoperative X-ray in August 2007 (A). X-ray on August 16, 2009, two years and five months after operation on right hip and one year and six months after operation on left hip (B). X-ray on October 2, 2010, three years and three months after operation on right hip and two years and eight months after operation on left hip, presenting type I necrosis of the femoral head (C).**

osteotomy. Among the 10 patients with bilateral involvement, 10 joints were operated between the ages of two and four years and the other ten joints between four and seven years of age, with a mean interval of four months between the surgical procedures.

Bertol et al.<sup>20</sup> evaluated 103 hips of eight boys and 85 girls (10 bilateral cases). All of them underwent open reduction and Salter's osteotomy, with or without associated rotational and varus osteotomy of the femur. In our sample, we did not perform varus correction.

Carvalho Filho et al.<sup>2</sup> evaluated three boys and 15 girls (four bilateral cases) who had already started to walk, with DDH that had not been treated previously. The surgery was performed in a single procedure and the patients' mean age was 19 months.

Rocha et al.<sup>23</sup> analyzed 18 female hips that underwent open reduction, Salter's osteotomy and Ombrédanne's procedure at

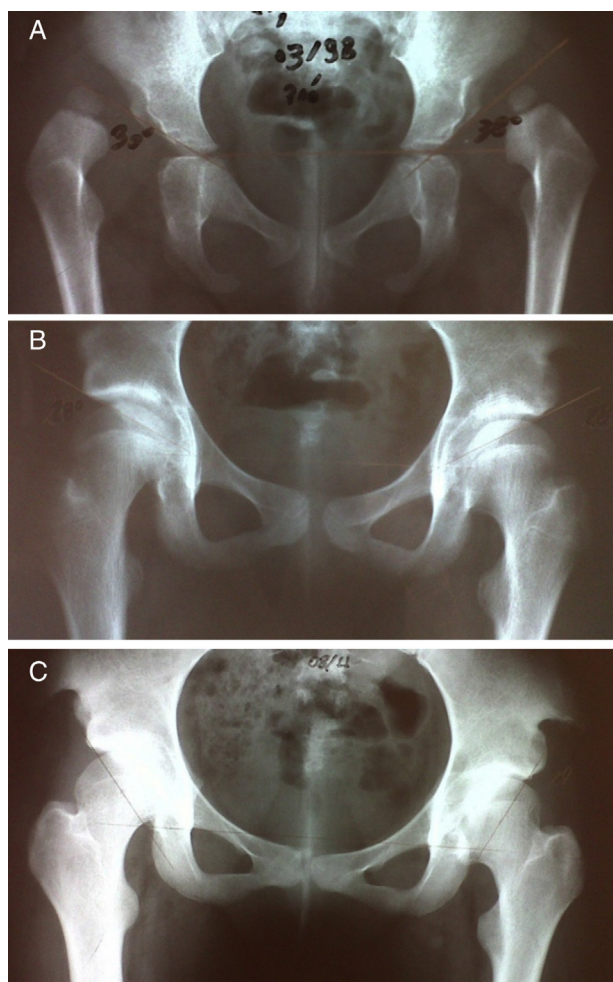


**Fig. 2 – Female patient aged three years and three months: preoperative X-ray in June 2004 (A). X-ray in January 2005, three months after operation on left hip and six months after operation on right hip (B). X-ray in October 2011, in the late postoperative period, seven years after operation on right hip and six years and nine months after operation on left hip, presenting type 4 necrosis of the femoral head (C).**

ages between two and eight months, in which four cases were bilateral. In these bilateral cases, the mean time between the surgical procedures was six months.

El-Sayed et al.<sup>24</sup> treated 87 patients with DDH by means of open reduction and Salter's osteotomy. There were 22 bilateral cases, which were operated with an interval of six weeks. Bhuyan<sup>25</sup> waited three to six months to perform the procedure on the contralateral hip.

Regarding the postoperative follow-up on the patients of the present study, the mean duration was 5.8 years. Carvalho Filho et al.<sup>2</sup> followed up their patients for a mean of four years, while Rocha et al.<sup>23</sup> did so for four years and eight months.



**Fig. 3 – Female patient aged two years: preoperative X-ray in March 1998 (A). X-ray in July 2007: postoperative radiographic control produced nine years and eight months after operation on right hip and nine years and two months after operation on left hip (B). X-ray in August 2011, at the age of 15 years and 11 months: 13 years and eight months after operation on right side and 13 years and two months after operation on left side (C).**

Many authors have described follow-ups on treated patients ranging from one year to 24 years and six months.<sup>11,20,21,23-32</sup>

Regarding radiographic evaluations, the mean preoperative AI among the cases studied here was 38°, with a mean value for the right side of 36.9° and for the left side of 39°. Regarding the AI six weeks after the operation, the mean value was found to be 21.8°, the right side 22.8° and the left side 20.8°. The mean for the late postoperative AI was 18.2°. There was a statistically significant difference between the pre- and postoperative AIs ( $p < 0.05$ ).

Carvalho Filho et al.<sup>2</sup> found a preoperative angle of 39° and a mean postoperative angle of 22°.

Rocha et al.<sup>23</sup> found preoperative mean values of 43.3° on the right side and 42.1° on the left side and postoperative values of 31.57° and 30.36°, respectively. Although the values were higher, they also observed a significant difference from before to after the operation ( $p < 0.001$ ).

Yagmurlu et al.<sup>26</sup> performed Salter or Steel osteotomy on six patients. The mean preoperative AI was 37.8°, and this improved to 21.2° after the operation.

El-Sayed et al.<sup>24</sup> found a statistically significant difference between the pre- and postoperative AI values, which diminished from 41.56° to 20.41° in children younger than four years. Bhuyan<sup>26</sup> reduced the AI from 42° ( $\pm 5$ ) to 21° ( $\pm 2$ ). Abdullah et al.<sup>27</sup> obtained a significant improvement in AI in all the 42 hips treated, thus decreasing it from 44° ( $\pm 2.5$ ) to 23° ( $\pm 3$ ). Among 63 children, Chang et al.<sup>11</sup> found a mean preoperative AI of 35.4°; the AI six months after the operation was 17° and it was 12.6° ten years after the operation. In our study, there was a decreasing trend in AI values with passage of time, changing to 18.2°, but without any statistically significant difference in relation to the values from six weeks after the operation ( $p = 0.06$ ).

The postoperative Wiberg CE angle obtained in our analysis was 19.4°, i.e., smaller than the angles of 28° found by Carvalho Filho et al.,<sup>2</sup> 31° ( $\pm 9$ ) and 32.3° ( $\pm 11.9$ ) by El-Sayed et al.<sup>24</sup> and 32.3° ( $\pm 11.9$ ) in patients with Salter's osteotomy and 36.9° ( $\pm 10.5$ ) in cases with associated femoral shortening treated by Tezeren et al.<sup>28</sup>

The radiographic classification described by Severin makes it possible to assess the results from Salter's osteotomy over the medium and long terms. In our study, we found that 65% of the hips had a satisfactory radiographic result. Better results were found by Carvalho Filho et al.,<sup>2</sup> with 81% of the hips in classifications I and II; Prado et al.,<sup>21</sup> with 92.8%; Rocha et al.,<sup>23</sup> with 88.9%; El-Sayed et al.,<sup>24</sup> with 88% (types I and II); Bhuyan,<sup>25</sup> with 83.3%; and Yagmurlu et al.,<sup>26</sup> with 74% showing satisfactory results.

Femoral shortening was performed on 24 hips, without any difference in the radiographic evaluation in relation to the cases without shortening. Bertol et al.<sup>20</sup> found that 75% of the results were good in the cases without shortening and 64.4% in the cases with femoral shortening. Prado et al.<sup>21</sup> performed femoral shortening on all of their patients with bilateral involvement. They suggested that femoral shortening should be used as an auxiliary surgical treatment method for DDH, since the final result depends on the procedures used in addressing the joint problem. They reported that, because of the diminished or even absent potential for recovery of acetabular development, simple replacement procedures in children over the age of three years give rise to unsatisfactory medium and long-term results. Ashay et al.<sup>34</sup> indicated femoral shortening in association with simple open reduction, for children over the age of three years. Tezeren et al.<sup>28</sup> evaluated their results and found Severin I in 75% and Severin II in 18.7% of the cases treated without shortening and Severin I in 76.9% and Severin II in 23% of the patients who underwent femoral shortening and concluded that there was no significant difference between the procedures.

In the study by Salter and Dubos,<sup>22</sup> among the patients who did not undergo femoral shortening, 98% of the results from subluxation were satisfactory in patients aged 18 months to six years; and 93.6% of the results from dislocations in children aged 18 months to four years. Among dislocated hips that were operated after the child had reached four years of age, the rate of satisfactory results decreased to 56.7%.



In relation to the duration of immobilization after the operation, Rocha et al.<sup>24</sup> kept their patients in plaster casts from the pelvis to the foot for 2.5 months, El-Sayed et al.<sup>25</sup> for two months and Sadeghpour et al.<sup>35</sup> for three months, i.e., longer periods than the six weeks recommended in the present study.

The time interval until removal of the synthesis material ranged from three months to five years and ten months, with a mean of 21.63 months. Carvalho Filho et al.<sup>2</sup> performed removal of the synthesis material between eight and twelve weeks after the operation, while Rocha et al.<sup>24</sup> did this one year after the operation.

Some complications from Salter's osteotomy have been described, such as superficial and deep infection, subluxation, renewed dislocation, chondrolysis, neuropraxia of the sciatic nerve and avascular necrosis.<sup>22</sup> In the present sample, there were 15 cases of avascular necrosis, without any significant difference between the sides. We did not find any cases of superficial or deep infection. There were three cases of renewed dislocation, which were resolved through a new surgical procedure.

We noted that in the cases of avascular necrosis, especially those of types 3 and 4, seven (16.66%) occurred in patients of more advanced age and with higher dislocation. These required greater capsule release because of adhesions and the consequent resection, given that the capsule is elongated, which is probably the reason for this incidence ( $p > 0.08$ ).

Bertol et al.<sup>20</sup> found a greater rate of growth plate injury in the group in which associated femoral shortening was performed ( $p < 0.05$ ), as well as more cases of subluxation and dislocation. Prado et al.<sup>21</sup> reported four cases of subluxation (9.5%). Rocha et al.<sup>23</sup> had one case of subluxation, one of osteonecrosis and one other of osteonecrosis associated with subluxation.

Chang et al.<sup>11</sup> operated on 63 children between the ages of one and three years, using the technique described by Salter, and found 30 cases of avascular necrosis: 16 cases with early signs of this, within the first two years after the operation, and 14 with signs seen later on after the operation.

Yagmurlu et al.<sup>26</sup> described four cases with avascular necrosis among 27 hips that were operated (14%). They did not cite the classification used, or the likely cause of the event.

Roposch et al.<sup>36</sup> found that 73% of their cases presented avascular necrosis (86/118) over a mean follow-up period of eight years (one to 19 years), according to the criteria of Ogden and Bucholz, among the patients treated with open and closed reduction, and they concluded that there was no relationship with performing femoral shortening.

We considered that renewed dislocation and bone necrosis predisposed patients to poor functional and radiographic results. Among the patients studied, the grade encountered ranged from types I to IV of Kalamchi and MacEwen, and was most frequently type II, with 11.9% (5/42), followed by type III, with 9.52% (4/42). These results were concordant with those of Holman et al.,<sup>37</sup> who found 10 cases of necrosis, all classified as Severin IV or worse, among their results from treatments using different techniques on 179 hips.

## Conclusions

Open reduction in association with osteotomy of the iliac bone as described by Salter presented a statistically significant improvement in the angular parameters measured on the patients' radiographs, from before to after the operation.

This improvement did not have any relationship with whether femoral shortening as described by Ombrédanne was performed.

There was no significant difference regarding the results between the sides operated.

Avascular necrosis of the femoral head was the most prevalent complication in the group studied and this had a relationship with higher dislocation and patients of more advanced age.

## Conflicts of interest

The authors declare no conflicts of interest.

## REFERENCES

1. Wilkinson AG, Wilkinson S. Neonatal hip dysplasia: a new perspective. *Neo Reviews*. 2010;11(7):e349-62.
2. Carvalho Filho G, Chueire AG, Ignácio H, Carneiro MO, Francese Neto J, Canesin AC. Tratamento cirúrgico da luxação congênita do quadril pós marcha: redução aberta e osteotomia de Salter. *Acta Ortop Bras*. 2003;11(1):42-7.
3. Bowen JR, Kotzias-Neto A. Developmental dysplasia of the hip. Brooklandville: Data Trace Publishing Company; 2006.
4. Wynne-Davies R. Acetabular dysplasia and familial joint laxity: two etiological factors in congenital dislocation of the hip. A review of 589 patients and their families. *J Bone Joint Surg Br*. 1970;52(4):704-16.
5. Dunn PM. The anatomy and pathology of congenital dislocation of the hip. *Clin Orthop Relat Res*. 1976;(119):23-7.
6. Wilkinson JA. A post-natal survey for congenital displacement of the hip. *J Bone Joint Surg Br*. 1972;54(1):40-9.
7. Ortolani M. Un segno poco noto e sua importanza per la diagnosi precoce di prelussazione congenita dell'anca. *La Pediatria*. 1937;45:129-35.
8. Salter RB. The classic. Innominate osteotomy in the treatment of congenital dislocation and subluxation of the hip by Robert B. Salter. *J. Bone Joint Surg (Brit)*. 43B:3:518, 1961. *Clin Orthop Relat Res*. 1978;(137):2-14.
9. Putti V. Early treatment of congenital dislocation of the hip. *J Bone Joint Surg Am*. 1933;15(1):16-21.
10. Ortolani M. Congenital hip dysplasia in the light of early and very early diagnosis. *Clin Orthop Relat Res*. 1976;(119):6-10.
11. Chang CH, Kao HK, Yang WE, Shih CH. Surgical results and complications of developmental dysplasia of the hip - one stage open reduction and Salter's osteotomy for patients between 1 and 3 years old. *Chang Gung Med J*. 2011;34(1):84-92.
12. Ombrédanne L. Précis clinique et opératoire de chirurgie infantile. Paris: Masson; 1923.
13. Salter RB. Role of innominate osteotomy in the treatment of congenital dislocation and subluxation of the hip in the older child. *J Bone Joint Surg Am*. 1966;48(7):1413-39.
14. Lloyd-Roberts GC. Osteoarthritis of the hip; a study of the clinical pathology. *J Bone Joint Surg Br*. 1955;37(1):8-47.



15. Gade HG. A contribution to the surgical treatment of osteoarthritis of the hip-joint. Oslo: Grøndahl & Sønns; 1947.
16. Wiberg GC. Studies on dysplastic acetabula and congenital subluxation of the hip joint, with special reference to the complication of Osteo-Arthritis (Translated from the Swedish by Helen Frey). *Acta Chir Scand.* 1939;83 Suppl. 58.
17. Severin EA. Contribution to the knowledge of congenital dislocation of the hip joint. Late results of closed reduction and arthrographic studies of recent cases (Translated from the Swedish by Helen Frey); 1941.
18. Kalamchi A, MacEwen GD. Avascular necrosis following treatment of congenital dislocation of the hip. *J Bone Joint Surg Am.* 1980;62(6):876-88.
19. Estatística por meio da internet. Available in: [www.sestatnet.ufsc.br](http://www.sestatnet.ufsc.br) [Online] [cited 2012 January 15].
20. Bertol P, Ishida A, Macnicol MF. Tratamento da displasia do desenvolvimento do quadril pela técnica de Salter isolada ou associada à osteotomia do fêmur. *Rev Bras Ortop.* 2004;39(5):232-44.
21. Prado JC, Santili C, Baptista PPR. Tratamento da luxação e subluxação congênitas do quadril pela técnica de Salter associada ao encurtamento do fêmur. *Rev Bras Ortop.* 1984;19(6):203-8.
22. Salter RB, Dubos JP. The first fifteen year's personal experience with innominate osteotomy in the treatment of congenital dislocation and subluxation of the hip. *Clin Orthop Relat Res.* 1974;(98):72-103.
23. Rocha VL, Thomé AL, Castro DL, Oliveira LZ, Moraes FB. Avaliação clínica e radiológica após procedimento de Salter e Ombredanne na displasia de desenvolvimento do quadril. *Rev Bras Ortop.* 2011;46(6):650-5.
24. El-Sayed M, Ahmed T, Fathy S, Zyton H. The effect of Dega acetabuloplasty and Salter innominate osteotomy on acetabular remodeling monitored by the acetabular index in walking DDH patients between 2 and 6 years of age: short- to middle-term follow-up. *J Child Orthop.* 2012;6:471-7.
25. Bhuyan BK. Outcome of one-stage treatment of developmental dysplasia of hip in older children. *Indian J Orthop.* 2012;46(5):548-55.
26. Yagmurlu MF, Bayhan IA, Tuhanioglu U, Kilinc AS, Karakas ES. Clinical and radiological outcomes are correlated with the age of the child in single-stage surgical treatment of developmental dysplasia of the hip. *Acta Orthop Belg.* 2013;79(2):159-65.
27. Abdullah ES, Razzak MY, Hussein HT, El-Adwar KL, Youssef AA. Evaluation of the results of operative treatment of hip dysplasia in children after the walking age. *Alexandria J Med.* 2012;48:115-22.
28. Tezereen G, Tukenmez M, Bulut O, Percin S, Cekin T. The surgical treatment of developmental dislocation of the hip in older children: a comparative study. *Acta Orthop Belg.* 2005;71(6):678-85.
29. Ertürk C, Altay MA, Yarimpapuç R, Koruk I, Işikan UE. One-stage treatment of developmental dysplasia of the hip in untreated children from two to five years old. A comparative study. *Acta Orthop Belg.* 2011;77(4):464-71.
30. Dobashi ET, Kiyohara RT, Matsuda MM, Milani C, Kuwajima SS, Ishida A. Tratamento cirúrgico do quadril displásico inveterado. *Acta Ortop Bras.* 2006;14(4):183-9.
31. Haidar RK, Jones RS, Vergroesen DA, Evans GA. Simultaneous open reduction and Salter innominate osteotomy for developmental dysplasia of the hip. *J Bone Joint Surg Br.* 1996;78(3):471-6.
32. Cordeiro EF, Matsunaga FT, Costa MP, Felizola M, Dobashi ET, Ishida A, et al. Análise radiográfica dos fatores prognósticos do quadril displásico inveterado. *Acta Ortop Bras.* 2010;18(4):218-23.
33. Forlin E, Munhoz da Cunha LA, Figueiredo DC. Treatment of developmental dysplasia of the hip after walking age with open reduction, femoral shortening, and acetabular osteotomy. *Orthop Clin North Am.* 2006;37(2):149-60.
34. Ashley RK, Larsen LJ, James PM. Reduction of dislocation of the hip in older children: a preliminary report. *J Bone Joint Surg Am.* 1972;54(3):545-50.
35. Sadeghpour A, Rouhani A, Mohseni MA, Aghdam OA, Goldust M. Evaluation of surgical treatment of developmental dysplasia of the hip for avascular necrosis of femoral head in children. *Pak J Biol Sci.* 2012;15(8):391-4.
36. Roposch A, Ridout D, Protopapa E, Nicolaou N, Gelfer Y. Osteonecrosis complicating developmental dysplasia of the hip compromises subsequent acetabular remodeling. *Clin Orthop Relat Res.* 2013;471(7):2318-26.
37. Holman J, Carroll KL, Murray KA, Macleod LM, Roach JW. Long-term follow-up of open reduction surgery for developmental dislocation of the hip. *J Pediatr Orthop.* 2012;32(2):121-4.