



RBO

REVISTA BRASILEIRA DE ORTOPEDIA

www.rbo.org.br



Original Article

Trauma to the nail complex[☆]Jefferson Braga Silva^{a,b,*}, Samanta Gerhardt^b^a Hand Surgery and Reconstructive Microsurgery Service, Hospital São Lucas, Pontifícia Universidade Católica do Rio Grande do Sul (PUC-RS), Porto Alegre, RS, Brazil^b Faculdade de Medicina da Pontifícia Universidade Católica do Rio Grande do Sul, Porto Alegre, RS, Brazil

ARTICLE INFO

Article history:

Received 10 March 2013

Accepted 10 October 2013

Available online 12 March 2014

Keywords:

Nail

Finger injuries

Nail bed

ABSTRACT

Objective: to analyze the results from surgical intervention to treat trauma of the nail complex.**Methods:** we retrospectively reviewed a series of 94 consecutive patients with trauma of the nail complex who were treated between 2000 and 2009. In 42 patients, nail bed suturing was performed. In 27 patients, nail bed suturing was performed subsequent to osteosynthesis of the distal phalanx. In 15, immediate grafting was performed, and in 10, late-stage grafting of the nail bed. The growth, size and shape of the nail were evaluated in comparison with the contralateral finger. The results were obtained by summing scores and classifying them as good, fair or poor.**Results:** the results were considered to be good particularly in the patients who underwent nail bed suturing or nail bed suturing with osteosynthesis of the distal phalanx. Patients who underwent immediate or late-stage nail grafting had poor results.**Conclusion:** trauma of the nail complex without loss of substance presented better results than did deferred treatment for reconstruction of the nail complex.

© 2014 Sociedade Brasileira de Ortopedia e Traumatologia. Published by Elsevier Editora Ltda. All rights reserved.

Trauma do complexo ungueal

RESUMO

Objetivo: analisar os resultados da intervenção cirúrgica do trauma do complexo ungueal.**Métodos:** revisamos 94 pacientes consecutivos com trauma do complexo ungueal entre 2000 e 2009. Em 42 pacientes foi feita a sutura no leito ungueal. Em 27, a sutura do leito foi posterior à osteossíntese da falange distal. Em 15, foi feito enxerto imediato e em 10, enxerto tardio do leito ungueal. Foram avaliados o crescimento, o tamanho e a forma da unha comparados ao dedo contralateral. Os resultados foram obtidos com a adição de escores e a classificação deles como bom, regular e ruim.**Resultados:** foram julgados como bons os pacientes que se submeteram principalmente a suturas do leito ungueal e sutura do leito e osteossíntese da falange distal. Pacientes submetidos a enxerto imediato e enxerto posterior da unha tiveram resultados ruins.

Palavras-chave:

Unha

Traumatismo dos dedos

Leito ungueal

[☆] Please cite this article as: Silva JB. Trauma do complexo ungueal. Rev Bras Ortop. 2014;49:111-115.

* Corresponding author.

E-mail: jeffmao@terra.com.br (J.B. Silva).

Conclusão: o trauma do complexo ungueal sem perda de substância apresentou melhores resultados comparado com a reconstrução do complexo ungueal.

© 2014 Sociedade Brasileira de Ortopedia e Traumatologia. Publicado por Elsevier Editora Ltda. Todos os direitos reservados.

Introduction

In many countries, hand trauma is the most frequent occupational trauma among adults. Among children, occurrences of crushed fingers in doors ("trapped fingers") are the main cause of trauma to fingers.¹ Trauma to the fingertips and nail system are the main reasons why patients seek hand surgery emergency services.^{2,3}

Fingertip trauma with or without exposure of the distal phalanx can be treated in different ways, using grafts and local flaps. In the nail matrix and in nail bed trauma, different techniques can also be used to achieve esthetic and functional nail growth over the long term.³

For this objective, a variety of techniques have been used: nail perforation with removal of the subungual hematoma, suturing of the nail bed, osteosynthesis of the distal phalanx of the nail and even nail bed grafts.

Material and methods

We reviewed 109 patients with trauma of the nail complex seen between January 2000 and December 2009. The mean age was 19 years (range: 16-48). The inclusion criteria were that these patients needed to have nail bed injuries with or without associated fractures of the distal phalanx, with a minimum follow-up of 18 months. Of these patients, 15 were excluded because we did not reach the postoperative length of follow-up proposed for the study, thus leaving 94 patients. The surgery was all performed by the same team, under locoregional anesthesia, or under general anesthesia in cases that required nail bed grafting from the hallux. In 42 patients, we performed simple suturing of the nail bed (SS) (Figs. 1-5); in 27, suturing of the nail bed followed by osteosynthesis of the distal phalanx (SO); in 15, immediate grafting of the nail bed (IG); and in 10, later grafting of the nail bed (LG), i.e. more than five days afterwards.

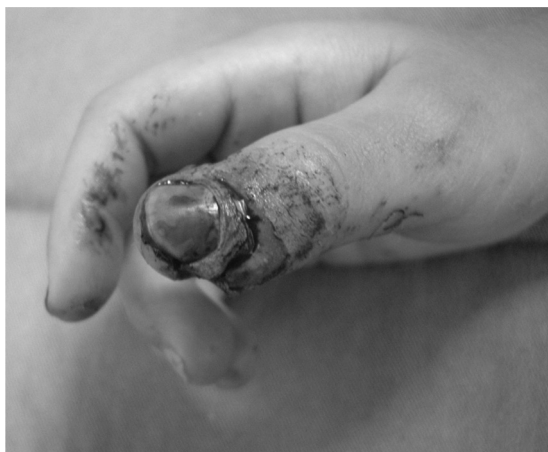

Fig. 1 – Crushing of the thumb, with subungual hematoma.

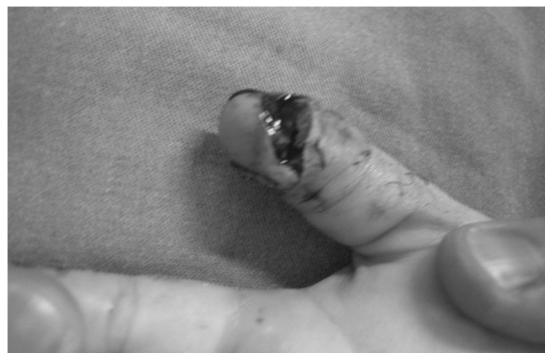

Fig. 2 – Crushing of the thumb: volar view.

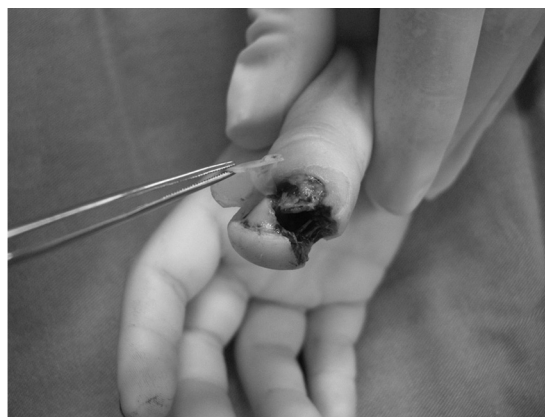

Fig. 3 – Nail bed injury.

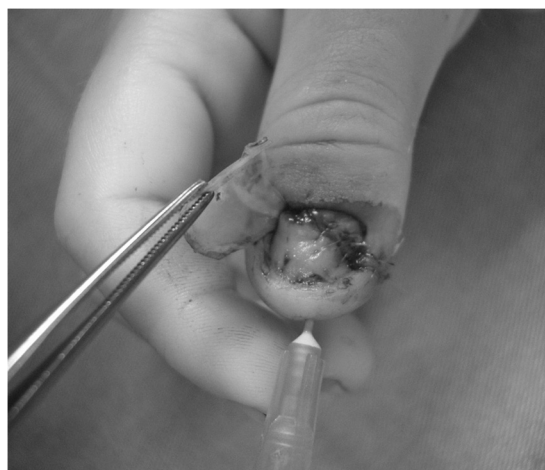


Fig. 4 – Repair of the nail bed.

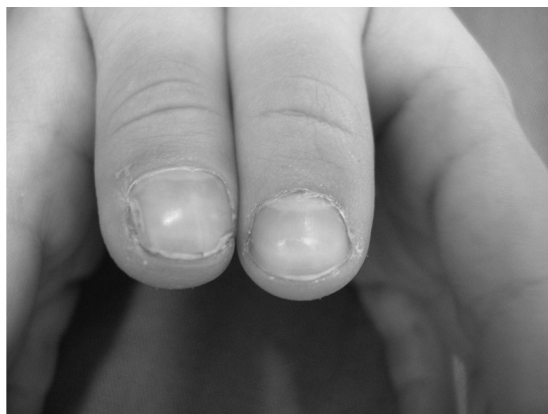

Fig. 5 – Final result.

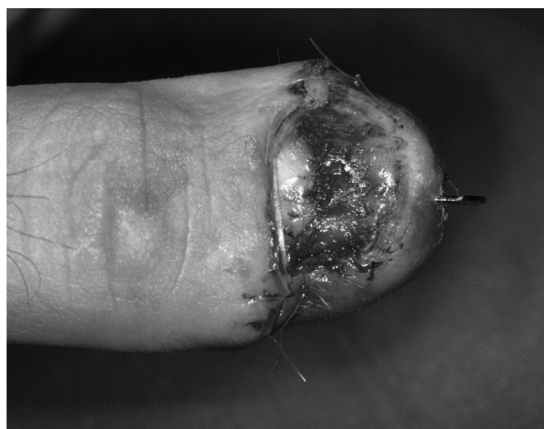

Fig. 7 – Repair of the nail bed.

The nail bed suturing was done using polyglactin 6.0 thread. When available, the traumatized nails were always reconditioned and were placed under the proximal fold of the nail and eponychium. This policy enabled better alignment of the nail bed suture and greater comfort for patients at the time of applying dressings. When the original nail was not available, a plate of synthetic material was improvised from a small piece of flexible silicone that was taken from the saline solution bags that are available in any surgical facility. Provisional immobilization was used for two weeks. In cases of fracturing of the distal phalanx, two crossed Kirschner wires and a volar Zimmer splint were used until radiological consolidation had been achieved (mean of six weeks). The donor zone for the nail bed graft was always the nail bed of the hallux (Figs. 6–9).

We assessed whether age, sex, injury mechanism, type of treatment used and time when the treatment was performed had any influence, and also evaluated the esthetic and functional results relating to the nail complex.

Results

Sex and age did not have any influence on the results obtained. There was a direct relationship between the injury mechanism, type of treatment used, time when treatment was performed and the esthetic and functional results obtained in

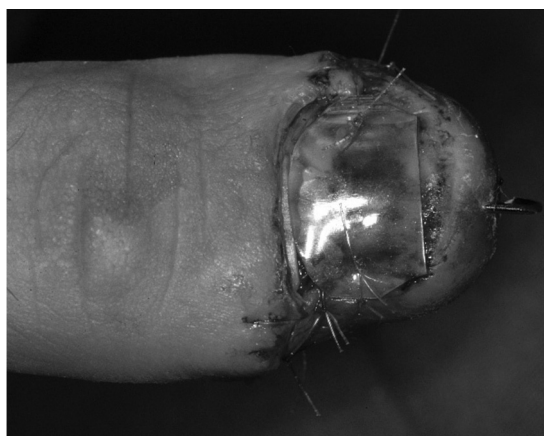

Fig. 8 – Silicone lamina.

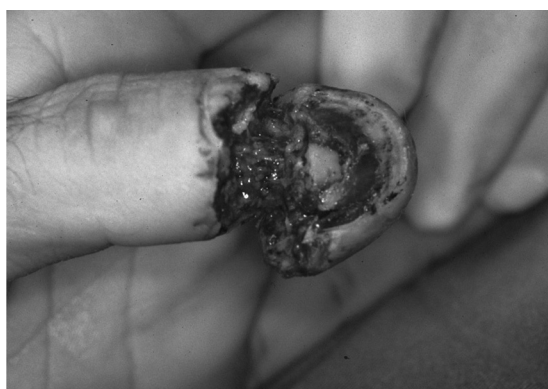

Fig. 6 – Trauma of the nail complex.

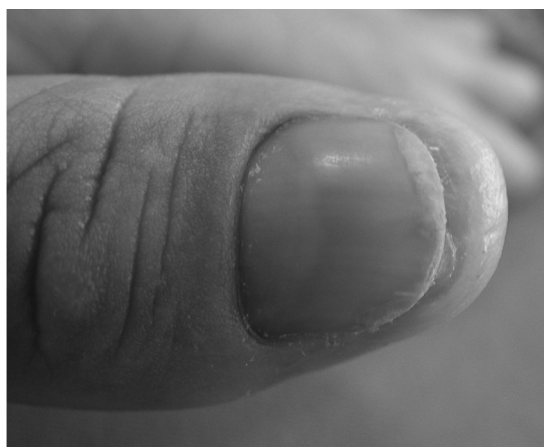

Fig. 9 – Final result.

this study. For the results to be better assessed, we developed a table of scores that included three factors (Table 1).

We assessed nail growth (0=without growth; 1=partial growth with restraints; and 2=normal growth), nail size ($0 \leq 50\%$; 1=between 50 and 75%; and $2 \geq 75\%$ of the size of the nail on the opposite side) and nail shape (0=significant

Table 1 – Esthetic and functional classification according to the summed results.

Nail growth	0 = without growth; 1 = partial growth with restraints; and 2 = normal growth.
Nail growth	0 ≤ 50%; 1 = between 50 and 75%; and 2 ≥ 75% of the size of the nail on the opposite side.
Nail shape	0 = significant deformity in the vertical plane; 1 = small deformity in the vertical plane; and 2 = without deformity.
Total score: 6	The results were obtained through addition and classification of the scores as good (5–6), fair (3–4) and poor (<3).

deformity in the vertical plane; 1 = small deformity in the vertical plane; and 2 = without deformity), in comparison with the opposite side. The results were obtained through addition and classification of the scores as good (5–6), fair (3–4) and poor (<3). The results were judged to be good in the following patients: SS (37/42); SO (23/27); IG (2/15); and LG (1/10). Poor results were found in IG patients (8/15) and LG patients (6/10) (Table 2).

Discussion

Trauma of the nail complex is the main cause of consultations in hand surgery emergencies. Trauma with or without exposure of the distal phalanx and with or without fracturing can be treated in different ways, through using grafts or regional flaps. The main functions of the nails are to provide stability for finger grips through counterpressure and esthetic definition for the extremities of the fingers.

Nail complex trauma is often manifested in different ways: subungual hematoma, lacerations, crushing and avulsion of the nail bed. Hematomas occur due to microvascular trauma in the nail bed, which compresses the blood coagulum below the nail. Understanding the delicate relationship between the nail and the dorsum of the fingertip and its vascular irrigation may contribute toward understanding the need for good restoration of the nail bed, in order to ensure recovery of the local anatomy. Microvascular studies have demonstrated the difference between the eponychium, nail bed and irrigation of the nail matrix.⁴

It is known that the entire nail bed is involved in germination and migration of the cornified cells of the nail. For this reason, it is necessary not only to preserve the germinative matrix but also to restore all of its structures, thereby making

it possible for the nail to grow in the most anatomical manner possible.

Emergency teams are usually involved in a multitude of tasks and give priority to general care. Trauma of the nail complex is often relegated and not evaluated by hand surgery specialists. It is important to define the limits of what might be non-complicated trauma or complex trauma so as to evaluate the possibility of sequelae in the nail complex, which are sometimes irreversible.⁵

Perforation of the nail to drain subungual hematomas seems to be the simplest way to treat trauma when there is no fracturing. Many authors have considered this type of treatment for small to moderate-sized hematomas (<50% of the nail surface). Pain relief and the simplicity of the procedure are the main advantages when this treatment is instituted in emergency situations.

We prioritize three factors in evaluating and classifying the results after treatment with different methods: nail growth, measured according to the length of the nail; nail size, in comparison with the contralateral finger; and nail shape, through measuring the deformity in the vertical plane.

Different studies have shown similarities in the results from nail bed suturing, in comparison with treatments using cyanoacrylate tissue adhesives.^{2,6,7} Along the same line of investigation, comparisons between tissue adhesives and nail bed suturing have been made, without showing any significant differences in the results.⁸ For avulsion or severe crushing of the nail bed and fingertip, the loss of tissue material needs to be replaced by means of nail bed grafts and regional flaps. Many flaps for reconstruction of the fingertip have been described. The type and mechanism of the fingertip trauma and the involvement of the nail bed determine the choice of reconstruction. Nail bed grafts may often be performed within acute and delayed contexts. These situations are limited mainly by the time at which the patient comes for consultation and the care given within the acute scenario.

In cases of avulsion or crushing of the nail bed and fingertip, the loss of tissue material needs to be replaced using grafts and/or local flaps. There is a considerable variety of therapeutic options for distal finger reconstructions. Same-finger neurovascular flaps can be highlighted. Nail bed grafts can be performed within an acute and delayed context. Different donor sites can be used for this purpose; the matrix and the nail bed of an amputated segment from a toe are most commonly used as full or partial-thickness grafts. It is

Table 2 – Results. Nail growth after treatment of different patterns of trauma of the nail complex.

Laceration of the nail bed + hematoma Treatment	Laceration of the nail bed + fracturing of the distal phalanx SS ^a	Loss of tissue substance/avulsion – severe crushing SO ^b	IG ^c	LG ^d
Good	37	23	2	3
Fair	5	4	5	1
Poor	0	0	8	6
Total	42	27	15	10

^a Simple suturing of the nail bed – SS.

^b Suture of the nail bed followed by osteosynthesis of the distal phalanx – SO.

^c Immediate grafting of the nail – IG.

^d Later grafting of the nail – LG.

important to take into account the possibility of scarring or possible deformity of the nail at the donor location.^{9,10}

Conclusion

The results from this study clearly showed that trauma due to crushing with loss of tissue material and deferred treatment of the nail complex (>5 days) presented outcomes that were inferior to those of cases in which the treatment was done as an emergency and in which there was no significant loss from the nail complex.

Conflicts of interest

The authors declare no conflicts of interest.

REFERENCES

1. Doraiswamy NV, Baig H. Isolated finger injuries in children – incidence and aetiology. *Injury*. 2000;31(8):571–3.
2. Strauss EJ, Weil WM, Jordan C, Paksima N. A prospective, randomized, controlled trial of 2-octylcyanoacrylate versus suture repair for nail bed injuries. *J Hand Surg Am*. 2008;33(2):250–3.
3. Yeo CJ, Sebastin SJ, Chong AK. Fingertip injuries. *Singapore Med J*. 2010;51(1):78–86.
4. Hasegawa K, Pereira BP, Pho RW. The microvasculature of the nail bed, nail matrix, and nail fold of a normal human fingertip. *J Hand Surg Am*. 2001;26(2):283–90.
5. Al-Qadhi S, Chan KJ, Fong G, Al-Shanteer S, Ratnapalan S. Management of uncomplicated nail bed lacerations presenting to a children's emergency department. *Pediatr Emerg Care*. 2011;27(5):379–83.
6. Hallock GG, Lutz DA. Octyl-2-cyanoacrylate adhesive for rapid nail plate restoration. *J Hand Surg Am*. 2000;25(5):979–81.
7. Yam A, Tan SH, Tan ABH. A novel method of rapid nail bed repair using 2-octyl cyanoacrylate (dermabond). *Plast Reconstr Surg*. 2008;121(3):148e–9e.
8. Roser SE, Gellman H. Comparison of nail bed repair versus nail trephination for subungual hematomas in children. *J Hand Surg-Am*. 1999;24A(6):1166–70.
9. Dumontier C, Nakache S, Abimelec P. Treatment of post-traumatic nail bed deformities with split-thickness nail bed grafts. *Chir Main*. 2002;21(6):337–42.
10. Hsieh SC, Chen SL, Chen TM, Cheng TY, Wang HJ. Thin split-thickness toenail bed grafts for avulsed nail bed defects. *Ann Plast Surg*. 2004;52(4):375–9.