



Case Report

Open anterior dislocation of the hip in an adult: a case report and review of literature^{☆,☆☆}

Anderson Luiz de Oliveira*, Eduardo Gomes Machado

Instituto Jundiense de Ortopedia e Traumatologia, Faculdade de Medicina de Jundiaí, Jundiaí, SP, Brazil

ARTICLE INFO

Article history:

Received 3 April 2013

Accepted 23 April 2013

Keywords:

Hip

Hip dislocation

Hip fractures

Open fractures

ABSTRACT

Open anterior hip dislocation is a rare condition and results from high-energy trauma. Ten cases of open anterior dislocation have been described in the literature so far. Its rarity is due to the inherent stability of the joint, its deep position in the pelvis, with strong ligaments and bulky muscles around the articulation. Several factors influence the prognosis, such as the degree of compounding, the associated soft tissue injuries, the age of the patient and, mainly, the delay in reduction. The main complications are: arthrosis of the hip, with incidence of 50% of cases, when associated with fractures of the femoral head; and osteonecrosis of the femoral head, with incidence between 1.7 and 40% (in closed anterior dislocation). Because of the rarity and the potential disability of this lesion, we report a case in a 46-year-old man, involved in an automobile accident. The hip was reduced (anterior superior dislocation) in the first three hours of the trauma. The patient was kept non-weight bearing until sixth week, with complete weight bearing after 10th week. After one year follow-up, the functional result was poor (Harris Hip Score: 52), probably because of the associated labral tear, but without signs of osteonecrosis of the femoral head in magnetic resonance imaging.

© 2014 Sociedade Brasileira de Ortopedia e Traumatologia. Published by Elsevier Editora Ltda. All rights reserved.

Luxação anterior exposta do quadril em um adulto: relato de caso e revisão da literatura

RESUMO

A luxação anterior exposta do quadril é condição rara e resulta de trauma de alta energia. Até o momento, foram descritos na literatura 10 casos. Sua raridade deve-se à estabilidade inerente da articulação e à posição profunda na pelve, com fortes ligamentos e musculatura volumosa ao seu redor. Influenciam o prognóstico dessa lesão diversos fatores, tais como grau de contaminação, lesões de partes moles, idade do paciente e, principalmente, atraso na redução. As principais complicações são: artrose do quadril, com incidência que pode chegar a 50% dos casos, quando associada a fraturas da cabeça femoral; e osteonecrose da cabeça

Palavras-chave:

Quadril

Luxação do quadril

Fraturas do quadril

Fraturas expostas

[☆] Please cite this article as: de Oliveira AL, Machado EG. Luxação anterior exposta do quadril em um adulto: relato de caso e revisão da literatura. Rev Bras Ortop. 2014;49:94-97.

^{☆☆} Study conducted at Hospital de Caridade São Vicente de Paulo, Jundiaí, SP, Brazil.

* Corresponding author.

E-mail: anderson.luizoliveira@hotmail.com (A.L. de Oliveira).

do fêmur, com incidência entre 1,7% e 40% (nos casos de luxação anterior fechada). Por causa da raridade e da potencial incapacidade funcional decorrente dessa lesão, relatamos o caso de um homem de 46 anos vítima de acidente automobilístico. Foi feita redução do quadril (luxação do tipo anterior alta) nas primeiras três horas pós-trauma. O paciente foi mantido sem carga até a sexta semana, com carga total após a 10^a semana. Após um ano de seguimento, observou-se resultado funcional pobre (Harris Hip Score: 52), provavelmente por causa de lesão labral associada, porém sem sinais na ressonância nuclear magnética de osteonecrose da cabeça femoral.

© 2014 Sociedade Brasileira de Ortopedia e Traumatologia. Publicado por Elsevier Editora Ltda. Todos os direitos reservados.

Introduction

The hip joint is inherently stable, which requires significant force to promote its dislocation.¹ Thus, hip dislocations usually result from high-energy trauma. Cranio-cerebral, thoracic and abdominal injuries are commonly associated. Skeletal injuries often associated include fractures of head or femoral neck, femoral shaft, acetabulum and pelvis, as well as knee, ankle and foot injuries and neurological lesions.^{1,2}

Previous hip dislocations are uncommon and constitute 12% of traumatic hip dislocations. These injuries may occur in accidents by deceleration, in that the vehicle occupant is with his (her) legs bent, abducted, and externally rotated during impact, as well as in motorcycle accidents in which the legs are often in hyperabduction. The hip position determines the type of anterior dislocation: pubic/superior type when the hip is extended, and obturator/lower type when it is in flexion.¹⁻³

So far, research in databases (Lilacs, Medline, SciELO and Cochrane) revealed ten cases of open anterior hip dislocation reported in the literature,⁴⁻¹³ six of them in children between five and 11 years, one in a teenager aged 15 years, and three in adults. Because of the rarity and the potential incapacity resulting from that injury, we describe this case.

Case report

Male patient, 46 years old, victim of an automobile accident, was ejected from the vehicle. He was admitted in our hospital about an hour after the injury, brought by the rescue team.

On examination, the following were observed: he was conscious and hemodynamically stable; with a wound of about 10 cm on the left inguinal region, cross position, with exposure of the left femoral head; hip in extension, abduction and external rotation (Fig. 1); distal pulses present and, apparently, no signs of neurological impairment in the affected limb.

The initial radiographs revealed high anterior dislocation of left hip (Fig. 2) and fracture of the left clavicle; no visceral injury was detected.

The patient was sent to the operating room two hours after admission. A lesion of the proximal rectus femoris muscle was viewed. Cleaning and debridement of the wound were made; the joint reduction was done by traction and internal rotation, without difficulties. Clinical and radiographic evaluation revealed a stable reduction (Fig. 3). The wound was

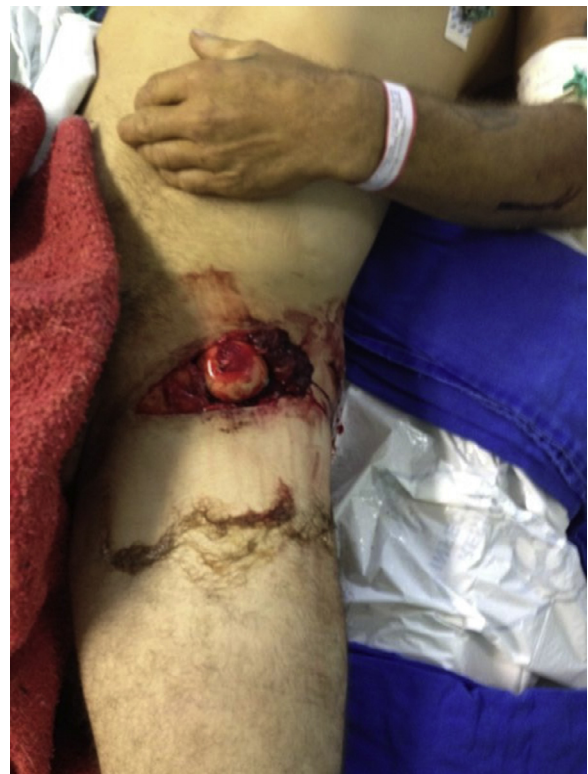

Fig. 1 – Appearance of wound at the root of the left thigh, exposing the femoral head.

closed with introduction of broad-spectrum antibiotics for 72 h. Wound healing without need for further debridement occurred.

The post-reduction computed tomography (CT) demonstrated joint congruence and great trochanter fracture without deviation, treated conservatively (Fig. 4). The patient was kept without loading for six weeks, followed by progressive load, with full load after 10 weeks.

After one year of follow-up, the functional outcome was poor (Harris Hip Score: 52 points) with limited range of motion of the hip (flexion 90°, extension 20°, abduction 20°, adduction 10°, internal rotation 10°, external rotation 30°) and without neurological deficit. Radiographs and magnetic resonance imaging (MRI) showed no signs of necrosis of the femoral head until the last follow-up. MRI showed a lesion of the

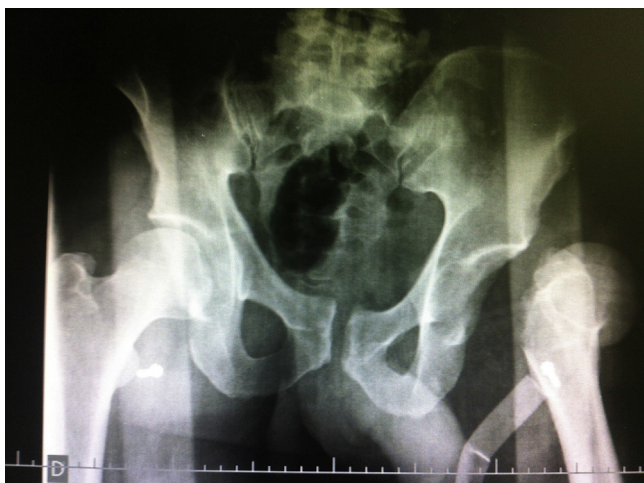


Fig. 2 – AP radiograph of the pelvis demonstrating anterosuperior dislocation of the left hip, with prominence of the lesser trochanter.

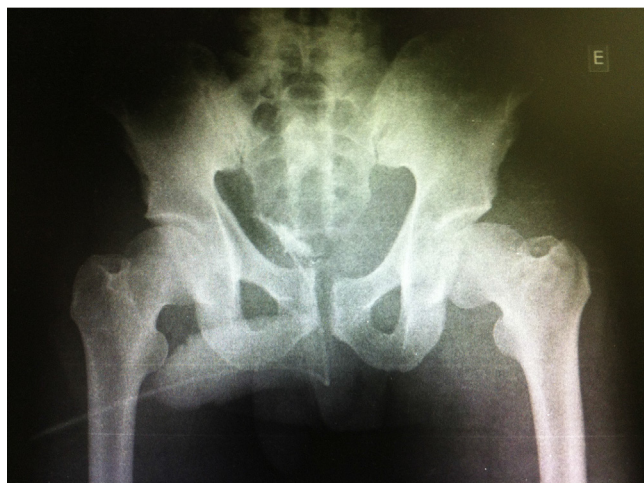


Fig. 3 – Postreduction radiograph showing left hip joint congruency.

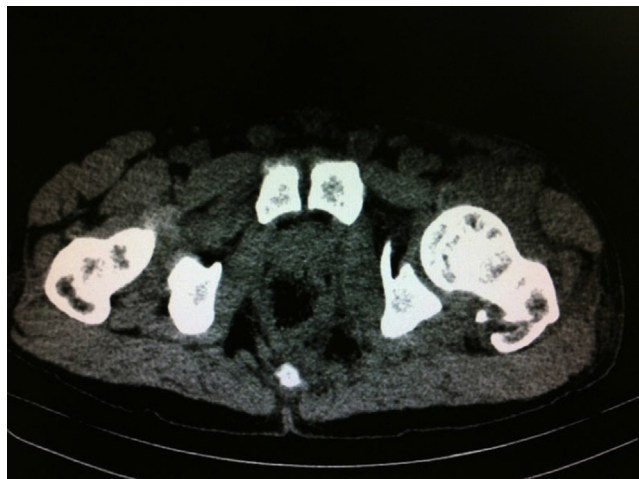

Fig. 4 – Postreduction CT showing fracture of left greater trochanter.

anterosuperior portion of the labrum, associated with thickening of the tendon of the rectus femoris muscle (Fig. 5).

Discussion

Anterior traumatic hip dislocation is a rare injury. The injury is classified according to the position taken by the femoral head: pubic (high) and obturator (low).² Biomechanical studies on cadavers have shown that extension, abduction and external rotation of the hip produces pubic dislocation with the femoral head positioned in front of the horizontal ramus of the pubis, with possibility of laceration of pectineus and iliopsoas muscles and of injury to the neurovascular bundle. On the other hand, flexion, abduction and external rotation of the hip produce dislocation of obturator type, in which the femoral head is held against the anterolateral margin of the obturator foramen, causing an indentation fracture in the anterosuperior aspect of the femoral head, without injury to the iliofemoral ligament.^{1,3,14}

Radiographically, the high dislocation can be confused with posterior displacement in the AP view of the pelvis, as the femoral head is located above the acetabulum. The

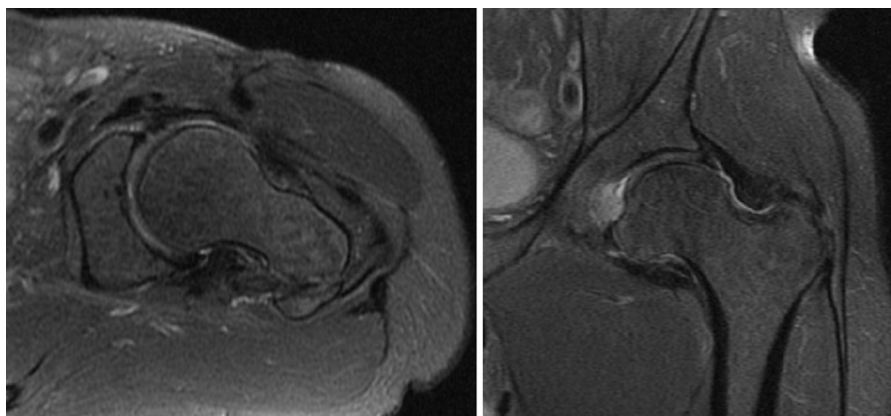


Fig. 5 – MRI showed no signs of osteonecrosis of femoral head; visualization of lesion of the anterior superior portion of the acetabular labrum.

observation of the lesser trochanter helps to distinguish between these two types. In anterosuperior dislocation, the hip is in external rotation and the lesser trochanter is prominent; in posterior dislocation, the femur is internally rotated, with the trochanter less prominent or obscured.³

The reduction is accomplished by traction and countertraction. In the case of superior displacement, the traction is done till the femoral head is leveled with the acetabulum, and then a smooth internal rotation is applied.¹

CT is useful in operative planning, required in cases of concomitant fractures, irreducible dislocation or incongruent reduction. Location, size and number of free intra-articular fragments are outlined, which allows an accurate preoperative planning.¹

Studies indicate that MRI is not consistent in predicting the occurrence of avascular necrosis and, therefore, in determining whether the early liberation of weight is a risk factor for femoral head collapse. In reduced hips, the rate of osteonecrosis of the femoral head is higher after six hours of injury. So, in these cases it may be reasonable to delay the liberation of total weight for eight to 12 weeks. In cases with reduction in the first six hours, the treatment includes a short rest period (two weeks), followed by progressive mobilization and loading. Continuous passive motion is desirable, to avoid intra-articular formation of adhesions and arthrosis. Extremes of motion must be avoided for six to eight weeks, to allow capsular healing.¹

Arthrosis is one of the most common complications, most frequently in cases of posterior versus anterior dislocation. The association with fractures of the femoral head can cause arthritis in 50% of patients.¹

In cases of closed anterior dislocation, the risk of avascular necrosis varies from 1.7% to 40% in different series.¹ In the case of open dislocations, there was osteonecrosis of femoral head in five of nine cases (of the ten cases previously described in the literature, one case of death in the immediate postoperative period was excluded). Of these five cases, three were associated with deep infection.⁴⁻¹³

Despite the absence of osteonecrosis of the femoral head and infection, the related case evolved to a poor clinical outcome, probably because of the associated labral lesion. Therefore, the degree of contamination, the delay in reducing the lesion and the associated soft tissue injuries are key factors in the treatment and prognosis of open anterior dislocations of the hip.^{4,5,7,8,11,12}

Conflicts of interest

The authors declare no conflicts of interest.

REFERENCES

1. Tornetta 3rd P. Hip dislocations and fractures of the femoral head. In: Bucholz RW, Heckman JD, Court-Brown CM, editors. *Rockwood & Green's fractures in adults*. 6th ed. Philadelphia: Lippincott, Williams and Wilkins; 2006. p. 1716-52.
2. Epstein HC, Harvey JP. Traumatic anterior dislocation of the hip: management and results. *J Bone Joint Surg Am*. 1972;54:1561-70.
3. Erb RE, Steele JR, Nance Jr EP, Edwards JR. Traumatic anterior dislocation of the hip: spectrum of plain film and CT findings. *Am J Roentgenol*. 1995;165(5):1215-9.
4. Muzaffar N, Ahmad N, Bhat A, Shah N. Open anterior hip fracture dislocation in a young adult with exposed femoral head: a case report. *Webmed Central Orthopaedics* [serial on the internet] 2011;2(9): [about 7 p.]. Available from: <http://www.webmedcentral.com/articleview/21705> [cited 28.09.11].
5. Schwartz DL, Haller JA Jr. Open anterior hip dislocation with femoral vessel transection in a child. *J Trauma*. 1974;14(12):1054-9.
6. García Mata S, Hidalgo Ovejero A, Martínez Grande M. Open anterior dislocation of the hip in a child. *J Pediatr Orthop B*. 1998;7(3):232-4.
7. Khan SA, Sadiq SA, Abbas M, Asif N, Gogi N. Open anterior dislocation of the hip in a child. *J Trauma*. 2001;51(4):773-6.
8. Rafai M, Ouarab M, Largab A, Guerch A, Rahmi M, Trafah M. Open post-traumatic anterior luxation of the hip in children. Apropos of a case and review of the literature. *Rev Chir Orthop Reparatrice Appar Mot*. 1995;81(2):178-81.
9. Renato L. Open anterior dislocation of the hip in a child. *Acta Orthop Scand*. 1987;58(6):669-70.
10. Grundy M, Kumar N. Open anterior dislocation of the hip. *Injury*. 1982;13(4):315-6.
11. Lamberti PM, Rabin SI. Open anterior-inferior hip dislocation. *J Orthop Trauma*. 2003;17(1):65-6.
12. Sadhoo UK, Tucker GS, Maheshwari AV, Kaul A. Open anterior fracture dislocation of the hip: a case report and review of literature. *Arch Orthop Trauma Surg*. 2005;125(8):550-4.
13. Sabat D, Singh D, Kumar V, Gupta A. Open perineal dislocation of hip in a child. *Eur J Orthop Surg Traumatol*. 2009;19: 277-9.
14. Amihood S. Anterior dislocation of the hip. *Injury*. 1975;7(2):107-10.