



## Case Report

# Fracturing of revision of a cobalt-chrome femoral head after fracturing of a ceramic femoral head, with diffuse metallosis. Case report

Pedro Miguel Dantas Costa Marques,<sup>1,\*</sup> António Félix,<sup>1</sup> Bruno Alpoim,<sup>1</sup> Maria Elisa Rodrigues,<sup>1</sup> Pedro Sá,<sup>1</sup> Carolina Oliveira,<sup>1</sup> Francisco Lima Rodrigues,<sup>2</sup> Paulo Gonçalves,<sup>2</sup> Maieiro Costa,<sup>2</sup> António Rodrigues<sup>3</sup>

<sup>1</sup>Resident in the Orthopedics and Traumatology Service, Local Healthcare Unit of Alto Minho, Viana do Castelo, Portugal.

<sup>2</sup>Hospital Attending Physician in the Orthopedics and Traumatology Service, Local Healthcare Unit of Alto Minho, Viana do Castelo, Portugal.

<sup>3</sup>Director of the Orthopedics and Traumatology Service, Local Healthcare Unit of Alto Minho, Viana do Castelo, Portugal.

Work performed at the Orthopedics and Traumatology Service, Local Healthcare Unit of Alto Minho, Viana do Castelo, Portugal.

## ARTICLE INFO

### Article history:

Received on March 5, 2012

Approved on May 8, 2012

### Keywords:

Femur Head, Ceramics

Hip Prosthesis

Metal Ceramic Alloys

## ABSTRACT

We present a case of a fracture of a cobalt-chrome femoral head after revision of a hip total prosthesis with ceramic femoral head fracture. During surgery we found the cobalt-chrome femoral head fracture, wear of the polyethylene and massive metallosis in muscular and cartilaginous tissue. Both femoral stem and acetabular cup were stable and without apparent wearing. After surgical debridement, we promoted the substitution of the femoral head and the acetabular polyethylene by similar ones. After 12 months of follow-up, the patient has no pain complaints, function limit or systemic signs associated with malign metallosis.

© 2013 Sociedade Brasileira de Ortopedia e Traumatologia. Published by Elsevier Editora Ltda. All rights reserved.

\*Corresponding author at: Rua Manuel da Silva nº 19, 4900-780, Viana do Castelo, Portugal.

E-mail: spotmarques@gmail.com

## Introduction

Use of ceramic femoral heads has achieved wide recognition for total hip arthroplasty since their first use 30 years ago. Their advantages of biocompatibility and resistance against corrosion contrast with their low plasticity and elasticity, in comparison with metal components, thus giving rise to greater risk of material failure.<sup>1</sup>

Contamination of the hip joint by ceramic fragments is a well-known consequence of ceramic femoral heads fracture. Revision surgery after a ceramic femoral head fracture may be problematic in terms of choosing the femoral head to insert. There have been reports of clinical cases of massive metallosis and detachment of the femoral stem when the revision is done using stainless steel femoral heads<sup>2</sup> and, more recently, cases of cobalt poisoning following revision using femoral heads made of cobalt-chrome.<sup>3</sup>

Although cases of fracturing of cobalt-chrome femoral heads have been described,<sup>4</sup> these occurred monoblock prostheses. Currently, there are no cases of fracturing of femoral heads made of cobalt chrome.

## Clinical case

In June 2006, a 46-year-old male patient with a body mass index of 24 underwent left-side uncemented total hip arthroplasty, due to idiopathic hip arthrosis. All the components were produced by Lafitt SA, consisting of a Selfitt 5 mm self-locking porous uncemented femoral stem, a Cupfitt Plus 48 mm porous spiked acetabular shell component, a Cupfitt Plus std 48 mm ceramic-plastic polyethylene acetabular liner for a 28 mm femoral head and a Dia 28 mm alumina ceramic femoral head.

The approach used was a posterior route (Gibson approach) and the procedure took place without intercurrents, in accordance with the surgical technique put forward by the manufacturer. The patient was released from hospital on the fifth postoperative day (Fig. 1).

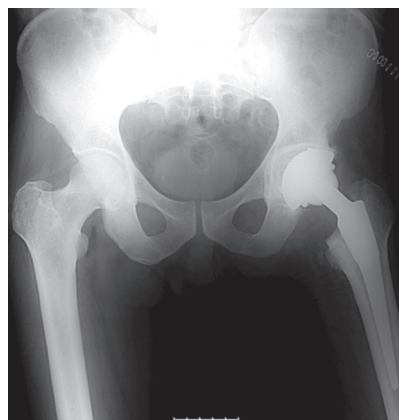
The patient was followed up for two years without intercurrents or joint pain, and presented good joint mobility. However, during the third year after the operation, in October 2009, he came to our emergency department because of an acute left hip pain with incapacity to mobilize the hip, following a fall. A radiological examination showed a comminuted fracture of the ceramic femoral head (Fig. 2).

The patient remained hospitalized until the revision surgery, which was performed one week later. During the operation, multiple fragments of the ceramic femoral head and central wear of the polyethylene were observed, but without any visible macroscopic abnormalities of the femoral neck or detachment of the femoral stem or acetabular component. Abundant lavage was performed using a pressure gun, with surgical debridement and removal of the ceramic fragments. The polyethylene acetabular component was replaced by another one that was the same, but indicated for metal heads (48 mm); and the ceramic femoral head was replaced by a Lafitt 28 mm cobalt-chrome head with a medium neck (Fig. 3). The remainder of the hospital stay passed by without

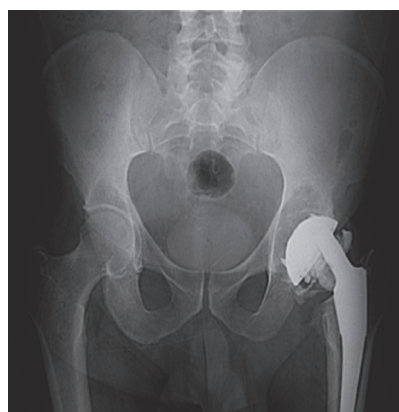
intercurrents, and the patient was released on the sixth day after the operation.

After another six months of follow-up, the patient was found to be free from painful complaints or abnormalities of mobility, and there was only a slight density increase on the lateral face of the thigh (region of the fascia lata) (Fig. 4).

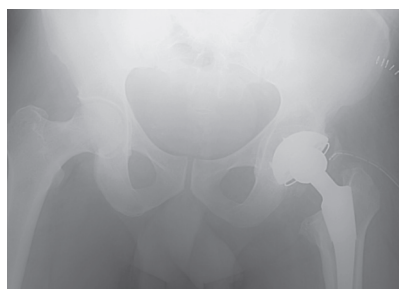
Approximately one year after the revision surgery, in October 2010, the patient was admitted to the emergency



**Fig. 1 - Immediate postoperative X-ray on left-side total hip arthroplasty.**



**Fig. 2 - Ceramic femoral head fracture after trauma.**



**Fig. 3 - Revision on ceramic femoral head fracture, with replacement by a cobalt-chrome femoral head.**

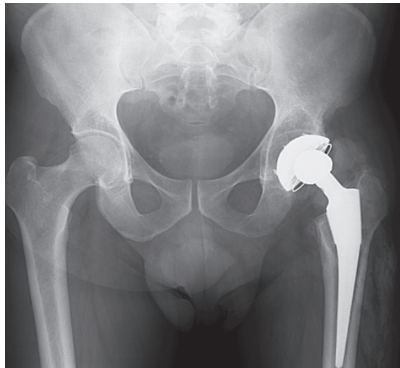
service presenting pain and functional incapacity of the left leg, with the hip flexed and externally rotated, compatible with posterior dislocation of the total hip prosthesis. Radiologically, dislocation of the total hip prosthesis was confirmed, with apparent fracturing of the cobalt-chrome femoral head and increased radiological opacity of the muscles of the lateral face of the thigh (Fig. 5). Closed reduction of the dislocation was performed under general anesthesia (Fig. 6), and subsequent revision surgery was advised, which was done in November of the same year.

During the operation, diffuse metallosis of the muscle and cartilage tissues was seen (Fig. 7), along with central wear of the

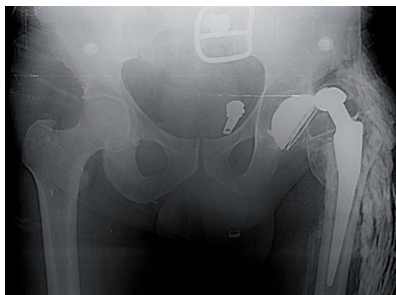polyethylene and fracturing of the cobalt-chrome femoral head, in a half-moon shape (Fig. 8). Once again, the femoral stem and acetabular component were found to be well attached and stable, with slight abrasions of the femoral neck. Wide-ranging surgical debridement was performed, with abundant lavage and replacement of the previous polyethylene acetabular component and femoral head by equal components (Fig. 9).

The hospital stay passed by without interurrences, and the patient was released on the sixth postoperative day. Neither before nor after the operation did he present any symptoms of malignant metallosis or cobalt poisoning (either clinically or in analytical control tests). In the anatomopathological examination, tissue fragments of fibroadipose nature were observed and several of them were seen to have abundant histiocytic cells containing a strange granular material, without apparent evidence of malignancy.

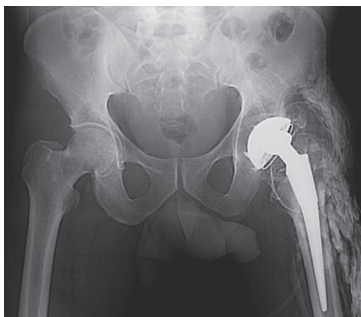
After 12 months of follow-up, the patient does not present any painful complaints and has good mobility for activities of daily living and professional activities. Radiologically, he does not show any signs of detachment or wear of the prosthetic components (Fig. 10).



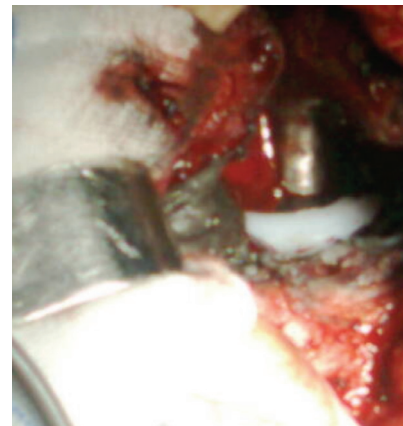**Fig. 4 - Six-month follow-up showing increased radiological density on the lateral face of the right thigh.**



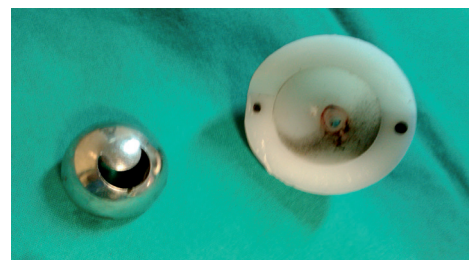
**Fig. 5 - Dislocation of total hip prosthesis with apparent fracturing of the cobalt-chrome femoral head and increased radiological opacity of the muscles of the lateral face of the thigh.**



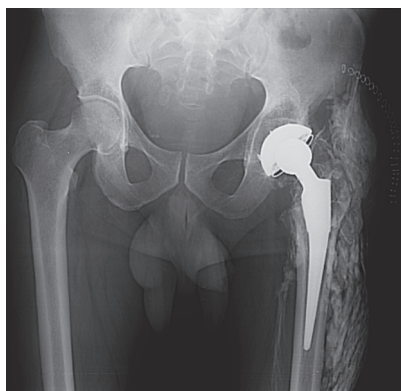
**Fig. 6 - Radiological control after reduction of the dislocation.**



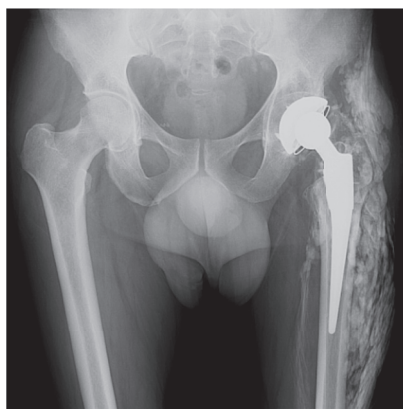
**Fig. 7 - Diffuse metallosis of the periarticular tissues.**



**Fig. 8 - Fracturing of the cobalt-chrome femoral head (left) and polyethylene wear (right).**



**Fig. 9 - Immediate postoperative period after revision of the total hip prosthesis, with new cobalt-chrome femoral head.**



**Fig. 10 - Follow-up 12 months after the operation.**

## Discussion

Although ceramic femoral head fracture is rare, it has been described in many clinical cases.

According to the literature available, up to 2006, at least 45 cases of fractured ceramic femoral heads had been described.<sup>5-22</sup> In addition, a large retrospective multicenter study on revision surgery following ceramic femoral head fracture had been published, along with recommendations from the French Society for Orthopedic and Traumatological Surgery (Sofcot).<sup>24,25</sup>

Several factors have been indicated as responsible for ceramic femoral head fracture, and these can be divided into factors that are dependent on the patient, such as trauma, physical activity or obesity,<sup>8,10,15,17,21</sup> and those that are independent of the patient, such as defects in the production of the material<sup>7,9,16,20</sup> or intraoperative complications (and this is the most frequent cause). The main intraoperative complications consist of excessive impacting of the femoral head and interposition of bone fragments between the femoral neck and the ceramic component.<sup>9,10,16,21,23</sup> Thus, the recommendations for how to prevent these complications

consist of careful handling of the cone and femoral head and careful placement of the ceramic head.

Observations of metallosis mostly occur after revision surgery on fracturing of a ceramic femoral head, with replacement by a metal head,<sup>2,12,21,23,26</sup> but may also occur after fracturing of a ceramic head because of the impingement between the femoral neck and the acetabular polyethylene.<sup>15</sup>

Most authors maintain the hypothesis that the treatment for this clinical situation consists of four essential parameters, replacement of the femoral head and the acetabular polyethylene, verify the state of the femoral stem and neck and a total synovectomy.

The acetabular polyethylene insert should always be replaced, even if no macroscopic alterations are seen, since there may be microparticles that create an abrasive surface between the polyethylene and the femoral head (especially if the replacement head is made of metal).<sup>23,26</sup>

In total synovectomy, the principles of tumor resection should be applied: lavage and surgical debridement with a wide safety margin). In our case, it was not possible to fully remove the metallosis, given that it was very extensive. As much surgical debridement as possible was performed, in order to be able to close the surgical wound and avoid joint instabilities.

There is greater controversy and less consensus in relation to choosing the type of femoral head to use for replacing the broken ceramic femoral head. This choice will be strongly related to the state of the femoral neck. Matziolis concluded that using a metal-polyethylene joint pair is contraindicated after fracturing of a ceramic head,<sup>26</sup> and that using a ceramic-ceramic pair might reduce the risk of metallosis.<sup>3</sup> In the presence of detachment of the femoral stem, this should always be replaced. Abnormalities in the medullary cone should also, if possible, lead to its replacement, with subsequent use of a new ceramic femoral head. If it is not possible to replace the femoral neck, use of ceramic heads is contraindicated and a cobalt-chrome head should be chosen.<sup>27</sup>

Currently, there is no guidance in the literature for cases of fracturing of cobalt-chromium femoral heads. In our case, since the femoral stem was stable and the medullary cone did not present any relevant macroscopic alterations, it was decided to replace the polyethylene and the cobalt-chrome cup with others that were the same. It was not possible to study the material extracted. Because of the variety of cases of cobalt poisoning that have been described, it is important to carry out rigorous clinical and analytical surveillance on the patient.<sup>28</sup> Thus, the present authors aim to draw attention to this clinical adversity in order to avoid similar situations.

## Conflicts of interest

The authors declare that there was no conflict of interests in conducting this study.



## REFERENCES

1. Davidson JA. Characteristics of metal and ceramic total hip bearing surfaces and their affect on long-term ultra high molecular weight polyethylene wear. *Clin Orthop*. 1993;(294):361-78.
2. Allain J, Goutallier D, Voisin MC, Lemouel S. Failure of a stainless steel femoral head of a revision total hip arthroplasty performed after fractura of a ceramic femoral head. Case report. *J Bone Joint Surg*. 1998;80(9):1355-60.
3. Oldenburg M, Wegner R, Baur X. Severe cobalt intoxication due to prosthesis wear in repeated total hip arthroplasty. Case report. *J Arthroplasty*. 2009;24(5):825.
4. Giori NJ. Unexpected finding of a fractured metal prosthetic femoral head in a nonmodular implant during revision total hip arthroplasty. Case report. *J Arthroplasty*. 2010;25(4):659.
5. Arenas A, Tejero A, Garbayo A, Arias C, Barbadillo J, Lecumperri J. Ceramic femoral head fractures in total hip replacement. *Int Orthop*. 1999;23(6):351-2.
6. Burckhardt A, Besberat C. How safe is ceramic heads as hip endoprotheses? A series of three head fractures within 3 months. *Arch Orthop Trauma Surg*. 1993;112(5):215-9.
7. Callaway Gh, Flynn W, Ranawat CS, Sculco TP. Fracture of femoral head after ceramic-on-polyethylene total hip arthroplasty. *J Arthroplasty*. 1995;10(6):855-9.
8. Fritsch E, Gleitz M. Ceramic femoral head fracture in total hip arthroplasty. *Clin Orthop*. 1996;(328):129-36.
9. Hannouche D, Nich C, Bizot P, Meunier A, Nizard R, Sedel L. Fractures of ceramic bearings. *Clin Orthop*. 2003;(417):19-26.
10. Higuchi F, Shiba N, Inoue A, Wakebe I. Fracture of an alumina ceramic head in total hip arthroplasty. *J Arthroplasty*. 1995;10(6):851-4.
11. Holmer P, Nielsen PT. Fracture of a ceramic femoral head in total hip arthroplasty. *J Arthroplasty*. 1993;8(6):567-71.
12. Kempf I, Semlitsch M. Massive wear of steel ball head by ceramic fragments in the polyethylene acetabular cup after revision of a total hip prosthesis with fractured ceramic ball. *Arch Orthop Trauma Surg*. 1990;109(5):284-7.
13. Krikler S, Schatzker J. Ceramic head failure. *J Arthroplasty*. 1995;10(6):860-2.
14. Mangione P, Pascarel X, Vinciguerra B, Honton JL. Fracture of the ceramic head in total hip prosthesis. Apropos of 2 cases. *Int Orthop*. 1994;18(6):359-62.
15. Mclean CR, Dabis H, Mok D. Delayed fracture of the ceramic femoral head after trauma. *J Arthroplasty*. 2002;17(4):503-4.
16. Michaud RJ, Rashad SY. Spontaneous fracture of the ceramic ball in a ceramic-polyethylene total arthroplasty. *J Arthroplasty*. 1995;10(6):863-7.
17. Moreschini O, Braidotti P. Traumatic breakage of the ceramic head of prosthesis in total hip replacement. *Ital J Orthop Traumatol*. 1991;17(3):339-43.
18. Otsuka NY, Schatzker J. A case of a fracture of a ceramic head in total hip arthroplasty. *Arch Orthop Trauma Surg*. 1994;113(2):81-2.
19. Peiro A, Pardo J, Navarrete R, Rodrigues-Alonso L, Martos F. Fracture of the ceramic head in total hip arthroplasty. Report of 2 cases. *J Arthroplasty*. 1991;6(4):371-4.
20. Piconi C, Labanti M, Magnani G, Caporale M, Maccauro G, Magliocchetti G. Analysis of a failed alumina THR ball head. *Biomaterials*. 1999;20(18):1637-46.
21. Pulliam I, Trousdale R. Fracture of a ceramic femoral head after revision operation. *J Bone Joint Surg*. 1997;79(1):118-21.
22. Wenda K, Ritter G, Rudig L. Theraoy of burst ceramic head of a hip prosthesis. *Aktuelle Traumatol*. 1993;23(6):294-6.
23. Allain J, Roudot-Thoraval F, Delecryn J, Anract P, Migaud H, Goutallier D. Revision total hip arthroplasty performed after fracture of a ceramic head. *J Bone Joint Surg*. 2003;85-A(5):825-30.
24. Connes H. Des déclarations à la matériovigilance aux décisions de La CNM. *Rev Chir Orthop*. 2003;89:49.
25. Dambreville A. Conduite de Chirurgie Orthopédique proposée aux chirurgiens confrontes au problème. *Rev Chir Orthop*. 2003;89:51.
26. Matziolis G, Perka C, Disch A. Massive metallosis after revision of fracture ceramic head onto a metal head. *Arch Orthop Trauma Surg*. 2003;123(1):48-50.
27. Panagopoulos A, Megas P, Tyllianakis J, Dimakopoilos P, Lambiris E. Ceramic femoral head fracture with massive metallosis and sever wear of the cone: a case report and review of the literature. *Eur J Orthop Surg Traumatol*. 2006;16(1):56-9.
28. Tower SS. Arthroprosthetic cobaltism: neurological and cardiac manifestations in two patients with metal-onmetal arthroplasty: a case report. *J Bone Joint Surg Am*. 2010;92(17):2847-51.