

Effect of topical mitomycin-C on total collagen deposits on the submucosa of intact vocal folds in swine

Efeito da mitomicina-C tópica sobre os depósitos de colágeno total na submucosa das pregas vocais íntegras de suínos

MARCELO CHARLES PEREIRA¹; JOÃO CARLOS DOMINGUES REPKA²; PAULO ANTONIO MONTEIRO CAMARGO³; DANIEL ZENI RISPOLI, ACBC-PR⁴; ANTÔNIO CARLOS LIGOCKI CAMPOS, TCBC-PR⁵; JORGE EDUARDO FOUTO MATIAS⁶

A B S T R A C T

Objective: To compare the effects of topical mitomycin-C at different concentrations on submucosal collagen deposition on the vocal folds of swine. **Methods:** The animals were divided into three groups according to the composition of the topical solution to be applied to the vocal folds: 0.9% saline solution (control group); 4 mg/ml mitomycin-C (group 1) and 8 mg/ml mitomycin-C (group 2). Thirty days after the application, all animals were sacrificed, their vocal folds were collected and stained by the picrosirius red technique, and submucosal collagen deposition areas were estimated by the Image Pro Plus 4.5® software. Mann-Whitney test was used to compare differences between parameters of each group. **Results:** The means of the areas of submucosal collagen deposits on vocal folds were 3110.44 square micrometers (μm^2), 3115.98 μm^2 and 3105.78 μm^2 for groups control, 1 and 2, respectively. There were no statistical differences across the three groups ($p>0.05$). **Conclusion:** Mitomycin-C topically applied to intact vocal folds of swine did not alter submucosal collagen deposition.

Key words: Wound healing. Mitomycin. Vocal cords. Collagen. Swine.

INTRODUCTION

Mitomycin-C is an antimetabolic agent that inhibits fibroblast proliferation when applied topically, and has frequently been used in experimental models to reduce cicatrix formation¹. It has been demonstrated that mitomycin-C is effective when used experimentally in the treatment of subglottic stenosis and posterior glottic stenosis, situations in which the abnormal scar tissue formation and stenosis were modulated and replaced by the regrowth of the lining mucosa with the topical application of mitomycin-C².

Studies have shown the effectiveness of mitomycin-C in reducing cicatrix formation and describe its mechanism of action as the inhibition and blockage of DNA synthesis, thus preventing fibroblast proliferation in the surgical area, allowing for less scar tissue formation where the substance is applied²⁻⁴. The action of mitomycin is directly related to its concentration and the length of time it remains in contact with the wound⁵. This behavior, in a way, leads one to expect that higher concentrations and longer exposure may produce greater biological effect.

Due to the small caliber of the laryngeal lumen, an unintended contact of mitomycin-C with the mucosal surface of the intact vocal cord may occur. Nevertheless, studies reporting on the repercussions of this sort of exposure are not found in the pertinent literature.

The objective of the present study was to evaluate the effect of the topical application of mitomycin-C at different concentrations on total collagen deposits on the submucosa of intact vocal folds in swine.

METHODS

In this experiment, nine swine of the larger white breed (*Suideo sus*) were used, in compliance with the guidelines of the Colégio Brasileiro de Experimentação Animal – COBEA⁶ (Brazilian College of Animal Experimentation) and recommendations for the euthanasia of experimental animals^{7,8}. The swine (4 males and 5 females), weighing between 8,700 g and 11,562 g (mean = 10,131 g) and age ranging from 27 to 31 days underwent clinical evaluation and were considered to be healthy and

Study conducted at the Experimental Farm of the Universidade Federal do Paraná (UFPR) and at the Experimental Surgery Laboratory of the Graduate Program in Clinics and Surgery of UFPR, Curitiba, PR, Brazil.

1. Master's student, Graduate Program in Clinics and Surgery, Universidade Federal do Paraná – UFPR (Federal University of Paraná); 2. Associate Professor, Department of Biochemistry, Unibrasil; 3 PhD student, Graduate Program in Clinics and Surgery, UFPR; 4. Master's student, Graduate Program in Clinics and Surgery, UFPR; 5. Full Professor, Department of Surgery, UFPR; 6. Associate Professor, Department of Surgery, UFPR.

within the normal distribution of weight for age according to EMBRAPA standards.

The animals were randomized into three groups according to the composition of the solution to be applied on both vocal cords of each animal: the control group was treated with the application of a cotton pledget soaked in 0.9% saline; group 1, a cotton pledget soaked in mitomycin-C at the concentration of 4 mg/mL; and group 2, a cotton pledget soaked in mitomycin-C at the concentration of 8 mg/mL.

Topical application of mitomycin

All animals underwent anesthetic induction with midazolam (Dormonid® 1mg/mL) at the dose of 0.1 mg/kg intramuscularly; acepromazine 1% (Acepran® 1%) at the dose of 0.1 mg/kg intramuscularly; ketamine (Ketalar® 50 mg/mL) at the dose of 10 mg/kg intramuscularly, and atropine 0.5 mg/mL at the dose of 0.06 mg/kg intramuscularly. The animals were anesthetized with Propofol® at the dose of 6 mg/kg intravenously (ear vein), and maintenance anesthesia was achieved with the same medication at the dose of 0.4 mg/kg intravenously.

Once anesthetized, the animals were placed in supine, in the reverse Trendelenburg position, on a special table covered with sterile drapes. To facilitate larynx alignment, a pad was placed under the upper dorsal region. For the visualization of the glottis and placement of cotton pledgets soaked in the solutions assigned to each group (Figure 1), an infant anterior commissure laryngoscope (Microfrance®) and a surgical microscope (D. F. Vasconcelos 6700) equipped with a camera system were used. The mucosa on the free border of the anterior third of the right and left vocal folds was exposed and visualized. Then, a cotton pledget with a diameter of approximately 3 mm across its longest axis, soaked in a 4 mg/mL mitomycin-C solution for group 1, and 8 mg/mL for group 2, was placed at that site, involving both vocal folds, for exactly three minutes. The same process described above was repeated for the control group, now with a saline-soaked pledget. After the three minutes, the pledget was removed and the region was washed with 0.9% saline.

Following anesthetic recovery, the swine were returned to pigsties, where the provision of water and ration was resumed 12 hours after the procedure.

The euthanasia of the animals was carried out 30 days after the endoscopic application of mitomycin-C. The animals went through the same preanesthetic and anesthetic protocols as used before, followed by electrocution. The whole of each animal's larynx was removed to make it easier to collect the vocal folds (Figure 2). An anterior longitudinal incision was made in the larynx to expose the region of the vocal folds and perform an incision bordering the thyroid cartilage for the removal of the vocal fold while preserving the mucosal coating. The specimen was pinned to a cardboard rectangle with identification of the animal, the side (right or left) of the vocal fold, as well as the anterior region of the vocal fold. Later on, that flap was fixed in 10% formalin. After a 24-

hour fixation period, using a histological slide on a grossing board, two rectangular samples were taken, stored in a histological cassette, and placed in a tissue processor (Leica® model RM 2145) for overnight processing. The samples were dehydrated serially in increasing concentrations of ethyl alcohol at 70%, 80% and 90%. Subsequently, they were cleared in xylol containing increasingly more concentrated paraffin mixtures for 12 hours. Once embedding in hot paraffin was conducted (Leica® model EG 1160), the blocks were sectioned by a microtome (Leica® model RM 2145) into 5 µm sections and arranged on a 75x25 mm glass slide. Sections were cut at two levels for each area.

The histological study was conducted using picosirius red staining with polarization microscopy, in which the non-collagenous material stained black and collagen stained yellow, orange-red and red. Those colors were selected through the software for quantification and summation of the selected areas in square micrometers. The reading of the slides was always performed in triplicate through the Image Pro plus 4.5® for Windows® software on a microcomputer coupled to an Olympus® BX50 microscope

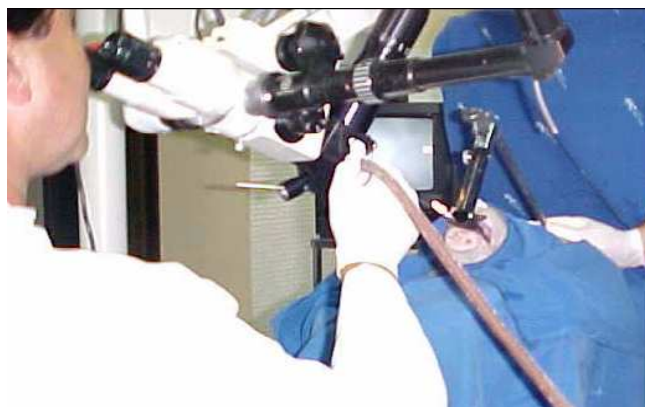

Figure 1 – Technique for the endoscopic application of mitomycin-C on the surface of vocal folds in an anesthetized animal, using a surgical microscope with an infant laryngoscope in place.

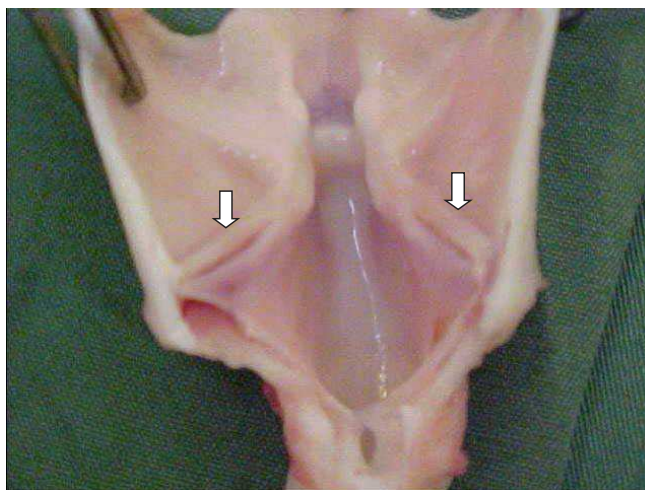


Figure 2 – Specimen (larynx) resected en bloc for subsequent vocal cord (arrows) sampling.

and a Sony® video camera, previously calibrated for measures in micrometers with a 20 x objective (Figure 3). The measurements were transferred to the Excel Windows® software and inserted into a table for statistical analysis.

Statistical analysis

In the present experimental study, three groups of three animals each, and six vocal folds per group were studied; each fold was analyzed in triplicate. The result evaluated in the present study quantified total collagen on the submucosa of the vocal folds in square micrometers (μm^2). When comparisons of results relating to differences in collagen content were made between groups, the nonparametric Mann-Whitney test was applied. In all comparisons, the null hypothesis referred to equal results in the compared groups, and the alternative hypothesis, to different results. For all tests, the significance level of 5% ($p=0.05$) was considered to be statistically significant.

RESULTS

No synechiae were observed in any of the larynx specimens examined after euthanasia.

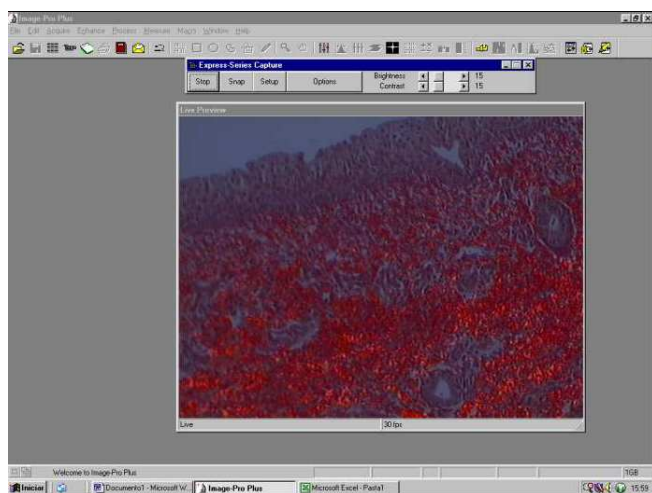


Figure 3 – A screen of the Image Pro Plus® software for analysis (calculation) of the surface area of sections, showing collagen fibers (picosirius red staining).

The means and standard deviations of the surface areas measured for collagen deposits on the vocal fold submucosa for each group of animals in the study are shown in table 1. In the control group (animals treated with topical application of 0.9% saline), the mean for the surface area of collagen deposited on the submucosa of the vocal folds was $3110.44 \mu\text{m}^2$. In group 1 (animals treated with topical application mitomycin-C at the concentration of 4mg/mL), the mean of the area of collagen deposited on the submucosa of the vocal folds was $3115.98 \mu\text{m}^2$. In group 2 (animals treated with topical application of mitomycin-C at the concentration of 8mg/mL), the mean for the area of collagen deposited on the submucosa of the vocal folds was $3105.78 \mu\text{m}^2$.

There was no significant difference between the measures of areas of total collagen deposition between the experimental groups (1 and 2) and the control group. The means for the areas of total collagen deposition in the two experimental groups were not statistically different either.

DISCUSSION

In a past study⁴ using the same model as the present study, in which an investigation was undertaken concerning the effect of topical mitomycin-C applied on a raw area of vocal fold fragment resection with CO₂ laser, it was found virtually impossible to ensure the absolutely selective use of mitomycin-C in such a small cavity as the larynx. Regardless of the greatest surgical care, the contact of the chemotherapeutic agent with the contralateral vocal fold would eventually occur. The question was, therefore, whether the effects of topical use of mitomycin-C on collagen deposits on operated vocal folds, already described in the literature, would be reproduced on anatomically intact vocal cords with their mucosal coating and free from any acute or chronic inflammatory process.

Several animal models have been proposed for experimental studies concerning endolaryngeal surgery. Garrett *et al*, 2000, compared vocal folds of dogs, pigs and monkeys, noting the amount of deposition of collagen, elastin fibers and amorphous tissue⁹. They concluded that the vocal folds of pigs and dogs are similar to those of humans

Table 1 – Quantification of collagen deposited on the submucosa of vocal cords in the studied groups.

Groups	Area of total collagen deposition (mm^2) Mean + Standard deviation	Statistical comparison with Control Group (p)	Statistical comparison Group 1 vs. 2 (p)
Control Group (0.9% Saline)	3110,44 + 340,66	—	—
Group1 (MMC 4mg/mL)	3115,98 + 279,91	0,9156	—
Group 2 (MMC 8mg/mL)	3105,78 + 308,28	0,9230	—
			0,9022

MMC= Mitomycin-C; mm^2 = square micrometer; mg/mL=miligrams per milliliter.

with respect to elastin and collagen content, in addition to exhibiting a microflap dissection plane similar to that in humans. In the present study, the experimental design required a medium-sized animal with vocal folds that resembled human vocal folds, without the need to observe function through laryngeal videostroboscopy. Otherwise, the dog would be the best model for the study of vocal fold function, as in the dog, unlike the swine, the vertical phase of the mucosal wave can be visualized by laryngeal videostroboscopy⁹.

Topical mitomycin-C has been increasingly used for situations in which the aim is to effectively control the scarring process that takes place following the surgical manipulation of vocal folds^{2,10-13}. However, in spite of experimental evidence showing significantly lower amounts of total collagen on operated vocal folds treated with mitomycin-C^{1,4,14-17}, no clinical or experimental reports can be found in the literature of similar effects or otherwise of mitomycin-C on intact vocal cords.

Under experimental conditions quite similar to those of the present study, it was possible to demonstrate a significant decrease in the area of total collagen deposited on vocal folds with partial resection of the free border and

treated with topical mitomycin-C at the concentration of 0.4 mg/mL, when compared with vocal folds submitted to an identical operation, yet without topical application of the chemotherapeutic agent⁴.

In the current study, when mitomycin-C was applied to the intact surface of anatomically healthy vocal folds, even at higher concentrations (4mg/mL and 8mg/mL), no difference was found in the estimated areas of total collagen deposition compared with the controls (Table 1). Such findings suggest selective local action of mitomycin-C on injured and healing tissues, thus corroborating the hypothesis that the intact mucosal lining of the vocal folds, without surgical manipulation and raw areas, prevents the antimetabolic effect of mitomycin-C on the submucosal deposits of total collagen.

In view of the results obtained in the present experimental study, it can be concluded that mitomycin-C, despite its already described inhibiting effect on the metabolism of total collagen on the submucosa of vocal folds with raw and/or healing areas, cannot reproduce such an effect when applied to intact vocal folds even at much higher concentrations than the therapeutic doses prescribed in the literature.

R E S U M O

Objetivo: Estudar o efeito da aplicação tópica de Mitomicina-C em diferentes concentrações sobre os depósitos de colágeno total na submucosa de pregas vocais íntegras de suínos. **Métodos:** Os animais foram divididos em três grupos de acordo com o conteúdo da solução tópica aplicada sobre as pregas vocais: solução fisiológica 0,9 % (grupo controle); Mitomicina-C tópica 4 mg/mL (grupo 1); e Mitomicina-C 8 mg/mL (grupo 2). Após 30 dias da aplicação, os animais foram submetidos à eutanásia, coletado amostras das pregas vocais e coradas pela técnica do picrosirius red com polarização para a quantificação computadorizada da deposição do colágeno, através do programa Image Pro plus 4.5®. Compararam-se as médias de área do colágeno depositado na submucosa das pregas vocais dos três grupos através do teste não paramétrico de Mann-Whitney. **Resultados:** As médias das áreas de depósito colágeno na submucosa das pregas vocais foram de 3.110,44 micrômetros quadrados (μm^2); 3.115,98 μm^2 e 3.105,78 μm^2 nos grupos controle, 1 e 2 respectivamente. Não houve diferença significativa nas áreas de depósitos de colágeno total da submucosa das pregas vocais entre os três grupos estudados ($p>0,05$). **Conclusão:** A mitomicina-C aplicada topicamente em pregas vocais suínas íntegras não alterou significativamente a deposição de colágeno na submucosa.

Descritores: Cicatrização de feridas. Mitomicina. Cordas vocais. Colágeno. Suínos.

REFERENCES

1. Garrett CG, Soto J, Riddick J, Billante CR, Reinisch L. Effect of mitomycin-C on vocal fold healing in a canine model. *Ann Otol Rhinol Laryngol*. 2001; 110(1):25-30.
2. Eliashar R, Eliashar I, Esclamado R, Gramlich T, Strome M. Can topical mitomycin prevent laryngotracheal stenosis? *Laryngoscope*. 1999; 109(10):1594-600.
3. Ilnat MA, Lariviere JP, Warren AJ, La Ronde N, Blaxall JR, Pierre KM et al. Suppression of P-glycoprotein expression and multidrug resistance by DNA cross-linking agents. *Clin Cancer Res*. 1997; 3(8):1339-46.
4. Camargo PAM, Campos ACL, Matias JEF, Rispoli DZ, Przysiechny PE, Fonseca VR. Efeito da mitomicina C tópica na cicatrização de prega vocal em modelo suíno. *Rev Bras Otorrinolaringol*. 2006; 72(5):601-4.
5. Ward RF, April MM. Mitomycin-C in the treatment of tracheal cicatrix after tracheal reconstruction. *Int J Pediatric Otorhinolaryngol*. 1998; 44(3):221-6.
6. C.O.B.E.A. Colégio Brasileiro de Experimentação Animal. Princípios éticos na experimentação animal. In: Congresso do Colégio Brasileiro de Experimentação Animal; São Paulo; 1991.
7. Close B, Banister K, Baumans V, Bernoth EM, Bromage N, Bunyan J et al. Recommendations for euthanasia of experimental animals: Part 2. DGXT of the European Commission. *Lab Anim*. 1997; 31(1):1-32.
8. Raymundo MM, Goldim JR. Ética da pesquisa em modelos animais. *Revista de Bioética e Ética Médica: Conselho Federal de Medicina*. Brasília. 2002; 10(1):31-42.
9. Garrett CG, Coleman JR, Reinisch L. Comparative histology and vibration of the vocal folds: implications for experimental studies in microlaryngeal surgery. *Laryngoscope*. 2000; 110(1):814-24.
10. Spector JE, Werkhaven JA, Spector NC, Huang S, Page RN, Baranowski B et al. Preservation of function and histologic appearance in the injured glottis with topical mitomycin-C. *Laryngoscope*. 1999; 109(7 pt 1):1125-9.
11. Hartnick CJ, Hartley BE, Lacy PD, Liu J, Bean JA, Willging JP et al. Topical mitomycin application after laryngotracheal reconstruction: a randomized, double-blind, placebo-controlled trial. *Arch Otolaryngol Head Neck Surg*. 2001; 127(10):1260-4.
12. Ribeiro FAQ, Borges JP, Zacbi FFS, Guaraldo L, Eckley CA. Clinical and histological healing of surgical wounds treated with mitomycin C. *Laryngoscope*. 2004; 114(1):148-52.

13. Roh JL, Yoon YH. Prevention of anterior glottic stenosis after transoral microresection of glottic lesions involving the anterior commissure with mitomycin C. *Laryngoscope*. 2005; 115(6):1055-9.
14. Correa AJ, Reinisch L, Sanders DL, Huang S, Deriso W, Duncavage JA, Garrett CG. Inhibition of subglottic stenosis with mitomycin-C in the canine model. *Ann Otol Rhinol Laryngol*. 1999; 108(11 Pt 1):1053-60.
15. Gray SD, Trittle N, Li W. The effect of mitomycin on extracellular matrix proteins in a rat wound model. *Laryngoscope*. 2003; 113(2):237-42.
16. Roh JL, Yoon YH. Prevention of anterior glottic stenosis after bilateral vocal fold stripping with mitomycin C. *Arch Otolaryngol Head Neck Surg*. 2005; 131(8):690-5.
17. Fang R, Sun J, Wang G, Sun D. Comparison between mitomycin C and chitosan for prevention of anterior glottic steno after CO₂ laser cordectomy in dogs. *Laryngoscope*. 2007; 117(11):2057-62.

Received in 12/10/2008

Accepted for publication in 17/12/2008

Conflict of interest: None

Financial source: None

How to cite:

Pereira MC, Repka JCD, Camargo PAM, Rispoli DZ, Campos ACL, Matias JEF. Effect of topical mitomycin-c on total collagen deposits on the submucosa of intact vocal folds in swine. *Rev Col Bras Cir*. [periódico na Internet] 2009; 36(3). Disponível em URL: <http://www.scielo.br/rcbc>

Correspondence address:

Jorge Eduardo Fouto Matias

E-mail: jefmatias@ufpr.br