

CEREBROSPINAL FLUID FISTULA AS THE PRESENTING MANIFESTATION OF PITUITARY ADENOMA

Case report with a 4-year follow-up

Ricardo Alexandre Hanel¹, Daniel Monte Serrat Prevedello², Alceu Correa³, Affonso Antoniuk⁴, João Cândido Araújo⁵

ABSTRACT - We report the case of a young woman who presented with cerebrospinal fluid (CSF) rhinorrhea due to an undiagnosed and untreated pituitary adenoma. The tumor had extended well beyond sella turcica and caused bony erosion. The patient initially refused surgery and was treated with bromocriptine and a radiation therapy. CSF leakage did not improve and she was submitted to surgery by the transsphenoidal approach with removal of a tumor mass located in sphenoid sinus and sellar region. Origin of the leak was localized and repaired with fascia lata and a lumbar subarachnoid drain was left in place for 5 days. After 4 years she has normal serum PRL levels and no rhinorrhea. The management, complications and mechanisms involved in this rare condition are discussed.

KEY WORDS: pituitary tumors, prolactinoma, CSF leakage.

Fístula líquórica como manifestação inicial de macroadenoma hipofisário: relato de caso com 4 anos de seguimento

RESUMO - Relatamos o caso de uma paciente que se apresentou com fístula líquórica devido a macroadenoma de hipófise sem diagnóstico e/ou tratamento prévio. O tumor estendia-se além dos limites da sela túrcica, causando erosão óssea. A paciente inicialmente recusou tratamento cirúrgico e foi então tratada com bromocriptina e radioterapia convencional. O fluxo de líquido da fístula não diminuiu e desta feita a paciente concordou com a realização da cirurgia. Realizou-se acesso transesfenoidal com remoção da massa tumoral do seio esfenoidal e selar. A origem da fístula foi reparada com enxerto autólogo de fascia lata. Drenagem líquórica lombar foi utilizada por 5 dias. Atualmente, após 4 anos de seguimento, a paciente se apresenta com níveis normais de prolactina e sem sinais de fístula líquórica. Discutimos o mecanismo fisiopatológico desta rara apresentação dos tumores hipofisários bem como seu manejo e complicações.

PALAVRAS-CHAVE: tumores hipofisários, prolactinoma, fístula líquórica.

Cerebrospinal fluid (CSF) fistula is a rare complication of skull base erosion by pituitary tumors and may occur after transsphenoidal surgery and has been reported in patients operated upon by this approach¹⁻³, radiotherapy^{1,3,4}, adjuvant bromocriptine use with such procedures⁵⁻⁹. Rhinorrhea occurring during primary treatment of prolactinomas with bromocriptine is also well recognized^{6,9-14}. Nevertheless, it is a rare condition in untreated patients; to our knowledge, only 15 well-documented cases have been reported¹⁵⁻²³.

We present the case of a woman with this rare condition.

CASE

A 26-year-old woman was admitted on January 1996 with aqueous rhinorrhea from her right nostril and mild left headache and earache with a history of a meningitis treated one year before. Despite significant rhinorrhea, general physical and neurological examination were negative. Initial laboratory evaluation of CSF and full blood count were normal. At the fifth day she started to report severe bilateral headache presenting meningismus and fever. Lumbar puncture was carried out and CSF analysis was compatible with septic meningitis. She was placed under strict bed rest and started ceftriaxone 2g IV daily. CSF culture showed growth of *Haemophilus influenzae* and therapy was continued. After she had improved, plain films

Study conducted in the Division of Neurosurgery, Department of Surgery, Hospital de Clínicas, Universidade Federal do Paraná (UFPR) and Department of Neurosurgery, Hospital Nossa Senhora das Graças (HNSG), Curitiba-PR, Brazil: ¹ Resident in Neurosurgery, HNSG; ² Medical Student, UFPR; ³ Associate Professor of Neurosurgery, UFPR; ⁴ Chairman of Neurosurgery, UFPR; ⁵ Associate Professor of Neurosurgery, UFPR and Neurosurgery Residency Coordinator, HNSG.

Received 14 August 2000, received in final form 17 November 2000. Accepted 21 November 2000.

Dr. Ricardo A. Hanel, MD - Rua Padre Anchieta 2004 / 604 - 80730-000 Curitiba PR - Brasil. FAX: 55 41 335 0191. E-mail: rhanel@hotmail.com

and a computerized tomography (CT) scan showed the presence of a sellar mass and erosion of the skull base. An enhanced CT scan showed a massive enhanced sellar tumor that extended superiorly into suprasellar cistern, inferiorly into sphenoid sinus, laterally into parasellar regions, anteriorly into superior and inferior orbital fissures and posteriorly into pre-pontine cistern with bone erosions of skull base and petrous apex bilaterally (Fig 1). Laboratory endocrine evaluation disclosed a serum prolactin (PRL) level superior than 2000 ng/dL (normal values up to 20 ng/dL) and other hormones were within normal levels such as serum GH 2.3 ng/dL (normal: <5 ng/dL), cortisol 6.1 µg/dL (normal: 5 to 25 µg/dL), TSH 4.27 µU/mL (normal: <10 µU/mL), T3 91.51 µg/dL (normal: 80 to 200 µg/dL), total T4 8.3 µg/dL (normal: 5 to 12 µg/dL), FSH 9.64 mU/mL (normal: 1 to 10 mU/mL in follicular fase) and LH 1.6 mU/mL (normal: 1 to 12 mU/mL in follicular fase). During investigation she presented episodes of bloody rhinorrhea.

Transsphenoidal biopsy of the tumor was carried out and pathologic evaluation revealed a pituitary adenoma. As soon as the biopsy was done she started to complain of visual difficulties and an ophthalmologic evaluation showed bitemporal hemianopsia. The patient initially refused surgery and was treated with bromocriptine and a radiation therapy. After one month of bromocriptine (7.5 mg, orally, per day) her serum PRL level was 595,92 ng/mL. She reported a significant improvement of visual fields by 2 months of treatment but rhinorrhea did not improve. Prolactin levels slowly returned to normal values and after 6 months of bromocriptine, on September 1996, was 18,2 ng/mL. CSF leakage did not improve and she was submit-

ted to surgery by transsphenoidal approach, on March 1997, with removal of a tumor mass located in sphenoid sinus and sellar region. The origin of leak was localized and repaired with fascia lata and a lumbar subarachnoid drain was left in place for 5 days. A confirmatory biopsy confirmed pituitary adenoma. Postoperatively, patient presented left ophthalmoplegia without evidence of CSF leakage. Two months after she developed another episode of rhinorrhea that subsided to bed rest.

One year after the surgery, on March 1998, she was still taking bromocriptine 7.5 mg/day presenting normal serum PRL levels and left abducens paresis without signs of rhinorrhea. On October 1998, without rhinorrhea, she stopped the bromocriptine treatment on her own. Significant tumor decrease was seen on magnetic resonance imaging (MRI) in the last evaluation on September 1999 at the outpatient clinics, and she had normal serum PRL levels, no rhinorrhea and had lost her left eye vision.

DISCUSSION

CSF fistula is a well-known complication of invasive prolactinomas occurring after treatment with bromocriptine, radiotherapy, and most frequently, after surgery^{2,9,17}. However, CSF rhinorrhea is a rare condition associated to untreated pituitary adenomas²². There are many studies involving pituitary adenomas and the occurrence of rhinorrhea, as the presenting symptom, is an extremely rare situation. In the historical Cushing's series there was not a single case and among 1700 cases submitted to transsphenoidal resection in the series of Wilson there was just a case²². Several reports of preoperative CSF rhinorrhea in patients with pituitary tumors, however most patients have been irradiated previously, had undergone bromocriptine therapy, did not have histopathologic analysis or the analysis showed another tumor²². There are only 15 well-documented cases of pre-treatment CSF rhinorrhea in patients with pituitary adenomas²² and practically all those cases were described as being rhinorrhea the presenting symptom. Nevertheless, an analysis showed that most cases presented a prior complaint as well as amenorrhea, impotence and visual changes^{3,22}. It probably signifies that rhinorrhea is a rarer situation, when considering it as the presenting symptom of a pituitary adenoma, than previously thought.

The pathogenesis of fistulae generated by surgery are easily understood. The procedure may create a

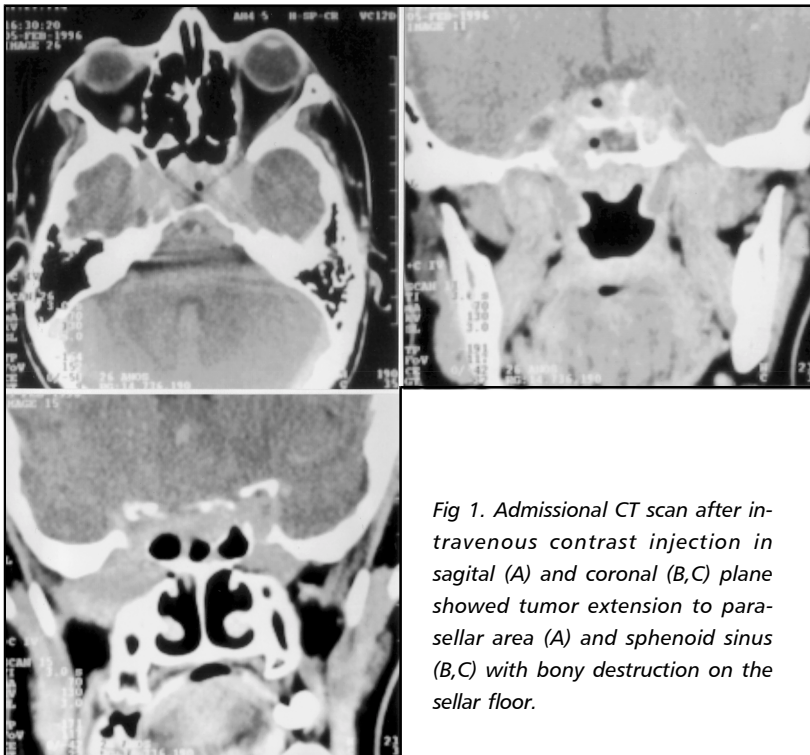


Fig 1. Admission CT scan after intravenous contrast injection in sagittal (A) and coronal (B,C) plane showed tumor extension to parasellar area (A) and sphenoid sinus (B,C) with bony destruction on the sellar floor.

shrinkage itself and rhinorrhea develops^{2,17}. When leakage occurs after a radiation therapy or the use of bromocriptine, fistula is explained by a exposition of a previously established defect in sellar floor due to tumoral contraction^{9,11,24}. The genesis of the CSF rhinorrhea spontaneously prior to treatment is not well understood.

CSF rhinorrhea in our patient appeared to be result of a direct extension of tumor superiorly through diaphragma sella and inferiorly into the sphenoid sinus. Many propositions have been carried out to explain the fistula occurring spontaneously in patients with pituitary adenoma. Most explanations to this phenomenon point out to a direct erosion through the skull base. Fager has suggested that the tumor may function as a "stopper" and after development of necrosis from hemorrhage or infarction, tumor could no longer block flow and CSF rhinorrhea could occur such as the situation after treatment with bromocriptine or radiation therapy¹. On the other hand, there is a study concluding that erosion of the skull floor by pituitary adenomas is not necessarily the mechanism for CSF rhinorrhea, but an alteration in CSF dynamics and pressures. Pituitary tumor would generate intracranial hypertension which would be relived by leakage of CSF through an anatomically fragile area in the base of the skull²².

Our patient developed meningitis complicating the CSF fistula. The history of a previous meningitis may signify a precocious infection due to fistula still not manifested by rhinorrhea or simply an isolated case of meningitis. Only five patients developed meningitis among the 13 reported patients with rhinorrhea and untreated pituitary adenoma²². In contrast to our patient, these cases of meningitis reported occurred in between several months to years after the onset of CSF rhinorrhea^{16, 17, 20, 23}.

In our case the surgery could not be accomplished initially because patient's wishes. After reassurance, patient accepted this procedure. The correction of skull base defect was the cornerstone to treat the CSF fistula. This repair added safety to bromocriptine use, once bromocriptine is a well-known cause of fistula and it must be stopped when fistula occurs secondarily to its use²⁵. The prompt surgical exploration and closure of a skull base defect is imperative in order to have a good result^{3,6,25,26}. We agree

to previous reports stressing that the treatment of choice should be direct surgery to remove tumor, repair dura and make definitive diagnosis^{22,25}.

REFERENCES

1. Fager CA. Nature and treatment of cerebrospinal fluid rhinorrhea in pituitary tumors. *Surg Clin N Am* 1973;53:283-290.
2. Landolt AM. Cerebrospinal fluid rhinorrhea: a complication of therapy of invasive prolactinomas. *Neurosurgery* 1982;11:395-401.
3. Spaziante R, de Divitiis E. Cerebrospinal fluid rhinorrhea in patients with untreated pituitary adenoma: report of two cases (Letter, comment). *Surg Neurol* 1991;36:150-151.
4. Hubbard JL, McDonald TJ, Pearson BW, Laws ER. Spontaneous cerebrospinal fluid rhinorrhea: evolving concepts in diagnosis and surgical management based on Mayo Clinic experience from 1970 through 1981. *Neurosurgery* 1985;16:314-321.
5. Aronoff SL, Daughaday WH, Laws ER. Bromocriptine treatment of prolactinomas (Letter). *N Engl J Med* 1979;300:1391.
6. Barlas O, Bayindir Ç, Hepgül K, et al. Bromocriptine-induced cerebrospinal fluid fistula in patients with macroprolactinomas: report of three cases and a review of the literature. *Surg Neurol* 1994;41:486-489.
7. Baskin SD, Wilson CB. CSF rhinorrhea after bromocriptine for prolactinoma (Letter). *N Engl J Med* 1982;306:178.
8. Fiad TM, McKenna TJ. Meningitis as a late complication of surgically and medically treated pituitary adenoma. *Clin Endocrinol* 1991;35:419-422.
9. Hildebrandt G, Zierski J, Christophis P, et al. Rhinorrhea following dopamine agonist therapy of invasive macroprolactinoma. *Acta Neurochir (Wien)* 1989;96:107-113.
10. Afshar F, Thomas A. Bromocriptine induced cerebrospinal fluid rhinorrhea. *Surg Neurol* 1982;18:61-63.
11. Bronstein MD, Musolino NR, Benabou S, Marino R Jr. Cerebrospinal fluid rhinorrhea occurring in long-term treatment for macroprolactinomas. *Surg Neurol* 1989;32:346-349.
12. Holness RO, Shlossberg AH, Heffernan LPM. Cerebrospinal fluid rhinorrhea caused by bromocriptine therapy of prolactinoma. *Neurology* 1984;34:111-113.
13. Kok JG, Bartelink AKM, Schulte BPM, et al. Cerebrospinal fluid rhinorrhea during treatment with bromocriptine for prolactinoma. *Neurology* 1985;35:1193-1195.
14. Wilson JD, Newcombe RLG, Long FL. Cerebrospinal fluid rhinorrhea during treatment of pituitary tumors with bromocriptine. *Acta Endocrinol* 1983;103:457-460.
15. Bashar K. sellar lesions presenting with cerebrospinal fluid rhinorrhea. *Bull Ophthalmol Soc Egypt* 1975;68:513-514.
16. Bilo HJG, Ponssen H, van der Veen EA, Wolbers JG. Rhinorrhea as the presenting symptom of pituitary adenoma. *Clin Neurol Neurosurg* 1984;86:47-49.
17. Cole IE, Keene M. Cerebrospinal fluid rhinorrhea in pituitary tumors. *J R Soc Med* 1980;73:244-254.
18. Giovanelli M, Perria C. cerebrospinal hinorrhea with pituitary adenoma. *Acta Neurochir (Wien)* 1967;16:261-266.
19. Hudson WR, Hughes LA. Cerebrospinal rhinorrhea. *South Med J* 1975;68:1520-1523.
20. McCallum PHG. Pituitary tumors in the Dunedin Neurosurgical Unit. *NZ Med J* 1960;59:146-150.
21. Nutkiewicz A, DeFeo DR, Kohut RI, Fierstein S. Cerebrospinal fluid rhinorrhea as a presentation of pituitary adenoma. *Neurosurgery* 1980;6:195-197.
22. Obana WG, Hodes JE, Weinstein PR, Wilson CB. Cerebrospinal fluid rhinorrhea in patients with untreated pituitary adenoma: report of two cases. *Surg Neurol* 1990;33:336-340.
23. Rothrock JF, Laguna JF, Raynolds AF. CSF rhinorrhea from untreated pituitary adenoma. *Arch Neurol* 1982;39:442-443.
24. Hildebrandt G. CSF rhinorrhea after dopamine agonist treatment for invasive macroprolactinoma (Letter). *Surg Neurol* 1990;34:133.
25. Eljamel MS, Foy PM, Swift AC, MacFarlane IA. Cerebrospinal fluid rhinorrhea occurring in long-term treatment for macroprolactinomas (Letter, comment). *Surg Neurol* 1992;38:321.
26. Spetzler RF, Wilson CB. Management of recurrent CSF rhinorrhea of the middle and posterior fossa. *J Neurosurg* 1978;49:393-397.