

Acupuncture therapy to the head and face to treat post-trauma paralysis of peripheral fascial nerve dextra

H Mihardja*, PA Meuratana, A Ibrahim

Department of Medical Acupuncture, Faculty of Medicine, Universitas Indonesia, Jakarta, Indonesia

*E-mail: hasanmihardja@gmail.com

Abstract. Damage to the facial nerve due to trauma from traffic accidents is the second most common cause of paralysis of the facial nerve. The treatments include both pharmacological and non-pharmacological therapy. Acupuncture is a method of treatment that applies evidence-based medical principles and uses anatomy, physiology, and pathology to place needles at certain acupuncture points. This paper describes a 26-year-old female patient with right-side facial palsy following a traffic accident who had an improved Brackmann's score after 12 sessions of acupuncture treatment. The acupuncture points were chosen based on Liu Yan's brain-clearing needling technique. Acupuncture can shorten healing time and improve the effect of treatment for facial-nerve paralysis.

1. Introduction

Facial palsy or facial paralysis is a partial or complete loss of motoric function of the facial muscles and is usually caused by lesions in the motor neurons, which can be peripheral (lower motor neuron, under the nuclear or infranuclear nerve cells) or central (upper motor neuron, above the nuclear or supranuclear cells) [1,2]. Unilateral peripheral facial-nerve palsy may be due to known causes (secondary facial-nerve palsy) or unknown causes (primary facial-nerve palsy) or may be idiopathic (Bell's Palsy). The most common causes of secondary facial-nerve paralysis are trauma, systemic viral infection, surgery, diabetes, local infections, tumors, immunological disorders, and medications. Three-quarters of facial-nerve paralysis is due to primary causes, and one-quarter is due to secondary causes [3]. In Dr. Ciptomangunkusumo Hospital, the site of this study, as in Indonesia as a whole, the most common cause is idiopathic followed by inflammation and trauma [4].

The incidence of facial-nerve paralysis is about 20 to 25 cases per 100,000 people per year. In the United States, the incidence is 25/100,000 people per year, and in China it is higher: 258/100,000 people per year. Facial-nerve paralysis can occur in all age groups, but the highest incidence is found in the 20–40 age group. The prevalence of facial paralysis in females and males is about equal, but research has shown that it is slightly higher in females [1,5]. After Bell's Palsy, trauma is the second most frequent cause of facial-nerve paralysis, with an incidence rate of 15%. Odebo and Ologe reported that among 794 cases of head trauma, 40 (5.04%) experienced facial-nerve paralysis, with the most common causes being traffic accidents (85%), falls (7.5%), violence (5.0%), and gunshot wounds (2.5%) [6]. Acupuncture is an effective technique for treating facial paralysis cases, as noted by the World Health Organization (WHO) [7]. Acupuncture is widely practiced in Asian countries, although there has been little research on its use to treat facial paralysis [2].

2. Materials and Methods

A female patient, age 26, was referred from the medical-rehabilitation department at Dr. Ciptomangunkusumo Hospital. The patient had an asymmetrical smile, inability to whistle, and inability to drink through a straw. In addition, for the previous 8 weeks, when the patient drank water from a glass, water would leak from the right corner of her mouth. The patient had begun experiencing these symptoms since awakening from 10 days in a comatose state after a motorcycle accident. The



patient also had a right mandibular fracture that was operated. She had stitches behind the right ear over an incision about 4 cm long. In addition, she had a lag of thalmus of ± 4 mm in the right eye. Examination of cranial nerve VII showed the following: no right forehead wrinkle, the right eyelid didnot close properly, the right side of the nasolabial fold appeared flat, and a House Brackmann score of IV.

Laboratory examination showed a leukocyte count of 21 K/ μ l. Results of X-rays on the same day showed a mandibular fracture dextra, a clavicular fracture dextra, costa fractures I and II dextra, costa fractures V and VI sinistra, and narrowing of the intervertebral discs thoracalis 5 and 6. CT scan showed cerebral edema, a comminuted simplex fracture, mandibular parasymyis dextra, and the presence of blood in the ethmoidal dextra and bilateral sphenoidal sinuses, indicating trauma to the head and facial areas. During hospitalization, the patient was medicated with Proneuron 1 x 1 tablets and Osphit 2 x 1 tablets. In addition, the patient had received physiotherapy 5 times in the medical-rehabilitation clinic.

The patient was diagnosed with paralysis of the facial nerve dextra post-traumata to the peripheral nerve. The patient had ipsilateral dextra facial weakness but no taste disorders, hearing loss, or lacrimation disorders. The lesion probably lay in the infrastapedian, supra khorda [8]. The facialis nerve from the motoric cortex of the gyrus precentral hemisphere cerebri consists of somato-motoric (efferent) fibers that supply the facial muscles, including the buccinator muscle, platysma muscle, digastric muscle, and posterior auricular muscle, and the occipital, stylohyoid, and stapedius muscles [7].

For acupuncture treatment of this case-study patient, points on the head were chosen because there is strong evidence that the function of the cerebral cortex is affected by the zone of therapy in the head. Stimulation of the scalp can regulate functions in the area associated with the cerebral cortex to treat disease. In addition, clinical evidence suggests that acupuncture stimulation of the scalp may regulate cerebral function and increase blood flow to the brain. The function of acupuncture on acupuncture points on the head is to dilate and constrict blood vessels, improve vascular elasticity, and improve motor and sensory functioning [9].

Acupuncture treatment was performed manually on the case-study patient from point GV21 toward point GV20, from point BL4 toward point BL5, from point GB4 toward point GB7, from point GB8 toward point TE20, from point GB9 toward point GB19, and from point GB9 toward point GB19 to assist the dilatation of blood vessels to overcome local edema and improve the motor and sensory functioning of the facial nerve.

The scalp stretches from the top of the forehead down the entire skull and consists of five layers: skin, subcutaneous tissue, galea aponeurotica, subaponeurotica tissue, and pericranium. The skin is the outermost layer of the scalp, containing hair and sebaceous glands and having a significant amount of blood flow. The subcutaneous tissue is also rich in cutaneous blood vessels and nerves. The aponeurotic galea is a structure supported by dense connective tissue and arterial anastomosis of the scalp. The subaponeurotic tissue is the layer in which acupuncture needles are manipulated, meaning that they do not interfere with blood flow or the nerves of the scalp because subaponeurotic tissue lies in the superficial fascia [9].

The patient in this case study was treated with acupuncture at points on the head and face. In the scalp, acupuncture needles were placed subcutaneously at specific zones in the head based on a somatotopic reflex system on the scalp surface that is based on Western medicine. This zone is a specific area in which the functions of the central nervous system and the endocrine system and channels are transported to and from the surface of the scalp. The zone corresponds to the cortical area of the cerebrum and cerebellum responsible for central nervous system functions, including motor activity, sensory input, sight, hearing, speech, and balance [10].

The somatotopic scalp system acts as a miniature transmitter-receiver directly connected to the central nervous system and endocrine system. Reflex stimulation of this area directly affects the cerebral cortex, cerebellum, thalamocortical circuit, thalamus, hypothalamus, and pineal body. The neurological and endocrine compositions of the scalp make it a point from which to externally

stimulate activity inside the brain. Scalp acupuncture treats and prevents disease through corresponding points on the scalp. This is accompanied by special manipulations to regulate and align the functional activity of the brain and body and restore and strengthen the functions of the body, organs, and tissues [10].

Treatment of the case-study patient used the penetrating needling technique on the following head points: from point GV21 toward point GV20, from point BL4 toward point BL5, from point GB4 toward point GB5, from point GB8 toward point TE20, from point GB9 toward point GB19, from point GB6 toward point GB7, from point ST6 toward point ST4, and from point GV26 toward the lesion. Penetrating needling is an acupuncture stimulation technique in which an acupuncture needle is inserted at one acupuncture point with the needle tip leading to another acupuncture point. This technique is easy, safe to manage, and its use requires fewer needles [9]. Each point was chosen based on the brain-clearing needling technique of Liu Yan (Diagrams of Acupuncture, 2003).

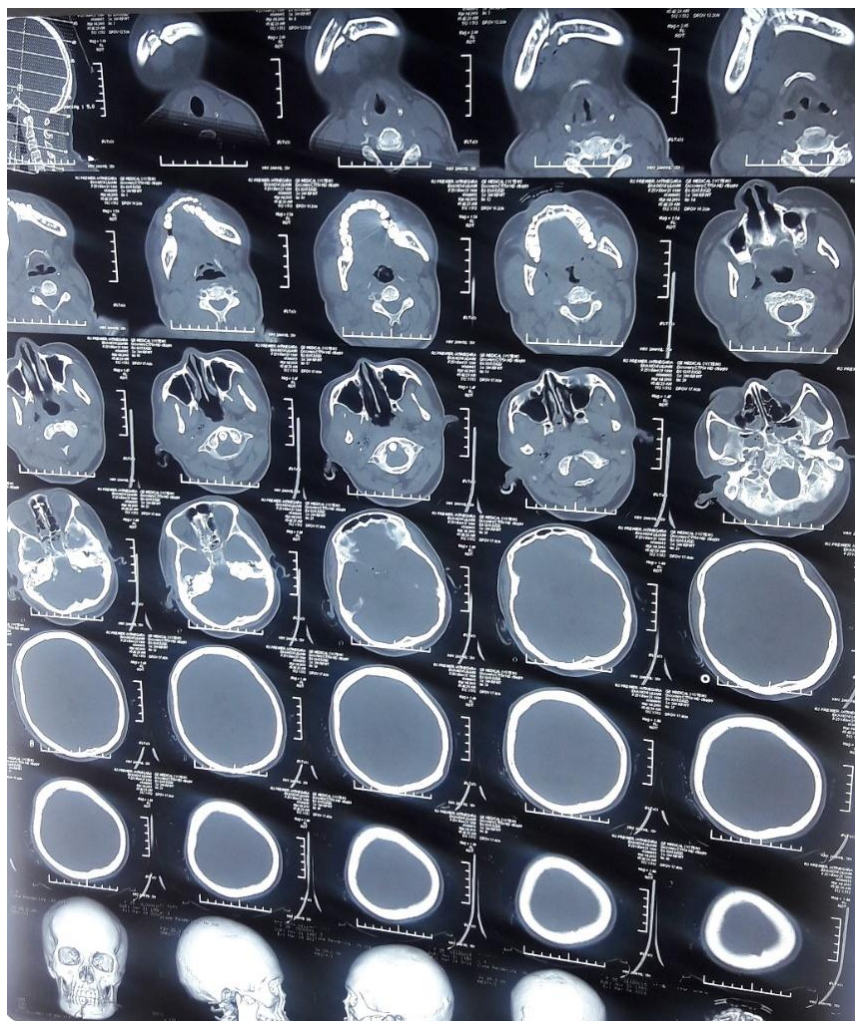


Figure 1. CT scan results showing cerebral edema, a comminuted simplex fracture and dextra mandibular parasymphyseal fracture, and the presence of blood in the ethmoidal, dextra and bilateral sphenoidal sinuses.

Acupuncture at point GV21 toward point GV20 corresponds to line MS5 on the International Standard of Nomenclature for Scalp Acupuncture (ISNSA) for paralysis and numbness. The

innervation of this area originates from the branch of the large occipital nerve of the second cervical and supratrochlear nerve branches originating from the frontal nerve of the ophthalmic nerve [11].

Acupuncture at point GB4 toward point GB7 corresponds to line MS10 on the ISNSA for motor aphasia, facial-nerve disorders, and throat disturbances. Its innervation comes from the temporal branch of the posterior aspect of the auriculotemporal nerve and the deep temporal nerves that branch off into the mandible nerve (V3) of the trigeminal nerve [11].

Acupuncture at point GB8 toward point TE20 is located in the anastomosis branch area of the posterior auriculotemporal nerve of the mandible nerve (V3) and the large occipital nerve of the cervical nerve (C2) of the dorsal primer of the cervical plexus. Its indications are for headache, deafness, tinnitus, and vertigo [11]. This area is located in the gyrus postcentralis of the lymphatic gland, which is the sensory area [9].

Acupuncture at point BL4 toward point BL5 is in the frontal lobe of the frontal gyrus region, which is a motor area that has indications for motor-function impairment, including paralysis, motor dysfunction, Bell's Palsy and seizures [9]. Acupuncture at point GB9 toward point GB19 and at point GB9 toward point GB11 lies above the sphenoid os against the temporal os boundary. This area is in the area of the Yamamoto New Scalp of Acupuncture (YNSA) basic point. Its indications are for treating all post-traumatic or post-operative pain and motor discomfort [9].

On the case-study patient's face, the technique used was manual acupuncture with needles placed at points so as to enable their sensation to be felt at points BL2, ST2, EX-HN4, TE23, and TE17. The sensation is a combination of pain, tingling, fullness, coldness, warmth, and weight around the site of the acupuncture point [12]. Acupuncture points on the facial area work locally on the facial-expression muscles. The BL2 point is located in the muscular orbicularis oculi, which is innervated in the facial nerve branch. The ST2 point is located in the zygomaticus minor musculus, which is supplied by the frontal nerve of the facial nerve. The EX-HN4 point is located in the muscular orbicularis oculi and is supplied by the facial nerve branches of the facial nerve. The GV26 point lies in the orbicularis oris musculus and is supplied by the infraorbital nerve. Based on the anatomy, the TE17 point lies posterior to the auricular lobe in the curvature between the mandibular and mastoid process, wherein lies the facial nerve [13].

3. Results and Discussion

Acupuncture is a method of treatment that applies evidence-based medical principles and uses anatomy, physiology, and pathology to place needles at certain acupuncture points. This paper describes a 26-year-old female patient with right-side facial palsy following a traffic accident who had an improved Brackmann's score after 12 sessions of acupuncture treatment. The acupuncture points were chosen based on Liu Yan's brain-clearing needling technique. Based on the results of this study, acupuncture can shorten healing time and improve the effect of treatment for facial-nerve paralysis. Table 1 shows the results of acupuncture therapy on this study.

Table 1. Results of acupuncture therapy for twice weekly for six weeks

Treatment Number	Complaint	House-Brackmann Score Difference between 2 Sides (mm)
1	Asymmetric smile, unable to whistle or drink through a straw.	IV eyebrows = 7 mm eyes = 3 mm lip = 5 mm
2	Asymmetric smile, unable to whistle or drink through a straw.	IV eyebrows = 7 mm eyes = 3 mm lip = 5 mm

Table 1.*Continued.*Results of acupuncture therapy for twice weekly for six weeks

Treatment Number	Complaint	House-Brackmann Score Difference between 2 Sides (mm)
3	Smile began to become more symmetrical, and there was energy in the right cheek, but the patient was unable to drink through a straw.	III eyebrows = 5 mm eyes = 1 mm lip = 4 mm
4	Face felt lighter. Smile began to become symmetrical, and there was energy in the right cheek, but the patient was unable to drink through a straw.	III eyebrows = 5 mm eyes = 1 mm lip = 4 mm
5	Smile began to become symmetrical, the right cheek could be moved, and the patient could drink through a straw (+) weakly.	III eyebrows = 5 mm eyes = 1 mm lip = 3 mm
6	When closed, the mouth seemed almost normally symmetrical, the right cheek could be moved, and the patient could drink through a straw (+) weakly.	II eyebrows = 5 mm eyes = 1 mm lip = 2 mm
7	Smile was almost symmetrical, the bottom lip began to contract, the right cheek could be moved, and the patient could drink through a straw (+).	II eyebrows = 4 mm eyes = 1 mm lip = 1 mm
8	The smile was almost symmetrical, and the lower lip began to contract.	I eyebrows = 3 mm eyes = 1 mm lip = 1 mm
9	The smile was almost symmetrical, and the lower lip began to contract.	I eyebrows = 3 mm eyes = 1 mm lip = 1 mm
10	The smile was almost symmetrical, and the lower lip began to contract.	I eyebrows = 2 mm eyes = 1 mm lip = 1 mm
11	The smile was asymmetrical, and the lower lip could contract but still looked slightly droopy.	I eyebrows = 1 mm eyes = 1 mm lip = 1 mm
12	The lower lip could contract but still looked slightly droopy.	I eyebrows = 0 mm eyes = 0 mm lip = 1 mm

4. Conclusion

Recovery of function from peripheral-nerve injury is a slow process due to the length of time required to regenerate nerves and reconstruct functions. However, acupuncture can shorten healing time and improve the effect of treating facial-nerve paralysis.

References

- [1] Mayor D F 2007 Electroacupuncture: An introduction and its use for peripheral facial paralysis. *J. Chinese Med.* **841**-19.
- [2] Zhang X, Feng L, Du L, Zhang A and Tang T 2012 Literature study on clinical treatment of facial paralysis in the last 20 years using Web of Science. *NEURAL Regen Res.* **7** 152-9.
- [3] Finsterer J 2008 Management of peripheral facial nerve palsy. *Eur. Arch. Otorhinolaryngol.* **265** 743-52.
- [4] Sjarifuddin, Bashiruddin J and Bramantyo B 2012 Kelumpuhan nervus fasialis perifer in: Soepardi A E Iskandar N *et al.* ed. *Buku Ajar Ilmu Kesehatan Telinga Hidung Tenggorok Kepala dan Leher* 7th ed (Jakarta: Balai Penerbit FK-UI) pp 92-95.
- [5] Tang H, Feng S, Chen J, Yang J, Yang M, Zhong Z, Li Y and Liang F 2014 Effects of electroacupuncture on facial nerve function and hsv-1 DNA quantity in hsv-1 induced facial nerve palsy mice. *Evid. Based Complement Altern. Med.* **2014** 1-7.
- [6] David G 2009 Facial Nerve Trauma. In: Texas
- [7] Zahid S, Bokhari H and Zahid S S 2010 Acupuncture treatment of facial palsy. *J. Ayub. Med. Coll. Abbottabad.* **22** 70-3.
- [8] Puvanendran K, Vitharana M and Wong P K 1977 Delayed facial palsy after head injury *J. Neurol. Neurosurg. Psychiatr.* **40** 342-50.
- [9] Yajuan W 2009 Microacupuncture in practice (St.Louis: Elsevier Inc)
- [10] Hao J J, States U, Hao L L and States U 2012 Review of clinical applications of scalp acupuncture for paralysis: An excerpt from chinese scalp acupuncture. *Glob. Adv. Health Med.* **1** 102-121.
- [11] Suh S C 2016 Acupuncture Anatomy (New York: CRC).
- [12] Xu S B, Huang B, Zhang C Y, Du P, Yuan Q, Bi G J, Zhang G B, Xie M J, Luo X, Huang G Y, Wang W 2013 Effectiveness of strengthened stimulation during acupuncture for the treatment of bell palsy: A randomized controlled trial. *Can. Med. Assoc. J.* **185**473-9.
- [13] World Health Organization 2008 WHO Standard Acupuncture Point Locations in the Western Pacific Region.