

# Assessing symmetry using the mirror stand device with manual and software-assisted methods in postoperative zygomatic fracture patients

A N Syarif and K Bangun\*

Division of Plastic Surgery, Department of Surgery, Faculty of Medicine, Universitas Indonesia, Jakarta, Indonesia

\*E-mail: kristaninta@yahoo.com

**Abstract.** Zygomatic fractures are among the most common fractures to the facial skeleton. However, because no standard and reliable method of evaluation is available to assess postoperative patients, we often rely on photographs and subjective assessments. A portable mirror stand device (MiRS), which is a new method for the standardization of photography, was developed in our institution. Used with image analysis software, this device provides a new method for evaluating outcomes after the open reduction and internal fixation of zygomatic fractures. The portable mirror stand device was set up in our outpatient clinic at the Cleft Craniofacial Center at Cipto Mangunkusumo Hospital. Photographs of 11 postoperative patients were taken using the device, and they were analyzed both manually and using image analysis software (ImageJ 1.46) for symmetry. The two methods were then compared to assess the correlation and agreement of the results. The measurements taken using the manual method and the software-assisted method did not differ significantly, which indicated the good agreement between the two methods. The results of the symmetry achieved at our center were similar to other centers in the Asian region ( $\Delta Z_y = 3.4 \pm 1.5$  mm,  $\Delta B_c = 2.6 \pm 1.6$  mm,  $\Delta C_h = 2.3 \pm 2.4$  mm) compared with ( $\Delta Z_y = 3.2 \pm 1.7$  mm,  $\Delta B_c = 2.6 \pm 1.6$  mm,  $\Delta C_h = 2.3 \pm 2.5$  mm). The treatment of zygomatic fracture at our center achieved good results. The portable mirror stand device assisted the image analysis software (ImageJ 1.46), which could be beneficial in assessing symmetry in postoperative zygomatic fracture patients.

## 1. Introduction

In the facial skeleton, the zygomatic bone has an important and prominent position. It provides most of the projection of the midface. It is often referred to as the “cheek bone,” which implies the importance of the zygoma in forming the shape of the cheeks, which are noticeable features of a human face [1]. Fractures of the zygoma are one of the most common maxillofacial fractures, and they are commonly caused by motor vehicle accidents, falls, or other violent incidents. They are second only to nasal fractures as the most common midface fractures. Zygomatic fractures can happen in isolation or with other facial fractures. The prevalence of these fractures is the highest in the age group from 21–30 years, and the distribution of males to females is 7:1 [2]. The success of intervention is often expressed as functional outcomes, such as occlusion and visual function [1,3]. However, previous studies have neglected the aesthetic appearance of the face, which is also an important outcome.



Development of a device to help acquire accurate and measurable photographs of the face by harnessing the principles of mirror reflection to produce reliable images from different angles in one photograph was conducted. This device is called the portable mirror stand (MiRS). It has been proved to produce good results in normal adult subjects [4]. It has the potential to be used in evaluations of our patients, particularly if symmetry is a concern, such as in zygomatic fractures. To the best of our knowledge, no previous study has assessed the results of zygomatic fracture surgery at our institution. Moreover, in clinical results, symmetry has not been assessed. The literature indicates that a difference in bone alignment and anthropometric measurement of less than 2 mm is considered symmetrical and an indication that further surgical intervention is not required [5,6]. In the original study, measurements of the photographs taken with the MiRS were done with a ruler that was included as a standard [4]. The process can be simpler and faster with the help of image analysis software because it can be calibrated to the ruler and any subsequent measurements of distance or angles can be made easily. This method has the potential to increase the practicality of using the MiRS. With the aid of the software, it is conceivable that accurate measurements of the facial region, particularly for the evaluation of symmetry, can be achieved more rapidly in combination with the newly developed MiRS.

## 2. Materials and Methods

This cross-sectional study focuses on patients with zygomatic fracture patients due to trauma, who underwent surgery in the Cleft Craniofacial Center at Cipto Mangunkusumo Hospital from January 2014 to March 2016. Patients' photographs were taken with aid of the MiRS device. The facial images were analyzed for the symmetry of the zygoma in the anteroposterior and basal projections. The measurements of distance were taken from the photographs using the same method as in the original MiRS study in addition to the ImageJ software. The measurement results were compared using three statistical calculations: correlation, comparison of means, and the Bland-Altman plot. The statistical software used was SPSS 20.0 (SPSS Inc., Chicago IL, USA). The tests included Pearson's and Spearman's correlation tests, a paired t-test, and the Wilcoxon test for the difference in two means. A linear regression was performed to analyze the Bland-Altman plot.

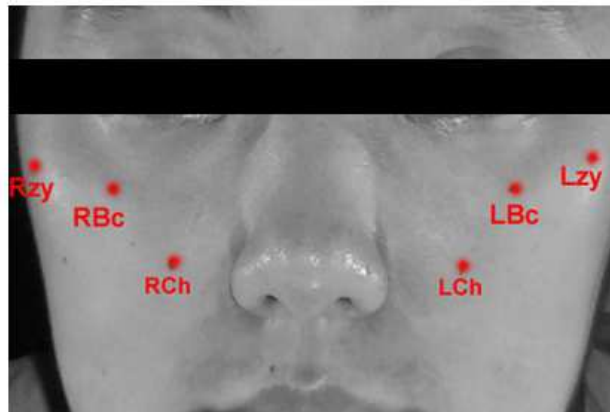
## 3. Results and Discussion

### 3.1 Results

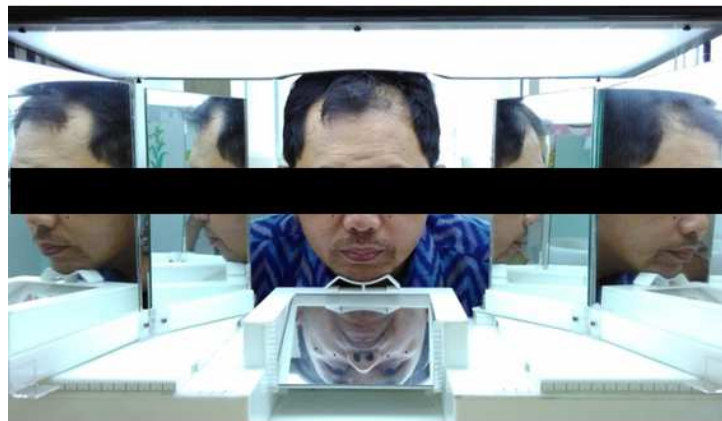Eleven patients participated in this study. The patients' faces were marked in six anatomic landmarks as described by Kim (2014) [5], and photographs were taken using the MiRS device according to the method described by Supit and Prasetyono (2015) [4]. Measurements were taken manually using digital calipers and the software-assisted method using ImageJ 1.46.

**Table 1.** Subjects' demographic information

No	Age (yr)	Sex (m/f)	Type of Fracture	Type of Fixation	Follow-up period (months)	Patients Concerns
1	38	m	Tetrapod left zygoma	plate+ screw 3 point	3	none
2	28	f	Tetrapod left zygoma, left mandibular corpus	plate+ screw 3 point	6	discomfort on plate location
3	27	f	Right zygomatico maxilla and inferior orbital rim	plate+ screw 2 point	6	none
4	35	m	Tetrapod left zygoma	plate+ screw 3 point	3	none
5	55	f	Tetrapod right zygoma	plate+ screw 3 point	8	none
6	19	f	Tetrapod left zygoma	plate+ screw 3 point	4	none
7	44	m	Tetrapod right zygoma	plate+ screw 3 point	6	none
8	19	m	Left corpus and zygomatic arch	plate+ screw 1 long plate	12	none
9	16	f	Tetrapod left zygoma	plate+ screw 3 point	14	none
10	40	m	Tetrapod left zygoma	plate+ screw 3 point	3	ectropion
11	47	f	Tetrapod right zygoma	plate+ screw 3 point	13	none



**Figure 1.** Soft tissue landmarks marked on facial soft tissue using the method described by Kim (2014): zygion' (Zy'), buccale (Bc), point of cheek (Ch), (R: right, L: left) [5]



**Figure 2.** Example of photographs taken with the MiRS device and the landmarks marked using a surgical marker

**Table 2.** Definitions of soft tissue landmarks [5]

Landmarks	Definitions
<i>Zygion' (Zy')</i>	The most lateral point where the zygomatic arch is the widest on the external surface
<i>Buccale (Bc)</i>	The point on the external surface of each zygomatic arch where the arch turns medially and then immediately sweeps backward
<i>Point of cheek (Ch)</i>	The most anterior point of the cheek

Pearson's correlation coefficient was used to measure the asymmetry of Zy points and Bc points. The results were 0.63 and 0.9, with p values of 0.041 and 0.00 respectively. Spearman's test was used to measure the Ch points, which yielded a correlation coefficient of 0.72 and a p value of 0.012. The correlation tests revealed significant moderate to strong correlations between the manual method and the software method.

**Table 3.** Correlations of the two methods

Measurement points	Correlation tests	Coefficient	p-value
Zy	Pearson	0.63	0.041
Bc	Pearson	0.90	0.000
Ch	Spearman	0.72	0.012

Paired t-tests were employed to the measurements of points Zy and Bc. The resulting p values were 0.556 and 0.808, respectively. The Ch point measurements were tested with the Wilcoxon signed ranks test, which yielded a p value of 0.959. The test results showed no significant differences in the results of the two methods used.

**Table 4.** Comparison of two means

Measurement (mm)	Manual		ImageJ		Difference of Means	p-value
	Mean	SD	Mean	SD		
Zy	3.4	1.5	3.2	1.7	0.25±0.42	0.556
Bc	2.6	1.6	2.6	1.6	0.54±0.72	0.808
Ch	2.3	2.4	2.3	2.5	0.12±0.25	0.959

Bland and Altman suggested that agreement between two methods of measurement could be determined accurately by using a scatter plot of the differences in measurements and the mean of two measurements results. The resulting numbers then are analyzed by linear regression [7]. The results of the Zy, Bc, and Ch measuring methods were as follows:  $\beta$  coefficient -0.158, -0.042, and 0.199 with significance values of 0.642, 0.902, and 0.558, respectively. These results reflect that no significant systematic bias was found, and the two methods are likely to have good agreement.

**Table 5.** Analysis of difference and mean of measurements

Measurement points	Mean difference	$\beta$ -Coefficient	p-value
Zy	0.254	-0.158	0.642
Bc	0.054	-0.042	0.902
Ch	0.009	-0.199	0.558

### 3.2 Discussion

We compared the manual and the software-assisted methods of measuring symmetry in the images acquired using the MiRS. This method of investigation is not ideal because it should be compared to Cone Beam CT, which was the original method used with the designated points of measurement in this study. The device was not yet available in our country, so we were only able to compare our results with the published data. In our study, the manual and software-assisted methods were well correlated, and no significant differences were found in the correlations or in the results of the two means statistical tests. According to Bland and Altman, correlations and the comparison of two means are not effective [7]. Therefore, we used a scatter plot and analysis as they suggested, the results of which showed that the two methods were in good agreement, and no systematic bias was found. In our study, the asymmetry in postoperative patients was more than 2 mm, which was greater than in the normal patients described by Hwang (2012) [8] and Kim (2014) [5]. However, the results of our measurements of postoperative patients were strikingly similar to those of the postoperative patients reported by Kim (2014): manual results ( $\Delta Zy = 3.4 \pm 1.5$  mm,  $\Delta Bc = 2.6 \pm 1.6$  mm,  $\Delta Ch = 2.3 \pm 2.4$  mm); software-assisted results ( $\Delta Zy = 3.2 \pm 1.7$  mm,  $\Delta Bc = 2.6 \pm 1.6$  mm,  $\Delta Ch = 2.3 \pm 2.5$  mm); the results of the Korean study (Zy:  $3.05 \pm 1.32$  mm, Bc:  $2.36 \pm 1.60$  mm, Ch:  $2.92 \pm 1.97$  mm) [5].

We think that these results showed that not only did our method of treatment yield clinical results that were similar to those of our Korean counterpart but also the method of examination using our standardized photography was comparable to Cone beam computed tomography (CBCT) in measuring asymmetry. Despite the measurement results, none of our patients complained of facial asymmetry. The reason might be that most of our patients had little education, and they were untrained to identify facial details. Previous reported that even experience clinicians have difficulty perceiving a difference of less than 2 mm [9]. We believe that our patients were simply unable to perceive the difference, which indicated that the results were acceptable. However, to confirm our findings, further studies should be conducted with a larger number of patients and more advanced tools such as CBCT.

However, until further results are available, we think that the use of our methods in the evaluation of postoperative patients would yield valuable results.

#### 4. Conclusion

The ImageJ software showed good agreement with the manual method used to acquire the MiRS images. The MiRS was proved a reliable and practical tool in measuring postoperative zygomatic symmetry. The open reduction and internal fixation of zygomatic fractures in our institution did not achieve the same values in the normal population. However, our results were comparable to those found in other treatment centers. The results of the present study indicate that the MiRS device combined with the ImageJ software is a reliable and practical method for evaluating the asymmetry of the face. It should be applied to evaluate patients with facial fracture both preoperatively and postoperatively because it would provide better input for surgical planning and evaluation. A further study using a larger number of patients and tools that are more advanced would be invaluable to establishing this method as a standard operating procedure.

#### References

- [1] Kale P T, Balani A, Kotrashetty S M and Baliga S D 2010 Intraoperative use of C-Arm as an aid in reduction of zygomatic complex fractures. *World. J. Dent.* **1** 13-6.
- [2] Holmes S 2011 Reoperative orbital trauma: management of posttraumatic enophthalmos and aberrant eye position. *Oral. Maxillofac. Surg. Clin. North. Am.* **23** 17-29.
- [3] Hasse P N, Gealh W C, Pereira C C, Coradazzi L F, Magro Filho O and Rangel Garcia I. Jr. 2011 Clinical and radiographic evaluation of surgical treatment of zygomatic fractures using 1.5 mm miniplates system. *Open. J. Stomatol.* **1** 172-8.
- [4] Supit L and Prasetyono T 2015 A portable mirror stand for clinical facial photo documentation. *Arch. Plast. Surg.* **42** 356-60.
- [5] Kim D H, Kim R H, Lee J, Chee Y D and Kwon K H 2014 Evaluation of soft tissue asymmetry using cone-beam computed tomography after open reduction and internal fixation of zygomaticomaxillary complex fracture. *J. Korean. Assoc. Oral. Maxillofac. Surg.* **40** 103-10.
- [6] Sonone R M, Kumar S, Kukreja P, Agarwal A, Bhatnagar A and Chhabra V 2015 Computed tomography scan evaluation of adequacy for reduction of zygomatic arch fracture using Gillie's temporal approach. *J. Dent. Specialities.* **3** 156-8.
- [7] Bland J M and Altman D G 2010 Statistical methods for assessing agreement between two methods of clinical measurement. *Int. J. Nurs. Stud.* **47** 931-6.
- [8] Hwang H S, Yuan D, Jeong K H, Uhm G S, Cho J H and Yoon S J 2012 Three-dimensional soft tissue analysis for the evaluation of facial asymmetry in normal occlusion individuals. *Korean J. Orthod.* **42** 56-63.
- [9] Ellis E 3rd, el-Attar A and Moos K F 1985 An analysis of 2,067 cases of zygomatico-orbital fracture. *J. Oral. Maxillofac. Surg.* **43** 417-28.