Three-dimensional image reconstruction of macula from stratus optical coherence tomography (OCT) for diagnosis of macular degeneration

Arinilhaq[1] **and R Widita**[1]

[1] Department of Physics, Faculty of Mathematics and Natural Sciences, Institut Teknologi Bandung, Jalan Ganesa 10, Bandung 40132, Jawa Barat, Indonesia

E-mail: arinilhaqueen@gmail.com

Abstract. Diagnosis of macular degeneration using a Stratus OCT with a fast macular thickness map (FMTM) method produced six B-scan images of macula from different angles. The images were converted into a retinal thickness chart to be evaluated by normal distribution percentile of data so that it can be classified as normal thickness of macula or as experiencing abnormality (e.g. thickening and thinning). Unfortunately, the diagnostic images only represent the retinal thickness in several areas of the macular region. Thus, this study is aims to obtain the entire retinal thickness in the macula area from Status OCT's output images. Basically, the volumetric image is obtained by combining each of the six images. Reconstruction consists of a series of processes such as pre-processing, segmentation, and interpolation. Linear interpolation techniques are used to fill the empty pixels in reconstruction matrix. Based on the results, this method is able to provide retinal thickness maps on the macula surface and the macula 3D image. Retinal thickness map can display the macula area which experienced abnormalities. The macula 3D image can show the layers of tissue in the macula that is abnormal. The system built cannot replace ophthalmologist in decision making in term of diagnosis.

1. Introduction

Macular degeneration is a deterioration or breakdown of the eye's macula. The macula is a small area in the retina, the light sensitive tissue lining at the back of the eye. The macula is the part of the retina that is responsible for your central vision, allowing you to see fine details clearly. There are two types of macular degeneration: (1) dry macular degeneration with drusen; this condition is caused by aging and thinning of the tissues of the macula, and (2) wet macular degeneration, which occurs when abnormal blood vessels begin to grow underneath the retina, characterized by thickening of the retina.

Diagnosis of macular degeneration using a Stratus OCT with a fast macular thickness map (FMTM) method produced 6 macular cross-section images from different angles [1]. The images were converted into a retinal thickness chart to be evaluated using normal distribution percentile of data so that it can be classified as normal thickness of the macula or as experiencing abnormality (e.g. thickening and thinning). Unfortunately, the diagnostic images only represent the retinal thickness in several areas of the macular region, namely the area of data acquisition at a certain angle. Due to the limitated the data obtained were not able to provide data on the overall macular thickness deviation, and therefore, the proposed methods to reconstruct the 6 OCT output images into a 3D image. The aim of this study is to obtain the entire retinal thickness in the macula area from Status OCT's output images.

Content from this work may be used under the terms of the Creative Commons Attribution 3.0 licence. Any further distribution of this work must maintain attribution to the author(s) and the title of the work, journal citation and DOI.
Published under licence by IOP Publishing Ltd

2. Method

This study uses a three-dimensional reconstruction method to obtain the image of the entire area of the macula (volumetric image). Input image that is used in the form of 6 macular cross-section images and 6 retinal thickness charts is obtained from 3 random samples. Basically the volumetric image is obtained by combining each of the six images to obtain three-dimensional images by using software MATLAB 2013a.

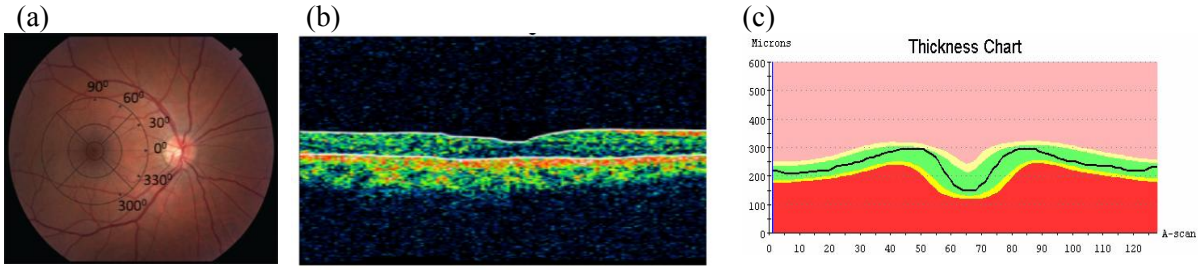

Figure 1. Left to right: (a) Data collection schemes of macular cross section images; (b) Macular cross section image; (c) Retinal thickness chart.

The reconstruction consists of a series of processes such as preprocessing, segmentation, and interpolation as described in flowchart below.

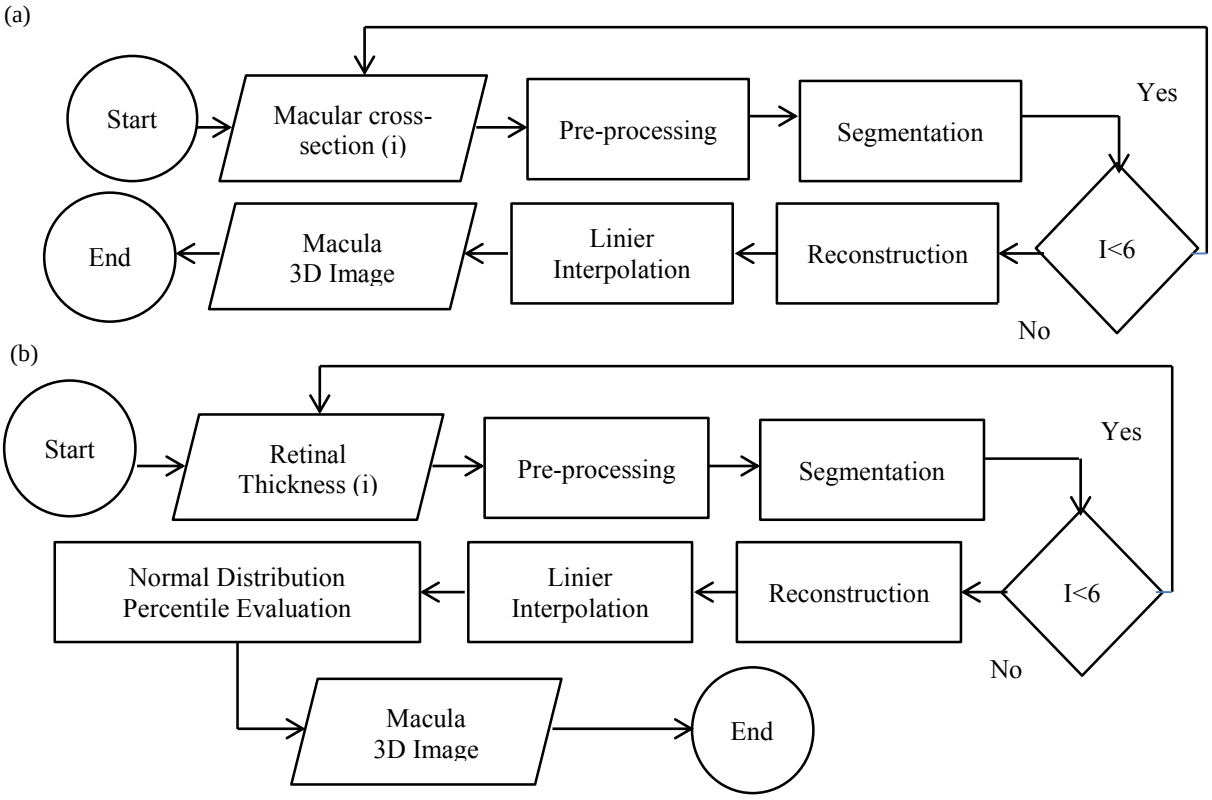

Figure 2. (a) Flowchart of macular cross-section processing; (b) Flowchart of retinal thickness processing.

2.1. Macular cross-section processing

Some The FMTM scan protocol was used for data acquisition. The protocol consists of 6 linear scans in a spoke pattern separated by 30° intervals centered at the fovea [1]. The line scans were 6 mm in the transverse direction, had a 2-mm axial depth, and was composed of 512 axial scans each [2-5]. In this

case, linear interpolation techniques are used to fill the empty pixels (no value) in the three-dimensional matrix through MATLAB 2013a software using the following equation:

$$Z(r,\theta_1) = \frac{\sin\theta_1}{\sin 30}\, Z(r,0) + \frac{\sin(30-\theta_1)}{\sin 30}\, Z(r,30) \tag{1}$$

where Z (r, θ) is the pixels value, 30 is interval of current data in degree, (r, θ_1) is pixel coordinate.

2.2. Retinal thickness processing

Stratus OCT can change the macular cross-section image into retinal thickness chart. Then, this data is extracted to obtain the thickness value of retina at each angle. Finally, the data from previous process are then reconstructed by linear interpolation in equation (1), resulting surface topography image of the macula. Reconstructed images were evaluated by a healthy macula normative data percentile to provide visualization of macular abnormalities.

3. Result and discussion

This study has two forms of results: (1) retinal thickness map on the surface of the macula, (2) macula 3D image. Retinal thickness map that were evaluated by the normal data distributions can display the macula area which has abnormalities such as thickening or thinning of the macula. The macula 3D image can show the layers of tissue in the macula based on the increase in thickness. The high refraction index tissue is represented by bright colors.

Table 1. Macula 3D images and retinal thickness map on the surface of the macula as result of macular cross-section image and retinal thickness processing.

No	Three-dimension Image	
	Macular cross-section image processing	**Retinal Thickness Processing**
1.	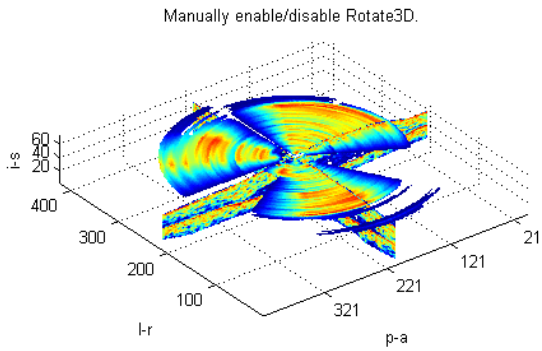	 Thickening = 19.61 × 10^{-2} Thinning = 32.902 × 10^{-7}

2

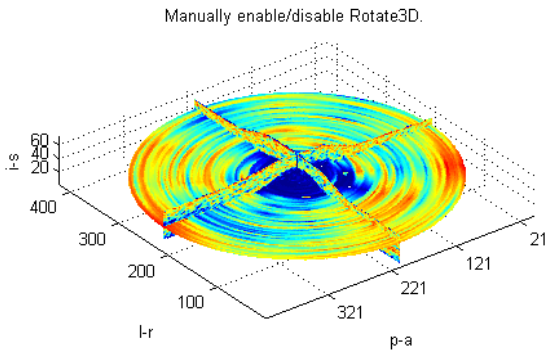

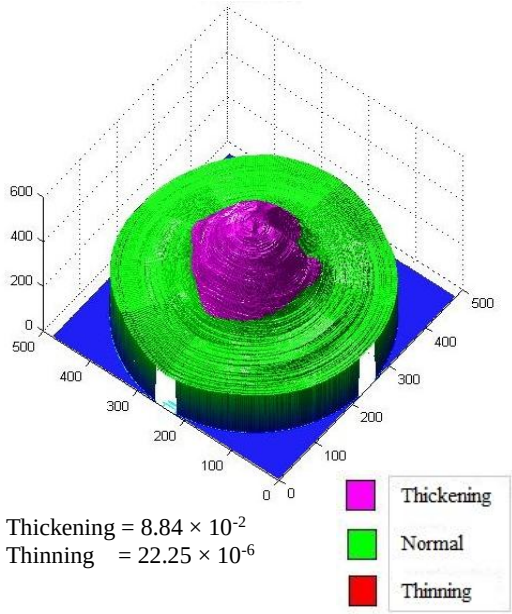

Thickening = 8.84×10^{-2}
Thinning = 22.25×10^{-6}

3

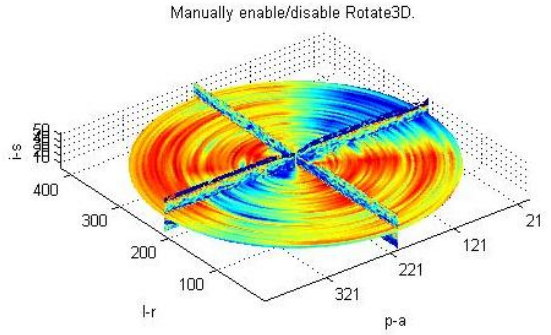

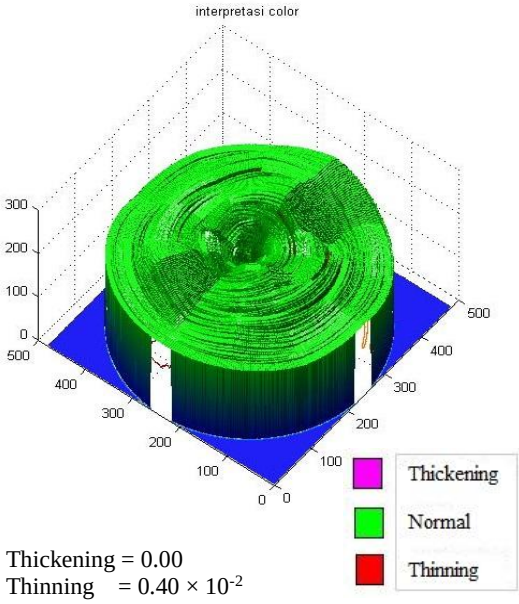

Thickening = 0.00
Thinning = 0.40×10^{-2}

Based on table 1, retinal thickness processing may provide an illustration of retinal thickness map of the macula surface. Then, macula normal distribution data contained in the Stratus OCT system was used to evaluate the retinal thickness map. Thus, the researchers can calculate the percentage of the thickening and thinning of the macula that have occurred in the sample per unit volume. The result of macular cross-section image processing can provide illustration layers of the macula. A high reflective tissue, such as the RNFL, appears green and yellow, whereas a less reflective tissue has darker colors such as blue [2].

4. Conclusion

The reconstruction method with linier interpolation is able to provide retinal thickness map on the surface of the macula and the macula 3D image. Retinal thickness map that were evaluated by the normal data distributions can display the macula area which is have abnormalities such as thickening or thinning of the macula. The macula 3D image can show the layers of tissue in an abnormal macula. However, the system built can't replace ophthalmologist and doctors in the decision making diagnosis.

References

[1] Peter M B *et al*. 2009 *The official journal of the international society for imaging in the eye* **40(1)** 25-31
[2] Gianmarco V *et al*. 2011 *Indian Journal of Ophthalmology* **59** 59-68
[3] Mark E B 2006 *Optical Coherence Tomography: Principles and Applications* (Boston, MA: Massachusetts Institute of Technology)
[4] James G F *et al*. 2000 *Neoplasia* **2** 9-25
[5] Michelle L G *et al*. 2011 *Investigative Ophthalmology & Visual Science* **52(5)**

Acknowledgments

The authors want to thank the other members of the biomedical imaging group Choirul Anam who indirectly supported the project as well as Erwin Iskandar from Department of Retina, Cicendo Eye Hospital, Bandung, Indonesia for supporting data rendering.