

## Diabetic peripheral neuropathy assessment through texture based analysis of corneal nerve images

Susana F. Silva<sup>1</sup>, Sofia Gouveia<sup>2</sup>, Leonor Gomes<sup>2</sup>, Luís Negrão<sup>3</sup>, Maria João Quadrado<sup>1,4</sup>, José Paulo Domingues<sup>1,5</sup> and António Miguel Morgado<sup>1,5</sup>

<sup>1</sup>IBILI - Institute for Biomedical Imaging and Life Sciences, Faculty of Medicine, University of Coimbra, Coimbra, Portugal

<sup>2</sup>Department of Endocrinology, Diabetes and Metabolism, Coimbra Hospital University Center, Coimbra, Portugal

<sup>3</sup>Department of Neurology, Coimbra Hospital University Center, Coimbra, Portugal

<sup>4</sup>Department of Ophthalmology, Coimbra Hospital University Center, Coimbra, Portugal

<sup>5</sup>Department of Physics, Faculty of Sciences and Technology, University of Coimbra, Coimbra, Portugal

Email: Susana.fig.silva@gmail.com

**Abstract.** Diabetic peripheral neuropathy (DPN) is one common complication of diabetes. Early diagnosis of DPN often fails due to the non-availability of a simple, reliable, non-invasive method. Several published studies show that corneal confocal microscopy (CCM) can identify small nerve fibre damage and quantify the severity of DPN, using nerve morphometric parameters. Here, we used image texture features, extracted from corneal sub-basal nerve plexus images, obtained *in vivo* by CCM, to identify DPN patients, using classification techniques. A SVM classifier using image texture features was used to identify (DPN vs. No DPN) DPN patients. The accuracies were 80.6%, when excluding diabetic patients without neuropathy, and 73.5%, when including diabetic patients without diabetic neuropathy jointly with healthy controls. The results suggest that texture analysis might be used as a complementing technique for DPN diagnosis, without requiring nerve segmentation in CCM images. The results also suggest that this technique has enough sensitivity to detect early disorders in the corneal nerves of diabetic patients.

### 1. Introduction

The use of morphologic information extracted from corneal confocal microscopy images of the sub-basal nerve plexus has been proposed for diagnosing and staging diabetic peripheral neuropathy (DPN) [1-3]. This research effort is well justified. DPN is one of the more common complications of diabetes, being the main cause of chronic disability in diabetic patients. It is present in about 8% of newly diagnosed patients, affecting up to 50% of the patients after 25 years of disease and is associated to 50-75% of non-traumatic amputations [4, 5]. Early diagnosis, which is very important to define higher risk patients, often fails or occurs only when patients became symptomatic due to the non-availability of a simple, reliable, non-invasive method [6]. The standard methods for DPN diagnosis, which are based on the evaluation of neuropathic symptoms and signs and on



electrophysiology measurements, are not adequate for detecting the early changes occurring in small nerve fibres. These can be detected measuring the intra-epidermal nerve fibre density through skin biopsy [7-9]. However this is an invasive, complex procedure. Corneal confocal microscopy (CCM) [10, 11] offers the possibility of inspecting *in vivo* small nerve fibres by non-invasive optical methods, using instrumentation already available at the ophthalmology departments of central hospitals.

It was already shown that diabetic patients have lower nerve density [12], even for short diabetes duration [13, 14], that CCM can accurately report the extent of corneal nerve damage and repair using fibre density and branching measurements [1], and that nerve tortuosity correlates with neuropathy severity. It was also demonstrated that corneal nerve fibre loss correlates with intra-epidermal nerve fibre loss [2], with the parameter corneal nerve fibre length showing higher discriminative capacity to diagnose DPN [15]. Recent works focus on the development of accurate methods for automatic segmentation and analysis of corneal nerves on CCM images [16-21] and on the reproducibility of CCM in the evaluation of corneal nerves morphology, using manual, semi-automated and automatic methods [22-24]. A review on this research area was recently published [25].

Here we present results of a pilot study designed to evaluate the use of texture analysis of corneal nerve images obtained with corneal confocal microscopy for DPN detection. Texture based analysis used image statistics obtained from the Gray Level Co-occurrence Matrix (GLCM) and from the Gray Level Run Length Matrix (GLRLM).

## 2. Methods

### 2.1. Study design

The study included 12 diabetic patients (type 2, insulin-treated, with mean age of  $58 \pm 10$  years), followed at the Department of Endocrinology, Diabetes and Metabolism of Coimbra Hospital University Center (CHUC), and 8 age-matched non-diabetic control individuals (mean age:  $54 \pm 7$  years).

The study was conducted according to guidelines of the Declaration of Helsinki and submitted to approval by the Medical Ethics Committee of the Faculty of Medicine of the University of Coimbra. Informed consent was obtained from all participants after explanation of the nature and possible consequences of the study. Clinical examinations followed the international consensus guidelines for diagnosis and management of DPN [26] and the Michigan Neuropathy Screening Instrument (MNSI) [27], comprising two separate assessments: a 15-item questionnaire and a lower extremity examination, that includes feet appearance evaluation, ankle reflex testing and sensory deficit evaluation (superficial pain, touch perception and vibrating sensation). Physical examination and questionnaire evaluation was done by medical doctors, in a random order, without information of other test results. The patients' clinical history was verified to ensure that peripheral neuropathy is a consequence only of diabetes.

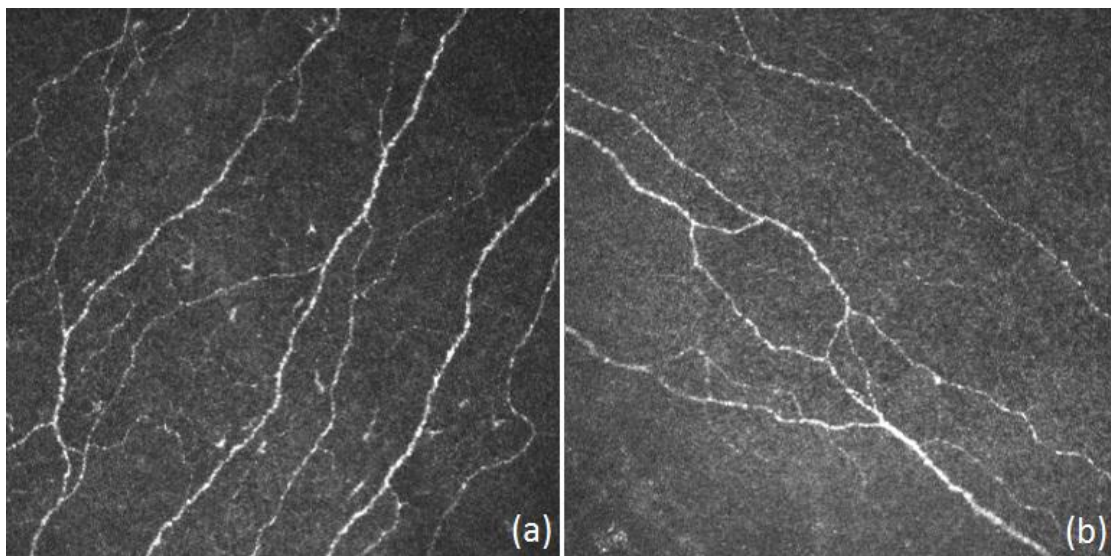
All individuals underwent electromyography (EMG) at the Department of Neurology of CHUC, using a Nicolet Biomedical EA4 (Nicolet Biomedical, Madison, WI, USA) recording device. EMG measurements comprised nerve conduction evaluation, motor (peroneal) and sensory (sural) nerve conduction velocity (NCV) and amplitudes, as well as cutaneous sympathetic response.

CCM images were obtained at the Department of Ophthalmology of CHUC, using a Heidelberg Retinal Tomograph equipped with a Cornea Rostock Module (Heidelberg Engineering, Heidelberg, Germany). The  $384 \times 384$  pixels images correspond to a  $400 \mu\text{m} \times 400 \mu\text{m}$  area and were saved in JPEG format. All individuals underwent bilateral examination by an ophthalmologist. We recorded 275 nerve images from healthy individuals and 356 images from diabetic patients. Image samples are shown in Figure 1.

## 2.2. DPN evaluation based on image texture features

Images were used as acquired, without any pre-processing. Textural analysis was based on first-order image statistics (variance), second-order statistics based on the Gray Level Co-occurrence Matrix (GLCM) [24] and higher order statistics, based on the Gray Level Run Length Matrix (GLRLM) [28, 29]. The second-order features extracted were energy, entropy, correlation, homogeneity, dissimilarity, cluster shade and cluster prominence. The correlation, energy and homogeneity parameters were obtained for orientations of 0, 45, 90 and 135°. The higher-order features extracted were Short Run Emphasis (SRE), Long Run Emphasis (LRE), Gray-Level Non-uniformity (GLN), Run Length Non-Uniformity (RLN), Run Percentage (RP), Low Gray-Level Run Emphasis (LGRE), High Gray-Level Run Emphasis (HGRE), Short Run Low Gray-Level Emphasis (SRLGE), Short Run High Gray-Level Emphasis (SRHGE), Long Run Low Gray-Level Emphasis (LRLGE) and Long Run High Gray-Level Emphasis (LRHGE). These higher-order features were also calculated for orientations of 0, 45, 90 and 135°. The total number of features extracted from each image was 61. All features were extracted using a Matlab program written for that purpose.

A support vector machine (SVM) system was used for supervised classification of each image in the DPN and No DPN groups and to classify each image of the No DPN group as Mild or Moderate DPN. Training and classification was done using the Weka Data Mining software [30] and Weka LibSVM [31], using the radial basis function kernel. The best features were automatically selected according to a rank given by the square of the weight assigned by a SVM classifier and then transformed by Principal Component Analysis (PCA), performed in the feature space. The SVM classification performance was assessed using both 10-fold cross-validation and leave-one-out validation.



**Figure 1.** Images of corneal sub-basal nerve plexus obtained by corneal confocal microscopy: (a) healthy cornea; (b) diabetic cornea

## 3. Results

### 3.1. Evaluation of study participants

According to their baseline evaluation, the diabetic patients were divided in three groups: absent (4 patients, 53±11 years), mild (5 patients, 58±9 years) and moderate DPN (3 patients, 60±9 years). No patient presented severe DPN. Table 1 summarizes the data of the study participants while Table 2 contains the results of EMG measurements.

**Table 1.** Summary of the four participants groups (baseline evaluation).

Group (DPN Severity)	Mean Age $\pm$ Std.Dev. (years)	MNSI Quest. (0-15)	MNSI Scoring (0-10)	EMG diagnosis
Control	54 $\pm$ 7	0	0	Normal
Absent	53 $\pm$ 11	0 - 3	0 - 1	Normal
Mild	58 $\pm$ 9	4 - 6	2 - 3.5	DPN/Normal
Moderate	60 $\pm$ 9	6 - 8	2 - 3	DPN

**Table 2.** Nerve conduction studies results (mean  $\pm$  std. dev.).

Groups	Motor nerve		Sensory nerve		Cutaneous Sympathetic response (s)
	NCV (m/s)	Amplitude ( $\mu$ V)	NCV (m/s)	Amplitude ( $\mu$ V)	
Control	46.8 $\pm$ 2.2	5.1 $\pm$ 2.0	47.9 $\pm$ 3.5	18.0 $\pm$ 6.7	1.98 $\pm$ 0.12
No DPN	43.9 $\pm$ 2.4	3.5 $\pm$ 1.2	43.9 $\pm$ 4.4	12.3 $\pm$ 5.5	1.86 $\pm$ 0.35
Mild DPN	44.1 $\pm$ 4.4	4.4 $\pm$ 3.0	46.5 $\pm$ 5.6	12.9 $\pm$ 2.2	2.16 $\pm$ 0.35
Moderate DPN	38.3 $\pm$ 5.3	2.4 $\pm$ 1.0	43.0 $\pm$ 6.4	5.2 $\pm$ 2.9	1.89 $\pm$ 0.01

For motor NCV and sensory nerve conduction amplitudes, significant differences were found between Control and Moderate DPN groups. Although statistical tests have not revealed any significant difference between the existing groups for the sensory NCV and for the sympathetic response, sensory NCV and amplitudes were established by the neurophysiologist as abnormal (below the limit) in patients with moderate degree of DPN.

Normal NCV values were observed for all patients without DPN and for the majority of patients with mild DPN. Nevertheless, the NCV and amplitude values were always lower for patients with mild and moderate DPN, for both motor and sensory nerves.

The results show large-fibre abnormalities in all patients with moderate DPN, and in one patient with mild DPN. Progressive axonal losses, demonstrated by decreased motor amplitudes and reduced sensory amplitudes, were found according to DPN severity. The low values of both motor and sensory NCV indicate that moderate DPN cases occur with severe nerve demyelination.

### 3.2. DPN evaluation based on image texture features

From the set of 61 extracted image texture features, 7 were automatically selected for use with the SVM classifier. The SVM was used to establish a supervised classification method to classify each image in the 'with DPN' or 'without DPN' groups. Two different evaluations were done: on the first evaluation the Control individuals and the No DPN diabetic patients were both considered as 'without DPN', while the Mild e Moderate DPN patients were tagged as 'with DPN'. On the second evaluation, the images from No DPN diabetic patients were not included. Table 3 presents the results, obtained for both evaluations, for 10-fold cross-validation and leave-one out validation.

**Table 3.** SVM classification of images from individuals with and without DPN.

‘with DPN’ or ‘without DPN’	Correctly Classified Instances	
	10-fold cross-validation	Leave-one out validation
Including No DPN diabetic patients (631 images)	73.5 %	73.7 %
Not including No DPN diabetic patients (525 images)	80.6 %	79.8 %

We also evaluated the ability of the classifier to classify correctly the images of the “with DPN” in the groups “mild DPN” and “moderate DPN”. The results are presented in Table 4.

**Table 4.** SVM classification of images from individuals with DPN.

	Correctly Classified Instances	
	10-fold cross-validation	Leave-one out validation
mild DPN’ or ‘moderate DPN’	79.3 %	78.9 %

In order to evaluate the reproducibility of the classifier, the images included in the ‘with DPN’ or ‘without DPN’ groups were randomly divided between two sub-groups. This way, two sets of ‘with DPN’ and ‘without DPN’ images were obtained. The first set had 124 images from DPN patients and 138 images from healthy controls. The second set included 126 images from DPN patients and 137 images from healthy controls. The diabetic patients without DPN were not included in this reproducibility assessment. The results are presented in Table 5.

**Table 5.** Reproducibility assessment of SVM classifier.

‘with DPN’ or ‘without DPN’	Correctly Classified Instances	
	10-fold cross-validation	Leave-one out validation
Set A (262 images)	82.1 %	82.1 %
Set B (263 images)	77.2 %	76.8 %

#### 4. Discussion

An automated image analysis system for objective detection and grading of DPN is essential for establishing CCM as a reference clinical technique for DPN diagnosis and assessment. The methods proposed by different research groups are based on automatic algorithms for nerve segmentation and extraction of morphology parameters. These parameters are then analyzed using statistical between groups comparison tests, for identifying differences between controls and patients groups, or using classification techniques to assign individuals to those groups [16, 17, 20]. This approach requires robust automatic nerve segmentation algorithms able to perform even with lower quality images.

In this work we considered a different methodology, where the nerve images were analysed as a whole, without performing a nerve segmentation step. We choose to use classification techniques based on features obtained from texture analysis of corneal nerve images. Although, to the best of our knowledge, this approach was never used for analysing CCM images, texture analysis has been extensively used for medical image processing, mainly in radiology and nuclear medicine, but also for medical imaging based on optical radiation. Recently, classification techniques based on texture

features were used for classifying hysteroscopic images [32]. Hysteroscopy produces images of superficial endometrial vessels, which have structural similarities with the images of the corneal sub-basal nerve plexus obtained by CCM.

We evaluated the use of this methodology to discriminate between individuals with and without DPN. This was done in two different ways: joining the diabetic patients without DPN with the healthy individuals to establish the ‘without DPN’ group or excluding those patients and using just the healthy individuals and the diabetic patients with DPN in the evaluation. In the first case we obtained an accuracy of 73.5% while in the second evaluation the observed accuracy was 80.6%.

We also used the same methodology to grade the images from patients with DPN in the mild and moderate groups. The achieved accuracy was 79.3%. In all instances the classifier used the same set of 7 attributes selected from the 61 image attributes computed.

The classifier reliability was evaluated by randomly assigning every image of the ‘with DPN’ and ‘without DPN’ groups to one of two subsets. This way, we setup two pairs of smaller ‘with DPN’ and ‘without DPN’ groups. In this procedure we obtained an average accuracy of  $79.7\% \pm 3.5\%$ . The small standard deviation obtained is a good indicator of the classifier reproducibility.

This are very promising results particularly because they were achieved for a low number of image features and without any image pre-processing or any adaptive process in the extraction of those texture features. It is reasonable to expect higher accuracies with more robust feature extraction methods.

The lower accuracies observed, when using images from diabetic patients diagnosed as not having diabetic neuropathy, suggests that the analysis of corneal nerve images is more sensitive to early nerve disorders in diabetic patients than the standard electrophysiological measurements or clinical examinations and assessments recommended by the international consensus guidelines for diagnosis and management of DPN and included in the Michigan Neuropathy Screening Instrument. It was already shown that morphometric analysis of corneal nerve images has enough sensitivity to detect early disorders in the corneal nerves of diabetic patients [1, 33, 34]. Our results suggest that texture analysis of corneal nerve images have the same potential. However, further studies are required to confirm such potential.

As far as we know, this is the first attempt to use the information contained in CCM images of the corneal sub-basal nerve plexus to assess DPN, without measuring morphology parameters after performing nerve segmentation. The evaluation of DPN based on the morphometric of corneal nerves has the important advantage of being based on parameters with a clear clinical meaning. Corneal nerve morphometric parameters provide direct quantification of small fibres disorders. The Nerve Fibre Length and Nerve Fibre Density parameters are related to enhanced nerve degeneration, while the Nerve Branching Density is associated to nerve regenerative capacity [1]. The methods based on these parameters are able to quantify corneal nerve fibre degeneration and regeneration and can be used to assess therapeutic efficacy of treatments. It will be difficult to obtain this amount of information using texture based methods for analysing corneal nerve images. However, as our results suggest, these methods may be suited for screening purposes.

## References

- [1] Malik RA, Kallinikos P, Abbott CA, van Schie CH, Morgan P, Efron N, et al. *Diabetologia* 2003 May;46(5):683-8.
- [2] Quattrini C, Tavakoli M, Jeziorska M, Kallinikos P, Tesfaye S, Finnigan J, et al. *Diabetes* 2007 Aug;56(8):2148-54.
- [3] Tavakoli M, Quattrini C, Abbott C, Kallinikos P, Marshall A, Finnigan J, et al. *Diabetes Care* 2010 Aug;33(8):1792-7.
- [4] Gooch C, Podwall D. *Neurologist* 2004 Nov;10(6):311-22.
- [5] Vinik AI, Park TS, Stansberry KB, Pittenger GL. *Diabetologia* 2000 Aug;43(8):957-73.
- [6] Rahman M, Griffin SJ, Rathmann W, Wareham NJ. *Diabet Med* 2003 May;20(5):368-74.

- [7] Smith AG, Howard JR, Kroll R, Ramachandran P, Hauer P, Singleton JR, et al. *Journal of the Neurological Sciences* 2005 Jan 15;228(1):65-9.
- [8] Lauria G, Hsieh ST, Johansson O, Kennedy WR, Leger JM, Mellgren SI, et al. *European Journal of Neurology* 2010 Jul;17(7):903-E49.
- [9] Malik RA, Veves A, Walker D, Siddique I, Lye RH, Schady W, et al. *Acta Neuropathol* 2001 Apr;101(4):367-74.
- [10] Patel DV, McGhee CN. *Clin Experiment Ophthalmol* 2007 Jan;35(1):71-88.
- [11] Erie JC, McLaren JW, Patel SV. *Am J Ophthalmol* 2009 Nov;148(5):639-46.
- [12] Rosenberg ME, Tervo TM, Immonen IJ, Muller LJ, Gronhagen-Riska C, Vesaluoma MH. *Invest Ophthalmol Vis Sci* 2000 Sep;41(10):2915-21.
- [13] Popper M, Quadrado MJ, Morgado AM, Murta JN, Van Best JA, Muller LJ. *Invest Ophthalmol Vis Sci* 2005;46(Suppl S):2194.
- [14] Midena E, Brugin E, Ghirlando A, Sommovilla M, Avogaro A. *J Refract Surg* 2006 Nov;22(9 Suppl):S1047-S1052.
- [15] Ahmed A, Bril V, Orszag A, Paulson J, Yeung E, Ngo M, et al. *Diabetes Care* 2012 Apr;35(4):821-8.
- [16] Scarpa F, Grisan E, Ruggeri A. *Invest Ophthalmol Vis Sci* 2008 Nov;49(11):4801-7.
- [17] Dabbah MA, Graham J, Petropoulos IN, Tavakoli M, Malik RA. *Med Image Anal* 2011 Oct;15(5):738-47.
- [18] Petropoulos IN, Alam U, Fadavi H, Marshall A, Asghar O, Dabbah MA, et al. *Invest Ophthalmol Vis Sci* 2014 Apr;55(4):2071-8.
- [19] Ferreira A, Morgado AM, Silva JS. *Computer Methods and Programs in Biomedicine* 2012 Jul;107(1):53-60.
- [20] Holmes TJ, Pellegrini M, Miller C, Epplin-Zapf T, Larkin S, Luccarelli S, et al. *Invest Ophthalmol Vis Sci* 2010 Sep;51(9):4480-91.
- [21] Scarpa F, Zheng X, Ohashi Y, Ruggeri A. *Invest Ophthalmol Vis Sci* 2011 Aug;52(9):6404-8.
- [22] Petropoulos IN, Manzoor T, Morgan P, Fadavi H, Asghar O, Alam U, et al. *Cornea* 2013 May;32(5):E83-E89.
- [23] Dehghani C, Pritchard N, Edwards K, Russell AW, Malik RA, Efron N. *Cornea* 2014 Jul;33(7):696-702.
- [24] Efron N, Edwards K, Roper N, Pritchard N, Sampson GP, Shahidi AM, et al. *Eye Contact Lens* 2010 Sep;36(5):245-8.
- [25] Papanas N, Ziegler D. *Corneal Current Diabetes Reports* 2013 Aug;13(4):488-99.
- [26] Boulton AJ, Gries FA, Jervell JA. *Diabet Med* 1998 Jun;15(6):508-14.
- [27] Feldman EL, Stevens MJ, Thomas PK, Brown MB, Canal N, Greene DA. *Diabetes Care* 1994 Nov;17(11):1281-9.
- [28] Galloway MM. *Computer Graphics and Image Processing* 1975;4(2):172-9.
- [29] Dasarathy BV, Holder EB. *Pattern Recognition Letters* 1991 Aug;12(8):497-502.
- [30] Hall M, Franck E, Holmes G, Pfahringer B, Reutemann P, Witten IH. *SIGKDD Explorations* 2009;11(1).
- [31] WLSVM: Integrating LibSVM into Weka Environment [computer program]. 2005.
- [32] Vlachokosta AA, Asvestas PA, Gkrozou F, Lavasidis L, Matsopoulos GK, Paschopoulos M. *Med Biol Eng Comput* 2013 Aug;51(8):859-67.
- [33] Hossain P, Sachdev A, Malik RA. *Lancet* 2005 Oct 15;366(9494):1340-3.
- [34] Kallinikos P, Berhanu M, O'Donnell C, Boulton AJ, Efron N, Malik RA. *Invest Ophthalmol Vis Sci* 2004 Feb;45(2):418-22.