

# Fully automated shape model positioning for bone segmentation in whole-body CT scans

A Fränzle<sup>1</sup>, M Sumkauskaitė<sup>2</sup>, J Hillengass<sup>2,3</sup>, T Bäuerle<sup>4</sup>, R Bendl<sup>1,5</sup>

<sup>1</sup> Department of Medical Physics in Radiation Oncology, German Cancer Research Center (DKFZ), Heidelberg, Germany

<sup>2</sup> Department of Radiology, German Cancer Research Center (DKFZ), Heidelberg, Germany

<sup>3</sup> Department of Internal Medicine V, University of Heidelberg, Heidelberg, Germany

<sup>4</sup> Department of Medical Physics in Radiology, German Cancer Research Center (DKFZ), Heidelberg, Germany

<sup>5</sup> Department of Medical Informatics, Heilbronn University, Heilbronn, Germany

E-mail: a.fraenzle@dkfz-heidelberg.de

**Abstract.** Analysing osteolytic and osteoblastic bone lesions in systematically affected skeletons, e.g. in multiple myeloma or bone metastasis, is a complex task. Quantification of the degree of bone destruction needs segmentation of all lesions but cannot be managed manually. Automatic bone lesion detection is necessary. Our future objective is comparing modified bones with healthy shape models. For applying model based strategies successfully, identification and position information of single bones is necessary. A solution to these requirements based on bone medullary cavities is presented in this paper.

Medullary cavities are useful for shape model positioning since they have similar position and orientation as the bone itself but can be separated more easily. Skeleton segmentation is done by simple thresholding. Inside the skeleton medullary cavities are segmented by a flood filling algorithm. The filled regions are considered as medullary cavity objects. To provide automatic shape model selection, medullary cavity objects are assigned to bone structures with pattern recognition. To get a good starting position for shape models, principal component analysis of medullary cavities is performed. Bone identification was tested on 14 whole-body low-dose CT scans of multiple myeloma patients.

Random forest classification assigns medullary cavities of long bones to the corresponding bone (overall accuracy 90%). Centroid and first principal component of medullary cavity are sufficiently similar to those of bone (mean centroid difference 21.7 mm, mean difference angle 1.54° for all long bones of one example patient) and therefore suitable for shape model initialization.

This method enables locating long bone structures in whole-body CT scans and provides useful information for a reasonable shape model initialization.

## 1. Introduction

Bone tumor diseases like bone metastasis or multiple myeloma have bone destructive effects on bone and cause osteolytic lesions. To assess overall disease progression or treatment response exact segmentations of all lesions are needed. Since the whole skeleton can be affected, segmentation of all lesions cannot be managed manually since it is too time-consuming. Therefore an automatic computerized approach is needed. To find modified regions in bones and to be able to find missing bone mass also in case of breached cortical bone, a reconstruction of



the outer bone contour is necessary first. Recent publications about bone segmentation present interactive methods [1] or are atlas based and defined for particular body regions [2], [3], [4]. Because of large image data in case of whole-body CT scans in multiple myeloma, we want to avoid any user interaction and provide global lesion detection on whole-body scans. For the reconstruction of the outer bone contour of single bones, statistical shape models [5] are to be used in our case. These shape models are able to deal with poor edge contrast in the joints and to reconstruct the former bone contour, since these models do not tend to leak into osteolytic modified bone contours. For successful segmentation, these models need a reasonable initial positioning. To segment the correct structure, the shape model has to be positioned near the corresponding bone. To prevent wrong alignment of the model during the adjustment process, the model has to be roughly aligned. In this paper, we focus on the automatic initialization of shape models as a necessary step before segmentation and present a method to get the information required for automatic positioning of shape models for segmentation of long bones. For this purpose an automatic segmentation of the medullary cavities is used. Medullary cavities can be segmented more easily compared to the bone structures themselves, since poor contrast and complex structures in the joints impede delineation of single bones with simple image processing methods, like thresholding. Medullary cavities have similar position and orientation as the bones themselves and therefore provide information necessary for model initialization. With automatic segmentation of medullary cavities and assignment to corresponding bone structures with pattern recognition we are able to locate bone structures in whole body CT scans without any user interaction. All information needed to select the appropriate shape models and to find a good starting position is provided with the presented method.

## 2. Material and Methods

Data, segmentation of medullary cavities and identification of segmented medullary cavity objects with a random forest classifier are described in detail in the following sections.

### 2.1. Data

Medullary cavity segmentation and bone identification were tested on 14 whole-body CT scans of multiple myeloma patients (voxel size  $0.98 \text{ mm} \times 0.98 \text{ mm} \times 3.0 \text{ mm}$ ). The comparison of position and orientation of bones and their medullary cavities was performed exemplarily on one patient.

### 2.2. Automatic segmentation of medullary cavities

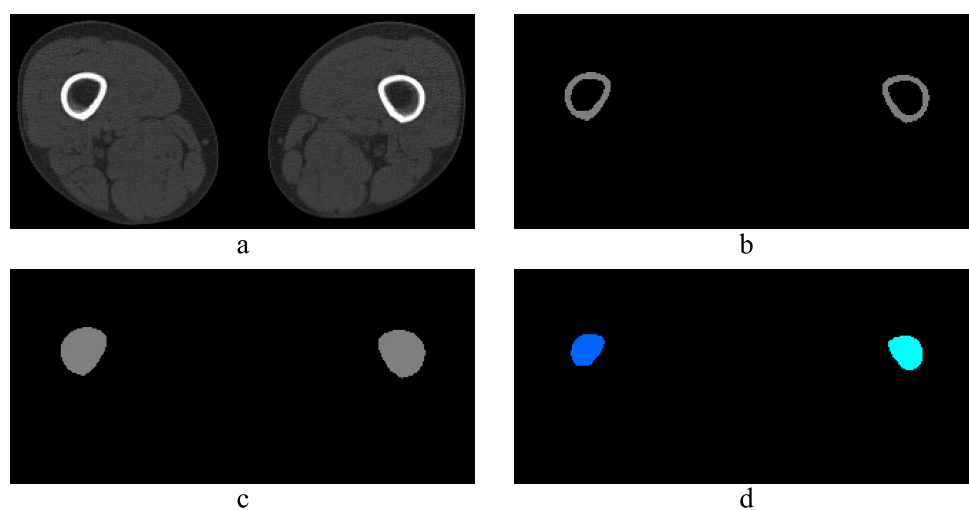
The segmentation of medullary cavities mainly consists of the following steps, which are shown in figure 1 for the femur bones (fig. 1 a):

- binarization of the bones with a global threshold (fig. 1 b)
- filling the segmented skeleton with a flood filling (fig. 1 c)
- determining the filled regions as difference of filled skeleton and skeleton segmentation.

The filled regions (fig. 1 d), can be considered as segmentation of the medullary cavities.

### 2.3. Bone identification with pattern recognition

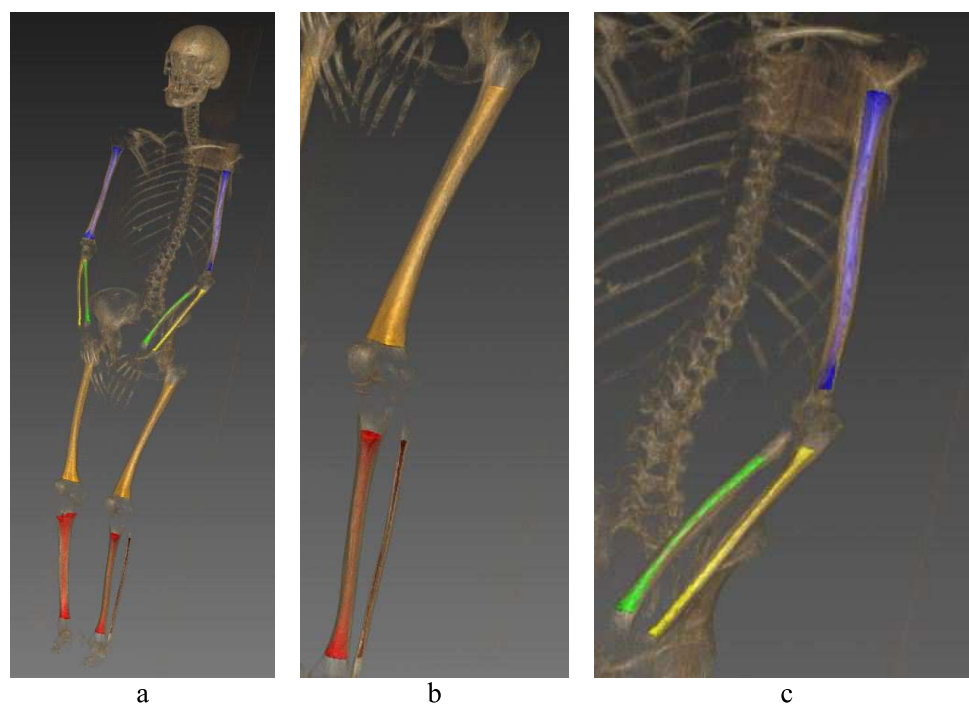
To be able to select the appropriate shape model for a specific bone for further developments the medullary cavity objects are assigned to the corresponding bone structure using random forests [6]. A classification is performed based on object volume and position parameters (distance of centroid to median plane, distance of centroid to mid-coronal plane, relative position of centroid in cranial-caudal direction). The classification performance was assessed by training 14 random forests with 100 trees, leaving one patient out as test case in each run.



**Figure 1.** Process of segmentation of medullary cavities. The skeleton (left and right femur shown here in a) is binarized (b) and filled (c). d shows the filled and labelled regions.

### 3. Results

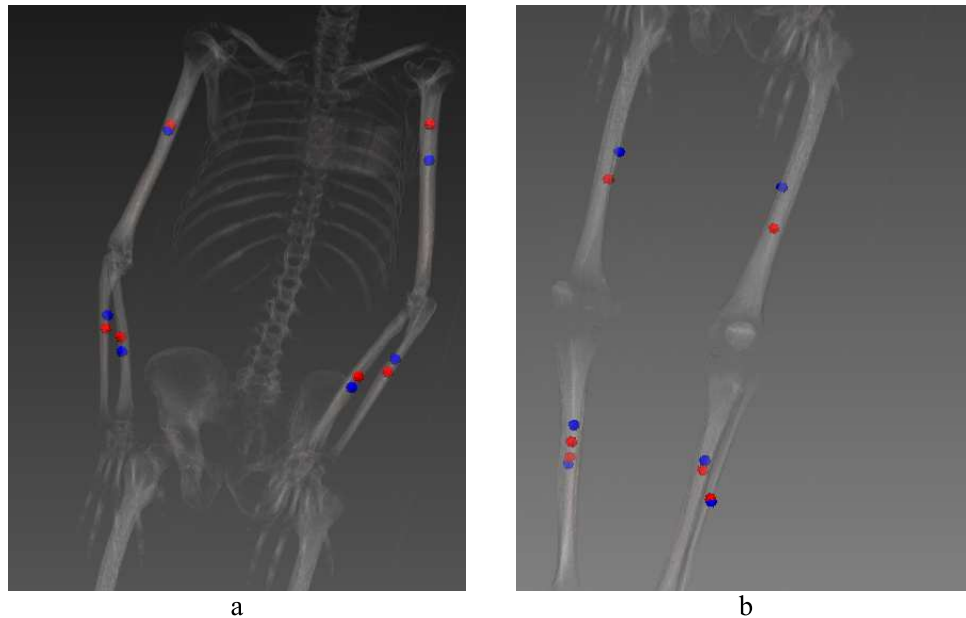
Figure 2 shows the automatically segmented medullary cavities.



**Figure 2.** Automatically segmented medullary cavities in the skeleton (a) and detailed in leg bones (b) and arm bones (c).

Figure 3 shows centroids of bone (blue) and medullary cavities (red). It can be seen, that bone centroids and medullary cavity centroids are located close to each other. To quantify deviations in location and orientation the mean centroid difference and mean angle between first principal components of bone and medullary cavity are calculated exemplarily for all long bones of one

patient. The mean centroid difference is 21.7 mm (SD 15.37 mm) and the mean angle is  $1.54^\circ$  (SD  $0.94^\circ$ ), which is accurate enough for model initialization.



**Figure 3.** Centroids of bone (blue) and medullary cavities (red) in arm bones (a) and leg bones (b).

To assess classifier performance the classification accuracy for the different long bones is determined: femur 90%, tibia 79%, fibula 79%, humerus 93%, radius 69%, ulna 46%, other 99%. The class "other" helps to exclude objects segmented in the medullary cavity segmentation process but not belonging to a long bone from further processing. The classification accuracy over all objects including those defined as "other" is 90%.

#### 4. Conclusions

Classification of medullary cavities enables identification of long bone structures in whole-body CT scans. The accuracy of identifying the ulna is low, but this bone could be identified after the identification of humerus and radius. The centroid of a medullary cavity can be used for initial positioning of a shape model and the first principal component can be used for initial orientation. In conclusion, the presented method provides all information needed for the automatic selection and initialization of a statistical shape model for long bone segmentation.

#### Acknowledgments

This project is funded by the German Research Foundation (DFG), Project BE 2523/3-1.

#### References

- [1] Liu L, Raber D, Nopachai D, Commean P, Sinacore D, Prior F, Pless R and Ju T 2008 *Med Image Comput Comput Assist Interv* **11** 296–304
- [2] Ehrhardt J, Handels H, Malina T, Strathmann B, Plötz W and Pöpl S J 2001 *Int J Med Inform* **64** 439–447
- [3] Haas B, Coradi T, Scholz M, Kunz P, Huber M, Oppitz U, André L, Lengkeek V, Huyskens D, van Esch A and Reddick R 2008 *Phys Med Biol* **53** 1751–1771
- [4] Wu C, Murtha P E and Jaramaz B 2010 *Int J Med Robot* **6** 1–17
- [5] Heimann T and Meinzer H P 2009 *Med Image Anal* **13** 543–563
- [6] Breiman L 2001 *Machine Learning* **45** 5–32