

PAPER • OPEN ACCESS

Antioxidant Activity of Haramounting Leaf Ethanol Extract (*Rhodomytrus tomentosa*) In Preventing Heart Damage of Mice (*Mus musculus* L.) after exposure to Electronic Cigarette

To cite this article: S Ilyas *et al* 2019 *IOP Conf. Ser.: Earth Environ. Sci.* **305** 012080

View the [article online](#) for updates and enhancements.

Antioxidant Activity of Haramounting Leaf Ethanol Extract (*Rhodymyrtus tomentosa*) In Preventing Heart Damage of Mice (*Mus musculus* L.) after exposure to Electronic Cigarette

S Ilyas^{1*}, R S Tanjung¹, S, Hutahaean¹, M Tanjung^{1,2}, Elimasni¹, I Jamilah¹, F Murdela¹

¹Department of Biology, Faculty of Mathematics and Natural Sciences, Universitas Sumatera Utara, Medan, Indonesia

²Center of Excellence for Natural Resources-Based Technology, Mangrove and Bio-Resources Group Universitas Sumatera Utara, Medan, Indonesia

*Email: syafruddin6@usu.ac.id

Abstract. Cigarette smoke is one factor that increases free radicals in the blood will affect liver health in the body. The purpose of this study is to find out the effect of giving leaves ethanol extract haramounting to histology of male mice liver exposed to electric cigarettes. The design of this study used Completely Randomized Design (CRD) consisting of + Group, - Group and three treatments of Haramounting Leaf Ethanol Extract (*Rhodymyrtus tomentosa* (Aiton) Hassk.) for 30 days at a dose of 100 mg/kg BW Body Weight, 200 mg/kg BW and 300 mg/kg BW for treatment use of five replications. Liver organ preparations were made using paraffin block method and Hematoxylin Erlich-Eosin (HE) staining. The results of the study show on histological observations The liver has a tendency that electric cigarette smoke can cause damage in liver cells. The results of this study indicate that ethanol extract leaves of Haramounting after exposure to electric cigarette smoke can effectively regenerate damaged liver cells.

1. Introduction

Epidemic of tobacco problems due to smoking is one of the biggest health threats the society currently faced by the world. Cigarettes an interesting phenomenon because besides its contribution as one of the health problems with a fairly high death rate, almost six million people per year with more composition out of five million deaths are the result of use direct cigarettes whereas more than six hundred thousand the remaining deaths are the result of non-smokers exposed to smokers [1]. Free radicals are a molecule which has unpaired electrons inside the outer orbitals are very reactive. Radical this tends to hold chain reactions that are if it occurs in the body it will get cause damage continuous and continuous. Human body have an endogenous defense system against free radical attacks mainly occur through events of normal cell metabolism and inflammation [2] Amount of free radicals can experience an increase due to factors stress, radiation, cigarette smoke and environmental pollution cause the body's defense system to exist inadequate, so the body needs it additional antioxidants from outside that can protect from free radical attacks.

Antioxidants are also used in food to control lipid oxidation. T-butyl hydroxy anisol (BHA) and di-butyl hydroxitoluen (BHT) compounds are used as food antioxidants, but the possibility of adverse



side effects is not used for therapeutic ingredients. Besides being able to protect the body from attacks by free radicals, natural antioxidants can also slow down the occurrence of chronic diseases caused by decreases in reactive oxygen species (ROS), especially hydroxyl radicals and superoxide radicals [3]. Chemicals used to prevent or slow down free radical damage is an antioxidant [4,5,6]. The endogenous antioxidant work to neutralize free radicals where in carrying out the process and also needed antioxidants from the outside (exogenous) in the form of vitamins and minerals has been obtained from food or supplements.

Haramounting (*Rhodymyrtus tomentosa* (Aiton) Hassk.) is a plant native to Southeast Asia and also spread in the territory of Indonesia. Haramounting can be used as an herbal remedy [7, 8]. that the people of Kalimantan and South Thailand utilize this plant as an anti-diabetic medications, diarrhea, burns, and abdominal pain. Haramounting leaf extract contains methanol which can lower blood glucose in blood. Flavonoid content results in leaves and fruit haramounting may be free-radical scavengers (anti-oxidants) for human. Edible leaves contain steroids, terpenoids, alkaloids, phenols, flavonoids, and saponins [9]. According to the study [10] conducted in vivo and in vitro extract of leaf extract (*Rhodymyrtus tomentosa* (Aiton) Hassk) has strong antioxidant activity. In previous studies into liver organs [11] against haramounting extracts on paracetamol [12] had an effect on the improvement in liver damage induced in paracetamol.

2. Methods

2.1 Research Design

This study uses a completely randomized design method that is divided in 5 treatments with 5 replications according to the Fereder formula, namely:

$$(t-1)(n-1) \geq 15$$

Description:

t = treatment group

n = repeat

Following this research treatment groupings can be seen in table 1

Table 1. Grouping of research treatments

	Aquadest	Smoke Electric Cigarette	Haramounting Extract 30 Days		
			100 mg/kg BW	200 mg/ kg BW	300 mg/kg BW
K (-)	√				
K(+)	√	√			
P1		√	√		
P2		√		√	
P3		√			√

2.2. Preparation Sample for extracts

The extraction method uses the maceration process using ethanol solvent. Making extracts is done by soaking simplicia for 48 hours with the composition of 1000 grams of leaves is haramounting with solvent ethanol. Then it will be filtered using Whatmann paper and the evaporation process is carried out to separate the solvent with the extraction results.

2.3. Exposure to e-cigarette smoke and administration of extracts

The mice tested were given food and drink in an ad libitum, then given oral haramounting extract orally with doses of 100 mg / kgBW, 200 mg / kgBW and 300 mg/kgBW each distinguished durations of 30 days. First poured 8 drops of liquid on the 4 sides of each burning cotton morning. Then electric cigarette smoke was blown into the smoking chamber. Then prepared the equipment

used in the presentation, namely smoking chamber and put the mouse in the cage per group containing five tail into the smoking chamber through the top of smoking chamber then closed again Repeated 4 times or according to the treatment then given extract of haramounting leaves after \pm 6 hours of administration

e-cigarette smoke and is done every day for 30 days.

2.4 Preparation for making histological preparations

Histological preparation of the liver using procedures [12]. First the liver that has been surgically removed is washed using 0.9% NaCl. After that, the organs are dissected and then fixed using a 10% formalin buffer. Then do dehydration with alcohol for 60 minutes. Then purified with xylol then infiltrated with paraffin in an oven with a temperature of 60-70 ° C for 2 hour. Then the infiltrated organ is then planted in a small box containing paraffin. Next, cut organs transversely in the form of paraffin tape with using a microtome with a thickness of 4 μ m and then affixed to the glass object which was smeared with glycerin which then deparaffinated using xylol and then rehydrated with multilevel alcohol. Then cleaned with running water and stained with Hematoxylin-Eosin staining and finally covered with vaseline and glass cover.

2.5 Histopathological Analysis of the Liver

The liver was taken to make histopathological preparations using paraffin method. Histopathological studies were performed under a microscope with a magnification of 10x40. Liver histological preparations were observed under a light microscope in 5 different fields, with a magnification of 40x10 x. Each field counted 20 cells randomly so that in one preparation 100 liver cells were found. Then the mean score of histopathology liver change score was calculated in five fields of each - each mouse with the Scoring Histopathology Manja Roenigk model. The liver structure observed was normal hepatocytes and hepatocytes which suffered damage both necrosis [6], parenchymous degeneration and hydropic degeneration. Then the number of percentages that occur [13] are counted and calculated. The Assessment of Hepatocyte Damage Assessment Criteria for Spoiled Roenigk who have been modified can be seen in Table 2.

Tabel 2. Assessment of Hepatocyte Damage Assessment Criteria for Spoiled Roenigk who have been modified

Damage Rate	Score
Normal	1
Parenkimatosa Degeneration	2
Hydropic Degeneration	3
Necrosis	4

2.6 Data Analysis

The data analysis used a complete randomized design (ANOVA) at 95% confidence level and , $\alpha = 0.5$ with bootstrap / duncan analysis. All data is analyzed using SPSS 23 program software.

3. Results and Discussions

The results will be discussed in two subsections, they are histopatology analysis and Hepatocyte Damage Rate.

3.1. Histopatology Analysis

Based on observations from histological liver that has been done on the liver of male mice after the exposure of electric cigarette smoke and given ethanol extract of Haramounting (*Rhomodytrus tomentosa* (Aiton) Hassk.) Can be seen in Figure 1.

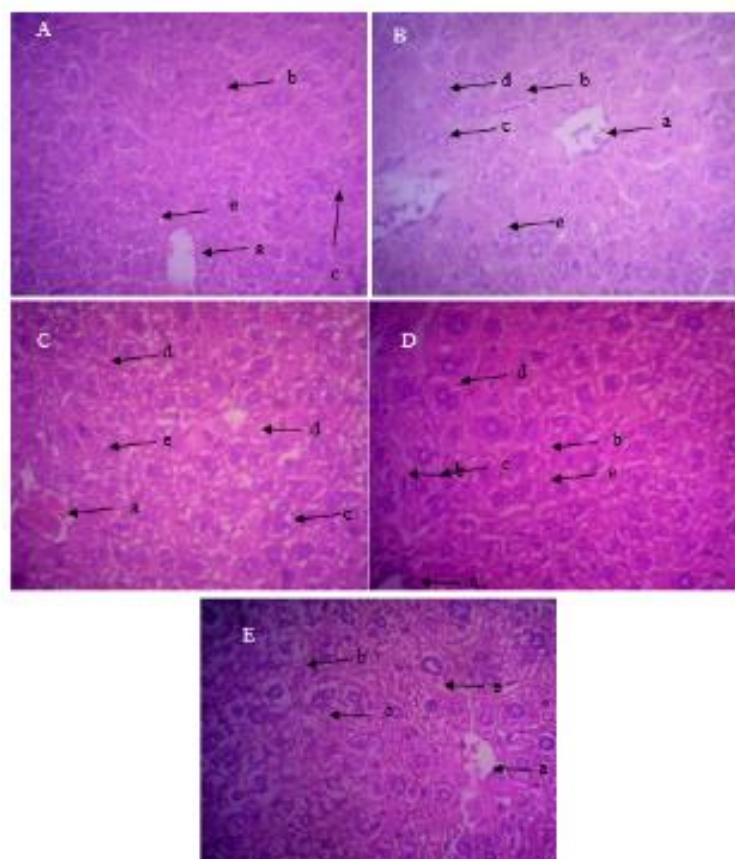


Figure 1. Microscopic Hepatocytes Giving Haramounting Leaf Ethanol Extracts (*Rhodomytus tomentosa* (Aiton) Hassk) and Electric Cigarette Smoke Expansion with HE Coloring and 400x Enlargement (A) K- = Negative Controls (mice are given nothing but feed; (B) K + = Positive Control, Mice were exposed to electric cigarette smoke (C), (D), (E) P1 = Treatment of 1,2, and 3 mice were exposed to electric cigarette smoke and were given extracts of 100 mg /kg BW, 200 mg /kg BW and 300 mg /kg BW for 30 Day: (a) Central Veins, (b) Normal Hepatocytes, (c) Parenchymous Degeneration, (d) Hydropic Degeneration and (e) Necrosis

In Figure 1 shows the results of the observation of the histology of the liver of male mice found cell changes. The percentage of normal hepatocytes in the K-group was more than the treatment. While the number of cells experiencing swelling, hydropic and necrosis is quite a lot. According to [9], the presence of hepatocyte swelling only occurs in the mitochondria and endoplasmic reticulum due to stimuli that produce oxidation. Hepatocyte damage in the form of swelling is reversible. Likewise with hydropic which is reversible. Hepatocytes that experience necrosis due to changes in the cell nucleus, this is natural because each cell will experience cell death. This is due to the presence of external factors, namely in the number of feeds and drinks in mice that are in accordance with the standard, the condition of the cage is less than ideal, the stress factor of mice, the influence of substances or other diseases, as well as other internal factors such as resistance and susceptibility of mice. In the treatment group, hepatocyte damage is likely due to the effect of treatment, which causes disruption of cell membrane permeability. The disruption of cell membrane permeability is due to the effect of giving ethanol extract of haramounting leaves and exposed to electric cigarette smoke where the content of haramounting leaf extract is high in flavonoids which interfere with free radicals. But in P1 treatment with haramounting leaf extract the amount of hepatocyte damage decreased compared to other treatments. This is because haramounting contains antioxidants that function as antioxidants to fight free radicals in the body including hepatocytes. This is in line with [10] Flavonoid compounds in

harmounting extract can be free radical agents, reduce the amount of lipids, NO production and increase the activity of antioxidant enzymes in the body that will be exposed to organs.

3.2. Hepatocyte Damage Rate

The results of observations on the level of hepatocyte damage in each treatment on the transmission of electric cigarette smoke and haramounting leaf extraction (*Rhodymyrtus tomentosa* (Aiton). Hask) stastic analysis test. From the data the data experienced a decrease in cell death (necrosis) compared with exposed to electric cigarette smoke. Average Necrosis K - (5.4%), K + (43.6%), P1 (20.2%), P2 (31.2%) and P3 (32.4%). Can be seen in table 3 .

Table 3. Histology hepar of micer after treatment

Treament	Score				Notation
	Normal (%)	Parenkimosa Degeneration (%)	Hidropyic Degeneration (%)	Necrosis (%)	
K-	94,4	0,2	0,0	5,4	a
K+	49,2	1,8	5,4	43,6	b
P1	51,6	17,4	10,8	20,2	c
P2	51,2	11,4	6,2	31,2	c
P3	46,0	15,2	6,4	32,4	d

Information. K- = Negative Control (mice are given nothing but feed; K + = Positive Control, mice are exposed to electric cigarette smoke; P1 = Treatment 1, mice are exposed to electric cigarette smoke and extracts of 100mg /kg BW for 30 days; P2 = Treatment 2 , mice were exposed to electric cigarette smoke and given 200mg /kg BW extract for 30 days; P3 = treatment 3, mice were exposed to electric cigarette smoke and given 300mg /kg BW extract for 30 days, different letters in different treatments showed significantly different.

Based on Table 3 it can be seen that there is a significant difference in the real level of hepatocyte damage between K- and K + and there is also a significant decrease in the number of presenatse necrosis in K+ with P1, P2 and P3 and Normal cell increase in K + with P1. This may be because the substances contained in electric cigarettes have not caused a harmful effect on the liver and also the content of ethanol extract of haramounting leaves which contain Falnovolid and Tanin which decreases the percentage of necrosis in the hepatocytes and also can protect the liver but can not restore the normal hepatocyte state. However, the percentage of P2 and P3 necrosis damage tends to increase with K- and K +. This is because the contents of the electronic cigarette are toxic to the liver and also the content of haramounting leaf extract which has flanovoid metabolite content.

This is in line with the study [14] states that the protection by haramounting leaf extract shows that haramounting leaf acetone extract has the ability to inhibit the formation of malondialdehyde (MDA) [15,16]; has a very strong reducing capacity; have capacity as a chealting agent. Hepatotoxicity due to chemical compounds is a potential complication that is almost always present in every chemical compound given because the liver is the center of metabolic disposition of all drugs and foreign substances that enter including electric cigarette smoke. Liver cell damage is rarely caused by a substance but often by metabolic toxic substances. The liver is an organ that is often damaged so that it can die through the path of apoptosis [17,18,19] or necrosis [20]. Metabolism of various compounds mainly occurs in the liver, resulting in very large organ damage. As a result the metabolic process does not run normally, it will cause various diseases. The cells contained in the liver will be deposited so they will change [21]

According to [20], hepatocytes are the type of cells that make up most of the liver. Hepatocytes are responsible for the central role of the liver in the metabolic process. These cells are located between

sinusoids filled with blood and bile ducts. According [22], if the liver cell is damaged due to various factors, a series of morphological changes will occur in the liver cells. These changes can be sublethal, degenerative or lethal in the form of necrotic.

One of the changes induced by free radicals is the change in the properties of cell membranes and cytoplasmic membranes in cell elements such as mitochondria and lysosomes caused by fat peroxide. After damaging the cell membrane, toxic effects that can also reach the nucleus and damage it, which causes the cell structure to become abnormal and eventually lead to necrosis [22]. Free radicals from the environment due to exposure to cigarette as occurs in passive smokers, causing antioxidants endogenous are no longer able to protect the body from oxidants, resulting in increased free radicals that trigger oxidative stress in cells [23, 24, 26].

The results of observations made on microscopic images of the liver given exposure [25] to electronic cigarette smoke and given haramounting leaf extract (*Rhodymyrtus tomentosa* (Aiton) Hassk.) Found that there were normal hepatocytes and hepatocytes that experienced changes in parenchymous degeneration, phidrophic degeneration and necrosis.

4. Conclusions

The real level of protection effect on the liver after exposure to cigarette smoke and protection of hepatocyte damage occurred in the administration of ethanol haramounting extract (*Rhodymyrtus tomentosa* (Aiton) Hassk.) Significantly ($p < 0.05$) at a dose of 100mg/kg BW even though it did not return the liver normal.

Acknowledgments

The authors gratefully acknowledge that the present research is supported by Univeristy of Sumatera Utara from Talenta proposal program on Professor research grant of year 2018, Contract number; 2590/UN5.1.R/PPM/2018.

References

- [1]. WHO (World Health Organization). 2013. *Media Centre: Fact Sheets of Tobacco*. <http://www.who.int/mediacentre/factsheets/fs339/en/>. (Citiation 18 August 2015).
- [2]. Soesilo, Novita Sari 2012 The Influence of Noni Fruit Juice (*Morinda citrifolia* L) Dosage Against Nitrie Oksidae (NO) Perionteium Macrophage In Rats Exposed to Cigarette Smoke. University of Diponegeoro.
- [3]. Wahdianingsih, S, Setowati, EP, and Wahyono, S. 2011. Free Radical Scavenging Activity Of (*Alsoephila glauca* J. Sm). *Majalah Obat Indonesia*. 16 (3) : 156 -160
- [4]. Satria D, Silalahi J, Haro G, Ilyas S, Poppy Anjelisa Z Hsb. 2017. Antioxidant and Antiproliferative Activities of an Ethylacetate Fraction of *Picria Fel-Terrae* Lour. Herbs. Asian Pac J Cancer Prev, 18(2), 399-403.
- [5]. Irianti, E, Ilyas,S., Rosidah, and Hutahaeen, S. 2017. Hsp70 Expression Profile in Preeclampsia Model of Pregnant Rat (*Rattus norvegicus*) after Giving the EVOO. IOP Conf. Ser.: Mater. Sci. Eng. 180 - 012161.
- [6]. Irianti, E., Ilyas, S., Hutahaen, S., Rosidah. 2018. The role of EVOO (extra virgin olive oil) in serum MDA concentration and blood pressure of pregnant mice (*Rattus norvegicus*) with pre-eclampsia. Research J. Pharm. and Tech, 11(3):1053-1057.
- [7]. Ilyas S, Tanjung RS, Thahira D, Wulandari J. 2018. Effectiveness of administration haramounting leaf (*Rhodymyrtus tomentosa*) as antioxidant in preventing the damage pancreas mice (*Mus musculus* L.) after exposure of electric cigarette smoke. IOP Journal of Physics : Conference Series 1116 - 052084: 1 -6.
- [8]. Situmorang PC, Ilyas S. 2018. Study of Preeclampsia in Placenta, Kidney, And Hepatic Dieases. Asian J Phamr res: 11(11). Situmorang PC and Ilyas S. 2018. Description of Testes

- Histology of *Mus musculus* after giving nano hebal *Rhodomirtus tomentosa* (Haramonting). Asian J Pharm Clin Res. 11(11)
- [9]. Geetha KM, Sridhar C, Murugan V. 2010. Antioxidant and Gastroprotective Activities of *Rhodomirtus tomentosa* (Ait.) Hassk. *International journal of Pharm Tech Research* 2(1): 283-291.
- [10]. Lavanya G, Voravuthikunchai, Supayang P, Towatana, Nongporn H. 2012. Acetone Extract from *Rhodomirtus tomentosa*: a Potent Natural Antioxidant. *Evidence-Based Complementary and alternative Medicine* 5 (1): 1-8.
- [11]. Ilyas S. 2018. The correlation of some of the heating of various palm oils to histologic and liver function of rats (*Rattus norvegicus*). IOP Conf. Series: Journal of Physics: Conf. Series 1116 - 052032.
- [12]. Irawati E. 2014. Hepatoprotective Effect of Kemunting (*Rhodomirtus tomentosa* (Aiton) Hassk) Leaves Extract Against Paracetamol- Induced Hepatotoxicity. Publication Paper. Tanjung Pura University.
- [13]. Prasetiawan E, Sabri E, Ilyas S. 2013. Histological Overview of Liver Mice (*Mus musculus* L.) DDW Strain After Administration of Andaliman Fruit N-Hexane Extract (*Zanthoxylum acanthopodium* DC.) During the Period of Pre-Implantation and Post Implantation.
- [14]. Braha MIA, 2003. Effect of 30-Day Percent Doses of Coffee on Winstar Mouse Liver Histology. [Final report]. Semarang: Diponegoro University.
- [15]. Ilyas, S., Hutahaeen, S., Irianti, D.E. 2018. Transforming growth factor expression (TGF- β) correlate with serum level of malondialdehyde (MDA) after EVOO administration in preclinical rat models of preeclampsia. IOP Conf. Ser.: Earth Environ. Sci. 130 - 012048.
- [16]. Masyithah C, Hadisahputra S, Ilyas S. 2015. Combinational effects of ethylacetate extract of *Zanthoxylum acanthopodium* DC. With doxorubicin MCF7 breast cancer cells. *Int.J. PharmTech Res.*, 7(4), 651-653.
- [17]. Ilyas S, Hutahaeen S, Nursal. 2016. Apoptosis overview of cerebellum Purkinje cell in mice (*Mus musculus* L.) after exposure to methanol extract of the seeds of bitter melon (*Momordica charantia*) and DMPA. *International Journal of Pharmtech Research*, 9(9): 444-449.
- [18]. Ilyas S, Lestari SW, Moeloek N, Asmarinah, Siregar NC. 2013. Induction of rat germ cell apoptosis by testosterone undecanoate and depot medroxyprogesterone acetate and correlation of apoptotic cells with sperm concentration. *Acta Med Indones-Indones J Intern Med*. 45(1), 32-37.
- [19]. Fajariyah.S. 2010. Synthetic Estrogen Delivery Effects (Diethylstilbestrol) on Hepar And Level Structure SGOT And SGPT In Mice (*Mus musculus*) Balb/C Female Strain. *Journal of Basic Science*. 11 :76-82.
- [20]. Lu FC, 1994. Basic Toxicology. Second Edition. Jakarta: University of Indonesia Press.
- [21]. Syahrizal, D. 2008. Effect of Vitamin C Protection on Transaminase Enzymes and Histopathological Overview of Liver of Mice Exposed to Plumbum. [Thesis]. Medan: Faculty of Medicine, University of North Sumatra.
- [22]. Hariyatmi, 2004. Ability of Vitamin E as an Antioxidant to Free Radicals in the Elderly. *MIPA* 14 (1): 54.
- [23]. Hasibuan R, Ilyas S, and Hannum, S. 2015. Effect of leaf extract Haramonting (*Rhodomirtus tomentosa*) to lower blood sugar levels in mice induced by alloxan. *International Journal of Pharmatech Research*. 8(6): 284-291.
- [24]. Sardini. S. 2007. Determination of SGOT and SGPT Enzyme Activity in Serum with Methods of Reaction of Enzymatic Kinetic in Accordance with IFCC (International Federation of Chemical Chemistry and Laboratory Medicine). Meeting Proceedings and Functional Scientific Presentation of Nuclear Technology Development.

- [25]. Masfria, Harahap U, Nasution MP, Ilyas S. 2014. Cytotoxic activity, proliferation inhibition and apoptosis induction of *Rhaphidophora pinnata* (L.F.) schott chloroform fraction to MCF-7 cell line. Int.J. PharmTech Res, 6(4), 1327-1333.
- [26] Situmorang, P., S. Ilyas. 2019. Description of Kidney Histology of *Mus musculus* After Giving Nano Herbal *Rhodomyrtus tomentosa* (Haramounting). International Journal of Ecophysiology Vol. 01, No. 01, 26–33.