IOP Conference Series: Materials Science and Engineering

PAPER • **OPEN ACCESS**

The formation of eyeball musculoskeletal stump using a Ni-Ti implant *in vivo*

To cite this article: E O Filippova *et al* 2019 *IOP Conf. Ser.: Mater. Sci. Eng.* **597** 012065

View the article online for updates and enhancements.

IOP ebooks™

Bringing you innovative digital publishing with leading voices to create your essential collection of books in STEM research.

Start exploring the collection - download the first chapter of every title for free.

This content was downloaded from IP address 106.110.68.45 on 20/09/2019 at 06:54

IOP Conf. Series: Materials Science and Engineering **597** (2019) 012065 doi:10.1088/1757-899X/597/1/012065

The formation of eyeball musculoskeletal stump using a Ni-Ti implant *in vivo*

E O Filippova[1,2], E A Gorbunova[2], O I Krivosheina[2] and N M Ivanova[1]
[1]Tomsk Polytechnic University, Lenin ave., 30, Tomsk, 634012, Russia
[2]Siberian State Medical University, Moskovskii tract, 2, Tomsk, 634012, Russia

E-mail: katerinabosix@mail.ru

Abstract. The purpose of this study is to investigate the possibility of forming an eyeball musculoskeletal stump using a Ni-Ti implant *in vivo*. Studies were performed on 18 Wistar rats. The animals were enucleated one of eyes. After the enucleation the musculoskeletal stump using Ni-Ti implant was formed. Ni-Ti implant was made from a thread of porous Ni-Ti (TN-10) with a thickness of 100 μm. Before implantation the Ni-Ti implant was sterilized by ethylene oxide. Results showed that the Ni-Ti implant surface was uniform and had not visible defects. The Ni-Ti implant surface was a hydrophobic with the mean value of $\theta = 93.5^{o} \pm 1.4$. The Ni-Ti implant in the eye orbit was mobile. The Ni-Ti implantation into the eye orbit contributed the connective tissue with blood vessels formation and insignificant leucocytes infiltration (macrophages and lymphocytes infiltration). The study showed the possibility of forming an eyeball musculoskeletal stump using a Ni-Ti implant.

1. Introduction

Removal of the eyeball due to severe pathological conditions of the eye is a frequent ophthalmology operation. It is a serious reconstructive surgery due to which there is a pronounced shortage of tissue volume. Consequently it is necessary to place an implant from a biocompatible material into the orbit [1]. There are a number of materials offered as an orbital implant.

Synthetic and biological implants for the formation of the musculoskeletal stump are known [2]. Biological materials include a cartilage and subcutaneous fatty tissue of the human sole. Synthetic materials include hydroxyapatite, porous polyethylene, carbon felt, polytetrafluoroethylene, etc. [3]. However, biological implants tend to dissolve over time. It is necessary to create a bank of such materials which is associated with significant material and labor costs [4]. The disadvantages of the synthetic materials implantation are the exposure and rejection of implants (from 4 to 38%), their deformation, and in some case the high price [5].

Wang J.K. et al. revealed that late complications during the implantation of bioceramic materials also arise after the evisceration. They proposed to cover the implant with a Vicryl mesh for the prevention of exposure, adding anteriorly with a scleral patch graft following enucleation with primary or secondary implantation [6].

Thus, natural and synthetic hydroxyapatites currently occupy a leading position among orbital implants. However, the disadvantages of hydroxyapatite implants are the complex implantation technique and its high price (from 600 to 800 dollars). Therefore, ophthalmologists from different countries are actively engaged in research and development of biocompatible synthetic porous materials.

The purpose of the study is to investigate the possibility of forming an eyeball musculoskeletal stump using a Ni-Ti implant *in vivo*.

Content from this work may be used under the terms of the Creative Commons Attribution 3.0 licence. Any further distribution of this work must maintain attribution to the author(s) and the title of the work, journal citation and DOI.
Published under licence by IOP Publishing Ltd

2. Material and methods

2.1. Ni-Ti implant

Ni-Ti implant was made from a thread of porous Ni-Ti (TN-10) with a thickness of 100 μm (TPU, Tomsk). The implant was round with a diameter of 4-5 mm (Figure 1).

Figure 1. The Ni-Ti implant.

2.2. Sterilization

The Ni-Ti implant was sterilized by ethylene oxide using the gas sterilizer Steri-Vac 3M (USA). The ethylene oxide concentration was 750 mg/l. The temperature was 37ºC. The sterilization time was 3 hours. The humidity was 70%.

2.3. The surface topography of the Ni-Ti implant

The surface topography was studied on the multipurpose correlator of optical, spectral and topographical surface objects properties "Centaur HR" (Russia). The surface roughness was estimated using the Gwyddion software. SEM of the Ni-Ti implant was obtained by using Hitachi S3400N Type II microscope (Japan).

2.4. The wetting angle of the Ni-Ti implant

The wetting angle for purified water and glycerol were calculated using the sessile drop technique with the room temperature of 25±2°C, the "KRÜSS EasyDrop DSA 20" device (Germany) and the special software, with the measurement accuracy of ± 0.1°.

2.5. Animals and treatments

18 pubescent male Wistar rats (SSMU, Tomsk, Russia) weighing 250 g were used. All animals were healthy and free of ocular diseases. All procedures were approved by the Siberian Medical State University Life Science Ethical Review Committee (protocol № 3898 from November 24th, 2014).

The animals after an enucleation were implanted the Ni-Ti implant. All animals were instilled Tobramycin Drops (6 times per day), 0.1% Diclofenac Sodium Ophthalmic Solution (3 times per day) and 0.05% Vitabact (4 times per day) in the postoperative period.

The overall duration of the experiment comprised 21 days. Such methods as visual check and photographic registration were also used in course of the experiment. Sampling was performed on days 7, 14, and 21 after the start of the experiment for morphology studying.

2.6. Histological processing specifics

The enucleated animal eyeballs were put into the Carnoy's fixative solution for 2 hours, in course of the preparation for the light microscopy. Sections of tissues were stained with hematoxylin and eosin, according to the method of Van-Gizona. Light microscopy of the slides was conducted with 200x and 400x zoom using LOMO Biolam AU-12 (Russia) microscope. The microscope has an integrated digital camera ICC50 with the USB interface.

2.7. Electron microscopy of tissues

The study of the cytology structure was performed by transmission electron microscopy. The tissue was fixed in a 2.5% solution of glutaraldehyde for 2 hours at a temperature of 4°C. Then it was washed twice with cacodylate buffer, was fixed in 1% solution of four osmium oxides (in 0.1 M cacodylate buffer) for 2 hours, and washed with cacodylate buffer again. Ultrathin tissue sections of 60–100 nm thick were prepared on an "Ultrotome III" ultratome (LKB, Sweden). The resulting sections were examined in a JEM-100 CXII electron microscope (JEOL, Japan) with an aperture diaphragm of 25–30 μm at an accelerating voltage of 80 kV.

2.8. Morphometric analysis

The morphometric analysis of corneal specimens was carried out in histological sections stained with hematoxylin and eosin. Light microscopy with Avtandilov's eyepiece graticule analyzed 30 visual fields at 400× in each specimen to determine the volume percent (v/v %) of blood vessels and number of cells (macrophages, lymphocytes, plasma cells, and granulocytes).

2.9. Statistical processing of the research results

Statistical package IBM SPSS Statistics 20 was used for the statistical processing of the obtained results. A Student's t-test for unpaired values was used to analyze statistical significance between four groups. The Kruskal–Wallis test was used for the quantitative data. The Fisher's exact test was used for the nominal data. The dynamics analysis was conducted using the Wilcoxon signed rank test, which is used when comparing the mean value of two paired tests. Values of $p < 0.05$ were considered to be statistically significant.

3. Results

3.1. The surface topography of the Ni-Ti implant

Surface analysis of the Ni-Ti implant showed that the surface was uniform and had not visible defects (pores, cracks, craters, etc.) and a bimodal distribution (Figure 2).

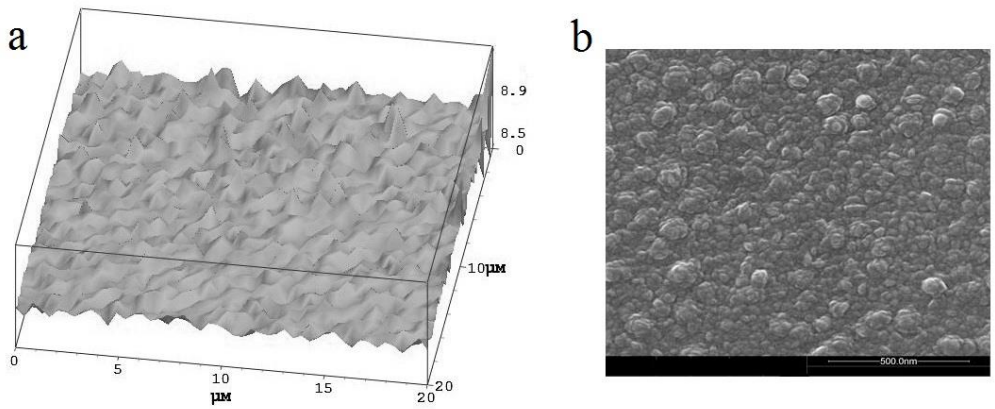

Figure 2. The surface topography of the Ni-Ti implant: a – AFM of implant surface; b - SEM of implant surface.

The surface roughness analysis showed that R_a of Ni-Ti implant surface was 35.0 ±5.4 nm, R_q was 42.1 ±6.2 nm, R_{sk} was 1.45. The ethylene oxide sterilization didn't influence on the surface roughness the Ni-Ti implant.

3.2. The wetting angle of the Ni-Ti implant

The measurement results of the wetting angle showed that the Ni-Ti implant surface was a hydrophobic with the mean value of $\theta = 93.5^{o} \pm 1.4$. The ethylene oxide sterilization didn't influence on the wetting angle of implant, the mean value of $\theta = 88.1^{o} \pm 6.0$.

3.3. Visual check

The conjunctival hyperemia of the eyelids and eye mucus discharge persisted on day 7 from the start of the experiment (Figure 3a). The Ni-Ti implant was round and mobile.

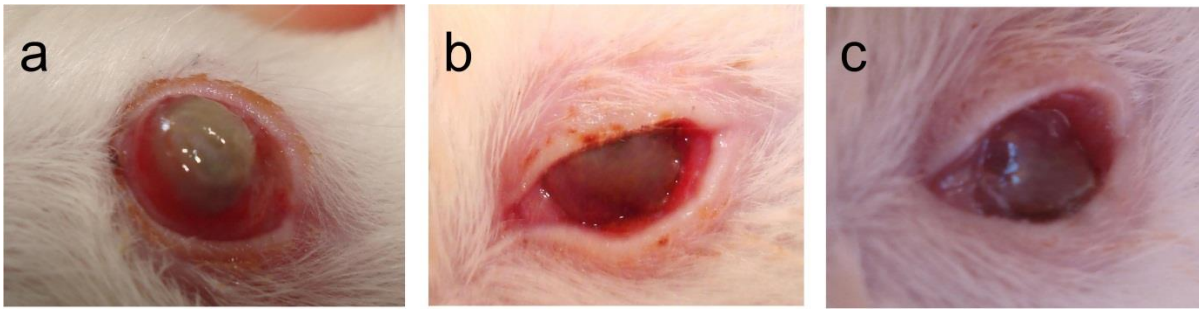

Figure 3. The visual check of eyes on day 7 (a), 14 (b) and 21 (c) from the start of the treatment.

The moderately pronounced conjunctival hyperemia persisted on day 14 from the start of the experiment. The Ni-Ti implant was round and mobile. The eye mucus discharge was absent (Figure 3b).

The moderately pronounced conjunctival hyperemia persisted on day 21 from the start of the experiment. The Ni-Ti implant was round and mobile. The eye mucus discharge was absent (Figure 3c).

3.4. Histology and electron microscopy results

The histology study showed the loose connective tissue with cells infiltration (macrophages, fibroblasts, lymphocytes, granulocytes) on day 7 from the start of the experiment (Figure 4a). Signs of lymphostasis were found in the lumen of the vessels.

The electron microscopy study showed that there were granulocytes (neutrophils) with di- and poly segmented nuclei and with many large lysosomes in the cytoplasm (Figure 4d). Macrophages with well-developed organelles (rough-surfaced endoplasmic reticulum with enlarged lumen cavities, mitochondria with normal structure) were encountered.

The eyeball cavity had the mature connective tissue with tightly arranged bundles of collagen fibers on day 14 from the start of the experiment (Figure 4b). Small areas of granulation tissue with a large number of newly formed vessels and diffuse cells infiltration (lymphocytes, monocytes, active fibroblasts, plasma cells) were observed between bundles of collagen fibers. The new formed blood vessels had thin walls.

Fibroblasts had the rough-surfaced endoplasmic reticulum, many ribosomes, mitochondrion with the destruction of the cristae and electron dense secretory granules. Euchromatin dominated in the nucleus of fibroblasts. The nucleolus was not visualized. The intercellular substance was determined around the fibroblasts where collagen fibrils were poorly ordered (Figure 4f).

The loose connective tissue was determined in the eyeball cavity on day 21 from the start of the experiment (Figure 4c). Collagen fibers were thin and randomly directed between which there were full-blooded arterioles, venules and cells (fibroblasts, macrophages, plasma cells and lymphocytes).

Cytoplasm fibroblasts had microvesicles, rough-surfaced endoplasmic reticulum with enlarged lumen cavities, mitochondrion. The fibroblast nucleus had also elongated shape. The euchromatin prevailed.

Endotheliocytes of the newly formed blood vessels had well-developed organelles (Figure 4g). An intercellular substance with a small number of thin collagen fibrils oriented randomly in different directions was found around blood vessels. Red blood cells were in the lumen of blood vessels.

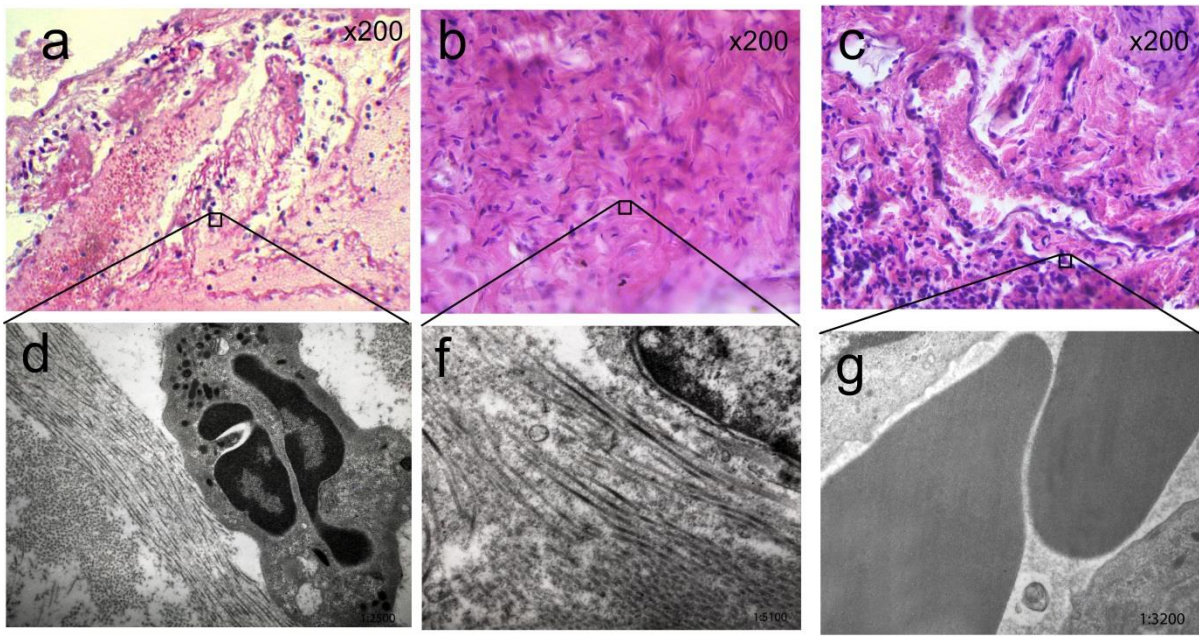

Figure 4. Histology tissue cross-sections (a, b, c) and electron microscopy pictures (d. f. g) on day 7 (a, d), 14 (b, f) and 21 (c, g) from the start of the treatment. Histology tissue cross-sections (a, b, c) are 200 magnification and hematoxylin and eosin stain.

3.5. Morphometric analysis

According the morphometric analysis the increasing of the cells infiltration of macrophages, lymphocytes and plasma cells were found on day 14 from the start of the experiment (Table 1). The number of granulocytes decreased by 2.5 times on day 14. It decreased by 7.6 times on day 21 from the initial value.

The statistically significant increasing of blood vessels number was noted on day 14 and day 21 day from the initial value (Table 1).

Table 1. Morphometric indicators of the eyeball musculoskeletal stump after Ni-Ti implantation.

	The day from the start of the experiment		
	7 day	14 day	21 day
Macrophages, cells	1078.8±191.9	2731.9±574.7*	985.7±264.9
Lymphocytes, cells	837.8±303.4	2012.1±353.3*	1034.9±297.9
Plasma cells, cells	147.9±75.3	295.7±131.4*	69.4±39.2*
Granulocytes, cells	342.3±207.5	135.9±95.9*	45.3±10.3*
Blood vessels (%)	0.02±0.014	2.4±1.2*	5.3±1.9*

Note: * - statistically significant differences according to the U test Mann-Whitney compared to the day 7.

The Ni-Ti implantation into the eye orbit contributes the connective tissue with blood vessels formation and leucocytes infiltration (macrophages and lymphocytes infiltration). The Ni-Ti implant into the eye orbit is mobile.

4. Conclusion

The surface of Ni-Ti implant is uniform and has not visible defects. The surface of Ni-Ti implant is a hydrophobic with the mean value of $\theta = 93.5^{o} \pm 1.4$. The Ni-Ti implant into the eye orbit is mobile. The implantation of Ni-Ti implant in the eye orbit contributes the connective tissue with blood vessels formation and insignificant leucocytes infiltration (macrophages and lymphocytes infiltration). The study showed the possibility of forming an eyeball musculoskeletal stump using a Ni-Ti implant.

Acknowledgments
This work was supported by the Ministry of Education and Science of the Russian Federation, the Federal Target Program (Agreement No. 14.575.21.0140, unique identifier RFMEFI57517X0140).

References
[1] Baino F, Potestio I 2016 *Mater. Sci. Eng. C. Mater. Biol. Appl*. **69** 1410
[2] Schellini S, Jorge E, Sousa R, Burroughs J, El-Dib R. 2016 *Orbit*. **35** (2) 78
[3] Perry A Adv. 1990 *Ophthalmic Plast. Reconstr. Surg*. **8** 75
[4] Feng K, Ying W 2017 *MATEC Web Conf.* **100** 04020
[5] Custer P L 2007 *Ophthalm. Plast. and Reconst. Surg*. **23** (1) 1
[6] Wang J-K, Lai P-C, Liao S L 2009 AJO. **147** (1) 162