PAPER • **OPEN ACCESS**

Comparative study between silk suture and metallic Staplers in skin wound closure in Rabbits

To cite this article: Zainab B. Abdulkareem *et al* 2019 *IOP Conf. Ser.: Mater. Sci. Eng.* **571** 012059

View the article online for updates and enhancements.



IOP ebooks™

Bringing you innovative digital publishing with leading voices to create your essential collection of books in STEM research.

Start exploring the collection - download the first chapter of every title for free.

This content was downloaded from IP address 171.35.163.4 on 19/09/2019 at 02:16

Comparative study between silk suture and metallic Staplers in skin wound closure in Rabbits

Zainab B. Abdulkareem, Luay A. Naeem and Mohammed M. Jassim
Department of Surgery and Obstetrics, College of Veterinary Medicine, University of Basrah, Basrah, Iraq

Abstract: This research aimed to compared between natural non-absorbable suture (silk) and metallic clips in skin wound closure , the result appeared that the use natural non-absorbable suture (silk) get the best result when closed the wound compared with staples. In view of this prospective study has been undertaken to highlight the outcomes of closure by clips and sutures with respect to speed of closure, cost effectiveness and postoperative wound dehiscence, acceptance of scar. It has been found that the use of silk in surgical wound closure gives faster speed of closure and better results.

Key words: Wounds, sutures, silk, metallic staplers, wound healing, rabbits.

1- Introduction:

Wound is the disruption of the cellular and anatomic continuity of a tissue [1]. Good wound management provides a minimal scar [15] . Wounds may be approximated with sutures, staples, clips, skin closure strips, or topical adhesives. Sutures are used to bring the edges of a wound in close apposition with least amount of scar [20] . Sutures initially provide the mechanical strength to seal the wound and protect it from pathogens [37] . Different suture materials and suture techniques are used and affect healing. Generally, monofilament non-absorbable suture materials are used with simple interrupted and horizontal mattress sutures for skin closure because they induce little foreign body response [36] .

Ideally, wound closure technique should provide skin apposition till healing occurs, prevent wound infection, provide equal strength throughout the length of the incision, have a good cosmetic result and should be easy and comfortable to use. An ideal wound closure material should be non-allergenic, easy to manufacture and use and cost effective [29] . As a general principle, the surgeon should use the finest atraumatic sutures that has adequate mechanical strength. The suture should be removed as early as possible to minimize scarring [18] .

Incisional wound alters the homeostatic state of the affected animal and trigger a sequence of events that constitutes four phases of wound healing [7], [27],[14] . In the acute inflammatory phase, the infiltrating phagocytes protect the wounded tissue from infection and remove damaged tissue [21] . The proliferative phase is characterized by the formation of granulation tissue, synthesis and deposition of collagen and matrix [24] .The remodeling/maturation phase is characterized by progressive alignment of collagen bundles. Scar modification during this phase adds further to the restoration of wound tensile strength [22] .

Content from this work may be used under the terms of the Creative Commons Attribution 3.0 licence. Any further distribution of this work must maintain attribution to the author(s) and the title of the work, journal citation and DOI.
Published under licence by IOP Publishing Ltd

The phases of wound healing are closely merged one into another without clear boundaries [10] . There were few studies concerning the effect of staplers suture on healing of cutaneous wound mainly in laboratory animals, Hence, this study was designed to compare between natural suture materials (silk) and application of staplers and their effect on wound healing based on clinico-histopathological observations.

2-Materials and Methods

2-1. Experimental animals:

Six apparently healthy adult rabbits of either sex were used for the experiment after ascertaining that they were free of any dermatological lesion. Rabbits were purchased from the local market. They were weighing 1.5-1.8 kg. and aged from 8-10 months. The rabbits were allocated randomly and equally into two groups (3rabits/group) .

2-2. Technique of skin wounding:

Rabbits do not need to be fasted, because they cannot vomit. Therefore, induction of anesthesia does not carry the same risk of aspiration as in dogs or cats. Rabbits do not need to be fasted, because they cannot vomit. Therefore, induction of anesthesia does not carry the same risk of aspiration as in dogs or cats.

Rabbits do not need to be fasted, because they cannot vomit. Therefore, induction of anesthesia does not carry the same risk of aspiration as in dogs or cats. The operative field [lateral abdominal wall] was prepared for aseptic surgical incisions. All rabbits were anesthetized with intramuscular injection of 5 mg/kg body weight from xylazine hydrochloride (xylo, Holland) as preanesthetic agents and 35 mg/kg body weight ketamine hydrochloride [Ketalar, Aspain] as general anesthetic agents [2] . The animals were restrained in lateral position and fixed to surgical table.

Under aseptic conditions linear full thickness skin incisions approximately 5 cm in length were created on the lateral abdominal wall (figure 1) . Bleeding was arrested by routine manner. In the first group, wounds were approximated with

While wounds of second (Staplers) group were closed with metallic staplers and are placed at a distance of 5mm from one another (figures 3and 4) . After compilation of the operation, The use of Elizabethan collars for all operated rabbits is important to prevent self-trauma to surgical wounds. Rabbits received broad spectrum antibiotic (penicillin- streptomycin) solution which was given IM., in a dose rate of 20000 IU and 10 mg/kg respectively for four consecutive days. Finally the skin silk stitches removed in a conventional way while staplers were taken-off using a stapler removal tool (fig. 5) at 10 days post-suturing. The animals were allowed free access to food and water *ad libitum*. A maintenance diet of both commercial feed pellets and fresh vegetables (carrot) were given.

2-3. Assessment of study parameters

2-3-1. Clinical assessment

The skin wounds were followed up on postoperative period which lasted for 21 days for clinical findings including; wound infection, hyperemia, sutures dehiscence, and swelling of the operative sites.

2-3-2. Microscopic assessment:

For microscopical examination, skin biopsies 1cm ^{3}from each experimental animal were taken on day 21 under light general anaesthesia and standard surgical procedure. Biopsies containing (dermis and epidermis) and including the operative line were excised carefully to avoid traumatization. The tissues were trimmed to the desirable size and fixed in 10% neutral buffered formalin, then dehydrated in a graded alcohol series, cleared with methyl benzoate, embedded in paraffin wax, sectioned at 5 μm thickness, and stained with hematoxylin and eosin H& E stain then mounted with cover slip and examined under light microscope .

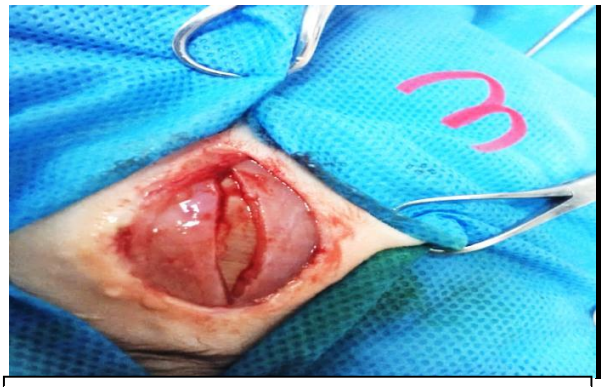

Fig. (1) Sharp longitudinal skin incision.



Fig. (2). Skin wound is closed with silk No.0)



Fig. (3) Show the skin Stapler



Fig. (4). Skin wound is closed with staples



Fig. (5). Skin staplers removal

3-Results:

3-1. Clinical observations:

All rabbits tolerated the surgical procedure well and were able to rise and stand immediately after compilation of the surgical operations. Following recovery from anesthesia, animals could drink water and consumed food without difficulty throughout the experiment. Operative time was short in stapler group when compared with silk group.

After a clinical follow-up of treated rabbits some health problems were noticed in both groups such as welling and hyperemia of the operative sites in the first three days with no significant difference in swelled areas of wounds sutured by silk or staple. Swelling started to subside gradually and dis-appeared earlier in staple group. The wounds of suture groups reflected infection represent by serous discharge, exudation and wound dehiscence with the incision line. Furthermore there were prominent eversion, sloughing and strangulated of the cutting wound edges with prominent scar tissue formation on the wound surface resulting in uneventfully and delaying of wound healing process in this group (required about 14 days) to heal. In contrast all skin wounds related to stapler group healed in the recommended time with no bleeding, or signs of infection or surgical wound dehiscence. Skin wounds approximation reflected good cosmetic appearance with fewer staples lesion marks in addition to decrease the thickness of skin cutting edges. This study revealed visible suture marks in wounds closed with silk these. On other hand these marks disappeared gradually in wounds closed with staplers (less prominent suture marks) .

Fair to good healing was observed in wounds sutured with silk. In contrast, all wounds closed with staplers, maintained excellent healing score and marked improvement was noted within 24 hours and all signs of inflammation had resolved by the 7th day of treatment.

3-2. Histopathological Findings:

Histopathological changes of the present study at day 21 post-wounding showed that suture group expressed accumulation of inflammatory containing polymorphic nuclear leukocytes mainly neutrophils and macrophage and prominent scar tissue formation (Fig.6 A and B) . In stapler group and at the same period, the main findings at this time were the presence of dermal appendages such as (hair follicles and sebaceous glands) in addition to formation of keratin

layer (Fig.7 A and B) . This result means that healing process was complete and better in staple group when compared with suture group.

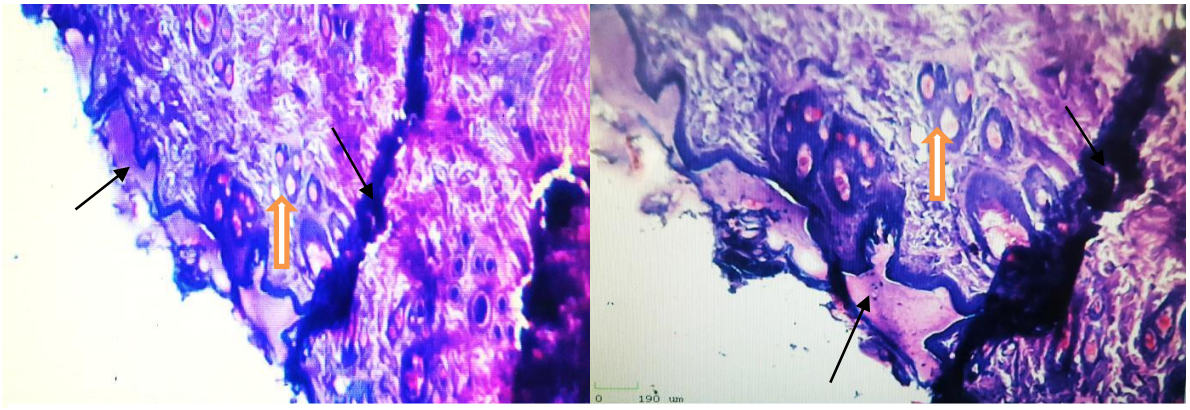

Figure 6 A and B: Histopathological section of wound in silk group, 21 days post-treatment show, line of healing with little hair follicle (orange arrow)and keratin (black arrows) (H &E 10X).

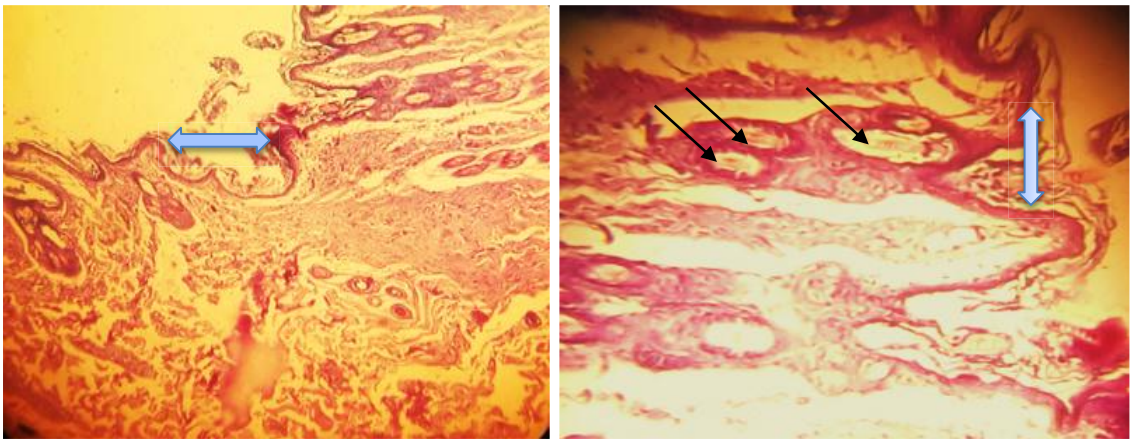

Figure 7. A and B: Histopathological section of wound of stapler group, 21 days post-treatment show, formation of hair follicles with sebaceous glands (black arrows) and keratin (blue arrows) (H &E 10X) .

4-Discussion:

4-1.Clinical observation:

According to the present study, swelling were noticed in both groups, this may be ascribed to inflammation (swelling considered one of cardinal signs of inflammation) . It subsided gradually with the advancement of experimental time in association with degree of inflammation. Infection was seen in the wound sites which was severe in silk group that cause wound dehiscence while infection was mild in staple groups and disappeared in a short time. This indicates the development of an inflammatory reaction against these materials. This

situation was further confirmed by the observation of hyperemia around some wound sites and this come in accordance with Servet [35] .

Suture materials affect healing through their interaction with tissue and the diameter and length of suture, its physical construction and its chemical composition are also considered to influence healing [6] . Silk exhibits high capillarity, which increases the risk of infection. Its fibers hold blood which is an excellent medium for bacterial proliferation. Silk has been shown to wick bacteria into a wound, and significant tissue reactions are observed in many species [8] . Kudur *et al*. [19] suggest that silk should not be used when the cosmetic appearance is important.

Wound infections in suture group are more liable to occur in surgical wounds. The chances of infection increase as the wounds become more contaminated. The clean surgical cases are less likely to get infected i.e. 1-2%. Infections due to surgical procedures are generally referred as surgical site infections (SSIs) [23] . Wound infections are associated with significant morbidity and mortality. It is estimated that over half of these SSIs are preventable [5] . These infections range from a minor wound discharge to life threatening sepsis and septic shock. Sutures like polypropylene are monofilament and relatively inert. These are associated with less chances of infection. Breaded sutures like silk are more prone to introduce infection. Metallic skin staples are made from stainless steel and are easy to place. Infection rates may be reduced due to staplers because of quick closure and inertness of the material [30] . Now a days most of the skin staplers are made from stainless steel but absorbable staplers also were used occasionally. In animal models, inflammatory response was minimum with absorbable staples [12] .

Redrobe [33] indicated that wound infection is usually due to self-inflicted wound trauma. It can be prevented with gentle preparation of the surgical site, atraumatic tissue handling, wound closure by opposing edges correctly and with no tension, minimally reactive suture materials, and perioperative local anesthesia

Skin closure is the final step in restoring mechanical defense against microorganism invasion after surgical procedure. Skin closure material and methods show some differences in wound infection, wound pain and healing rates. Obesity, diabetes and previous radiation exposure increase the chance of wound infections [26] .

4-2.Histopathological findings:

The histopathological appearance of the wounds in current study were similar to many

researches correlated with wound healing [11], [31],[28] . The suture group revealed inflammatory cells, this may be due to the fact that when skin is wounded, blood comes in contact with collagen, triggering blood platelets to begin secreting inflammatory factors also platelets express sticky glycoproteins on their cell membranes that allow them to aggregate, forming a mass. These idea was in consistent with Baum and Arpey [3] who found that fibrin deposition play role in preventing hemorrhage in addition fibrin and fibronectin cross-link together and form a plug that traps proteins and particles and prevents further blood loss.

Upon tissue injury, the disruption in the epidermal barrier causes the underlying keratinocytes to release a pre-stored inflammatory mediator like histamine, serotonin and interleukin-1. This inflammatory mediator is the first signal that alerts the surrounding cells to damage. Concurrently, blood components are released into the wound site initiating the clotting cascade. Platelets de-granulate releasing alpha granules, which secrete growth factors such as epidermal growth factor, platelet derived growth factor and transforming growth factor [32]. The interleukin 1 is pro-inflammatory cytokine that play an important role in attracting neutrophils to the wound site to remove harmful foreign bodies. The transforming growth factor-β works at the site of injury to convert monocytes into macrophages which play a key role in granulation tissue development [34]. Histopathological changes of the present study at day 21 post-wounding showed that the silk group expressed complete healing process but the healing process in the stapler group was better than those in the silk group, these result may indicate that the maturation phase is started early in the stapler group. The complete healing of the incision in the staple group at this time associated with normal epidermal layer and dermal appendages such as hair follicles and sweat glands which were clearly shown in the microscopical sections of the current study and these findings were noticed by Miller *et al.* [25] and Jahoda and Reynolds [16] in pigs.

During remodeling/maturation phase, collagen type III , which is prevalent during proliferation, is replaced by collagen type I [9] . The onset of the maturation phase may vary extensively, depending on the size of the wound and whether it was initially closed or left opened, ranging from approximately 3 days to 3 weeks [13] . The maturation phase can last for a year or longer, similarly depending on wound type. As the phase progresses, the tensile strength of the wound increases [17],[1] .

5- References:

[1] Abdul-Basit, S.; Habib A.; Sohaib, H.; Yasir M.; Fazal H. (2018) . To Compare Outcomes of Stainless Skin Staples and Polypropylene Sutures for Skin Closure in Clean Elective Surgeries. Isra. Med. J. 10 (1) :32-35.

[2] Barter, L. S. (2011) . Rabbit analgesia. Vet. Clin. North Am. Exot. Anim. Pract., 14(1) :93–104.

[3] Baum, C. L. and Arpey CJ. (2005) . Normal cutaneous wound healing: clinical correlation with cellular and molecular events. Dermatol. Surg.,31:674-686.

[4] Bennett, R. G. (1988) . Selection of wound closure materials. Am. Academy of Dermatology, 18: 619-637.

[5] Berrios-Torres, S. I, Umscheid, C.A.; Bratzler, D.W. and Kelz, R. R. (2017) . Centers for Disease Control and Prevention Guideline for the Prevention of Surgical Site Infection. J. Am. Med. Surg., 152(8) :784-791.

[6] Boothe, H.W. (1998) . Selecting suture materials for small animal surgery. Compendium Continental Educ. and Pract. in Veterinary, 20: 155-162.

[7] Braiman- Wilesma, L.; Solomonir, I. and Tennenbum, T. (2007) . Novel Insights into Wound Healing Sequence of Events. J. Toxicol. Pathol., 34: 767-779.

[9] DeNardo, G. A.; Brown, N.; Trenkabetha, S. and Marretta, S. (1996) . Comparison of seven different suture materials in the feline oral cavity. J. of Am. Anim. Hosp. Associ., 32 164-172.

[10] Diegelmann, R. (2003) . Analysis of collagen synthesis. Methods Mol. Med., 78: 349-353.

[11] Diegelmann, R.F. and Evans, M.C. (2004) . Wound healing: an overview of acute, fibrotic and delayed healing. Front Biosci., 9:283-289.

[12] Eming, S. A.; Martin, P. and Tomic-Canic, M. (2014) . Wound repair and regeneration: mechanisms, signaling, and translation. Sci. Trans. Med., 6: 265-266.

[13] Fick, J. L.; Novo, R. E. and Kirchhof, N. (2005) . Comparison of gross and histologic tissue responses of skin incisions closed by use of absorbable sub-cuticular staplers,

cutaneous metal staplers, and polyglactin 910 suture in pigs. Am. J. Vet. Res., 84(11) :66-70.

[14] Finnson, K.W.; McLean, S.; di Guglielmo, G.M. and Philip, A. (2013) . Dynamics of Transforming Growth Factor Beta Signaling in Wound Healing and Scarring. Adv. Wound Care. 2: 195–214.

[15] Forbes, S.J. and Rosenthal, N. (2014) . Preparing the Ground for Tissue Regeneration from Mechanism to Therapy. Nat. Med., 20: 857-869.

[16] Hollander, J. E. and Singer, A. J. (1999) . Laceration management. Ann. Emergency of Med., 34: 356-361.

[17] Jahoda, C.A. and Reynolds, A.J. (2001) . Hair follicle dermal sheath cells: unsung participants in wound healing. Lancet, 358:1445–1448.

[18] Jimi, S.; de Francesco, F.; Ferraro, G.A.; Riccio, M. and Hara, S. A. (2017) . Novel Skin Splint for Accurately Mapping Dermal Remodeling and Epithelialization During Wound Healing. J. Cell Physiol., 232: 1225-1232.

[19] Karbhari, S. and Bhavikatti, A. (2012) . Study of skin staples and conventional suture for abdominal skin wound closure. I.J.B.A.R., 3(7) :79-84.

[20] Kudur, M. H.; Pai, S. B.; Sripathi, H. and Prabhu, S. (2009) . Sutures and suturing techniques in skin closure. Indian J. of Dermatology,75:425-434.

[21] Kumar A, (2002) . A suture material and techniques by Tyagi RPS, Singh J, In Ruminant surgery 6th Ed. CBS Publishers and Distributors New Delhi- 59-73.

[22] Li, Y.B.; Shi, Y.; Zhang, W. and Wen, Z. (2012) . Roles of Macrophages and Neutrophils During Regeneration. J.B.C., 287(30) : 25353–25360.

[23] Lindley, L. E.; Stojadinovic, O.; Pastar, I.; Tomic-Canic, M. (2016) . Biology and Biomarkers for Wound Healing. Plast. Reconstr. Surg.,138: 18−28.

[24] Mackeen, A. D.; Schuster, M. and Berghella, V. (2015) . Suture versus staplers for skin closure after C.S. Am. J. Obstet. Gynecol., 212(5) : 1-10.

[25] Midwood, K. S.; Williams, L. V. and Schwarzbauer, J. E. (2004) . Tissue repair and the dynamics of the extracellular matrix. Int. J. Biochem. Cell Biol., 36:1031−1037.

[26] Miller S.J.; Burke, E.M.; Rader, M.D. and Lavker RM. (1998) . Re-epithelialization of porcine skin by the sweat apparatus. J. Invest. Dermatol., 110: 13-19.

[27] Moore, D. C.; Sellers, M. H.; Archer, K. R. and Holt, G. E. (2013) .Staples equal sutures for skin closure. Clin. Orthop. Relat. Res., 471(3) :899-904.

[28] Nawaz, Z. and Bentley, G. (2011) : Surgical Incisions and Principles of Wound Healing. Surgery, 29 (2) : 59-62.

[29] Olaifa, A. K and Adeyemi, I. M. (2017) . Epidermal Wound Contraction Rates on Different Parts of the Body of West African Dwarf Goats. J. Vet. Med. and Surgery. 1 (1) : 7-13.

[30] Orlinsky, M.; Goldberg, R.M. and Chan L (1995) . Cost analysis of stapling versus suturing for skin closure. Am. J. Emerg. Med., 13(1) :77-81.

[32] Oswal, S.; Borle, R.; Bhola, N.; Jadhav, A. and Surana S. (2017) . Surgical Staples: A Superior Alternative to Sutures for Skin Closure After Neck Dissection-A Single-Blinded Prospective Randomized Clinical Study. J. Oral Maxillofac. Surg., 75(12) :27-36.

[32] Pereira, R. F. and Bartolo, P. J. (2016) . Traditional therapies for skin wound healing. Adv. wound care, 5: 208−229.

[33] Pierce, G.; Mustoe, T., Altrock, B. (1991) . Role of platelet derived growth factor in wound healing. J. Cell Biochem., 45: 319-323.

[34] Redrobe, S. (2002) . Soft tissue surgery of rabbits and rodents. Semin Avian Exot. Pet., 11:231-245.

[35] Schultz, G.S. and Wysocki, A. (2009) . Interactions between extracellular matrix and growth factors in wound healing. Wound Repair and Regeneration, 17(2) :153-162.

[36] Servet, K. (2002) . Comparison of the Effects of Some Wound Healing Materials on Full Thickness Skin Wounds in Rabbits. Turk. J. Vet. Anim. Sci., 26: 263-272.

[37] Smeak, D. D. (1992) . Buried continuous intradermal suture closure. Compendium Continental Education and Practice in Veterinary, 14: 907-919.

[38] Yang, C. S.; Yeh, C. H.; Chen, M. Y. and Jiang, C.H. (2009) . Mechanical evaluation of the influence of different suture methods on temporal skin healing. J. of Dermatological Surgery,35 1880-1885.