

PAPER • OPEN ACCESS

## Toxic Effect of Aflatoxin B1 on Heart, Lung, and Testis of Male Albino Rats: Histopathology Study

To cite this article: Alia M. Kudayer *et al* 2019 *IOP Conf. Ser.: Mater. Sci. Eng.* **571** 012055

View the [article online](#) for updates and enhancements.



**IOP | ebooks™**

Bringing you innovative digital publishing with leading voices to create your essential collection of books in STEM research.

Start exploring the collection - download the first chapter of every title for free.

## Toxic Effect of Aflatoxin B1 on Heart, Lung, and Testis of Male Albino Rats: Histopathology Study

**Alia M. Kudayer,**

Anatomy and Histology Department, Veterinary Medicine College, University of Basrah, Iraq.

**Alaa T.A. Alsandaqchi**<sup>(a)</sup>

Veterinary Public Health Department, Veterinary Medicine College, University of Basrah, Iraq.

**Faleah M. Saleh**

Food Science Department, Agricultural College, University of Basrah, Iraq.

**Nawras A. Alwan**

Physiology, Pharmacology and Biochemistry Department, Veterinary Medicine College,  
University of Basrah, Iraq

<sup>(a)</sup> Corresponding author: [alaa\\_tariq2001@yahoo.com](mailto:alaa_tariq2001@yahoo.com)

**Abstract:** The current study was carried out to investigate the toxic effects of aflatoxin B1 exposure on heart, lung, and testis of male Albino rats. Twelve healthy male Albino rats were used in the current study. They were divided equally into 2 groups (control and treated groups). The treated group was given aflatoxin B1 orally by a gastric tube at concentration 0.5 mg per kg of body weight for 7 day. The control group was given distilled water alone. At the end of experiment (1 week), the rats were killed under ether anesthesia and the internal organs (heart, lung, and testis) were collected immediately for histological examination. The histopathology examination in heart revealed that there is oedema between myocardial. In lung, there is a large number of inflammatory cells and dilated the alveolar sac with exudates. The testis revealed the excessive vacuolated cells and suppression spermatogenesis. In conclusion, oral dose of aflatoxin B1 exposure could induce a deleterious effect on the histological structure of the heart, lung, and testis of male Albino rats. High level of attention must be taken to prevent the possible contamination of our food with aflatoxin B1.

**1.Introduction:** Aflatoxin is a mycotoxin produced by two types of *Aspergillus* includes *Aspergillus flavus* and *Aspergillus parasiticus*. Mycotoxin produced by *A. flavus* is most often found when certain grains such as wheat, corn, beans, and rice are grown under stressful conditions such as high moisture and temperature, but it can also be found on harvested grains if the grains are stored damp [1]. Aflatoxin can also be found in milk, eggs, and meat products when ruminants fed on contaminated foods [2]. It can cause aflatoxicosis in domestic animals and humans in developing than they are in developed countries [3]. Its importance was first recorded in 1960 in the United Kingdom when 100,000 turkeys and other poultry died in a single event. The cause of this was the bird's fed on ground nut meal contaminated with aflatoxin B1 [3].



In animals, aflatoxicosis causes liver damage, reduced milk and egg production, and susceptible to the infection of harmful microorganisms as a result of immunity suppression (e.g. salmonellosis) [4]. New borne animals might affect as a result of the alteration of aflatoxin B1 to the metabolite aflatoxin M1 excreted in milk of dairy cattle. Cattle are more susceptible to aflatoxicosis than sheep and horses, but outbreak occurs mostly in sheep [4].

In humans, aflatoxicosis causes gastrointestinal dysfunction, anemia, and reduced fertility [4,5]. There are different types of aflatoxin mycotoxins. *A. flavus* produce only aflatoxins B1 and B2, whereas *A. parasiticus* produce aflatoxins B1, B2, G1, and G2 [6]. Aflatoxin B1 is the most common aflatoxin, as well as the most toxic effect in humans and carcinogenic effect in susceptible laboratory animals[6]. Due to its carcinogenic effect, contamination of grains, milk and dairy products with aflatoxin may pose a risk for consumers. Hence, it is considered a public health concern. This work aimed to study toxicity effect of B1 on heart, lung, and testis of male Albino rats.

## 2. Material and Methods

### 2.1 Experimental Design

The study was carried out on 12 male of albino rats (100-150g). They were kept in standard cages for 2 weeks at 23-25 °C temperature under 12 h light-dark cycles for adaptation before beginning the experiment. All experimental animals fed balanced diet (Lipton India Ltd., Calcutta) and water during the period of experiment. Experimental animals were divided equally into 2 groups (control and treated groups). The treated group was given aflatoxin B1 orally by a gastric tube at concentration 0.5 mg per kg of body weight for 7 days [7]. The control group was given distilled water alone. At the end of experiment (1 week), the rats were killed under ether anesthesia. Then, the heart, lung, and testis were immediately isolated and kept in 10% formalin for 24 h at room temperature. Prior to paraffin embedding, specimens were removed from the buffered-formalin and processed through a graded series of ethanol and xylene. After that, specimens were embedded in paraffin, sectioned at the thickness of 5 microns using rotary microtome, mounted on slide, and stained with haematoxyline-eosin [8]. Slides were then examined under light microscope (Olympus) to detect and describe any histopathological changes in heart, lung, and testis on male albino rats induced by aflatoxin B1.

### 2.2 Chemicals:

Aflatoxin B1 was obtained from Sigma Chemical Company (Sigma Aldrich,USA).

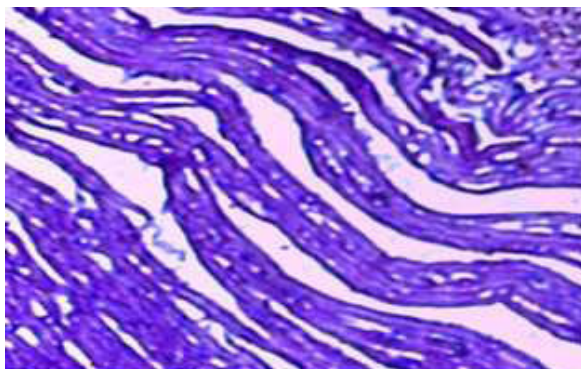
### 2.3 Histopathology:

Histopathological changes in heart, lung, and testis were examined.

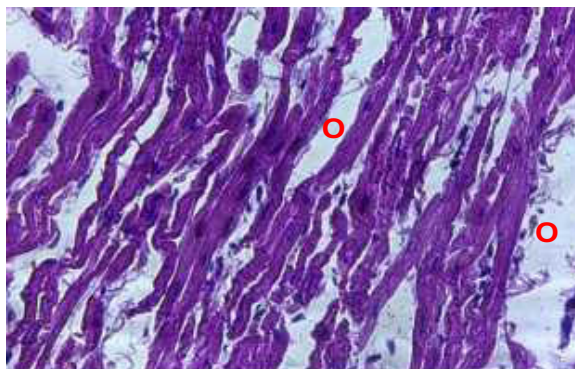
## 3. Results

The present study revealed the effect of aflatoxin B1 on male of albino rats; where, on the heart, there was oedema between myocardial muscles cells (figure 2) compared with control (figure 1); on the lung revealed a large number of inflammatory cells and dilated the alveolar sac with

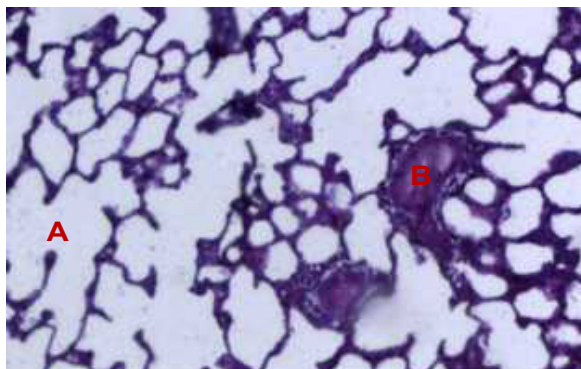
exudates (figure 4) compared with control (figure 3); and on the testis, there were excessive vacuolated cells, in addition, suppression of spermatogenesis (figure 6) was revealed compared with control (figure 5).



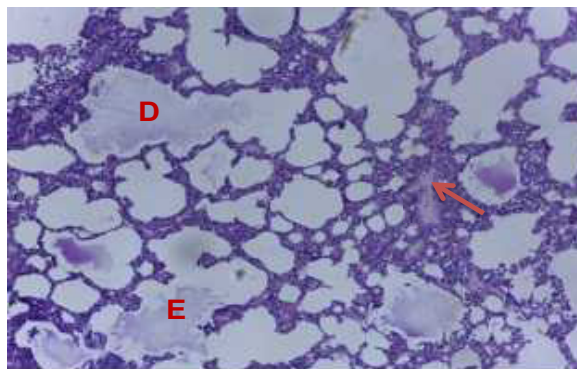
**Fig 1:** Longitudinal section in heart of control group showing the normal myocardial muscle cells .10x



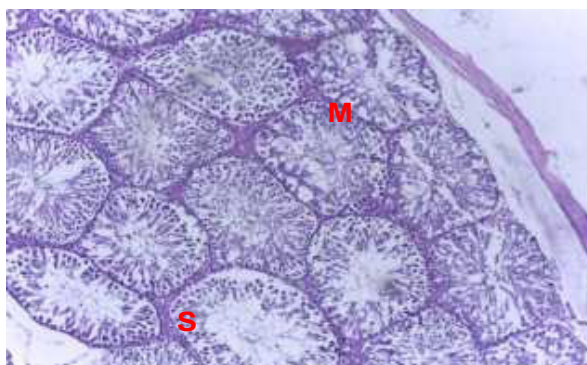
**Fig 2:** Longitudinal section in heart of treated group with AFB1 showing the Interstitial odema (O between myocardial muscle cells. 10x



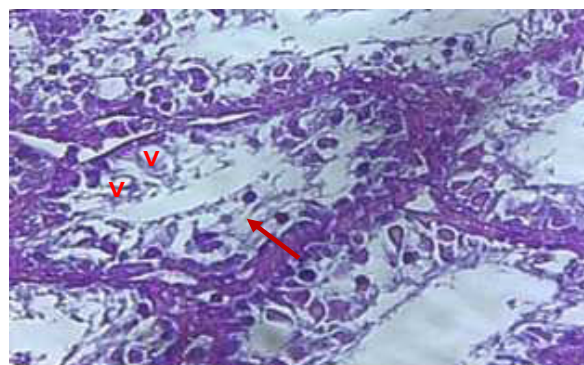
**Fig 3:** Cross section in lung of control group showing normal bronchioles (B) and alveolar sac (A) .10x



**Fig 4:** Cross section in lung of treated group with AFB1 showing dilated of alveolar sac (D) with exudates (E) and inflammatory cells (arrow).10x



**Fig 5:** Cross section of testes in control group Showing normal basement membrane cells (M) with different stage of spermatogenesis(S).



**Fig 6:** Cross section in testes of treated group with AFB1 showing the vacuolated cells (V) and suppression of spermatogenesis (arrow)

**4. Discussion:** The present study revealed the effect of aflatoxin B1 on heart, lung, and testis tissues of male albino rats. Aflatoxins are highly liposoluble compounds absorbed by the blood stream from the gastrointestinal and respiratory tracts [9]. The histopathology study of heart tissue revealed the presence of major change in myocardial fibers which characterized by distribution of oedema between the myocardial fibers. This finding is in agreement with previous studies; where, aflatoxins have serious influences on the cardiovascular system including heart damage [9,10].

In the lung, the current histopathology study revealed a large number of inflammatory cells and dilated the alveolar sac with exudates. This finding is in agreement with previous studies, in which aflatoxins have serious unwanted influences on the respiratory system of rat and human [11,12, 13]. It has been reported that many people working in food industries get exposed to aflatoxin B1 when they in hale dusts contaminated with aflatoxin during grain shelling and processing [13]. The aflatoxin may be converted to active metabolites in the nasal mucosa [14]. Furthermore, aflatoxin B1 was reported to induce pathological alteration in the form of pulmonary adenomas and lung cancers [15]. The susceptibility of the lung to aflatoxin B1 toxicity may be low capacity for glutathione S-transferase-catalyzed detoxification of bio-activated aflatoxin B1 in lung [16].

Concerning the effect of aflatoxin B1 on the testis, this histopathology study revealed that there was an excessive vacuolated cell and a suppression of spermatogenesis process. This finding is in agreement with previous studies, in which aflatoxins have serious unwanted effects on the reproductive system [17, 18]. Moreover, authors reported that aflatoxin B1 may be toxic to the male of reproductive system in wild, domestic animals, and human. It has been found that there is a reduce in the leydig cells, spermatogenesis, spermatocytes, and spermatids [17]. Furthermore, aflatoxin B1 was reported to induce pathological alteration in testis and epididymis in the form of the degeneration and necrosis the lining epithelium of seminiferous tubules [18,19]. Aflatoxin B1 was also reported to induce pathological alteration in sperm mitochondrial and extrusion of outer dense fibres [20]. Infertility problem could develop from aflatoxin B1 consumption due to increase sperm cells morphologic abnormalities and reduce sperm cells count, viability, and mortality.



**5.Conclusion:** The present study concluded that oral dose of aflatoxin B1 exposure could induce a deleterious effect on the histological structure of the heart, lung, and testis of male Albino rats. High level of attention must be paid to prevent the possible contamination of our food with aflatoxin B1.

### References:

- [1] Algül I. & Kara D. Determination and chemometric evaluation of total aflatoxin, aflatoxin B1, ochratoxin A and heavy metals content in corn flours from Turkey. *Food Chem.* vol. 157, pp. 70–76, 2014.
- [2] Dawit G., Barbara S., Tegegne A., Hanson J. & Grace D. Aflatoxin contamination of milk and dairy feeds in the Greater Addis Ababa milk shed, Ethiopia. *Food Control.* vol. 59, pp. 773–779, 2016.
- [3] Monson M., Coulombe R. & Reed K. Aflatoxicosis: Lessons from toxicity and responses to Aflatoxin B1 in poultry, *Agriculture.* vol. 5, no. 3, pp. 742–777, 2015.
- [4] Dhanasekaran D., Shanmugapriya S., Thajuddin N. & Panneerselvam A. Aflatoxins and Aflatoxicosis in Human and Animals. *Aflatoxins - Biochemistry and Molecular Biology*, pp 222-245, 2011.
- [5] Nurul A.Z. & Mohd R. S. Effect of dietary macronutrients on aflatoxicosis: a mini-review. *Journal of the Science of Food and Agriculture.* vol. 97, no. 8. pp. 2277–2281, 2017.
- [6] Mtimet N., Walke M., Baker D., Lindahl J., Hartmann M. & Grace D. Kenyan awareness of aflatoxin: An analysis of processed milk consumers. Poster presented at the 29th International Conference of Agricultural Economists (ICAE), Milan, Italy, 8-14 August. Nairobi: ILR, 2015
- [7] Yilmaz S., Kaya E., Karaca A. & Karatas O. Aflatoxin B1 induced renal and cardiac damage in rats: Protective effect of lycopene. *Res Vet Sci.* 119:268-275, 2018.
- [8] Corrin B. Carleton's Histological Technique. *J. Clin. Pathol.* vol. 34, no. 5, pp. 572–572, 1981.
- [9] Gursoy N., Durmus N., Bagcivan I., Sarac B., Parlak A., Yildirim S. & Kaya T. Changes in spontaneous contractions of rat ileum by aflatoxin in vitro. *Food Chemistry and Toxicology.* 46(6): 2124-2127, 2008
- [10] Wangikar P.B., Dwivedi P., Sinha N., Sharma A.K. & Telang A.G. Teratogenic effects in rabbits of simultaneous exposure to ochratoxin A and aflatoxin B1 with special reference to microscopic effects. *Toxicology*, 215, 37-47, 2005.
- [11] Lee R. J., Workman A. D., Carey R. M., Chen B., Rosen P. L., Doghramji L. & Cohen N. A. Fungal Aflatoxins Reduce Respiratory Mucosal Ciliary Function. *Scientific Reports*, 6, 33221, 2016.
- [12] Massey T.E., Smith G. B. & Tam A. S. Mechanisms of aflatoxin B1 lung tumorigenesis. *Experimental lung research.* 26, 673–683, 2000.
- [13] Larsson P. & Tjälve H. Intranasal instillation of aflatoxin B1 in rats: Bioactivation in the nasal mucosa and neuronal transport to the olfactory bulb. *Toxicol. Sci.*, 55, 383-391, 2000.

- [14] Larsson P.& Tjalve H. Intranasal instillation of Aflatoxin B1 in rats: Bioactivation in the nasal mucosa and neuronal transport to the olfactory bulb. *Toxicological Science*. 55, 383-391,2000.
- [15] Roger A. & Coulombe Jr. Nonhepatic disposition and effects of aflatoxin B1. *The Toxicology of Aflatoxins: Human Health, Veterinary and Agricultural Significance*, New York: Academic Press. p89-101,1994.
- [16] Stewart R.K., Serabjit-Singh C.J. & Massey T.E. Glutathione S-transferase-catalyzed conjugation of bioactivated aflatoxin B1 in rabbit lung and liver. *Toxicol Appl Pharmacol*. 140(2):499-507,1996.
- [17] Nair A. & Verma R.J. Effect of aflatoxin on histoarchitecture of testis of male mouse and its amelioration by vitamin E. *Indian J. Toxicol.*, 114: 452-462,2000.
- [18] Abeer F., Shaima A. & Shaima A. Toxicity Effect of Aflatoxin B1 on Reproductive System of Albino Male Rats. *Pakistan Journal of Biological Sciences*. 18: 107-114,2015.
- [19] El-Shewy E.A & Ebrahim M.F. Ameliorative effect of vitamin E against the toxicity of aflatoxin B1 on rats with special reference to its effect on male fertility. *Proceedings of the 1st Annual Conference FVM, Moshtohor*, pp: 189-214,2004.
- [20] Faisal K., Periasamy VS., Sahabudeen S., Radha A., Anandhi R. & Akbarsha MA. . Spermatotoxic effect of aflatoxin B1 in rat: extrusion of outer dense fibres and associated axonemal microtubule doublets of sperm flagellum. *Reproduction*, 135(3):303-10, 2008.