



University
of Glasgow

Gutierrez-Quintana, Rodrigo (2012) *Factors affecting the prognosis following thoracolumbar spinal cord disease in the dog.*

MVM(R) thesis

<http://theses.gla.ac.uk/3540/>

Copyright and moral rights for this thesis are retained by the author

A copy can be downloaded for personal non-commercial research or study, without prior permission or charge

This thesis cannot be reproduced or quoted extensively from without first obtaining permission in writing from the Author

The content must not be changed in any way or sold commercially in any format or medium without the formal permission of the Author

When referring to this work, full bibliographic details including the author, title, awarding institution and date of the thesis must be given

FACTORS AFFECTING THE PROGNOSIS FOLLOWING THORACOLUMBAR SPINAL CORD DISEASE IN THE DOG

**Rodrigo Gutierrez Quintana
MVZ**

**Submitted in fulfilment of the requirement for the Degree of Master in
Veterinary Medicine**

**University of Glasgow
School of Veterinary Medicine**

July 2012

SUMMARY

Thoracolumbar spinal cord disease is common in dogs, with numerous processes affecting the T3 to L3 spinal cord segments. Being able to accurately predict the outcome is of critical importance for clinicians and owners, in order to inform the clinical decision making process. A large number of variables, including the signalment, findings of the clinical examination, the choice of diagnostic techniques and choice of therapy could potentially have an influence on the outcome. Although there are a large number of reports detailing the use of magnetic resonance imaging (MRI) in the investigation of canine thoracolumbar spinal diseases, little is known about the historic trends in the choice of imaging technique for investigating thoracolumbar spinal cord diseases in dogs and whether this altered choice has affected prognosis. In Chapter III, I demonstrate that the choice of myelography or MRI as diagnostic imaging modality does not significantly affect either the grade or speed of recovery in dogs with thoracolumbar spinal cord diseases. I also describe that the historical trend has been for MRI to progressively replace other diagnostic imaging techniques for investigation of spinal cord diseases. The age and weight of the patient on presentation are two variables that are easy to obtain and could have an influence on the outcome of dogs with thoracolumbar spinal cord diseases. In chapter IV, I show that neither age nor weight of the patient at presentation affects the neurological recovery, and that there is no significant difference even when comparing extreme groups of age or weight. The neurological examination remains an indispensable tool to localise and grade lesions affecting the spinal cord and is essential for accurate planning and interpretation of diagnostic imaging techniques and formulating the prognosis. In Chapter V, I demonstrate that the presence of a cutaneous trunci reflex is useful in further localising the maximal level of spinal cord lesion within the T3 to L3 spinal cord segments to an accuracy of up to four vertebrae. In addition the cutaneous trunci reflex can be used to rapidly segregate dogs with an ambulatory paresis into less and more severely affected populations on the basis of clinical severity.

TABLE OF CONTENTS

Summary	i
Table of Contents	ii
List of Tables.....	v
List of Figures	vi
Acknowledgements.....	viii
Author's Declaration	ix
Publications and Presentations.....	x
Publications and Presentations.....	x
 Chapter I REVIEW OF PROGNOSTIC FACTORS IN DOGS WITH THORACOLUMBAR SPINAL CORD DISEASE	 1
1.1 Thoracolumbar Spinal Cord Disease in the Dog	2
1.1.1 Primary and Secondary Injury Mechanisms	3
1.1.2 Spinal Cord Repair	4
1.2 Determination of the Prognosis Following Canine Thoracolumbar Spinal Cord Disease	4
1.3 The effect of signalment on the outcome	5
1.3.1 Age	5
1.3.2 Body Weight (Breed Size)	5
1.3.3 Gender	6
1.3.4 Breed.....	6
1.4 The effect of findings of the clinical history on outcome	7
1.4.1 Duration of clinical signs	7
1.4.2 Rate of onset of the clinical signs	8
1.4.3 Previous history of spinal cord disease.....	8
1.5 The effect of the findings of the neurological examination on outcome	9
1.5.1 The presence of nociception caudal to the lesion (deep pain perception) and grading scales	9
1.5.2 Site of injury	15
1.5.3 Symmetry of the neurological deficits	15
1.5.4 The effect of deterioration or improvement of the neurological deficits on prognosis.....	16

1.6	The effect of the clinical investigation on outcome	17
1.6.1	Cerebrospinal fluid (CSF) examination.....	17
1.6.2	Diagnostic imaging technique	17
1.6.3	Electrophysiological studies	19
1.7	The effect of the aetiology of the lesion on outcome	20
1.8	The effect of treatment modality on outcome.....	23
1.8.1	Surgery decompression and fenestration	23
1.8.2	Conservative treatment and medications	24
1.8.3	Physiotherapy.....	25
1.9	Aims of this Thesis.....	25
Chapter II MATERIALS AND METHODS		27
2.1	Case selection and data collection.....	28
2.1.1	Retrospective case selection and data collection	28
2.1.2	Prospective case selection and data collection.....	29
2.2	Diagnostic imaging techniques.....	29
2.2.1	Diagnostic imaging techniques in the retrospective cases	29
2.2.2	Diagnostic imaging techniques in the prospective cases	30
2.3	Age analysis.....	31
2.4	Breed size and weight analysis	31
2.5	Cutaneous trunci reflex.....	31
2.6	Clinical grading	32
2.7	Statistical analysis.....	32
2.7.1	Statistical analysis in the retrospective cases	32
2.7.2	Statistical analysis in the prospective cases	33
Chapter III CHANGING DIAGNOSTIC IMAGING TRENDS FOR CANINE THORACOLUMBAR SPINAL DISEASE AND ITS INFLUENCE ON OUTCOME (2000-2010).		34
3.1	Introduction	35
3.2	Results.....	37
3.2.1	Animals	37
3.2.2	Historical trends in the choice of diagnostic imaging technique... 38	
3.2.3	Association between diagnostic imaging technique performed, clinical presentation and outcome	40

3.3	Discussion	42
Chapter IV	THE INFLUENCE OF AGE AND WEIGHT ON RECOVERY IN DOGS WITH THORACOLUMBAR SPINAL CORD DISEASE.....	46
4.1	Introduction	47
4.2	Results.....	48
4.2.1	Animals	48
4.2.2	Analysis of age groups: Young group (≤ 3 years).....	49
4.2.3	Analysis of age groups: Old group (≥ 9 years).....	50
4.2.4	Influence of age on speed and grade of recovery	52
4.2.5	Analysis of weight groups: Small breeds group	54
4.2.6	Analysis of weight groups: Large breeds group	54
4.2.7	Influence of weight on speed and grade of recovery	57
4.3	Discussion	59
Chapter V	THE CUTANEOUS TRUNCI REFLEX AS A LOCALISING AND GRADING TOOL IN DOGS WITH THORACOLUMBAR SPINAL CORD DISEASE	62
5.1	Introduction	63
5.2	Results.....	64
5.2.1	Signalment and diagnosis	64
5.2.2	The cutaneous trunci reflex as a localising tool	65
5.2.3	The cutaneous trunci reflex as a grading tool	66
5.3	Discussion	69
Chapter VI	DISCUSSION.....	72
	LIST OF REFERENCES	76

LIST OF TABLES

Table 1 The commonly used 5-point grading scale for the determination of the severity of thoracolumbar spinal cord injuries in dogs, applicable to the clinical setting (Sharp and Wheeler, 2005).....	11
Table 2 Correlation between clinical grade (based on the 5-point grading scale presented in Table 1) and outcome following thoracolumbar intervertebral disc disease managed conservatively and surgically. (Anderson et al., 1991; McKee, 1992; Muir et al., 1995; Cudia and Duval, 1997; Scott and McKee, 1999; Davis and Brown, 2002; Olby et al., 2003; Brisson et al., 2004; Sharp and Wheeler, 2005; Ruddle et al., 2006).....	12
Table 3 The Texas spinal cord injury scoring system for canine patients with spinal cord injury. The different components (gait, proprioceptive positioning and nociception) are graded independently for each limb and then the combined score is obtained by adding the results of the 4 limbs. The possible range for the combined score was 0-24 for the gait, 0-8 for proprioceptive positioning and 0-8 for nociception (Levine et al., 2009).	13
Table 4 The detailed 14-point grading scale for canine patients with thoracolumbar spinal cord injury (Olby et al., 2001). Classification of patients with this grading scale requires the use of video gait analysis.	14
Table 5 Rates of recovery to voluntary ambulation in dogs following traumatic and ischaemic spinal cord injuries (Davies and Sharp, 1983; McKee, 1990; Cauzinille and Kornegay, 1996; Duval et al., 1996; Cudia and Duval, 1997; Scott and McKee, 1999; Davis and Brown, 2002; Ferreira et al., 2002; Gandini et al, 2003; Olby et al., 2003; Brisson et al., 2004; Sharp and Wheeler, 2005; Ito et al., 2005; Ruddle et al., 2006; Dunie-Merigot et al., 2007; Levine et al., 2007; Bruce et al., 2008 de Risio et al., 2008).....	22

LIST OF FIGURES

Figure 1 Historical changes in the choice of diagnostic imaging modality for the investigation of canine thoracolumbar spinal cord disease following the introduction of MRI as a diagnostic imaging modality in a veterinary referral institution. A) Proportional representation of the choice of diagnostic imaging technique from 2000 to 2010 demonstrates that MRI has progressively replaced myelography, CT-myelography and survey radiographs for the investigation of canine thoracolumbar spinal cord disease. There is a progressive increase in the case numbers having MRI and a corresponding decline in case numbers having myelography, CT-myelography and radiography. B) Absolute case numbers for each of the four imaging modalities used for the investigation of canine thoracolumbar spinal cord disease..... 39

Figure 2 Distribution of diagnosis (intervertebral disc disease, suspected ischaemic myelopathy and trauma) in the general population, young group (dogs of ≤ 3 years) and old group (dogs of ≥ 9 years). 51

Figure 3 Grade of improvement per day of hospitalisation in relation to the age at the time of spinal cord disease in 129 dogs. Linear regression demonstrated no correlation between the grade of improvement per day of hospitalisation and the dog's age. The grade of improvement per day of hospitalisation = $0.1698 + 0.000057 \text{ age}$, $R^2=0$, $P=0.922$ 53

Figure 4 Distribution of diagnosis (intervertebral disc disease, suspected ischaemic myelopathy and trauma) in the general population, small breed group (dogs of $\leq 10\text{Kg}$) and large breed group (dogs of $\geq 25\text{Kg}$). 56

Figure 5 Grade of improvement per day of hospitalisation in relation to the weight at the time of spinal cord disease in 129 dogs. Linear regression demonstrated no correlation between the dog's weight and the grade of improvement per day of hospitalisation. Grade of improvement per day of hospitalisation = $0.167 + 0.000767 \text{ weight}$, $R^2=0.2$, $P=0.637$ 58

Figure 6 Vertebral level of the cutaneous trunci reflex cut-off in relation to the vertebral level of the maximal spinal cord lesion in 39 dogs with thoracolumbar spinal cord lesions. The presence of a cutaneous trunci reflex cut-off indicates spinal cord lesion 0 to 4 vertebrae cranial to the level of the cut-off, with 62% of these lesions being 2-3 vertebrae cranial to the cut-off (yellow circles). 67

Figure 7 Presence of a cutaneous trunci reflex cut-off in relation to the clinical grade in 47 dogs with thoracolumbar spinal cord lesions. The presence of a cutaneous trunci reflex cut-off is significantly correlated with a more severe clinical grade ($P < 0.0001$ in the whole population and $P = 0.0344$ in dogs with grade II ambulatory paraparesis on the 0 to 5 grading scale, allowing segregation of this population into more and less severely affected groups)..... 68

ACKNOWLEDGEMENTS

I would like to thank my supervisor, Professor Jacques Penderis for his support and guidance.

I would also like to thank Dr Annette Wessmann for all the help during my residency.

I would also like to thank Professor Jim Anderson, Dr Julia Edgar and Dr Giunio Bruto Cherubini for their help with some of the chapters of this thesis.

I would like to thank the previous and present members of the neurology team Rita Goncalves, Raquel Monteiro, Mark Lowrie, Roberto Jose Lopez, Maria Ortega, Allison Haley, Gillian Calvo and Deborah Lightfoot for their help and support during this project.

Finally I would like to thank all the students and hospital staff for their help in videotaping the cases used in this project.

AUTHOR'S DECLARATION

The work presented in this thesis was performed solely by the author except where the assistance of others has been acknowledged.

Rodrigo Gutierrez Quintana, July 2012

PUBLICATIONS AND PRESENTATIONS

Some of the work contained in this thesis has been the subject of the following publications and presentations:

Publication:

Gutierrez-Quintana, R., Edgar, J., Wessmann, A., Cherubini, G.B., Penderis, J., 2012. The cutaneous trunci reflex for localizing and grading thoracolumbar spinal cord injuries in dogs. *Journal of Small Animal Practice*, In Press.

Conference proceedings:

The evolution in diagnostic imaging technique of choice in dogs with thoracolumbar spinal cord injuries and its influence on outcome (2000-2007). Rodrigo Gutierrez, Thomas J. Anderson, Giles Innocent and Jacques Penderis. 21st Annual Symposium of the ESVN: September 2008. (Poster presentation)

The cutaneous trunci reflex as a localizing and grading tool in dogs with thoracolumbar spinal cord injuries Rodrigo Gutierrez, Julia Edgar, Annette Wessmann, Guino B Cherubini and Jacques Penderis. 23rd Annual Symposium of the ESVN: September 2010. (Oral presentation)

CHAPTER I

1 REVIEW OF PROGNOSTIC FACTORS IN DOGS WITH THORACOLUMBAR SPINAL CORD DISEASE

1.1 Thoracolumbar Spinal Cord Disease in the Dog

Canine patients presenting with evidence of spinal cord disease involving the thoracolumbar segments (T3-L3) are relatively common in veterinary practice, representing 19.6% of the neurological cases seen in one veterinary referral hospital (Fluehmann et al., 2006). There are numerous diseases that affect the spinal cord of dogs at this level, either by direct damage or secondary spinal cord compression. The most frequent condition in dogs older than one year being degenerative intervertebral disc disease (Brisson, 2010). Degenerative intervertebral disc disease is uncommon in dogs less than 1 year of age, and in this age category traumatic disc extrusions, spinal cord inflammation, discospondylitis and trauma are more likely (Platt and Olby, 2004; Dewey, 2008). In large, non-chondrodystrophoid breeds ischaemic myelopathy (fibrocartilaginous embolisms or FCE) and, in dogs over 6 years of age, degenerative myelopathy are also important differential diagnoses (Platt and Olby, 2004; Sharp and Wheeler, 2005; Bagley, 2005;). Neoplasia is more prevalent in older dogs, but should still be considered in younger patients with thoracolumbar spinal cord lesions and may even occur in patients as young as 4 months old, with nephroblastoma being one such example (Bagley, 2010; Brewer et al., 2011).

The clinical presentation following spinal cord disease is dependent on the anatomical level of the spinal cord lesion and the severity of the lesion. Mild lesions affecting the T3-L3 spinal cord segments may only result in evidence of spinal pain. The main clinical sign associated with more severe lesions affecting the T3-L3 spinal cord segments is evidence of upper motor neuron deficits in the pelvic limbs and these are characterised by pelvic limb paresis or plegia, proprioceptive deficits, ataxia, increased muscle tone and normal to increased segmental spinal reflexes. Urinary retention, a cutaneous trunci reflex cut-off, spinal hyperaesthesia and Schiff-Sherrington syndrome may also be present, depending on the severity of the lesion and the specific disease (Platt and Olby, 2004; Sharp and Wheeler, 2005; Bagley, 2005; Dewey, 2008)

1.1.1 Primary and Secondary Injury Mechanisms

The spinal cord is relatively well protected within the bony vertebral canal. However, if the protection afforded by the vertebrae fails or if a lesion arises within the spinal canal itself, then the spinal cord is susceptible to injury. The spinal cord is a tissue that can readily be damaged and both primary and secondary mechanisms of injury have been described. Primary injury is caused by direct damage to the parenchyma and vasculature of the spinal cord, usually due to compression, contusion, shearing, laceration or stretching (Olby, 2010). Blood vessels are damaged, axons are disrupted and the integrity of neural-cell membranes is breached. Following this, the spinal cord swells and may occupy the entire diameter of the spinal canal at the level of the injury. The secondary mechanisms of injury correspond to the cascade of pathological events that are triggered by the primary injury. As a consequence of the spinal cord swelling, ischaemia may develop if the pressure within the spinal cord exceeds the vascular pressure of the spinal cord blood supply (Olby, 2010). Due to the ischaemia, and secondary to the primary injury, the damaged cells, axons and blood vessels release toxic chemicals that result in secondary damage to intact neighbouring cells. Glutamate has been demonstrated to cause excitotoxic damage to the spinal cord parenchyma and resultant neuronal and oligodendrocyte destruction (Weil et al., 2008). Restoring perfusion to the ischaemic tissue may also result in detrimental effects, with the formation of reactive oxygen species which may produce oxidative damage (Platt and Olby, 2004; Bagley, 2005; Weil et al., 2008; Olby, 2010).

In other spinal cord conditions where the injury is not the result of trauma, compression or ischemia, the pathophysiology is usually disease specific. Chronic degenerative radiculomyelopathy (degenerative myelopathy or CDRM) is a degenerative neurological disorder resulting in progressive pelvic limb ataxia and paresis in older large breed dogs, particularly the German shepherd dog (GSD). This condition has recently been shown to be associated with a substitution mutation (G>A) in the superoxidase dismutase-1 (SOD-1) gene and has an autosomal recessive inheritance (Coates and Wininger, 2010). Neoplasia usually either results in direct compression of the spinal cord as for example in vertebral tumours, or may demonstrate local invasion of the spinal cord

parenchyma as for example nerve sheath tumours (Bagley, 2010). Myelitis can be of non-infectious origin, as in granulomatous meningoencephalitis (GME), or of infectious origin, with viral, bacterial, fungal or protozoal agents involved (Tipold and Stein, 2010).

1.1.2 Spinal Cord Repair

Classically the CNS has been considered to be a tissue with poor regenerative capabilities, and this is certainly true for most of the neuronal cell populations in the adult nervous system. Following spinal cord disease there is usually permanent loss of axons. This is contrary to the situation in the peripheral nervous system, as damaged or transected CNS axons do not have the ability to grow into and through a spinal cord lesion and re-establish functional synapses distal to the lesion (Weil et al., 2008). There are two large classes of molecular signals that inhibit axonal regeneration within the CNS: the myelin associated molecules and those associated with the extracellular matrix (Rhodes and Fawcett, 2004; Fawcett, 2006; Olby, 2010).

1.2 Determination of the Prognosis Following Canine Thoracolumbar Spinal Cord Disease

A large number of studies that are discussed in the following sections have examined the utility of different clinical factors in accurate determination of the prognosis in dogs with thoracolumbar spinal cord diseases. The presence or absence of the conscious perception of pain caudal to the lesion (so-called “deep pain” perception or nociception) is widely recognised as one of most important prognostic indicators in canine spinal cord injury, but many other factors influence the grade and speed of recovery. Accurate prediction of the outcome is of critical importance for the clinician and the owner, in order to allow informed decisions to be made and to dictate the most appropriate clinical interventions.

1.3 The effect of signalment on the outcome

1.3.1 Age

In light of the greater plasticity of the juvenile nervous system, it would be logical to assume that younger dogs would have a better outcome following thoracolumbar spinal cord injury. However, the influence of age on the outcome following spinal cord diseases remains controversial. A number of studies found no positive correlation between the patient's age and eventual outcome (Dhupa, et al., 1999a; Davis and Brown, 2002; Olby et al., 2004; Penning et al., 2006; Kathmann et al., 2006; Bull et al. 2008), while other studies demonstrated that a successful outcome was more likely in younger dogs (Macias et al., 2002; Levine et al., 2007; Bull et al., 2008). However age does appear to influence the speed of recovery following spinal cord injury, with younger dogs having a more rapid rate of recovery (Olby et al., 2003). Comparison between the different published studies is confounded by differences in individual study design. In some studies age was considered as a continuous variable, while in other studies dogs were divided into different groups on the basis of age. An additional important factor is that the number of very young and very old patients tended to be low in these studies.

There are also conflicting results in the human literature about the influence of age on outcomes of traumatic and non-traumatic spinal cord diseases. Some studies found that the age of the patient influences the outcome (DeVivo et al., 1990; Seel et al., 2001; Scivoletto et al., 2003), but others concluded the opposite (Yarkony et al., 1988; Kennedy et al., 2003; New and Epi, 2007; Furlan et al., 2010).

1.3.2 Body Weight (*Breed Size*)

Body weight is a variable that is easy to determine and which could also potentially have an influence on the prognosis following spinal cord disease. Studies examining the effect of body weight have revealed conflicting results: some demonstrated no correlation between body weight and outcome following spinal cord injury (Dhupa et al., 1999a; Macias et al., 2002; Olby et al., 2004;

Kathmann et al., 2006; Ruddle et al., 2006), while others described a negative effect of increasing body weight on the speed (Cudia and Duval, 1997; Olby et al., 2003) and degree (Hawthorne et al., 2001; Bull et al., 2008) of the recovery. The heavier the dog, the longer the time to recovery and the worse the outcome. However, an important factor to consider which may have affected the studies with a worse outcome in heavier dogs is the ease of management of recumbent large breed dogs, where owners may elect for euthanasia in heavier dogs due to difficulties in nursing these patients.

1.3.3 Gender

Experimental studies have demonstrated that female hormones have a neuroprotective effect (Weaver et al., 1997; Marchetti et al., 2000; Bjorling et al., 2002). Interestingly in dogs, some studies report a gender predisposition for the development of spinal cord damage secondary to intervertebral disc disease (Ferreira et al., 2002; Brisson et al., 2004; Penning et al., 2006) and ischaemic myelopathy (Hawthorne et al., 2001; de Risio et al., 2007), with a higher prevalence in male dogs. However, these studies did not examine the influence of gender on outcome. One study examining the influence of gender on the outcome following spinal cord damage secondary to intervertebral disc disease in large breed dogs revealed no effect (Macias et al., 2002). Similarly no gender predilection was evident when examining the risk of recurrence of intervertebral disc disease in a population of Dachshunds (Brisson et al. 2004).

1.3.4 Breed

Breed predispositions exist for different conditions affecting the spinal cord, however studies examining the influence of the breed on the outcome following acute intervertebral disc disease did not demonstrate any significant effect (Olby et al. 2004; Ruddle et al., 2006). An increased risk of recurrence has been demonstrated for Dachshunds following intervertebral disc disease, when compared with other breeds but no effect on the outcome was reported (Dhupa et al., 1999b; Brisson et al., 2004; Mayhew et al., 2004). The breed may play a role if this affects body size and weight, but this is discussed in section 1.3.2.

1.4 The effect of findings of the clinical history on outcome

1.4.1 Duration of clinical signs

The duration of the clinical signs prior to therapeutic intervention is important in two different groups of dogs: those with absent nociception (deep pain perception) caudal to the lesion and dogs with intact nociception and it has been studied mainly in dogs with spinal cord injury secondary to intervertebral disc disease.

In dogs with absent nociception it is difficult to determine the exact time point at which nociception was lost and therefore the time that has elapsed since nociception has been lost. However, most studies in spinal cord injury secondary to intervertebral disc disease report a higher recovery rate in dogs with a shorter duration absence of nociception prior to therapeutic intervention (Muir et al., 1995; Scott and McKee, 1999). Recovery rates range from 53 to 76% when nociception has been lost for less than 12 hours, 38 to 50% if nociception has been lost for between 12 and 24 hours and 25 to 43% if nociception has been lost for between 24 and 48 hours (Muir et al., 1995; Scott and McKee, 1999; Olby et al., 2003). Most institutions consider the likelihood of recovery following spinal cord injury to be very poor if more than 48 hours has elapsed after the loss of nociception and most of these patients are usually euthanised without treatment. However, one study reported recovery in some dogs with complete absence of nociception for long durations (Kazakos et al., 2005).

The duration of the clinical signs prior to therapeutic intervention also plays a role in less severe spinal cord injuries secondary to intervertebral disc disease in which nociception remains intact caudal to the lesion. The majority of the studies (Davis and Brown, 2002; Macias et al., 2002; Ferreira et al., 2002; Olby et al., 2003; Kazakos et al., 2005; Ito et al., 2005) demonstrated that the duration of clinical signs prior to therapeutic intervention did not influence the outcome, although a longer duration did correlate with a longer recovery (Davis and Brown, 2002; Macias et al., 2002; Ferreira et al., 2002). A single study

assessing the success of medical management in dogs with spinal cord injury secondary to intervertebral disc disease established that the duration of clinical signs prior to treatment was a predictor of success, with longer duration of clinical signs having a worse response to conservative management (Levine et al., 2007).

1.4.2 Rate of onset of the clinical signs

The rate of onset of the clinical signs is sometimes difficult to evaluate, as determining the exact speed of onset depends on the owner's subjective description of the clinical signs. Some studies described that the outcome was not related to the rate of onset of the clinical signs (Cudia and Duval, 1997; Macias et al., 2002; Olby et al., 2003; Ito et al., 2005). However, other studies in dogs with paraplegia secondary to intervertebral disc disease concluded that a more rapid loss of motor function was associated with a worse prognosis, as compared to dogs with a slower and more progressive loss of the ability to ambulate (Scott and McKee, 1999; Ferreira et al., 2002). The authors suggested that dogs suffering a sudden extrusion of intervertebral disc material have a consequent more severe concussion of the spinal cord and a greater severity of pathological changes within the spinal cord to explain the worse prognosis, however histological studies were not performed.

1.4.3 Previous history of spinal cord disease

The effect of a previous episode of spinal cord disease on the outcome following a second episode of spinal cord disease has been studied in dogs with a recurrence of intervertebral disc disease. The findings of the studies suggest that prior episodes of intervertebral disc disease does not influence the outcome following a repeated episode of intervertebral disc disease (Bull et al., 2008) and that the likelihood of functional recovery in dogs after a second decompressive surgery was identical to the functional recovery of dogs after a first surgery (Dhupa et al., 1999b).

1.5 The effect of the findings of the neurological examination on outcome

1.5.1 The presence of nociception caudal to the lesion (deep pain perception) and grading scales

The most important clinical feature affecting the prognosis in spinal cord diseases is the initial severity grading at the time of presentation (Platt and Olby, 2004; Dewey, 2008). In human patients the American Spinal Injury Association (ASIA) has standardised the physical examination of patients with spinal cord injuries to determine the precise sensory, motor and neurological level of the injury, as well as the severity of the lesion (Scivoletto and Di Donna, 2009). Severity grading in animals is complicated by the difficulty in accurately assessing a number of the sensory pathways within the spinal cord, including temperature discrimination, pressure, touch, etc. However, there are still enough spinal cord pathways of varying susceptibility that we can assess to allow us to accurately grade spinal cord lesion in dogs.

Despite the fact that the assessment of nociception is clinically subjective and the patient response may vary (Ruddle et al., 2006), it is considered a critical prognostic feature in the majority of the studies (Anderson et al., 1991; McKee, 1992; Muir et al., 1995; Scott, 1997; Cudia and Duval, 1997; Scott and McKee, 1999; Dhupa et al., 1999a; Davis and Brown, 2002; Gandini et al., 2003; Olby et al., 2003; Brisson et al., 2004; Ito et al., 2005; Ruddle et al., 2006; Levine et al., 2007; Bull et al. 2008; de Risio et al. 2008). The recovery after surgical decompression in dogs with intervertebral disc disease and absent nociception caudal to the lesion for less than 48 hours varies from 25 to 76%, depending on the individual study (Anderson et al., 1991; Muir et al., 1995; Duval et al., 1996; Scott and McKee, 1999; Olby et al., 2003; Laitinen and Puerto, 2005; Loughin et al., 2005; Ito et al., 2005; Ruddle et al., 2006). The difference in recovery rates between the different studies in part reflects the different clinical severity of spinal cord injury that may be evident in dogs with loss of nociception caudal to the lesion and the relatively small populations of dogs with this severity grade in the various studies. The persistent absence of nociception clearly indicates a severe injury, however it should not be taken to indicate complete anatomic

spinal cord transection, but may represent a functional block to impulse transmission that is potentially reversible (Olby et al., 2003). In contrast to the situation in dogs with absent nociception, if nociception is intact caudal to the lesion then the prognosis for recovery after surgical decompression in dogs with intervertebral disc disease increases to over 90% (McKee, 1992; Cudia and Duval, 1997; Davis and Brown, 2002; Brisson et al., 2004; Ito et al. 2005).

The severity of the neurological deficits in dogs with spinal cord disease is commonly scored using a scale from 0 to V originally developed by Griffiths (Griffiths, 1982), but subsequently modified (Anderson et al., 1991; Scott, 1997; Scott and McKee, 1999; Sharp and Wheeler, 2005; Levine et al., 2009) (Table 1). This 5-point grading scale is useful within the clinical setting for rapidly assigning a severity grade to dogs with spinal cord disease, helping to inform the prognosis. This grading scale is particularly useful for predicting the outcome in dogs with intervertebral disc disease (Table 2). In dogs with spinal cord injury due to ischaemic myelopathy, the neurological score at presentation was associated with the outcome but not with the speed of recovery (Gandini et al., 2003; De Risio et al., 2008).

The main disadvantage of the 5-point scoring system is that it does not allow fine discrimination of the severity of the spinal cord injury, in particular during the recovery period. The most common clinical grades at the time of presentation and during the recovery period are dogs with grade 2 (ambulatory paresis) and grade 3 (non-ambulatory paresis) severity grades. However it is not possible to discriminate between patients within these two groups, despite them representing a wide spectrum of severity. Recently a new spinal cord injury scale was developed and validated by Levine and co-workers (Levine et al., 2009). The main advantages of this scoring system are that it allows evaluation of each limb individually and it takes into account the presence or absence of proprioception within the affected limbs in establishing the grade, but finer discrimination is still difficult (Table 3). A more advanced 14-point scoring system that allows fine discrimination was developed, however this grading scale is limited in that it requires video gait analysis and is less suited to rapid clinical assessment (Table 4) (Olby et al., 2001).

Grade	Clinical signs
0	Normal
I	Pain only
II	Ambulatory paraparesis
III	Non ambulatory paraparesis
IV	Paraplegia
V	Paraplegia with no nociception (deep pain perception)

Table 1 The commonly used 5-point grading scale for the determination of the severity of thoracolumbar spinal cord injuries in dogs, applicable to the clinical setting (Sharp and Wheeler, 2005)

Grade at presentation	Intervertebral disc disease: Conservative management	Intervertebral disc disease: Surgical decompression
1	100%	97%
2	84%	95%
3	84%	93%
4	81%	95%
5	7%	53-76% (<12Hrs*) 38-50% (12-24Hrs*) 25-43% (24-48Hrs*)

Table 2 Correlation between clinical grade (based on the 5-point grading scale presented in Table 1) and outcome following thoracolumbar intervertebral disc disease managed conservatively and surgically. (Anderson et al., 1991; McKee, 1992; Muir et al., 1995; Cudia and Duval, 1997; Scott and McKee, 1999; Davis and Brown, 2002; Olby et al., 2003; Brisson et al., 2004; Sharp and Wheeler, 2005; Ruddle et al., 2006).

*Time since lost of deep pain perception until surgical decompression.

Grade	Clinical signs
GAIT	
0	No voluntary movement seen when supported
1	Intact limb protraction with no ground clearance
2	Intact limb protraction with inconsistent ground clearance
3	Intact limb protraction with consistent ground clearance (>75%)
4	Ambulatory, consistent ground clearance with moderate paresis-ataxia (will fall occasionally)
5	Ambulatory, consistent ground clearance with mild paresis-ataxia (does not fall, even on slick surfaces)
6	Normal gait
PROPRIOCEPTIVE POSITIONING	
0	Absent response
1	Delayed response
2	Normal response
NOCICEPTION	
0	No deep pain perception
1	Intact deep nociception, no superficial nociception
2	Nociception present

Table 3 The Texas spinal cord injury scoring system for canine patients with spinal cord injury. The different components (gait, proprioceptive positioning and nociception) are graded independently for each limb and then the combined score is obtained by adding the results of the 4 limbs. The possible range for the combined score was 0-24 for the gait, 0-8 for proprioceptive positioning and 0-8 for nociception (Levine et al., 2009).

Grade	Clinical signs
Stage 1	
0	No pelvic limb movement and no nociception
1	No pelvic limb movement with nociception
2	No pelvic limb movement but voluntary tail movement
Stage 2	
3	Minimal non-weight-bearing protraction of the pelvic limb (Movement of one joint)
4	Non-weight-bearing protraction of the pelvic limb with more than one joint involved less than 50% of the time.
5	Non-weight-bearing protraction of the pelvic limb with more than one joint involved more than 50% of the time.
Stage 3	
6	Weight-bearing protraction of the pelvic limb less than 10% of the time
7	Weight-bearing protraction of the pelvic limb 10-50% of the time
8	Weight-bearing protraction of the pelvic limb more than 50% of the time
Stage 4	
9	Weight-bearing protraction 100% of the time with reduced strength of pelvic limb. Mistakes: more than 90% of the time
10	Weight-bearing protraction 100% of the time with reduced strength of pelvic limb. Mistakes: 50-90% of the time
11	Weight-bearing protraction 100% of the time with reduced strength of pelvic limb. Mistakes: less than 50% of the time
Stage 5	
12	Ataxic pelvic limb gait with normal strength, but mistakes made more than 50% of the time
13	Ataxic pelvic limb gait with normal strength, but mistakes made less than 50% of the time
14	Normal pelvic limb gait

Table 4 The detailed 14-point grading scale for canine patients with thoracolumbar spinal cord injury (Olby et al., 2001). Classification of patients with this grading scale requires the use of video gait analysis.

1.5.2 Site of injury

Lesions affecting the spinal cord also differ in their outcome depending on the level of the spinal cord injury, with a poorer outcome in lesions affecting the cervical and lumbar intumescences (with lower motor neuron deficits), compared to lesions affecting the C1 to C5 or T3 to L3 spinal cord segments (Dhupa et al., 1999). Some studies evaluating intervertebral disc disease affecting the lumbar intumescence concluded this was not associated with a worse outcome (Dhupa et al., 1999a; Olby et al., 2003; Olby et al., 2004; Ruddle et al., 2006; Bull et al., 2008). However, closer examination reveals that the population of intervertebral disc disease cases included in these studies only rarely affected the lumbar intumescence and this did not allow adequate comparison. One of these studies also evaluated if the location of the intervertebral disc herniation within the thoracolumbar region had an effect on the ability and speed to regain ambulation, and found no correlation (Ruddle et al., 2006).

One of the major spinal cord diseases in canine practice that frequently affects the intumescences are ischaemic myelopathies. In one study that included histologically confirmed and suspected cases of ischaemic myelopathy, lower motor neuron signs were more frequent in dogs that were euthanised and had a confirmed diagnosis of ischaemic myelopathy, suggesting a worse prognosis for this localisation (Cauzinille and Kornegay, 1996). However, in the same study (Cauzinille and Kornegay, 1996) and in subsequent studies (Gandini et al., 2003; de Risio et al., 2008) no influence of lesion localisation was reported on the outcome or time to recovery in dogs with suspected ischaemic myelopathy.

1.5.3 Symmetry of the neurological deficits

The influence of the symmetry of the neurological deficits on outcome has been studied in dogs with ischaemic myelopathy (Cauzinille and Kornegay, 1996; Gandini et al., 2003). Both studies concluded that the presence of asymmetrical clinical signs is associated with a better prognosis, presumably as the damage is

restricted to a part of the spinal cord in these lesions, while in symmetrical lesions a large cross-sectional area of the spinal cord is affected.

1.5.4 The effect of deterioration or improvement of the neurological deficits on prognosis

Following spinal cord injury serial neurological examinations should be performed in order to establish whether the neurological deficits are becoming more severe or resolving, and this can be important for establishing the prognosis. Myelomalacia should be suspected if there is a cranial migration of the caudal most level at which the cutaneous trunci reflex can be elicited, if there is development of lower motor neuron signs in the pelvic limbs or the development of tetraparesis in a dog that was previously just demonstrating paraplegia (Olby et al., 2003; Okada et al., 2010). If there is evidence of ascending or descending myelomalacia then the prognosis is hopeless.

In dogs with no nociception caudal to the lesion, then repeated evaluation of nociception should be performed for up to two to four weeks after decompressive surgery (Scott and McKee, 1999; Olby et al., 2003; Laitinen and Puerto, 2005). The recovery of nociception is a positive prognostic indicator, with 67% of dogs demonstrating a good recovery if nociception became present caudal to the lesion by two weeks following decompressive surgery (Laitinen and Puerto 2005). Another prognostic factor that should be evaluated is motor function. Cases of intervertebral disc disease that demonstrated voluntary motor ability in the pelvic limbs postoperatively, had a significantly shorter time to ambulation (7.9 days) than dogs without voluntary motor ability at this time point (16.4 days) (Davis and Brown, 2002). Tail wag was a useful early prognostic indicator for recovery of motor function in one study (Olby et al., 2003).

1.6 The effect of the clinical investigation on outcome

1.6.1 Cerebrospinal fluid (CSF) examination

Dogs with acute and clinically severe signs of intervertebral disc disease appear to demonstrate a significant increase in CSF total protein and white blood cell count (Thomson et al., 1989; Windsor et al., 2008), although these changes have not been demonstrated to have any prognostic value (Macias et al., 2002). However, a recent study in dogs with intervertebral disc disease found that the percentage of CSF macrophages could be used as a prognostic indicator for regaining ambulation in dogs with no deep pain perception (Sruogo et al., 2011). In ischaemic myelopathy, one study reported no association between CSF abnormalities and the outcome (de Risio et al., 2008), while other studies suggested that dogs with normal CSF parameters were more likely to recover the ability to walk than those with abnormal CSF (Cauzinille and Kornegay, 1996; Gandini et al., 2003).

Different biomarkers of spinal cord injury in the CSF have been evaluated with variable success. Matrix metalloproteinase-9 activity in the CSF of dogs with acute intervertebral disc disease was shown to be more common in paraplegic dogs than dogs with intact voluntary movement, but no difference in the length of hospitalisation was evident on the basis of matrix metalloproteinase-9 activity (Levine et al., 2006). Evaluation of the levels of myelin basic protein (MBP) in the CSF of dogs with acute intervertebral disc disease found that a concentration of MBP of 3ng/ml or higher had a sensitivity of 78% and a specificity of 76% for predicting an unsuccessful outcome (Levine et al., 2010). Cartilage oligomeric matrix protein is another CSF biomarker that is increased in dogs with intervertebral disc disease and may have potential as a prognostic indicator (Tokunaga et al., 2010).

1.6.2 Diagnostic imaging technique

Surprisingly the choice of diagnostic imaging technique (myelography, computed tomography (CT), CT- myelography and magnetic resonance imaging (MRI)) for investigation of spinal cord disease does not appear to influence the outcome

(Olby et al., 2004; Parry et al., 2010). Additionally, no difference in time to ambulation was apparent in dogs with intervertebral disc disease that received a single or multiple myelographic contrast injections (Davis and Brown, 2002).

The findings on the basis of spinal radiographs and myelography have been studied to assess their influence on outcome. The number of calcified discs has been shown to be a significant risk factor for recurrence of intervertebral disc disease, with each calcified disc evident on radiography increasing the risk of recurrence by 1.4 times (Mayhew et al., 2004). The length of spinal cord swelling evident on myelography relative to the length of the L2 vertebra has been evaluated in dog with intervertebral disc disease and absence of nociception caudal to the lesion (Duval et al., 1996; Scott and McKee, 1999). One of the studies demonstrated that a cut-off of 5 for this ratio had an influence on the prognosis, with 61% of dogs recovering if the ratio was less than 5, but only 21% of dogs recovering if the ratio was 5 or more (Duval et al., 1996). The second study could not reproduce these findings and explained that the length of the swelling in myelography can be affected by several factors, including the site of injection of contrast medium, the speed of injection, the contrast medium agent used and the timing of radiographs after injection (Scott and McKee, 1999). In dogs with ischaemic myelopathy, one study (Cauzinille and Kornegay, 1996) reported a worse prognosis in dogs with intramedullary swelling on myelography, while a second study (Gandini et al., 2003) found no influence of the presence of intramedullary swelling on the time of recovery.

MRI changes have been analysed in two different ways to establish their influence in the prognosis. The first method evaluated the degree of spinal cord compression in dogs with intervertebral disc disease. Although it may be intuitive to think that severe compression of the spinal cord due to extruded disc material would be associated with severe neurological dysfunction, this was not the case in one study (Penning et al., 2006). These findings can in part be explained because the severity of the spinal cord injury is due to a combination of concussion and compression, or because of the absence of a fine grading system for severity in the study. These findings were confirmed by a separate study, which found that the only measurement of spinal cord compression that correlated with the clinical severity was the length of the spinal cord

compression, but this did not have any association with the outcome (Levine et al., 2009). The explanation for the length of spinal cord compression being more clinically relevant than the degree of spinal cord compression is that compression over a greater length of spinal cord may exert a greater effect on axonal function than a focal compression. In contrast to what has been demonstrated in canine patients, in human patients (Furlan et al., 2007) and in an experimental rat model (Dimar et al., 1999) the degree of spinal cord compression was related to the outcome.

The second category of MRI changes that have been evaluated are intraparenchymal spinal cord changes. A multicenter study in human patients reported that the presence of intraparenchymal spinal cord changes (in particular spinal cord oedema) was associated with a worse outcome (Shepard and Bracken, 1999). One study in paraplegic dogs with intervertebral disc disease found that an area of hyperintensity in the spinal cord at least as long as the L2 vertebral body on preoperative T2-weighted images was associated with a poor prognosis for functional recovery (Ito et al. 2005). Dogs with no nociception caudal to the lesion and an area of spinal cord hyperintensity had a satisfactory recovery in 31% of dogs. When the analysis was widened to include dogs of all severity grades with acute intervertebral disc disease, a lower proportion of dogs with spinal cord intramedullary T2-weighted hyperintensity recovered ambulation than dogs lacking this hyperintensity (Levine et al., 2009). Similar findings have been reported in dogs with suspected ischaemic myelopathy and acute non-compressive nucleus pulposus extrusions, suggesting that the extent of the spinal cord T2-weighted hyperintensity was significantly associated with the outcome (de Risio et al. 2007; de Risio et al. 2008; de Risio et al. 2009).

1.6.3 Electrophysiological studies

The ability of different electrophysiological techniques to predict the outcome has been evaluated in dogs with spinal cord injuries. Magnetic motor evoked potentials have been shown to not be useful in predicting the prognosis in traumatic spinal cord injuries (Sylvestre et al., 1993). Cortical evoked responses appear to be useful as a prognostic indicator in dogs with paraplegia, but a

prospective study with more cases was recommended by the authors to confirm their preliminary findings (Bright et al., 1977). Spinal evoked potentials were of value in determining the prognosis for recovery in dogs with acute compressions, mainly intervertebral disc disease (Shores et al., 1987). Spinal evoked potentials using a ratio of *conduction velocity: addition of durations* revealed that dogs with a ratio <30 had a less favourable outcome, while dogs with a ratio of >30 had a more favourable outcome.

1.7 The effect of the aetiology of the lesion on outcome

Most of the veterinary literature examining outcome following spinal cord disease in dogs is focused on intervertebral disc disease because it is the most common disease affecting the spinal cord in dogs (Brisson, 2010). The recovery after surgical decompression in dogs with intervertebral disc disease and no nociception (for less than 48 hours) varies from 25 to 76% between the studies (Anderson et al., 1991; Muir et al., 1995; Duval et al., 1996; Scott and McKee, 1999; Olby et al., 2003; Laitinen and Puerto, 2005; Loughin et al., 2005; Ito et al., 2005; Ruddle et al., 2006). The prognosis for recovery after surgery in dogs with intact nociception is around 90% (McKee, 1992; Cudia and Duval, 1997; Davis and Brown, 2002; Brisson et al. 2004; Ito et al., 2005). The recovery in dogs following conservative treatment and with intact nociception is between 54 to 85% (Davies and Sharp, 1983; Sharp and Wheeler 2005; Levine et al., 2007) (Table 5). A successful surgical outcome is more likely in dogs with nuclear intervertebral disc extrusions (Hansen type-I intervertebral disc disease) compared to annular intervertebral disc protrusions (Hansen type-II intervertebral disc disease) (Macias et al., 2002).

Vertebral fractures and luxations were associated with a worse prognosis than intervertebral disc disease in dogs with absent nociception (Olby et al., 2003), suggesting that dogs with non-displaced vertebral fractures but absent nociception had only a minimal probability of recovery (McKee, 1990). This most likely reflects the increased probability of structural spinal cord transection secondary to spinal cord laceration and tearing following vertebral luxations. Dogs and cats with spinal fractures or luxations where nociception was intact prior to surgery had a good prognosis for functional recovery (Bruce et al.,

2008). Surgical and conservative techniques for the management of spinal fractures and luxations have been described (Sharp and Wheeler 2005; Jeffery 2010).

The proportion of dogs that recovered from a suspected episode of ischaemic myelopathy was between 74 to 91% when nociception was intact, but less than 43% in dogs with absent nociception (Cauzinille and Kornegay, 1996; Gandini et al., 2003; Dunié-Mérigot et al., 2007; de Risio et al., 2008) (Table 5).

The diagnosis of degenerative myelopathy was associated with a poor prognosis. The rate of deterioration varied between cases, but euthanasia was usually performed between 4 to 18 months after the first clinical signs became apparent (Kathmann et al., 2006; Coates and Wininger, 2010).

The prognosis in dogs with tumours affecting the spinal cord was poor, but was dependent on the tumour type, the tumour location and the treatment used. The most common extradural spinal cord tumours in dogs were sarcomas (osteosarcoma, fibrosarcoma and myxosarcoma) (Levy et al., 1997; Dernell et al., 2000; Sharp and Wheeler, 2005); and were associated with a guarded prognosis with a median survival time of 135 days that was not impacted greatly by the choice of treatment (Dernell et al., 2000). Plasma cell tumours are rare extradural spinal cord tumours in dogs, but tended to have a better prognosis, with survival after chemotherapy or a combination of chemotherapy and radiotherapy of 4 to 65 months (Rusbridge et al., 1999). Meningiomas are reported as the most common intradural/extramedullary primary CNS tumours in dogs; with a mean survival time of 19.5 months with surgery only (Moissonier et al., 2002) and a significant improvement in the outcome with postoperative radiation (Petersen et al., 2008). Other tumours affecting the thoracolumbar spinal cord (T3-L3) have been reported; however as only a small number of cases have been treated it is difficult to define their prognosis (Bagley, 2010).

	Intervertebral disc disease: Conservative management	Intervertebral disc disease: Decompressive surgery	Vertebral fracture or luxation: Conservative management	Vertebral fracture or luxation: Surgical management	Suspected ischaemic myelopathy
Deep pain perception intact	54-85%	80-96%	93-96%	83-88%	74-91%
No deep pain perception	7%	25-76%(<48hrs*)		22%	43%

Table 5 Rates of recovery to voluntary ambulation in dogs following traumatic and ischaemic spinal cord injuries (Davies and Sharp, 1983; Mckee, 1990; Cauzinille and Kornegay, 1996; Duval et al., 1996; Cudia and Duval, 1997; Scott and Mckee, 1999; Davis and Brown, 2002; Ferreira et al., 2002; Gandini et al, 2003; Olby et al., 2003; Brisson et al., 2004; Sharp and Wheeler, 2005; Ito et al., 2005; Ruddle et al., 2006; Dunie-Merigot et al., 2007; Levine et al., 2007; Bruce et al., 2008 de Risio et al., 2008).

* Time since lost of deep pain perception until surgical decompression.

Inflammatory and infectious diseases tend to be multifocal and their prognosis depends on the infectious agent involved and the length of treatment (Platt and Olby, 2004; Bagley, 2005; Dewey, 2008). The prognosis for dogs with discospondylitis is considered to be good; however long-term treatment with antimicrobial drugs (mean duration of 53.7 weeks in one study (Burkert et al., 2005) and cage rest confinement are recommended (Platt and Olby, 2004; Bagley, 2005; Dewey, 2008).

1.8 The effect of treatment modality on outcome

1.8.1 Surgery decompression and fenestration

Different surgical parameters have been examined in dogs following intervertebral disc disease. The duration of anaesthesia or surgery has been shown not to correlate with the time to ambulation (Davis and Brown, 2002). The presence of extensive haemorrhage did not seem to affect the prognosis in dogs with intervertebral disc disease if extensive decompressive surgery was performed (Tartarelli et al., 2005). Despite the fact that some authors consider durotomy a diagnostic technique for myelomalacia, euthanasia based on macroscopic changes during a durotomy is not recommended (Olby et al., 2003; Sharp and Wheeler, 2005). The decompressive effect of durotomy in the presence of spinal cord swelling is unknown, but performing a durotomy has not been shown to have any effect on the post-operative recovery of voluntary motor function (Anderson et al., 1991; Loughin et al., 2005; Laitinen and Puerto 2005).

A dorsolateral hemilaminectomy is considered the decompressive technique of choice for thoracolumbar intervertebral disc disease (Sharp and Wheeler, 2005). Most studies comparing hemilaminectomy with dorsal laminectomy in dogs with intervertebral disc disease found no significant difference in the long term outcome between the two techniques (McKee, 1992; Muir et al. 1995; Dhupa et al., 1999a; Laitinen and Puerto, 2005). The only difference was that dogs where a hemilaminectomy was performed had a better neurological status immediately

after surgery, suggesting less manipulation of the spinal cord was required during surgery (Muir et al., 1995).

The influence of fenestration on the recurrence of intervertebral disc disease remains controversial. Less recurrence of intervertebral disc disease in dogs has been reported where hemilaminectomy and fenestration was performed than where a dorsal laminectomy alone was performed (McKee, 1992). A large retrospective study demonstrated no significant difference between recurrence rates in dogs that underwent prophylactic fenestration as compared to those, which did not (Brisson et al., 2004). However, a recent prospective study concluded that multiple site disc fenestration decreased the rate of recurrent intervertebral disc herniation in small breed dogs when compared with the use of single site fenestration (Brisson et al., 2011).

1.8.2 Conservative treatment and medications

Strict cage rest is the most important component of a conservative treatment regime in dogs with intervertebral disc disease. A minimum duration of 4 to 6 weeks has been recommended on the basis that this is presumed to be the minimum time needed for the annulus fibrosus to repair (Sharp and Wheeler, 2005). However, evaluation of the efficacy of conservative management in intervertebral disc disease found no association between the length of cage rest and a successful outcome (Levine et al., 2007). When conservative treatment is used then the outcome is better in ambulatory than non-ambulatory dogs (Davies and Sharp, 1983; Sharp and Wheeler, 2005; Levine et al., 2009).

The use of different steroid treatment protocols have been shown to have no influence on the outcome of dogs with spinal cord injuries (Davis and Brown 2002; Laitinen and Puerto, 2005; Loughin et al., 2005; Levine et al. 2007; Bull et al., 2008; de Risio et al., 2008; Levine et al., 2008). However these findings are difficult to interpret in light of the wide range of treatment protocols and treatment timing in these studies. A higher prevalence of adverse effects have been reported in dogs receiving dexamethasone (Levine et al., 2008). In human patients a revision study (Hurlbert, 2001; Scivoletto and di Donna, 2009)

concluded that steroid administration has yet to be unequivocally linked to neurological improvement following spinal cord injury (Hurlbert, 2001; Scivoletto and Di Donna, 2009).

1.8.3 Physiotherapy

No significant correlation has been demonstrated between the use of physiotherapy as part of the treatment regime and the outcome in dogs with suspected ischaemic myelopathy (Gandini et al., 2003; de Risio et al., 2008). However, dogs with more severe neurological dysfunction were more likely to undergo physiotherapy than were dogs with milder deficits. Dogs with suspected degenerative myelopathy receiving intensive physiotherapy had longer survival times and remained ambulatory for longer periods of time than animals that did not receive physical treatment (Kathmann et al., 2006).

1.9 Aims of this Thesis

There are a large number of variables that may help in the prediction of the prognosis or influence the outcome. However, attempts to investigate these factors have been complicated by the variability in the measures of outcome and the small group size of many of the studies. An additional complication of any analysis of historically published data is the change in the standard procedures to investigation spinal cord disease in dogs with the advent of MRI. The major determinant of outcome is the clinical severity, but many of the recent fine discrimination grading scales are not amenable to rapid clinic use and therefore the most clinically applicable grading scale is still the 0 to V grading scale. In light of this the major aims of this thesis were:

1. To describe the historical trends in the choice of diagnostic imaging technique in dogs with thoracolumbar spinal cord diseases at a referral institution.

2. To evaluate the effects of choice of diagnostic imaging technique on the neurological grade at discharge and the speed of recovery in dogs with thoracolumbar spinal cord disease.
3. To describe the frequency and distribution of intervertebral disc disease, ischaemic myelopathy and trauma in dogs with thoracolumbar spinal cord disease of different ages and weights.
4. To evaluate the effects of age and weight on the neurological grade at discharge and the speed of recovery in a large cohort of dogs with intervertebral disc disease, suspected ischaemic myelopathy and vertebral fracture and luxation.
5. To identify if the cutaneous trunci reflex could be used as a localising and grading tool in dogs with thoracolumbar spinal cord diseases.

CHAPTER II

2 MATERIALS AND METHODS

2.1 Case selection and data collection

2.1.1 Retrospective case selection and data collection

Cases for inclusion in Chapters III and IV were retrospectively selected. All dogs with a diagnosis of thoracolumbar (T3-L3) intervertebral disc disease, suspected ischaemic myelopathy and traumatic spinal cord injuries presented to the Small Animal Hospital, School of Veterinary Medicine, University of Glasgow, between January 2000 and December 2010 were included in the study. Five hundred and thirty two cases met the inclusion criteria and were included in this part of the study.

Data collected for each case included: diagnosis, age, weight, breed, gender, date of onset, date of presentation, neurological grade at presentation and discharge, length of hospitalisation, imaging modality, treatment (medical or surgical) and whether the dog was euthanased at presentation or during the hospitalisation period. The neurological grade at presentation and discharge was assessed using the standard 0 to V grading system (Table 1). The duration of the neurological signs was defined as the time interval from the onset of the clinical signs until presentation at the University of Glasgow Veterinary School. Patients were categorised into two groups on the basis of the duration of their neurological signs: 1) a short duration of neurological signs (≤ 7 days), and 2) a long duration of neurological signs (> 7 days). The length of hospitalisation was defined as the time from presentation to the University of Glasgow Veterinary School to discharge. Radiography, myelography and CT were available during the all study period. MRI became intermittently available from 2001 (once and then twice a week) and permanently available from 2009. If more than one imaging modality was used, the one that gave the most information for the final diagnosis was recorded. Case management included surgical and conservative treatment. The main surgical treatment was hemilaminectomy with fenestration of the affected intervertebral disc, with or without fenestration of adjacent intervertebral discs. In selected cases vertebral body plating was used. Conservative cases were treated with strict confinement if spinal cord compression or instability was diagnosed or suspected, and with physiotherapy if no spinal cord compression or instability was diagnosed or suspected. The speed

of recovery was evaluated by calculating the average grade of improvement per day of hospitalisation using the formula: ((neurological grade at presentation - neurological grade at discharge) / days of hospitalisation).

2.1.2 Prospective case selection and data collection

Cases for inclusion in Chapter V were prospectively selected. Forty-seven dogs were included in this part of the study. All dogs presented with spinal cord disease localised to the thoracolumbar spinal cord segments (T3-L3) were included. Complete physical and full neurological examinations were performed in all cases. Nociception (deep pain perception) was tested in paraplegic animals by applying pressure to the digits and tail using haemostat forceps and recording the conscious response. Serum biochemistry profiles and complete blood cell counts were performed in all animals. Data collected for each animal included the age, breed, gender, duration of neurological signs and diagnosis. The duration of the neurological signs was defined as the time interval from onset of clinical signs until presentation and it was categorised as short duration (≤ 7 days) or long duration (> 7 days).

2.2 Diagnostic imaging techniques

2.2.1 Diagnostic imaging techniques in the retrospective cases

The diagnostic imaging techniques used in the cases included in Chapters III and IV comprised survey radiography, myelography, CT-myelography and MRI. Where survey radiography was included as the diagnostic imaging technique, this included lateral and ventrodorsal radiographs of the thoracolumbar spine either as the only diagnostic imaging technique or prior to myelography (Zoomax, Control-X-Medical, Ltd, USA and Multix Fusion, Siemens, Camberley, United Kingdom). Myelography was performed by injecting ioversol (Optiray 300mg/ml, Tyco Healthcare) into the subarachnoid space at the cisterna magna, caudal lumbar spine or both. Lateral and ventrodorsal radiographic projections were obtained in all cases and oblique radiographic views were obtained in selected cases. CT-myelography was performed with a computed tomography scanner

(CT twin Flash, Elscint Ltd, Israel). In all cases where it was undertaken, it was performed after conventional myelography in order to further categorise the lesion type, in terms of localisation and lateralisation. This was particularly the case where the myelographic study encountered technical problems interfering with the diagnostic quality of the study or where adverse effects of the myelogram were observed on the patient during anaesthesia. MRI was performed with a 1.5-Tesla MRI system (Gyrosan ACS NT, Philips Medical System, Eindhoven, the Netherlands, or Magnetom, Siemens, Camberley, United Kingdom). The MRI studies included the following sequences in the majority of cases: T2-weighted images in the dorsal, sagittal and transverse planes and T1-weighted images in the sagittal and transverse planes of the thoracolumbar spine (from the third thoracic vertebrae to the caudal lumbar spine). Selected cases also included the following sequences: T1-weighted post-intravenous contrast images (gadopentetate dimeglumine, Magnevist; Bayer HealthCare Pharmaceuticals, UK) and T2* gradient-echo images.

2.2.2 Diagnostic imaging techniques in the prospective cases

Diagnostic imaging was used prospectively in the cases included in Chapter V to localize the lesion and provide a diagnosis. MRI of the thoracolumbar spine was performed under general anaesthesia in 41 dogs, using a 0.5, 1 or 1.5 tesla system (Aperto, Hitachi; Gyrosan ACS NT, Philips Medical System; Magnetom, Siemens). T2-weighted images of the thoracolumbar spine were acquired in the sagittal and transverse plane in all cases. A variety of other sequence types and orientations were obtained in order to further characterise the lesion, the choice of which depended on the individual case. In 6 dogs the lesion was characterised using radiography of the thoracolumbar spine, including lumbar myelography in 5 dogs (comprising intrathecal injection of 0.4ml/kg Ioversol [Optiray 300mg/ml, Tyco Healthcare]) (Zoomax, Control-X-Medical, Ltd, USA and Multix Fusion, Siemens, Camberley, United Kingdom) and CT imaging in one dog (CT twin Flash, Elscint Ltd, Israel). Lateral and ventrodorsal radiographic projections were obtained in all cases and oblique radiographic views were obtained in selected cases. The final diagnosis, lesion lateralisation (right, left or midline), total lesion extent (vertebral length), maximal lesion level

(vertebral level) and lesion cranial extent (vertebral level) were recorded. The maximal lesion level was defined as the vertebral level demonstrating the greatest spinal cord compression, signal change or contrast medium attenuation. The cranial lesion extent was defined as the vertebral level corresponding to the cranial extent of any spinal cord signal change or subarachnoid space attenuation.

2.3 Age analysis

The influence of the age at presentation on recovery was assessed in two different ways. The first way was to consider age as a continuous variable and the second was to select two extreme age groups. The dogs were divided into a young group (dogs of ≤ 3 years) and an old group (dogs of ≥ 9 years) and both groups were compared.

2.4 Breed size and weight analysis

The influence on recovery of the breed size and weight at presentation was assessed in two different ways. The first way was to consider weight as a continuous variable and the second was to select two extreme weight groups. The dogs were divided into a small breed group (dogs of ≤ 10 Kg) and a large breed group (dogs of ≥ 25 Kg) and both groups were compared.

2.5 Cutaneous trunci reflex

The cutaneous trunci reflex was recorded for all dogs prospectively selected for inclusion in Chapter V. This was elicited in all dogs using haemostat forceps prior to any further investigation. The skin was pinched unilaterally on each side of the dorsal spinous processes approximately 1-2 cm lateral to the midline, starting at L7 dorsal spinous process. If no cutaneous trunci reflex response (bilateral skin twitching) was observed after three attempts then the same procedure was repeated at the next dorsal spinous process cranially. This was repeated for every spinous process until a response was elicited, or until the level of T1 dorsal spinous process. The presence or absence of a cutaneous trunci reflex was recorded on the left and right. If a cutaneous trunci reflex

cut-off was identified, the vertebral level of the cut-off was recorded by counting cranially from the L7 dorsal spinous process.

2.6 Clinical grading

The clinical grade was determined for all dogs prospectively selected for inclusion in Chapter V using video gait analysis. All dogs were videotaped from the side and from behind, walking on a lead for a minimum of ten steps on a smooth, non-slippery surface. Non-ambulatory dogs were videotaped while supported by holding the tail base to allow non-weight bearing voluntary movements of the pelvic limbs to be assessed (Olby et al., 2001). The gait was independently scored by two of the authors using the standard 0 to V grading system (Sharp and Wheeler, 2005) (Table 1) and the 14-point grading system (Olby et al., 2001) (Table 4). The mean score for each grading system was calculated for each dog. In dogs with asymmetrical clinical signs the grade of the most severely affected limb was used as the final grade.

2.7 Statistical analysis

Data were analysed using commercially available software (Minitab, Minitab Inc.). Descriptive statistics were reported as mean, range and standard deviation (sd).

2.7.1 Statistical analysis in the retrospective cases

The statistical analysis used in the cases included in Chapters III and IV comprised the following: The two outcome variables were (1) grade of improvement per day of hospitalisation and (2) length of hospitalisation. Both were treated as continuous variables and a general linear model was used to test the significance of possible explanatory variables (diagnosis, age, age group, breed, gender, weight, weight group, duration of signs, grade at presentation, imaging technique of choice and treatment). Variables with $P < 0.3$ on the univariable analysis were considered for inclusion in the multivariable general linear model. Variables were selected for inclusion in the final model if they

significantly improved the fit. $P < 0.05$ was considered significant. Binary logistic regression was tried but did not fit the data. For the average of grade improvement per day only dogs where the neurological grade was recorded at presentation and discharge and with a neurological grade at presentation from III to V were included (n=129 cases). Patients with neurological grades I and II at presentation were excluded from the analysis, because with the grading scale used we are unable to quantify a real improvement in those cases. For the length of hospitalisation all patients where the neurological grade was recorded at presentation and discharge and that were not euthanased were included (n=212 cases).

2.7.2 Statistical analysis in the prospective cases

The statistical analysis used in the cases included in Chapter V comprised the following: Linear regression analysis was performed to determine the relationship between the vertebral level of the cutaneous trunci reflex cut-off and the maximal lesion level and the cranial lesion extent. The hypothesis that cutaneous trunci reflex cut-off was associated with more severe spinal cord injury was tested using a Mann Whitney test, with one-tailed significance defined as $P < 0.05$.

CHAPTER III

3 CHANGING DIAGNOSTIC IMAGING TRENDS FOR CANINE THORACOLUMBAR SPINAL DISEASE AND ITS INFLUENCE ON OUTCOME (2000-2010)

3.1 Introduction

Intervertebral disc disease, ischaemic myelopathy and trauma are frequently reported in dogs with thoracolumbar spinal cord disease and their investigation and differentiation almost invariably requires the use of diagnostic imaging techniques (Platt and Olby, 2004; Sharp and Wheeler, 2005). Spinal radiographs are less invasive than myelography and may facilitate detection of vertebral fractures, vertebral luxation and intervertebral disc disease, but lack the ability to assess for the presence and localisation of spinal cord compression or injury. Non-contrast radiography has been reported to only be between 51% and 70% accurate in identifying the exact location of spinal cord compression in dogs with intervertebral disc disease (Kirberger et al, 1992; Olby et al, 1994; Lamb, 2002).

Following the development of radiographic contrast media, particularly the non-ionic, water-soluble iodine-based contrast media, myelography was adopted as the standard technique for investigation of spinal cord compression in dogs where a definitive diagnosis was not possible on survey radiographs (Funkquist, 1962; Kirberger et al., 1992; Olby et al., 1994). While performing the myelographic study a number of technical problems may arise, including injection of contrast medium into the central canal (Kirberger et al., 1993; McCartney, 1997), subdural space (Penderis et al., 1999) and epidural space, or poor distribution of contrast medium making lesion identification and characterisation difficult (Funkquist, 1962; Allan and Wood, 1988; Widmer and Blevins, 1991; Lamb, 1994). Related to the more invasive nature of the technique and the injection of foreign material (contrast medium) into the subarachnoid space, myelography is also associated with a number of adverse patient effects, including transient apnoea, seizures on recovery from anaesthesia, exacerbation of neurological signs (Kirberger et al., 1993), intracranial subarachnoid haemorrhage (Packer et al., 2007), cardiac arrhythmias (Carroll et al., 1997) and death (Funkquist, 1962; Adams and Stowater, 1981; Wright and Clayton, 1981; Allan and Wood, 1988; Widmer and Blevins, 1991; Butterworth and Gibbs, 1992; Lewis and Hosgood, 1992). The reported accuracy of myelography for lesion localisation in dogs with intervertebral disc disease ranges from 40 to 97% (Wright and Clayton, 1981; Allan and Wood, 1988; Butterworth and Gibbs, 1992; Kirberger et al., 1992; Olby

et al., 1994; McCartney, 1997; Olby et al., 1999; Israel et al., 2009).

CT is an advanced diagnostic imaging technique that is particularly useful for the investigation of vertebral column disorders. However, when used for the assessment of spinal cord lesions there is usually the requirement for subarachnoid injection of contrast media. This technique is termed CT-myelography, and although lower quantities of contrast medium are usually required compared to conventional myelography, the technique is essentially equivalent to conventional myelography with similar technical problems and patient-related adverse effects. CT without contrast has been used to investigate Hansen type-I intervertebral disc disease, and where the disc material is calcified the technique has a reported accuracy of 81 to 90% for lesion identification (Olby et al., 1999; Olby et al., 2000; Israel et al., 2009). CT myelography has been reported to have an accuracy of 94% for detection of intervertebral disc extrusion and CT with intravenous contrast medium injection of contrast medium had an accuracy of 97% in the same study (Schroeder et al., 2011)

MRI has only become routinely available for the investigation of spinal disease in canine patients over the past 10 to 15 years. Since its introduction into the veterinary field it has become progressively more widely available and has influenced the way in which spinal cord disease is investigated in dogs. MRI is considered to be less invasive, associated with fewer adverse effects and to provide greater detail of the soft tissue structures of the vertebral column and spinal cord than other diagnostic imaging modalities as myelography and CT. The availability of MRI in veterinary medicine has resulted in the description of, and differentiation between, a variety of spinal disorders in dogs in a manner not previously possible, including intervertebral disc disease (Besati et al., 2006), ischaemic myelopathies (Abramson et al., 2005) and traumatic spinal cord injuries (Gopal and Jeffery, 2001; Chang et al., 2007). The advent of MRI for the investigation of spinal disorders in human patients initially caused a greater awareness of spinal disorders resulting in the increased use of other spinal diagnostic imaging modalities (including radiography, myelography and CT-myelography) before these techniques started to decline to be largely replaced by MRI. The use of MRI for imaging the vertebral column and spinal cord in

human patients has therefore significantly increased during the past two decades (Ackerman et al., 1997; Maitino et al., 2003).

Although there are a large number of reports detailing the use of MRI in the investigation of canine thoracolumbar spinal diseases, little is known about the historic trends in the choice of imaging technique for investigating thoracolumbar spinal cord disease in dogs and whether this altered choice has affected prognosis. Investigation of the effect of choice of imaging technique on outcome has suggested there is no influence on outcome between myelography and CT in dogs with intervertebral disc disease (Olby et al., 2004) and between myelography and MRI for the investigation of thoracolumbar spinal cord disorders (Parry et al., 2010). The choice of diagnostic imaging technique was substantially affected by availability, cost limitation and acceptance of the technique by veterinary surgeons and owners in all these studies.

The aims of this part of the study were to describe the historical trends in the choice of diagnostic imaging technique in dogs with thoracolumbar spinal cord disease at a referral institution, and to evaluate the effects of this change on the speed of recovery and neurological grade at discharge in these patients.

3.2 Results

3.2.1 *Animals*

Five hundred and thirty two dogs met the criteria for inclusion in the study. The mean neurological grade at presentation was 3.18 (range: 1-5; sd: 1.12) and at discharge was 2.39 (range: 1-5; sd: 0.59). The duration of neurological signs was classified as short in 80.5% and as long 19.5% of the cases. Surgery was performed in 64% of the cases. The mean length of hospitalisation was 7.83 days (range: 1-44; sd: 7.17). Euthanasia was performed in 9.74% of the dogs, 5.08% following imaging and 4.66% during the hospitalisation period.

3.2.2 Historical trends in the choice of diagnostic imaging technique

The choice of diagnostic imaging modality in the referral institution for the entire 11 years was as follows: non-contrast radiography was performed in 6% of cases, myelography in 28% of cases, CT-myelography in 5% of cases and MRI in 61% of cases. However, the introduction of MRI resulted in a dramatic change in the choice of diagnostic imaging modality (Figure 1). Initially the introduction of MRI in 2001 resulted in an increase in the number of myelograms performed, but over the following years as MRI became more accepted and established for the investigation of spinal disorders in dogs the use of myelography dramatically declined and MRI became the diagnostic imaging modality of choice for the investigation of canine thoracolumbar spinal cord disease. The use of CT-myelography remained reasonably constant as a proportion of the total myelograms performed, but the use of non-contrast radiography in order to investigate thoracolumbar spinal cord injuries declined markedly.

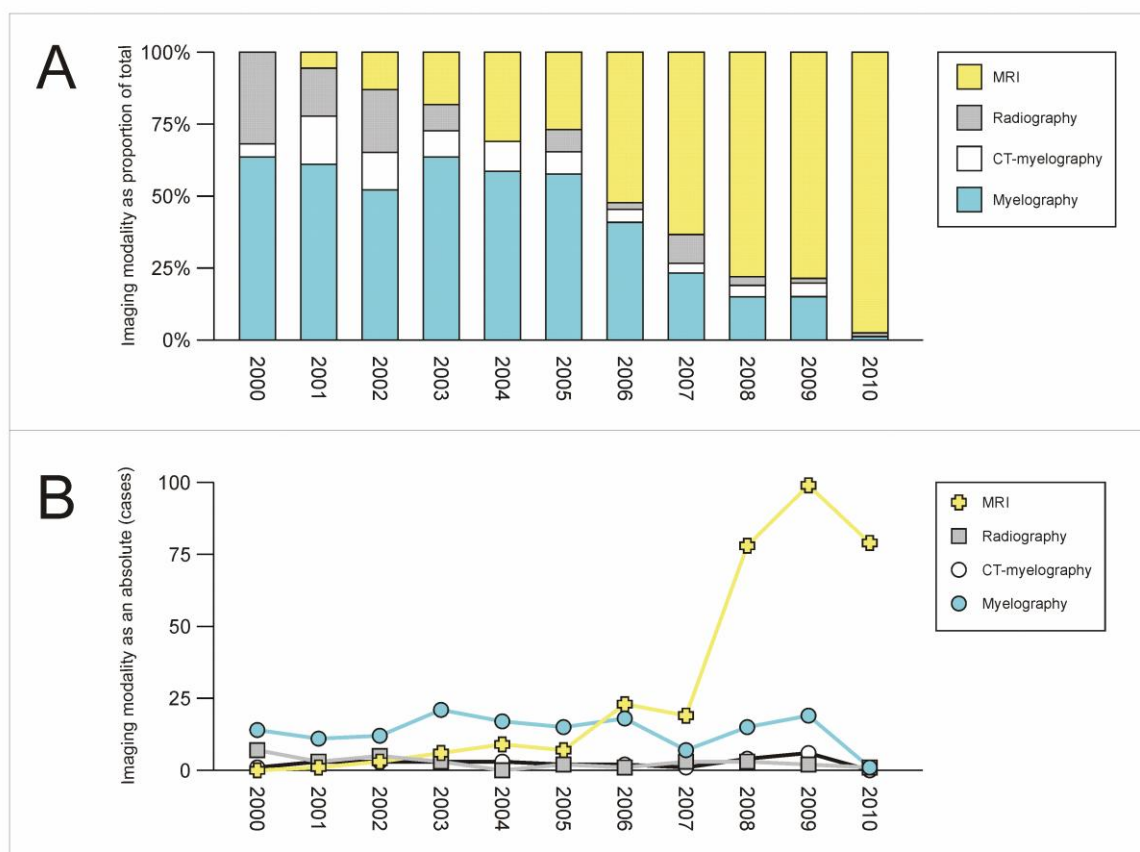


Figure 1 Historical changes in the choice of diagnostic imaging modality for the investigation of canine thoracolumbar spinal cord disease following the introduction of MRI as a diagnostic imaging modality in a veterinary referral institution. A) Proportional representation of the choice of diagnostic imaging technique from 2000 to 2010 demonstrates that MRI has progressively replaced myelography, CT-myelography and survey radiographs for the investigation of canine thoracolumbar spinal cord disease. There is a progressive increase in the case numbers having MRI and a corresponding decline in case numbers having myelography, CT-myelography and radiography. B) Absolute case numbers for each of the four imaging modalities used for the investigation of canine thoracolumbar spinal cord disease.

3.2.3 Association between diagnostic imaging technique performed, clinical presentation and outcome

The results of the most important variables (neurological grade at presentation, neurological grade at discharge, duration of clinical signs prior to presentation and length of hospitalisation) for the different imaging modalities are presented in Table 6. The neurological grade at presentation was equally distributed between grades II to V for myelography patients. In contrast, prior to 2008 the majority of MRI patients (54%) were classified as grade II. Subsequent to this period the neurological grade at presentation was equally distributed within the MRI patients. In the cases that only had radiography performed 75% of these patients were either classified as grade II or as grade V. Adverse effects associated with myelography were observed in 0.6% of the cases and included post-myelographic seizures and bradycardia during anesthesia.

No statistical difference was found between the length of hospitalisation for any of the diagnostic imaging modalities. With the exception of myelography patients and the CT-myelography patients, with CT-myelography patients having an average hospital stay of over 4 days longer than myelography patients ($P=0.045$). The neurological grade at discharge and the average of grade of improvement per day of hospitalisation (calculated for all non-euthanased patients with a neurological grade of III to V at presentation) showed no statistical difference between any of the diagnostic imaging modalities. The average age and weight of dogs was similar in all the imaging technique groups. Comparison of the rates of euthanasia revealed that 38% of the non-contrast radiography patients, 10% of the myelography patients, 6% of the CT-myelography patients and 1% of the MRI patients were euthanased prior to discharge, but this was not statistically significant when neurological grade at presentation was considered.

	Radiography	Myelography	CT-Myelography	MRI
Mean neurological grade at presentation	3.6 (sd: 1.32)	3.4 (sd: 1.08)	3.89 (sd: 0.65)	2.53 (sd: 0.89)
Mean neurological grade at discharge	2.6 (sd: 1.32)	2.48 (sd: 0.62)	2.6 (sd: 0.63)	2.25 (sd: 0.52)
Mean length of hospitalisation (days)	4.2 (sd: 4.1)	8.53 (sd: 7.66)	14.06 (sd: 9.83)	6.46 (sd: 5.2)
Duration of clinical signs prior to presentation	Short: 95% Long: 5%	Short: 88% Long: 12%	Short: 94% Long: 6%	Short: 61.3% Long: 38.7%

Table 6 Mean neurological grade at presentation, mean neurological grade at discharge, mean length of hospitalisation and duration of clinical signs prior to presentation for the different imaging modalities.

3.3 Discussion

Following its first introduction into veterinary medicine, the use of MRI in neurological patients was initially primarily limited to the investigation of intracranial lesions (Gavin, 2011). However, over time and following the optimisation of hardware and software protocols in order to improve image resolution, MRI has progressively become accepted as a suitable imaging modality for the investigation of spinal lesions in dogs. The results of this part of the study indicate that MRI has largely replaced myelography and CT-myelography for the investigation of traumatic spinal cord lesions in dogs in a veterinary referral institution. While this study is limited to one center, it does provide an insight into the changes occurring within the veterinary profession following the introduction of new technology and techniques.

This change in the choice of diagnostic imaging technique can, in part, be explained by the greater soft tissue detail provided by MRI as compared to myelography. In the study of da Costa et al. (2006) MRI appeared to be more accurate in predicting the site, severity and nature of the spinal cord compression in dogs with cervical spondylomyelopathy. In humans, previous reports (Weisz et al., 1988; Jia and Shi, 1991; Kido et al., 1993) have suggested that MRI is as accurate or more accurate than myelography for the diagnosis of lumbar disc herniation, but with the added advantage of being a less invasive procedure. Similar trends in the use of MRI are apparent in human medicine over the past 15 years: for example the use of MRI for the investigation of lower back pain increased dramatically (Ackerman et al., 1997). Over the period 1993 to 1999, the use of MRI for the investigation of spinal disease in human patients increased by 78% (Maitino et al., 2003).

A further explanation for the change in choice of diagnostic imaging technique is the perceived invasive nature of myelography and CT-myelography with the potential for patient adverse effects that may impair the recovery grade and speed. A number of adverse effects have been associated with myelography in the dog (Funkquist, 1962; Adams and Stowater, 1981; Wright and Clayton, 1981; Allan and Wood, 1988; Widmer and Blevins, 1991; Butterworth and Gibbs, 1992; Lewis and Hosgood, 1992; Kirberger and Wrigley, 1993). Despite this, studies

have demonstrated no influence on outcome between myelography and non-contrast CT in dogs with intervertebral disc disease (Olby et al., 2004) and between myelography and MRI for the investigation of thoracolumbar spinal cord disorders (Parry et al., 2010). Likewise within this study the choice of myelography or MRI as the diagnostic imaging modality did not significantly affect either the neurological grade at discharge or speed of recovery. One potential explanation may be that the reported exacerbation of the neurological deficits reported after myelography is temporary, only lasting up to 4 days in most cases (Adams and Stowater, 1981; Butterworth and Gibbs, 1992; Lewis and Hosgood, 1992; Kirberger et al., 1993). An alternative explanation is that the 5-point grading scale used does not allow sufficiently fine discrimination between patients of different severity grades in order to identify subtle differences in outcome between the different imaging modalities (Olby et al., 2004). This part of the study demonstrates that myelography did not adversely affect the outcome prior to discharge in the majority of cases, however the analysis could not determine if there is a substantial negative effect in a small number of cases where myelography was used: there may be no complications in the majority of cases, but when they do occur they may be catastrophic. It is also important to consider that myelography was being done in an institution with high caseload and experienced operators so the outcome of myelography in less experienced hands might have been worse. However, the significant increase in the length of hospital stay for patients that had a CT-myelogram may indicate a population of patients in which the myelograms did have a detrimental effect. CT-myelography within the institution in which this part of the study was performed was largely limited to those patients where the routine myelogram was non-diagnostic or had to be abandoned due to technical problems or patient adverse effects related to the myelogram and it is likely that this increased length of hospital stay was directly ascribable to the myelographic procedure, rather than the CT procedure. One interpretation may therefore be that in the majority of cases (where no technical problems or patient adverse effects are encountered during the procedure), myelography does not affect the neurological grade at discharge or speed of recovery; however where these technical problems or patient adverse effects are encountered, that there is a significant effect on outcome. These patients were also then not included in the myelography group, potentially improving the apparent outcome within this group. The apparent

differences in the rate of euthanasia prior to discharge between the different diagnostic imaging modalities, were not statistically significant once the patient grade was taken into consideration for neurological grade at discharge or speed of recovery.

The higher prevalence of a low neurological grade at presentation and a long duration of clinical signs in the MRI cases prior to 2008 in this part of the study could be explained by the intermittent availability of MRI at the institution during that period (with, in general, once or twice weekly availability). The clinical urgency of patients with a high neurological grade at presentation would require rapid intervention and therefore myelography would be selected in these cases if MRI was not immediately available. An alternative explanation may be due to the perceived safety of MRI, that owners and clinicians were more inclined to pursue investigations in patients with low neurological grades at presentation with MRI to avoid the perceived risk of deterioration in these cases with myelography. Radiography as the only diagnostic imaging modality was mainly used in two groups of dogs: those with a low neurological grade at presentation (grade II) and those with a high neurological grade at presentation (grade V). In the dogs with a low neurological grade at presentation this imaging modality was most likely selected by owners who were reluctant to pursue further investigation (for financial or other reasons). In dogs with a high neurological grade at presentation, radiography was presumably selected as a rapid and cost-effective diagnostic screening method, before electing for euthanasia if these did not demonstrate an easily treated condition (in agreement with the high percentage of radiography cases euthanased prior to discharge). Within the cases included in the study, MRI was used in the diagnosis and assessment of vertebral fracture/luxation. The utility of MRI may be questioned in these cases (with, for example, CT providing greater bone detail), but reports in human medicine (Ramon et al., 1997, Selden et al., 1999) support the use of MRI in these patients, with the presence and extent of any intra-axial haematoma and the extent of spinal cord compression by extra-axial hematoma useful as a prognostic indicators.

The adoption of MRI as an imaging modality for canine patients has resulted in a dramatic change in this veterinary referral institution in the choice of diagnostic

imaging modality for thoracolumbar spinal cord injuries in dogs. MRI has largely replaced myelography as the technique of choice for the evaluation of canine patients. Despite the perceived increased patient safety and relatively non-invasive nature of MRI, as compared to myelography and CT-myelography, this part of the study did not demonstrate a difference in outcome between MRI and myelography when measured as neurological grade at discharge or speed of recovery.

CHAPTER IV

4 THE INFLUENCE OF AGE AND WEIGHT ON RECOVERY IN DOGS WITH THORACOLUMBAR SPINAL CORD DISEASE

4.1 Introduction

The age and weight of the patient on presentation are two variables that are easy to obtain and could have an influence on the outcome of dogs with thoracolumbar spinal cord disease (Dhupa et al., 1999a; Davis and Brown, 2002; Olby et al., 2004; Kathmann et al., 2006; Penning et al., 2006; Bull et al., 2008). Different aetiologies often demonstrate specific age and weight predispositions, making it more difficult to understand the role of these variables on the outcome (Platt and Olby, 2004; Dewey, 2008). Despite the fact that intervertebral disc disease, ischaemic myelopathy and trauma are more frequent in specific age and weight groups, they can and do affect dogs of any age and weight, and therefore it is possible to compare outcomes between dogs of very different ages and weights (Platt and Olby, 2004; Dewey, 2008; Brisson, 2010).

The number of elderly veterinary patients seems to have grown considerably in the past few decades (Fluehmann et al., 2006). The animal's age is sometimes used as a factor during the decision making process to decide whether or not to perform further diagnostics tests or treatment. It would be logical to assume that young dogs with thoracolumbar spinal cord injuries have a better prognosis because of the greater degree of plasticity in the juvenile nervous system. However, the current literature is confusing when the impact of age is considered on the grade and speed of recovery in dogs with thoracolumbar spinal cord disease. Some studies have demonstrated no correlation between the animal's age and the outcome (Dhupa et al., 1999a; Davis and Brown, 2002; Olby et al., 2004; Kathmann et al., 2006; Penning et al., 2006; Bull et al., 2008), while others found that a successful outcome was more likely in younger dogs (Macias et al., 2002; Levine et al., 2007) and that the speed of recovery was more rapid in younger dogs (Olby et al., 2003). It is difficult to compare the different studies because some of the studies considered age as a continuous variable, while others compared groups of dogs with a specific age range. Another important consideration was that the numbers of young and old patients were limited in these studies and therefore they did not address the trends in these categories of patients.

Body weight, and indirectly breed size, is another variable where the influence on outcome remains controversial. Some reports found no correlation between the animal's body weight and the outcome (Dhupa et al., 1999a; Macias et al., 2002; Olby et al., 2004; Kathmann et al., 2006; Ruddle et al., 2006), but others described that the speed of recovery (Cudia and Duval, 1997; Olby et al., 2003) and the prognosis (Hawthorne et al., 2001; Bull et al., 2008) was negatively influenced by the weight of the dog, with heavier dogs associated with a longer recovery and a poorer prognosis.

The aims of this part of the study were to retrospectively describe the frequency and distribution of intervertebral disc disease, ischaemic myelopathy and trauma in dogs with thoracolumbar spinal cord disease of different ages and weights, and to evaluate the effects of the dog's age and weight at presentation on the neurological grade at discharge and the speed of recovery.

4.2 Results

4.2.1 Animals

Five hundred and thirty two dogs met the criteria for inclusion in the study. The mean age was 6 years (range: 0.25-12.33; sd: 2.5). The mean weight was 16.5kg (range: 2.5-52; sd: 10.7). Sixty-seven percent (67%) of the dogs were males. The most common breeds were the Dachshund (14%), Cocker spaniel (11%), Lhasa-Apso (7%), Cavalier King Charles spaniel (6%), Labrador retriever (5%), Shih-tzu (4%), Basset hound (4%), Border collie (4%) and Staffordshire bull terrier (3%). The most common diagnosis was intervertebral disc disease (76.2%) followed by suspected ischaemic myelopathy (19.1%) and vertebral fracture and luxation (4.7%). In the dogs with a diagnosis of intervertebral disc disease, 75% were classified as Hansen type-I intervertebral disc disease, 8.8% were classified as Hansen type-II intervertebral disc disease and 16.2% were unclassified (Figures 2 and 4). The mean neurological grade at presentation was 3.18 (range: 1-5; sd: 1.12) and at discharge was 2.39 (range: 1-5; sd: 0.59). The duration of neurological signs was classified as short in 80.5% and as long 19.5% of the cases. Surgery was performed in 64% of the cases. The mean length of hospitalisation

was 7.83 days (range: 1-44; sd: 7.17). Euthanasia was performed in 9.74% of the dogs, 5.08% following imaging and 4.66% during the hospitalisation period.

The mean age for Hansen type-I intervertebral disc disease was 6.2 years (range: 1-12.33; sd: 2.47), for Hansen type-II intervertebral disc disease 7.54 years (range 2-11; sd: 2.42), for suspected ischaemic myelopathy 4.9 years (range: 0.25-10; sd: 2.31), and for vertebral fracture and luxation 4.23 years (range: 0-8.42; sd: 2.49).

The mean weight for Hansen type-I intervertebral disc disease was 13.72 Kg (range: 2.5-50; sd: 9.75), for Hansen type-II intervertebral disc disease 20.86 Kg (range 8-52; sd: 12.68), for suspected ischaemic myelopathy 21.7 Kg (range: 4.5-45; sd: 10.31), and for vertebral fracture and luxation 20.31 Kg (range: 7-45; sd: 10.69).

4.2.2 Analysis of age groups: Young group (≤ 3 years)

Twenty nine cases were dogs of 3 years of age or younger. The mean age was 2.24 years (range: 0.25-3; sd: 0.89). The mean weight was 13.78 kg (range: 2.5-45; sd: 11.38). Fifty-eight point six percent (58.6%) of the dogs were males. The most common breeds were the Lhasa-Apso (5 cases), Pekingese (3 cases) and Shih-Tzu (3 cases).

The most common diagnosis was type-I intervertebral disc disease (61.4%), followed by suspected ischaemic myelopathy (27.57%) and vertebral fractures and luxation (10.35%) (Figure 2).

The mean neurological grade at presentation was 3.55 (range: 2-5; sd: 1.15) and at discharge 2.53 (range: 1-5; sd: 0.58). The duration of neurological signs was short in 89.65% and long in 10.35%. Surgery was performed in 58.62% of the cases. The mean length of hospitalisation was 9.38 days (range: 1-35; sd: 9.24) and a mean of improvement per day of 0.11. Euthanasia was performed in 10.34% of the dogs, all immediately following imaging.

4.2.3 Analysis of age groups: Old group (≥ 9 years)

Forty-one cases were dogs of 9 years of age or older. The mean age was 9.93 years (range: 9-12.33; sd: 0.92). The mean weight was 17.62 kg (range: 5.3-45; sd: 10.03). 55.17% of the dogs were males. The most common breeds were Cocker Spaniel (6 cases) and Cross breed (5 cases).

The most common diagnosis was Hansen type-I intervertebral disc disease (77.75%), followed by Hansen type-II intervertebral disc disease (12.2%) and suspected ischaemic myelopathy (9.75%). There were no cases of vertebral fractures or vertebral luxation (Figure 2).

The mean neurological grade at presentation was 2.98 (range: 1-5; sd: 1.06) and at discharge 2.38 (range: 1-3; sd: 0.63). The duration of neurological signs was short in 65.85% and long in 34.15%. Surgery was performed in 70.73% of the cases. The mean length of hospitalisation was 7.02 days (range: 1-28; sd: 5.87) and a mean of improvement per day of 0.085. Euthanasia was performed in 4.88% of the dogs, 2.44% immediately following imaging and 2.44% during the hospitalisation period.

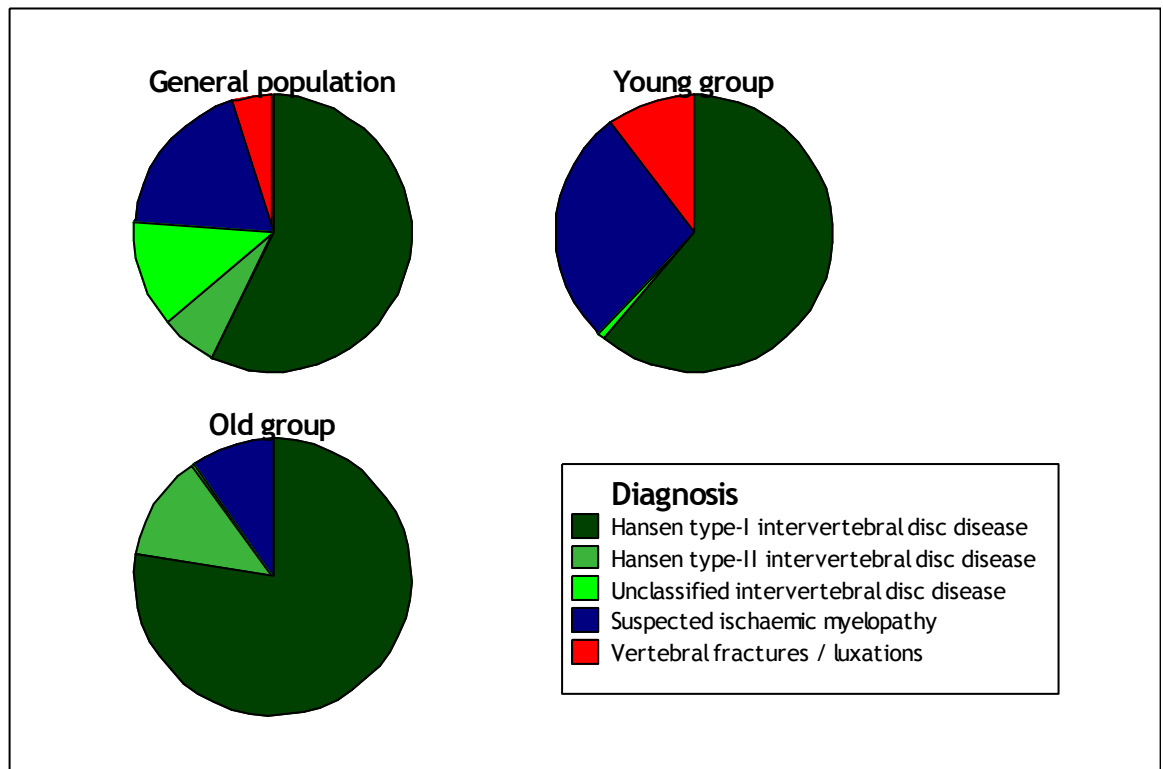


Figure 2 Distribution of diagnosis (intervertebral disc disease, suspected ischaemic myelopathy and trauma) in the general population, young group (dogs of ≤ 3 years) and old group (dogs of ≥ 9 years).

4.2.4 Influence of age on speed and grade of recovery

Age was not significantly associated with length of hospitalisation or grade of improvement per day of hospitalisation (Figure 3). Eighteen cases in the young group and 23 cases in the old group had a grade at presentation between III-V and were included for analysis of the effect of age group on the outcome. However, no significant difference was apparent when comparing the length of hospitalisation or the grade of improvement per day of hospitalisation between the different age groups.

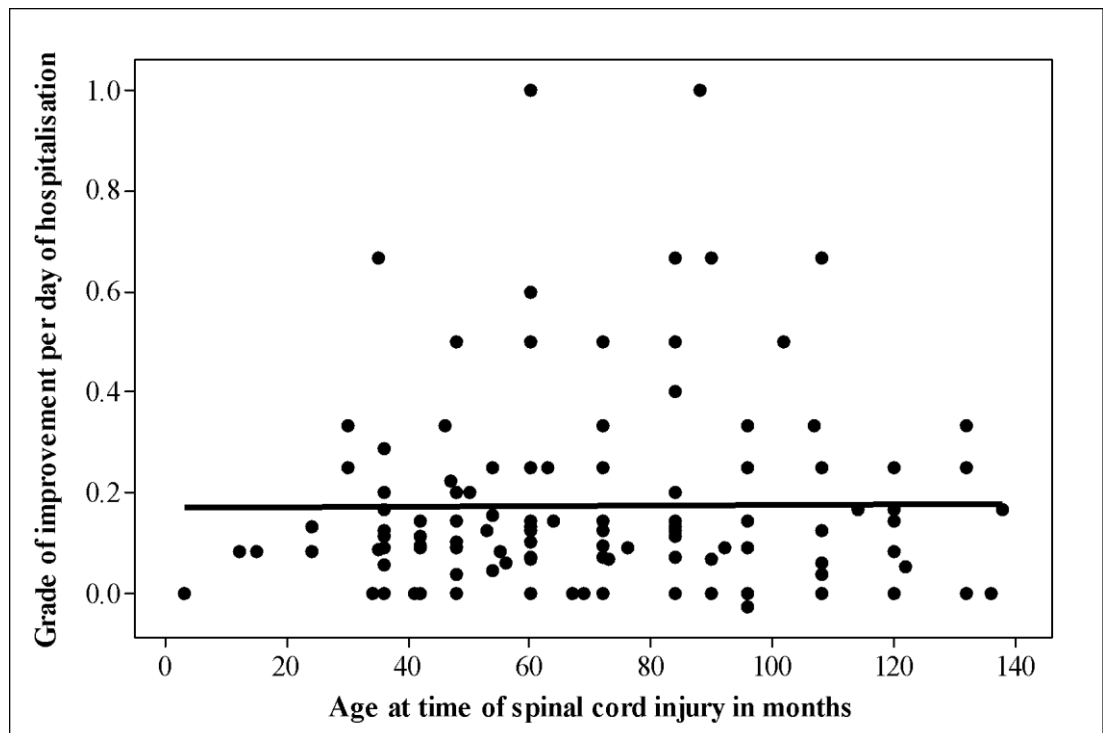


Figure 3 Grade of improvement per day of hospitalisation in relation to the age at the time of spinal cord disease in 129 dogs. Linear regression demonstrated no correlation between the grade of improvement per day of hospitalisation and the dog's age. The grade of improvement per day of hospitalisation = $0.1698 + 0.000057 \text{ age}$, $R^2=0$, $P=0.922$.

4.2.5 Analysis of weight groups: Small breeds group

Ninety-two cases were dogs of 10kg or less. The mean body weight was 6.94kg (range: 2.5-10; sd: 1.78). The mean age was 5.25 years (range: 1-12.33; sd: 2.28). Sixty percent (59.78%) of the dogs were males. The most common breeds were the Dachshund (29 cases), Lhasa-Apso (12 cases), Shih-Tzu (10 cases) and Cavalier King Charles Spaniel (8 cases).

The most common diagnosis was Hansen type-I intervertebral disc disease (89.1%), followed by Hansen type-II intervertebral disc disease (4.35%), suspected ischaemic myelopathy (4.34%) and vertebral fractures or luxation (2.17%) (Figure 4).

The mean neurological grade at presentation was 3.2 (range: 1-5; sd: 1.13) and at discharge 2.44 (range: 1-5; sd: 0.62). The duration of neurological signs was short in 78.26% and long in 21.74%. Surgery was performed in 76.08% of the cases. The mean length of hospitalisation was 8.7 days (range: 1-35; sd: 7.35) and a mean grade of improvement per day of 0.087. Euthanasia was performed in 6.52% of the dogs, 5.43% immediately following imaging and 1.09% during the hospitalisation period.

4.2.6 Analysis of weight groups: Large breeds group

Fifty-three cases were dogs of 25kg or more. The mean body weight was 33.12kg (range: 25-52; sd: 6.8). The mean age was 6.44 years (range: 1.25-11.5; sd: 2.4). Seventy seven percent (77.36%) of the dogs were males. The most common breeds were the Labrador Retriever (10 cases), Basset Hound (8 cases) and German Shepherd Dog (7 cases).

The most common diagnosis was Hansen type-I intervertebral disc disease (47.2%), followed by suspected ischaemic myelopathy (38.5%), Hansen type-II intervertebral disc disease (11.33%) and vertebral fractures or luxation (2.97%) (Figure 4).

The mean neurological grade at presentation was 3.06 (range: 2-5; sd: 1.03) and at discharge was 2.41 (range: 2-4; sd: 0.54). The duration of neurological signs was acute in 75.47% of dogs and chronic in 24.53% of dogs. Surgery was performed in 50.94% of the cases. The mean length of hospitalisation was 7.33 days (range: 1-20; sd: 5.18) and the mean grade of improvement per day was 0.089. Euthanasia was performed in 7.55% of the dogs, 1.89% immediately following imaging and 5.66% during the hospitalisation period.

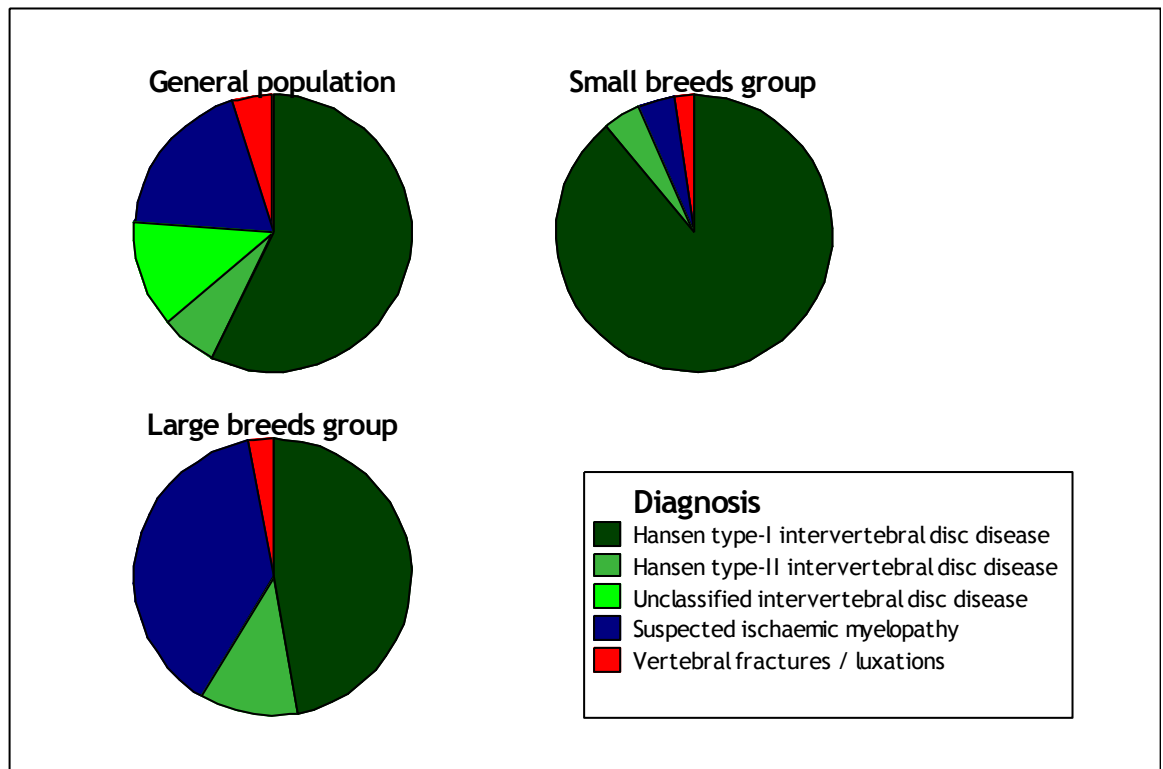


Figure 4 Distribution of diagnosis (intervertebral disc disease, suspected ischaemic myelopathy and trauma) in the general population, small breed group (dogs of $\leq 10\text{Kg}$) and large breed group (dogs of $\geq 25\text{Kg}$).

4.2.7 Influence of weight on speed and grade of recovery

Weight was not significantly associated with length of hospitalisation or grade of improvement per day of hospitalisation (Figure 5). Fifty five cases in the small breed group and 29 cases in the large breed group had a grade at presentation between III-V and were included for analysis of the effect of breed group on the outcome. No significant difference was evident between breed groups when the length of hospitalisation or the grade of improvement per day of hospitalisation were compared.

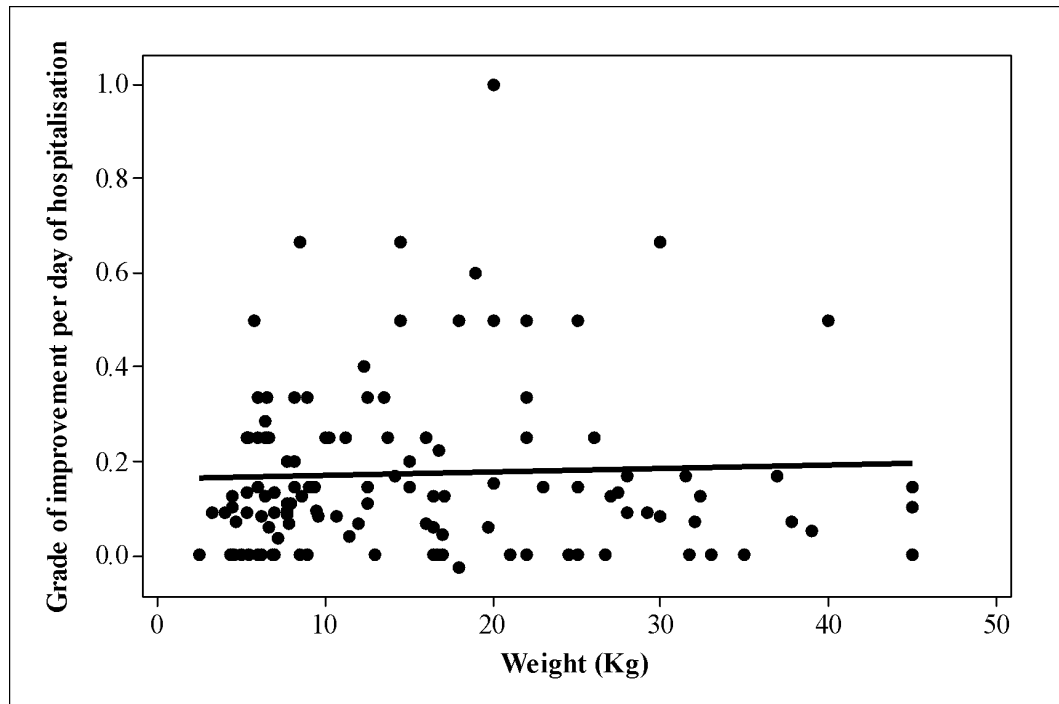


Figure 5 Grade of improvement per day of hospitalisation in relation to the weight at the time of spinal cord disease in 129 dogs. Linear regression demonstrated no correlation between the dog's weight and the grade of improvement per day of hospitalisation. Grade of improvement per day of hospitalisation = $0.167 + 0.000767 \text{ weight}$, $R^2=0.2$, $P=0.637$

4.3 Discussion

This part of the study analysed the influence of the age and weight at presentation on the grade and speed of recovery in a large population of dogs with thoracolumbar spinal cord disease. The results suggest that neither age nor weight affected the neurological recovery of these patients, with no significant difference even when comparing extreme groups of age or weight.

The mean age of dogs with Hansen type-I intervertebral disc disease, Hansen type-II intervertebral disc disease, suspected ischaemic myelopathy and trauma reported in the present study corresponded to the findings of previous reports (Cauzinille and Kornegay, 1996; Dhupa et al., 1999a; Davis and Brown, 2002; Gandini et al., 2003; Olby et al., 2004; Kathmann et al., 2006; Penning et al., 2006; Bruce et al., 2008; Bull et al., 2008; de Risio et al., 2008; Brisson, 2010). When evaluating the different age groups, Hansen type-I intervertebral disc disease was the most common diagnosis in both the young and old group, but represented a larger proportion of the cases in the old group. Suspected ischaemic myelopathy was almost 3 times more frequent in the young group and trauma was not reported in the old group. As would be expected in degenerative diseases, Hansen type-II intervertebral disc disease was not reported in the young group, consistent with the previous reported increased incidence of this disease in older dogs (Brisson, 2010). This prevalence of intervertebral disc disease also explains the longer duration of neurological signs and the higher frequency of surgical cases observed in the old group when compared to the young group.

When all variables were included in the statistical analysis no influence of the age at presentation on neurological grade at discharge or the speed of recovery was demonstrated, which is in accordance with the majority of the previous veterinary studies (Dhupa et al., 1999a; Davis and Brown, 2002; Olby et al., 2004; Kathmann et al., 2006; Penning et al., 2006; Bull et al., 2008). In a recent study in a large cohort of human patients with spinal cord injuries, age was not significantly associated with motor or sensory outcomes and the authors of the study suggested that the heterogeneity in the results of previous studies in part may be a consequence of the methodology of those studies (Furlan et al., 2010).

The mean weight of dogs with Hansen type-I intervertebral disc disease, Hansen type-II intervertebral disc disease, suspected ischaemic myelopathy and trauma correspond with those previously reported (Cauzinille and Kornegay, 1996; Dhupa et al., 1999; Davis and Brown, 2002; Gandini et al., 2003; Olby et al., 2004; Kathmann et al., 2006; Penning et al., 2006; Bruce et al., 2008; Bull et al., 2008; de Risio et al., 2008; Brisson, 2010). When the different weight groups were examined, Hansen type-I intervertebral disc disease was the most common diagnosis in both the small and large breed group, but represented a larger proportion of the cases in the small breed group. This finding can be explained by the increased frequency of Hansen type-I intervertebral disc disease in chondrodystrophic breeds, which are by definition small breeds (Brisson, 2010). The findings of this part of study also demonstrate that Hansen type-I intervertebral disc disease is relatively common in large breed dogs, representing around 50% of the cases in this group of dogs. Suspected ischaemic myelopathy is reported to occur more frequently in large breed dogs (Cauzinille and Kornegay, 1996; Gandini et al., 2003; de Risio et al., 2008) and that was evident in this part of my study. Vertebral fractures and luxations were as frequent in the large and small breed groups. As was evident in the analysis of the age groups, the variation in the incidence of different aetiologies in different weight groups also explains the higher frequency of surgical cases in the lower body weight (or small breed) group where Hansen type-I intervertebral disc disease was more common, when compared to the higher body weight (or large breed) group where suspected ischaemic myelopathy was more common (and which is a non-surgical condition).

When all the variables were included in the statistical analysis no influence of the weight at presentation on the neurological grade at discharge or speed of recovery was found, which is in accordance to the majority of the previous veterinary studies (Dhupa et al., 1999a; Macias et al., 2002; Olby et al., 2004; Kathmann et al., 2006; Ruddle et al., 2006). However, due to the retrospective nature of this part of the study, it was not possible to evaluate if individual body score had any effect on the prognosis. In human patients with spinal disease a higher body mass index has been associated with a significantly worse functional status (Fanuele et al., 2002). An important factor to consider is that the present

study was performed in a referral institution where management of recumbent large breed dogs was facilitated by the higher staff levels and better animal handling facilities. The management (and therefore the outcome) would likely be worse in recumbent large breed dogs in veterinary practices where staffing levels and facilities were less.

The main limitations of this part of the study are related to its retrospective nature. It was only possible to evaluate the short-term outcome during hospitalisation as the information for long-term follow up was not available for most of the cases. The 0 to V clinical grading scale used in this study also does not allow fine discrimination, but this was the only grading scale that could be used in light of the retrospective nature of the study.

In conclusion, the findings of this part of the study indicate that neither the age nor the body weight at presentation appear to have a significant effect on the neurological grade at discharge or speed of recovery of dogs with thoracolumbar spinal cord disease during the period of hospitalisation. Further studies evaluating the effect of these variables on the long-term outcome would be necessary.

CHAPTER V

5 THE CUTANEOUS TRUNCI REFLEX AS A LOCALISING AND GRADING TOOL IN DOGS WITH THORACOLUMBAR SPINAL CORD DISEASE

5.1 Introduction

The neurological examination remains an indispensable tool to localise and grade lesions affecting the spinal cord and is essential for accurate planning and interpretation of diagnostic imaging techniques and formulating the prognosis.

The cutaneous trunci reflex is a polysynaptic reflex with intersegmental transmission of impulses. It is elicited by pinching unilaterally the skin of the dorsal trunk between the second thoracic vertebra (T2) and the sixth to seventh lumbar vertebrae (L6 or L7) and observing a contraction of the cutaneous trunci muscles bilaterally (Holstege and Blok, 1989; Blight et al., 1990; Platt and Olby, 2004). The afferent axons from individual dermatomes enter the spinal cord approximately two vertebrae cranial to the level tested, but individual variability is evident. Within the spinal cord segment corresponding to each particular dermatome, the afferent neurons synapse on long inter-neurons at the level of the dorsal gray column and the axons of these long inter-neurons enter the fasciculus proprius of the spinal cord bilaterally. The axons course cranially to the eighth cervical (C8) and first thoracic (T1) spinal cord segments, where they terminate in the ventral gray matter columns and synapse with somatic neurons that give rise to the lateral thoracic nerve and innervate the cutaneous trunci muscles (Krogh and Towns, 1984; Holstege and Blok, 1989; Blight et al., 1990; de Lahunta and Glass, 2009). A focal spinal cord lesion interrupting this pathway results in loss of the cutaneous trunci reflex when dermatomes caudal to the level of the lesion are stimulated and this is known as a cutaneous trunci cut off.

The presence of a cutaneous trunci reflex cut-off can be used as an aid to localising lesions affecting the thoracolumbar spinal cord in dogs and guinea pigs (Fox, 1963; Borgens et al., 1990), but its accuracy in predicting lesion localisation has not been assessed in dogs. It has been suggested that the cutaneous trunci reflex may be absent in normal dogs (de Lahunta and Glass, 2009), however studies have shown that the reflex may be reliably demonstrated in the vast majority of normal dogs up to the vertebral level L6 (Fox, 1963;

Muguet-Chanoit et al., 2011) and the reflex is consistently affected in dogs with spinal cord disease cranial to L1 (Olby et al., 2004).

In addition to localisation, the neurological examination allows lesion severity to be graded in order to establish the prognosis. The various systems used and their limitations have been presented in section 1.5.

In this part of the study, the primary objectives were to 1) evaluate the accuracy of the level of cutaneous trunci reflex cut-off to localise canine thoracolumbar spinal cord disease in a cohort of clinical patients, and 2) to identify if there is a correlation between the clinical neurological grade at presentation and the loss of the cutaneous trunci reflex.

5.2 Results

5.2.1 Signalment and diagnosis

Forty-seven dogs were included. Mean age at presentation was 5.5 years (range: 0.4-10.9). There were 20 females (11 intact and nine spayed) and 27 males (23 intact and four neutered). Chondrodystrophic breeds comprised 32 cases. The most common individual breeds included the Dachshund (eight cases), Staffordshire bull terrier (five cases), Lhasa apso (three cases) and Border collie (three cases). The duration of clinical signs was classified as short (≤ 7 days since onset) in 38 cases (80.8%) or long (> 7 days) in nine cases (19.2%). After further investigations that depending on the case included radiography, myelography, CT-myelography, MRI, cerebrospinal fluid examination and tissue biopsy the following diagnoses were reached: degenerative intervertebral disc disease (26 cases, 54.2%), traumatic intervertebral disc extrusion (10 cases, 21.3%), neoplasia (four cases, 8.5%), ischaemic myelopathy (three cases, 6.4%), subarachnoid cyst (two cases, 4.2%), hemivertebra (one case, 2.1%) and vertebral subluxation (one case, 2.1%).

5.2.2 *The cutaneous trunci reflex as a localising tool*

The vertebral localisation of the maximal lesion level on the basis of diagnostic imaging was between the T8 and L3 vertebra in all cases, with the following distribution: T8-T9 in one case (2.1%), T9-T10 in one case (2.1%), T10-T11 in two cases (4.2%), T11-T12 in 10 cases (21.3%), T12-T13 in 17 cases (36.2%), T13-L1 in 11 cases (23.4%), L1-L2 in 3 cases (6.4%) and L2-L3 in two cases (4.2%) (Figure 6). In 85.4% of the cases the lesion extent was restricted to one or less than one vertebral body length, while in 14.6% the lesion extent was between one and two vertebral bodies in length. The lesion was lateralised to the right side in 11 cases (23.4%), to the left side in 16 cases (34%) and was midline in 20 cases (42.6%). In 37 dogs (78.7%) the lesion extent was restricted to \leq one vertebral body length, while in 10 dogs (21.3%) the lesion extent was between one and two vertebral bodies in length.

The cutaneous trunci reflex remained intact in 8 cases and cut-off was present in 39 cases (83%). In 34 cases the cut-off was bilateral and in five cases the cut off was unilateral. In all the cases with a unilateral cutaneous trunci reflex cut-off, the lesion was ipsilateral to the side of the cutaneous trunci reflex cut-off. The level of the cutaneous trunci reflex cut-off ranged from zero to four vertebrae caudal to the maximal lesion level, with 61.5% (24 dogs) having the cut off two or three vertebrae caudal to the lesion, and from zero to five vertebrae caudal to the cranial extent of the lesion (Figure 6). There was no significant difference in the level of cutaneous trunci reflex cut-off relative to the spinal cord lesion when comparing maximal lesion level, cranial extent of lesion, aetiology, duration of the clinical signs, lesion length and lesion lateralisation. However, there was a trend for a more caudal cutaneous trunci reflex cut-off relative to the level of the cranial extent of the spinal cord lesion (but not maximal spinal cord lesion) in dogs with paraplegia (more severe injuries) than dogs with paraparesis (less severe injuries). The respective means were 3.1 vertebrae and 2.5 vertebrae caudal to the level of the cranial extent of the spinal cord lesion. This was not the case with maximal lesion extent though.

5.2.3 *The cutaneous trunci reflex as a grading tool*

The presence or absence of a cutaneous trunci reflex cut-off correlated significantly with the clinical severity grading, with its presence being associated with a more severe clinical grade when assessed over the entire population ($P<0.0001$) (Figure 7). Loss of the cutaneous trunci reflex occurred at a severity grade lower than that associated with loss of ambulation. All dogs with a 14-point severity grade of <7 (most severe) had a cutaneous trunci reflex cut-off. All dogs with a 14-point severity grade of >10 (least severe) did not have a cut-off. Assessment in dogs with an ambulatory paresis (grade II on the grade 0 to V grading scale) revealed that the presence of a cutaneous trunci reflex cut-off was significantly associated with a more severe 14-point severity grade ($P=0.0344$) and allowed segregation of this population into less and more severely affected groups (Figure 7).

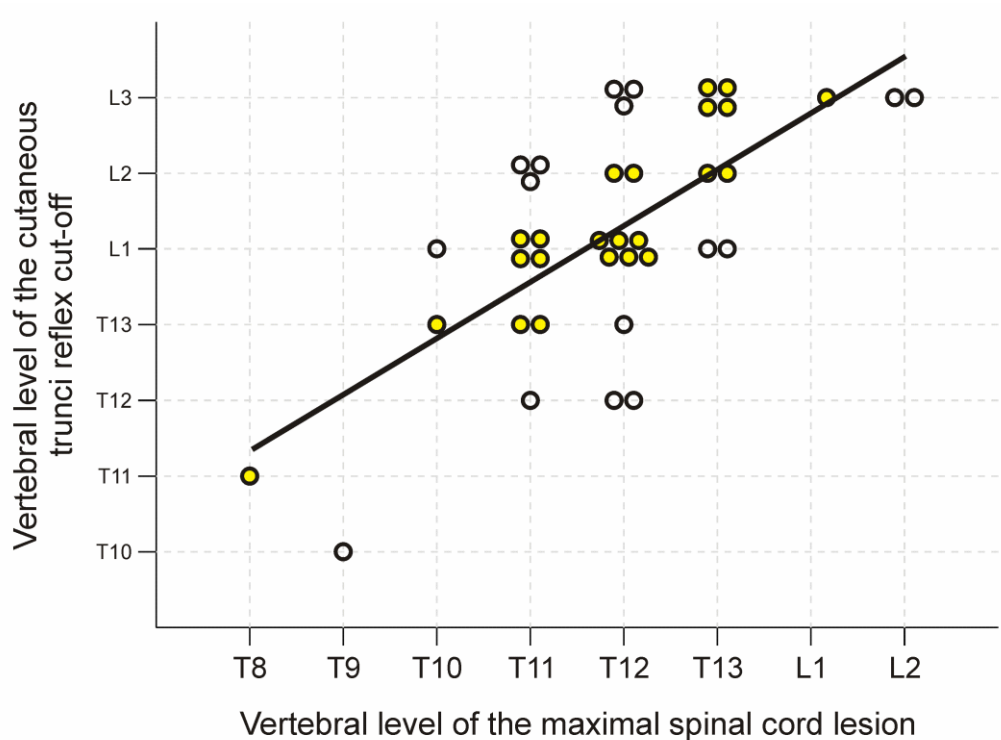


Figure 6 Vertebral level of the cutaneous trunci reflex cut-off in relation to the vertebral level of the maximal spinal cord lesion in 39 dogs with thoracolumbar spinal cord lesions. The presence of a cutaneous trunci reflex cut-off indicates spinal cord lesion 0 to 4 vertebrae cranial to the level of the cut-off, with 62% of these lesions being 2-3 vertebrae cranial to the cut-off (yellow circles).

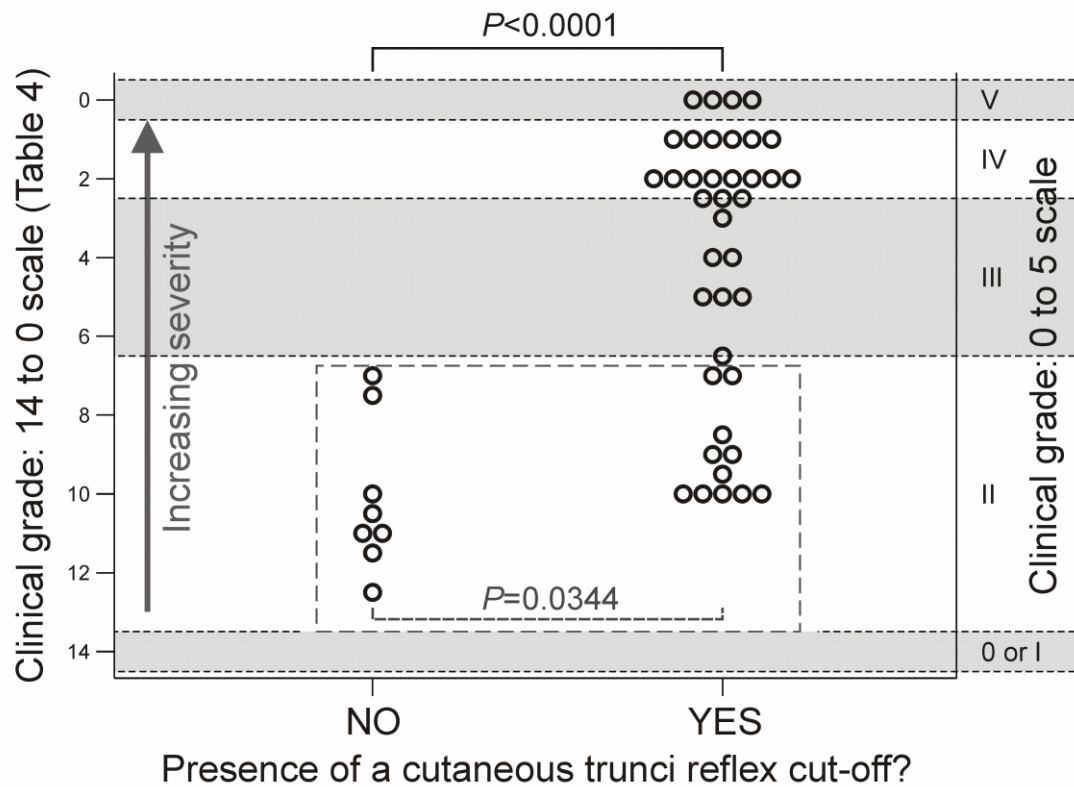


Figure 7 Presence of a cutaneous trunci reflex cut-off in relation to the clinical grade in 47 dogs with thoracolumbar spinal cord lesions. The presence of a cutaneous trunci reflex cut-off is significantly correlated with a more severe clinical grade ($P < 0.0001$ in the whole population and $P = 0.0344$ in dogs with grade II ambulatory paraparesis on the 0 to 5 grading scale, allowing segregation of this population into more and less severely affected groups)

5.3 Discussion

The findings of this part of the study indicate that the presence of a cutaneous trunci reflex cut-off is useful in localising the maximal level of spinal cord lesion within the T3 to L3 spinal cord segments to an accuracy of up to four vertebrae. This part of the study also indicates that the cutaneous trunci reflex cut-off is useful for rapidly segregating dogs with an ambulatory paresis into less and more severely affected populations on the basis of clinical severity, without the requirement for video gait analysis. The accuracy of the cutaneous trunci reflex cut-off to localise thoracolumbar spinal cord injuries in dogs relies on the distribution of dermatomes relative to their individual spinal cord segments within the vertebral column (Bailey et al., 1984) and corresponds with descriptions of the anatomical pathway of this reflex (Platt and Olby, 2004; Dewey, 2008; de Lahunta and Glass, 2009). In 61.5% of the cases in this study where a cutaneous trunci reflex cut-off was identified, the maximal spinal cord lesion was between 2 or 3 vertebrae cranial to the level of the cutaneous trunci reflex cut-off.

The level of the cut-off tended to be further caudal to the cranial extent of the lesion in dogs with more severe spinal cord lesions, although this difference was not apparent for the maximal lesion level. The most likely explanation is that the severity of a spinal cord injury is not uniform over its entire extent and is likely to be more severe at the maximal lesion level. Dogs with more severe spinal cord lesions also tended to have more extensive lesions. The cranial extent of the spinal cord changes identified on diagnostic imaging may not be severe enough to interrupt the cutaneous trunci reflex, resulting in a more caudal cutaneous trunci reflex cut-off correlating with the level of the maximal spinal cord lesion.

There are numerous advantages associated with improved clinical localisation, not least that it allows planning and assessment of diagnostic imaging with considerably more confidence. However, the variability in the localisation of lesions to between 0 to 4 vertebrae cranial to the level of the cutaneous trunci reflex cut-off shows that the assessment of the cutaneous trunci reflex in clinical settings is not as accurate as described in an anatomical study of

dermatomes. There are a variety of possible explanations. Variation in individual dermatomes may be apparent between different animals (Bailey et al., 1984) or the cranial extent of the lesion as identified by diagnostic imaging may not correlate with the true cranial extent of the functional injury. In addition the potential for operator error cannot be fully excluded when manually counting the dorsal spinous processes, particularly in overweight animals in which bony landmarks are harder to identify.

Unilateral cutaneous trunci reflex cut-off may occur with lateralised thoracolumbar spinal cord lesions (Blight et al., 1990; Borgens et al., 1990). The pathway from the cutaneous nerves to the contralateral motor pathway is thought to cross segmentally at the level of input into the spinal cord, since the contralateral response is spared caudal to the lesion (Blight et al., 1990; Borgens et al., 1990; de Lahunta and Glass, 2009). Five dogs were identified with unilateral cutaneous trunci reflex cut-off and all of these dogs demonstrated marked asymmetrical clinical signs. In all of these dogs the diagnosis was consistent with non-degenerative traumatic disc extrusion or ischaemic myelopathy and the lesion was ipsilateral to the side of the cutaneous trunci reflex cut-off.

This part of the study found a significant positive correlation between more severe clinical grades and loss of the cutaneous trunci reflex. All non-ambulatory patients had a cutaneous trunci reflex cut-off, suggesting that the cutaneous trunci reflex is lost at a less severe clinical grade than that associated with a loss of ambulation. The clinical presentation of ambulatory paresis is a common one, but the current clinical grade 0 to V grading scale does not allow further classification of the clinical severity in these cases. The 0 to 14 grading scale is very useful for subdividing this group further, but this technique is not amenable for use within the consulting room setting, requiring retrospective video gait analysis. The presence or absence of a cutaneous trunci reflex cut-off was particularly interesting when examined within the group of dogs with ambulatory paresis and allowed segregation of these dogs into less and more severely affected populations. This could therefore be used as a rapid grading tool to subdivide ambulatory patients.

The literature reports absence of the cutaneous trunci reflex in some normal dogs and this could represent a limitation for using it clinically (de Lahunta and Glass, 2009). However, studies in normal dogs concluded that the cutaneous trunci reflex can be reliably demonstrated in the vast majority (94-97%) of normal dogs up to the vertebral level L6 (Fox, 1963; Muguet-Chanoit et al., 2011). The cutaneous trunci reflex was present in all dogs in our study, either cranial to the level of the cut-off or cranial to L6 in cases with no cut-off. A previous study (Olby et al., 2004) reported that the cutaneous trunci reflex was intact in the majority of dogs with injuries at the level of, or caudal to, L1 vertebrae, as a result of the caudal extension of the first lumbar dermatome (Bailey et al., 1984). The use of the cutaneous trunci reflex as a grading tool is therefore potentially of less value in dogs with spinal cord lesions caudal to the first lumbar vertebra. However, in practice this does not appear to represent a major limitation as most lesions occurred secondary to degenerative intervertebral disc disease (Olby et al., 2001) and the majority of these occur cranial to L1 vertebra (Brisson, 2010). In the cases included in this part of the study only five cases had lesions at the level of L1 or L2 and in three of these cases a cutaneous trunci cut-off was present.

The cutaneous trunci reflex is a useful clinical tool for localising thoracolumbar spinal cord lesions, thereby allowing more accurate planning and interpretation of diagnostic techniques. The cutaneous trunci reflex could also represent a grading tool in dogs with thoracolumbar spinal cord disease presenting as ambulatory paresis.

CHAPTER VI

6 DISCUSSION

Spinal cord diseases involving the thoracolumbar segments (T3-L3) are relatively common in dogs, representing 19.6% of the neurological cases in a referral hospital (Fluehmann et al., 2006). Many studies have been published regarding the value of different variables in predicting the outcome in dogs following thoracolumbar spinal cord disease. The presence of deep pain is the most important of these variables, particularly to identify severe spinal cord injury. However, many other variables have also been shown to be useful to inform the grade and speed of recovery, in severe and less severe spinal cord injury. Being able to predict the outcome is of critical importance for the clinician and the owner in order to make the most appropriate clinical decisions.

The studies presented in this thesis analyse the influence of the variables of diagnostic imaging technique of choice, age and body weight on the outcome in a large population of dogs with thoracolumbar spinal cord disease. MRI has only become routinely available for the investigation of spinal disease in canine patients over the past 10 to 15 years but has become progressively more widely available, thereby influencing the way in which these cases are now managed. The results of the present study indicate that MRI has largely replaced radiography, myelography and CT-myelography for the investigation of spinal cord lesions in dogs in the referral institution in which the work was performed. However, it also demonstrated that the choice of diagnostic imaging modality did not significantly affect either the neurological grade at discharge or speed of recovery. This is in agreement with other studies that have demonstrated no influence on outcome between myelography and CT in dogs with intervertebral disc disease (Olby et al., 2004) and between myelography and MRI for the investigation of thoracolumbar spinal cord disorders (Parry et al., 2010).

In this study, the influence of the age and body weight at presentation on the outcome of dogs with thoracolumbar spinal cord disease was analysed in two different ways. First these two variables were considered as continuous variables, and then the outcomes were compared in the two extreme groups of age and weight. No influence of the age at presentation was evident on the neurological grade at discharge or speed of recovery, which is in accordance to the majority of the previous veterinary studies (Dhupa et al., 1999a; Davis and Brown, 2002; Olby et al., 2004; Penning et al., 2006; Kathmann et al., 2006; Bull

et al. 2008) and the recent human studies (Furlan et al., 2010). The same was found for body weight, with no influence of body weight at presentation on the speed or grade of recovery (Dhupa et al., 1999a; Macias et al., 2002; Olby et al. 2004; Kathmann et al., 2006; Ruddle et al., 2006).

The current study also compared the frequency and distribution of common thoracolumbar spinal cord diseases as intervertebral disc disease, ischaemic myelopathy and trauma in dogs of different ages and weights. When evaluating the different age and weight groups, Hansen type-I intervertebral disc disease was the most common diagnosis in all groups, making it the most common spinal cord disease affecting the thoracolumbar region as previously reported (Dhupa et al., 1999a; Davis and Brown, 2002; Olby et al., 2004; Brisson, 2010). Suspected ischaemic myelopathy was more frequent in the young and the large breeds groups, as these diseases tend to affect younger dogs of large breeds (Cauzinille and Kornegay, 1996; Gandini et al., 2003; de Risio et al., 2008; Brisson, 2010). Vertebral fractures and luxations were as frequent in the large and small breeds groups, but were more common in the young group.

One of the main limitations of the retrospective part of the study was that the severity grade was scored using a scale from 0 to V (Sharp and Wheeler, 2005) (Table 1). The main disadvantage of this grading scale is that it does not allow discrimination between patients with an ambulatory paresis, classified as grade II, despite these patients representing a broad spectrum of clinical severity. A more detailed 14-point grading scale was developed by Olby et al. (2001) which allows subdivision of dogs with ambulatory paresis (classified as grade II in the 0 to V grading scale) into 7 subcategories. However this is less suited to rapid clinical assessment within the consulting room and relies on video gait analysis (Table 4).

The findings of the current study indicated that the presence of a cutaneous trunci reflex cut-off is useful in localising the maximal level of the spinal cord lesion within the T3 to L3 spinal cord segments, to an accuracy of up to four vertebrae. The study furthermore indicates a significant positive correlation between a more severe clinical grade and loss of the cutaneous trunci reflex. All non-ambulatory patients and some of the ambulatory ones had a cutaneous

trunci reflex cut-off, suggesting that the cutaneous trunci reflex is lost at a less severe clinical grade than that associated with a loss of ambulation. The presence or absence of a cutaneous trunci reflex cut-off was particularly useful within the group of dogs with ambulatory paresis (grade II in the 0 to V grading scale), where it allowed segregation of these dogs into less and more severely affected populations, and could therefore be used as a rapid grading tool to subdivide ambulatory patients.

In summary, the retrospective part of this study (Chapters III and IV) found that MRI has largely replaced myelography as the technique of choice for the evaluation of canine patients. Despite the perceived increased patient safety and relatively non-invasive nature of MRI, as compared to myelography and CT-myelography, this study did not demonstrate a difference in outcome between MRI and myelography when measured as grade or speed of recovery. However, my study design did not allow us to determine if the use of myelography in a small minority of cases may have resulted in catastrophic adverse effects. Neither the age nor the body weight at presentation appears to have a significant effect on the neurological grade at discharge or speed of recovery in dogs with thoracolumbar spinal cord disease, during the hospitalisation period. However, what would be interesting to perform next would be further studies evaluating the effect of these variables on the long-term outcome once the animal has been discharged back into the owner's care. The prospective part of this study (Chapter V) demonstrated that the cutaneous trunci reflex is a useful clinical tool for localising thoracolumbar spinal cord lesions, allowing accurate planning and interpretation of diagnostic techniques. The cutaneous trunci reflex could also represent a grading tool in dogs with thoracolumbar spinal cord disease presenting with ambulatory paresis, with the associated advantages of establishing a more accurate clinical severity grade.

LIST OF REFERENCES

Abramson, C.J., Garosi, L. Platt, S.R., Dennis, R., Mcconnell, J.F., 2005. Magnetic resonance imaging appearance of suspected ischemic myelopathy in dogs. *Veterinary Radiology & Ultrasound* 46, 225-229.

Ackerman, S.J., Steinberg, E.P., Bryan, R.N., Bendebba, M., Long, D.M., 1997. Trends in Diagnostic Imaging for Low Back Pain: Has MR Imaging Been a Substitute or Add-on? *Radiology* 203,533-538.

Adams, W.M. and Stowater, J.L., 1981. Complications of metrizamide myelography in the dog: summary of 107 clinical case histories. *Veterinary Radiology* 22, 27-34.

Allan, G.S. and Wood, A.K.W., 1988. Iohexol myelography in the dog. *Veterinary Radiology* 29, 78-82.

Anderson, S.M., Lippincott, C.L., Gill, P.J., 1991. Hemilaminectomy in dogs without deep pain perception. *California Veterinary*, 45, 24-28.

Bagley, R.S., 2005. Clinical features of important and common diseases involving the spinal cord of dogs and cats. In: *Fundamentals of Veterinary Clinical Neurology* 1st ed., Wiley-Blackwell, 151-176.

Bagley, R.S., 2010. Spinal neoplasms in small animals. *The Veterinary Clinics of North America. Small Animal Practice*, 40, 915-927.

Bailey C.S., Kitchell R.L., Haghighi S.S., Johnson R.D., 1984. Cutaneous innervation of the thorax and abdomen of the dog. *American Journal of Veterinary Research*, 45, 1689-1698.

- Besalti, O., Peckcan, Z., Sirin, Y.S., Ebras, G., 2006. Magnetic resonance imaging findings in dogs with thoracolumbar intervertebral disk disease: 69 cases (1997- 2005). *Journal of the American Veterinary Association* 228, 902-908.
- Bjorling, D.E., Beckman, M., Clayton, M.K., Wang, Z.Y., 2002. Modulation of nerve growth factor in peripheral organs by estrogen and progesterone. *Neuroscience*, 110, 155-167.
- Blight A.R., McGinnis M.E., Borgens R.B., 1990. Cutaneous trunci muscle reflex of the guinea pig. *The Journal of Comparative Neurology*, 296, 614-633.
- Borgens R.B., Blight A.R., McGinnis M.E., 1990. Functional recovery after spinal cord hemisection in guinea pigs: The effects of applied electric fields. *The Journal of Comparative Neurology*, 296, 634-653.
- Brewer, D.M., Cerda-Gonzalez, S., Dewey, C.W., Diep, A.N., Van Horne, K., McDonough, S.P., 2011. Spinal cord neuroblastoma in dogs: 11 cases (1985-2007). *Journal of the American Veterinary Medical Association*, 238, 618-624.
- Bright, R.M., Breazile, J.E. and Bojrab, M.J., 1977. Prognostic application of cortical evoked responses in dogs with spinal cord injury. *Veterinary Surgery*, 6, 55-59.
- Brisson, B.A., Moffatt, S.L., Swayne, S.L., Parent, J.M., 2004. Recurrence of thoracolumbar intervertebral disk extrusion in chondrodystrophic dogs after surgical decompression with or without prophylactic fenestration: 265 cases (1995-1999). *Journal of the American Veterinary Medical Association*, 224, 808-1814.
- Brisson, B.A., 2010. Intervertebral disc disease in dogs. *The Veterinary Clinics of North America. Small Animal Practice*, 40, 829-858.

Brisson, B.A., Holmberg, D.L., Parent, J., Sears, W.C., Wick, S.E., 2011. Comparison of the effect of single-site and multiple-site disc fenestration on the rate of recurrence of thoracolumbar intervertebral disc herniation in dogs. *Journal of the American Veterinary Medical Association*, 12, 1593-1600.

Bruce, C.W., Brisson, B. A., Gyselinck, K., 2008. Spinal fracture and luxation in dogs and cats; A retrospective evaluation of 95 cases. *Veterinary Comparative Oorthopaedics and Traumatology*, 21, 280-284.

Bull, C., Fehr, M., Tipold, A., 2008. Canine intervertebral disk disease: a retrospective study of clinical outcome in 238 dogs (2003-2004). *Berliner und Münchener tierärztliche Wochenschrift*, 121, 159-170.

Burkert, B.A., Kerwin, S.C., Hosgood, G.L., Pechman, R.D., Fontenelle. J.P., 2005. Signalment and clinical features of diskospondylitis in dogs: 513 cases (1980-2001). *Journal of the American Veterinary Medical Association*, 227, 268-275.

Butterwoth, S.J. and Gibbs, C., 1992. A review of the usefulness of myelography in 50 dogs. *Veterinary Record* 130, 461-465.

Carroll, G.L., Keene, B.W., Forrest, L.J., 1997. Asystole associated with iohexol myelography in a dog. *Veterinary Radiology & Ultrasound* 38, 284-287.

Cauzinille, L. and Kornegay, J.N., 1996. Fibrocartilaginous embolism of the spinal cord in dogs: review of 36 histologically confirmed cases and retrospective study of 26 suspected cases. *Journal of Veterinary Internal Medicine*, 10, 241-245.

Chang, Y., Dennis, R., Platt, S.R., Penderis J., 2007. Magnetic resonance imaging of traumatic intervertebral disc extrusion in dogs. *Veterinary Record* 160, 795-799.

Coates, J.R. and Wininger, F.A., 2010. Canine degenerative myelopathy. *The Veterinary Clinics of North America. Small Animal Practice*, 40, 929-950.

da Costa R., Parent J., Dabson H., Holwberg D., Partlow G., 2006. Comparison of magnetic resonance imaging and myelography in 18 doberman pinscher dogs with cervical spondylomyelopathy. *Veterinary Radiology & Ultrasound* 47, 523-531.

Cudia, S.P. and Duval, J.M., 1997. Thoracolumbar intervertebral disk disease in large, nonchondrodystrophic dogs: a retrospective study. *Journal of the American Animal Hospital Association*, 33, 456-460.

Davies, J.V. and Sharp, N.J.H., 1983. A comparison of conservative treatment and fenestration for thoracolumbar intervertebral disc disease in the dog. *Journal of Small Animal Practice*, 24, 721-729.

Davis, G.J. and Brown, D.C., 2002. Prognostic indicators for time to ambulation after surgical decompression in nonambulatory dogs with acute thoracolumbar disk extrusions: 112 cases. *Veterinary Surgery*, 31, 513-518.

DeVivo, M.J., Karus, P.L., Rutt, R.D., Stover, S.L., Fine P.R., 1990. The influence of age at time of spinal cord injury on rehabilitation outcome. *Archives of Neurology*, 47, 687-691.

Dernell, W.S., Vechten, B.J., Straw, R.C., Larue, S.M., Powers, B.E., Withrow. S.J., 2000. Outcome following treatment of vertebral tumors in 20 dogs (1986-1995). *Journal of the American Animal Hospital Association*, 36, 245-251.

Dewey, C.W., 2008. Myelopathies: Disorders of the spinal cord. In: *A Practical Guide to Canine and Feline Neurology* 2nd ed., Wiley-Blackwell, 323-388.

Dhupa, S., Glickman, N.W., Waters, D.J., 1999a. Functional outcome in dogs after surgical treatment of caudal lumbar intervertebral disk herniation. *Journal of the American Animal Hospital Association*, 35, 323.

Dhupa, S., Glickman, N., Waters, D.J., 1999b. Reoperative neurosurgery in dogs with thoracolumbar disc disease. *Veterinary Surgery*, 28, 421-428.

Dimar, J.R., Glassman, S., Raque, G., Zhang, Y., Shields C., 1999. The influence of spinal canal narrowing and timing of decompression on neurologic recovery after spinal cord contusion in a rat model. *Spine*, 24, 1623.

Dunié-Mérigot, A., Huneault, L., Parent, J., 2007. Fibrocartilaginous embolic myelopathy in dogs: a retrospective study. *The Canadian Veterinary Journal*, 48, 63-68.

Duval, J., Dewey, C., Roberts, R., Aron, D., 1996. Spinal cord swelling as a myelographic indicator of prognosis: a retrospective study in dogs with intervertebral disc disease and loss of deep pain perception. *Veterinary Surgery*, 25, 6-12.

Fanuele, J.C., Abdu, W.A., Hanscom, B., Weinstein, J.N., 2002. Association between obesity and functional status in patients with spine disease. *Spine*, 27, 306-312.

Fawcett, J.W., 2006. Overcoming inhibition in the damaged spinal cord. *Journal of Neurotrauma*, 23, 371-383.

Ferreira, A.J.A., Correia, J.H.D., Jaggy, A., 2002. Thoracolumbar disc disease in 71 paraplegic dogs: influence of rate of onset and duration of clinical signs on treatment results. *Journal of Small Animal Practice*, 43, 158-163.

Fluehmann, G., Doherr, M.G., Jaggy, A., 2006. Canine neurological diseases in a referral hospital population between 1989 and 2000 in Switzerland. *Journal of Small Animal Practice*, 47, 582-587.

Fox M.W., 1963. Clinical observations on the panniculus reflex in the dog. *Journal of the American Veterinary Medical Association*, 142, 1296-1299.

Funkquist, B., 1962. Thoracolumbar myelography with water-soluble contrast medium in dogs. I. Technique of myelography; side effects and complications. *Journal of Small Animal Practice* 3, 53-66.

Funkquist, B., 1962. Thoracolumbar myelography with water-soluble contrast medium in dogs. II. Appearance of myelogram in disk protrusion and its relation to functional disturbances and patho-anatomic changes in the epidural space. *Journal of Small Animal Practice* 3, 67-73.

Furlan, J.C., Fehlings, M., Massicotte, E., Aarabi, B., Vaccaro, A.R., Bono, C.M., Madrazo, I., Villanueva, C., Grauer, J.N., Mikulis, D., 2007. A quantitative and reproducible method to assess cord compression and canal stenosis after cervical spine trauma: a study of interrater and intrarater reliability. *Spine*, 32, 2083-2091.

Furlan, J.C., Bracken, M.B., Fehlings, M.G., 2010. Is age a key determinant of mortality and neurological outcome after acute traumatic spinal cord injury? *Neurobiology of Aging*, 31, 434-446.

Gandini, G., Cizinauskas, S., Lang, J., Fatzer, R., Jaggy A., 2003. Fibrocartilaginous embolism in 75 dogs: clinical findings and factors influencing the recovery rate. *Journal of Small Animal Practice*, 44, 76-80.

Gavin, P.R., 2011. Growth of clinical veterinary magnetic resonance imaging. *Veterinary Radiology & Ultrasound*, 52, S2-S4.

Griffiths, I., 1982. Spinal disease in the dog. *In Practice*, 4, 44.

Gopal, M.S. and Jeffery, N.D., 2001. Magnetic resonance imaging in the diagnosis and treatment of a canine spinal cord injury. *Journal of Small Animal Practice* 42, 29-31.

Hawthorne, J.C., Wallace L.J., Fenner, W.R., Waters D.J., 2001. Fibrocartilaginous embolic myelopathy in miniature schnauzers. *Journal of the American Animal Hospital Association*, 37, 374-84.

Holstege G. and Blok B.F., 1989. Descending pathways to the cutaneous trunci muscle motoneuronal cell group in the cat. *Journal of Neurophysiology*, 62, 1260-1269.

Hurlbert, R.J., 2001. The role of steroids in acute spinal cord injury: an evidence-based analysis. *Spine*, 26, S39.

Israel, S.K., Levine, J.M., Kerwin, S.C., Levine, G.J., Fosgate, G.T., 2009. The relative sensitivity of computed tomography and myelography for identification of thoracolumbar intervertebral disk herniations in dogs. *Veterinary Radiology & Ultrasound* 50, 247-252.

Ito, D., Matsunaga, S., Jeffery, N.D., Sasaki, N., Nishimura, R., Mochizuki, M., Kasahara, M., Fujiwara, R., Ogawa, H., 2005. Prognostic value of magnetic resonance imaging in dogs with paraplegia caused by thoracolumbar intervertebral disk extrusion: 77 cases (2000-2003). *Journal of the American Veterinary Medical Association*, 227, 1454-1460.

Jeffery, N.D., 2010. Vertebral fracture and luxation in small animals. *The Veterinary Clinics of North America. Small Animal Practice*, 40, 809-828.

Jia L.S. and Shi Z.R., 1991. MRI and myelography in the diagnosis of lumbar canal stenosis and disc herniation. A comparative study. *Chinese Medical Journal* 104, 303- 306.

Kathmann, I., Cizinauskas, S., Doherr, M.G., Steffen, F., Jaggy A., 2006. Daily controlled physiotherapy increases survival time in dogs with suspected degenerative myelopathy. *Journal of Veterinary Internal Medicine*, 20, 927-932.

Kazakos, G., Polizopoulou, Z.S., Patsikas, M.N., Bimopoulos, G., Roubies, N., Dessirir, A., 2005. Duration and severity of clinical signs as prognostic indicators in 30 dogs with thoracolumbar disk disease after surgical decompression. *Journal of Veterinary Medicine Series A*, 52, 147-152.

Kennedy, P., Evans, M.J., Berry, C., Mullin, J., 2003. Comparative analysis of goal achievement during rehabilitation for older and younger adults with spinal cord injury. *Spinal Cord*, 41, 44-52.

Kido D.K., Wippold F.J., Wood R.C., 1993. The role of nonionic myelography in the diagnosis of lumbar disc herniation. *Investigative Radiology* 28, s62-s66.

Kirberger, R. M, Roos, C.J., Lubbe, A.M., 1992. The radiological diagnosis of thoracolumbar disk disease in the dachshund. *Veterinary Radiology & Ultrasound* 33, 255-261.

Kirberger, R.M. and Wrigley, R.H., 1993. Myelography in the dog: review of patients with contrast medium in the central canal. *Veterinary Radiology & Ultrasound* 34, 253- 258.

Krogh J.E. and Towns L.C., 1984. Location of the cutaneous trunci motor nucleus in the dog. *Brain Research*, 295, 217-225.

de Lahunta A. and Glass E., 2009. Lower motor neuron: Spinal nerve, general somatic efferent system. In: *Veterinary neuroanatomy and clinical neurology* 3rd ed., Saunders Elseiver, St Louis Missouri, USA: 77-133.

Laitinen, O.M. and Puerto, D.A., 2005. Surgical decompression in dogs with thoracolumbar intervertebral disc disease and loss of deep pain perception: a retrospective study of 46 cases. *Acta Veterinaria Scandinavica*, 46, 79-86.

Lamb, C.R., 1994. Common difficulties with myelographic diagnosis af acute intervertebra disc prolapse in dogs. *Journal of Small Animal Practice* 35, 549-558.

Lamb, C.R., 2002. Accuracy of survey radiographic diagnosis of intervertebral disc protrusion in dogs. *Veterinary Radiology & Ultrasound* 43, 222- 228.

Levine, G.J., Levine, J.M., Budke, C.M., Kerwin, S.C., Au, J., Vinayak, A., Hettlich, B.F., Slater, M.R., 2009. Description and repeatability of a newly developed spinal cord injury scale for dogs. *Preventive Veterinary Medicine*, 89, 121-127.

Levine, G.J., Levine, J.M., Witsberger, T.H., Kerwin, S.C., Russell, K.E., Suchodolski, J., Steiner, J., Fosgate, G.T., 2010. Cerebrospinal fluid myelin basic protein as a prognostic biomarker in dogs with thoracolumbar intervertebral disk herniation. *Journal of Veterinary Internal Medicine*, 24, 890-896.

Levine, J.M., Ruaux, C.G., Bregman, R.L., Coates, J.R., Steiner, J.M., Williams, D.A., 2006. Matrix metalloproteinase-9 activity in the cerebrospinal fluid and serum of dogs with acute spinal cord trauma from intervertebral disk disease. *American journal of veterinary research*, 67, 283-287.

Levine, J.M., Levine, G.J., Johnson, S.I., Kerwin, S.C., Heltlich, B.F., Fosgate G.T., 2007. Evaluation of the success of medical management for presumptive thoracolumbar intervertebral disk herniation in dogs. *Veterinary Surgery*, 36, 482-491.

Levine, J.M., Levine, G.J., Boozer, L., Schatzberg, S.J., Platt, S.R., Kent, M., Fosgate, G.T., 2008. Adverse effects and outcome associated with dexamethasone administration in dogs with acute thoracolumbar intervertebral disk herniation: 161 cases (2000-2006). *Journal of the American Veterinary Medical Association*, 232, 411-417.

Levine, J.M., Fosgate, G.T., Chen, A.V., Rushing, R., Nghiem, P.P., Platt, S.R., Bagley, R.S., Kent, M., Hicks, D.G., Young, B.D., Schatzberg, S.J., 2009. Magnetic resonance imaging in dogs with neurologic impairment due to acute thoracic and lumbar intervertebral disk herniation. *Journal of Veterinary Internal Medicine*, 23, 1220-1226.

Levy, M.S., Kapatkin, A.S., Patnaik, A.K., Mauldin, G.N., Mauldin G.E., 1997. Spinal tumors in 37 dogs: clinical outcome and long-term survival (1987-1994). *Journal of the American Animal Hospital Association*, 33, 307-312.

Lewis, D.D. and Hosgood, G., 1992. Complications associated with the use of iohexol for myelography of the cervical vertebral column in dogs: 66 cases (1988-1990). *Journal of the American Veterinary Association* 200, 1381-1384.

Loughin, C.A., Dewey, C.W., Ringwood, P.B., Pettigrew, R.W., Kent, M., Budsberg S.C., 2005. Effect of durotomy on functional outcome of dogs with type I thoracolumbar disc extrusion and absent deep pain perception. *Veterinary and Comparative Orthopaedics and Traumatology*, 18, 141-146.

Macias, C., Mckeew, M., May, C., Innes, J.F., 2002. Thoracolumbar disc disease in large dogs: a study of 99 cases. *Journal of Small Animal Practice*, 43, 439-446.

Maitino, A.J., Levin, D.C., Parker, L., Rao, V.M., Sunshine, J.H. 2003. Nationwide trends in rates of utilization of noninvasive diagnostic imaging among the medicare population between 1993 and 1999. *Radiology* 227,113-117.

Marchetti, B., Gallo, F., Farinella, Z., Tirolo, C., Testa, N., Caniglia, S., Morale, M.C., 2000. Gender, Neuroendocrine-Immune Interactions and Neuron-Glial Plasticity: Role of Luteinizing Hormone-Releasing Hormone (LHRH). *Annals of the New York Academy of Sciences*, 917, 678-709.

Mayhew, P.D., Mclear, R.C., Ziemer L.S., Culp, W.T., Russell, K.N., Shofer, F.S., Kapatkin, A.S., Smith, G.K., 2004. Risk factors for recurrence of clinical signs associated with thoracolumbar intervertebral disk herniation in dogs: 229 cases (1994-2000). *Journal of the American Veterinary Medical Association*, 225, 1231-1236.

Mccartney, W.T., 1997. Lumbar myelography in 79 dogs, using different puncture sites. *Veterinary Record* 141, 417-419.

McKee, W.M., 1990. Spinal trauma in dogs and cats: a review of 51 cases. *Veterinary Record*, 126, 285-289.

McKee, W.M., 1992. A comparison of hemilaminectomy (with concomitant disc fenestration) and dorsal laminectomy for the treatment of thoracolumbar disc protrusion in dogs. *Veterinary Record*, 130, 296-300.

Moissonier P., Crigel M.H. and Timmerman P., 2002. Spinal tumours in dogs: retrospective study of 18 cases. *Veterinary Surgery*, 31, 301.

Muir, P., Johnson, K.A., Manley, P.A., Dueland, R.T., 1995. Comparison of hemilaminectomy and dorsal laminectomy for thoracolumbar intervertebral disc extrusion in dachshunds. *The Journal of Small Animal Practice*, 36, 360-367.

Muguet-Chanoit, A.C., Olby, N.J., Babb, K.M., Lim, J.H., Gallagher, R., Niman, Z., Dillard, S., Campbell, J, 2011. The xensory field and repeatability of the cutaneous trunci muscle reflex of the dog. *Veterinary Surgery*, 40, 781-785.

New, P.W. and Epi, M.C., 2007. Influence of age and gender on rehabilitation outcomes in nontraumatic spinal cord injury. *The Journal of Spinal Cord Medicine*, 30, 225-237.

Okada, M., Kitagawa, M., Ito, D., Itou T., Kanayama, K., Sakai, T., 2010. Magnetic resonance imaging features and clinical signs associated with presumptive and confirmed progressive myelomalacia in dogs: 12 cases (1997-2008). *Journal of the American Veterinary Medical Association*, 237, 1160-1165.

Olby, N.J., Dyce, J., Houlton, J.E.F., 1994. Correlation of plain radiographic and lumbar myelographic findings with surgical findings in thoracolumbar disc disease. *Journal of Small Animal Practice* 35, 345-350.

Olby, N.J., Muñana, K.R., Sharp, N.J.H., Flegel, T., Van Camp, S., Berry, C.R., Thrall ,D.E., 1999. A comparison of computed tomography and myelography in the diagnosis of acute intervertebral disc disease in dogs. Proceedings of the American College of Veterinary Internal Medicine Forum. June 10 to 13, Chicago :705.

Olby, N.J., Muñana, K.R., Sharp, N.J.H., Thrall, D.E., 2000. The computed tomographic appearance of acute thoracolumbar intervertebral disc herniations in dogs. *Veterinary Radiology & Ultrasound* 41, 396-402.

Olby, N.J., de Risio, L., Munana K.R., Wosar, M.A., Skeen, T.M., Sharp, N.J., Keene, B.W., 2001. Development of a functional scoring system in dogs with acute spinal cord injuries. *American Journal of Veterinary Research*, 62, 1624-1628.

Olby, N.J., Levine, J., Harris T., Munana, K., Skeen, T., Sharp, N., 2003. Long-term functional outcome of dogs with severe injuries of the thoracolumbar spinal cord: 87 cases (1996-2001). *Journal of the American Veterinary Medical Association*, 222, 762-769.

Olby, N.J., Harris, T., Burr, J., Munana, K., Sharp, N., Keene, B., 2004. Recovery of pelvic limb function in dogs following acute intervertebral disc herniations. *Journal of Neurotrauma*, 21, 49-59.

Olby N., 2010. The pathogenesis and treatment of acute spinal cord injuries in dogs. *The Veterinary Clinics of North America. Small Animal Practice*, 40, 791-807.

Packer, R.A., Bergman, R.L., Coates, J.R., Essman, S.C., Weis, K., O'brien, D.P., Johnson G.C., 2007. Intracranial subarachnoid hemorrhage following lumbar myelography in two dogs. *Veterinary Radiology & Ultrasound* 48,323-327.

Parry, A.T., Harris A., Upjohn, M.M., Chandler, K., Lamb, C.R., 2010. Does choice of imaging modality affect outcome in dogs with thoracolumbar spinal conditions? *The Journal of Small Animal Practice*, 51, 312-317.

Penderis, J., Sullivan, M., Schwartz, T., Griffiths, I.R., 1999. Subdural injection of contrast medium as a complication of myelography. *Journal of Small Animal Practice* 40, 173-176.

Penning, V., Platt, S.R., Dennis, R., Cappello, R., Adams V., 2006. Association of spinal cord compression seen on magnetic resonance imaging with clinical outcome in 67 dogs with thoracolumbar intervertebral disc extrusion. *Journal of Small Animal Practice*, 47, 644-650.

Petersen, S.A., Sturges, B.K., Dickinson P.J., Pollard, R.E., Kass, P.H., Kent, M., Vernau, K.M., Lecouteur, R.A., Higgins, R.J., 2008. Canine intraspinal meningiomas: imaging features, histopathologic classification, and long-term outcome in 34 dogs. *Journal of Veterinary Internal Medicine*, 22, 946-953.

Platt, S. and Olby, N.J., 2004. Paraparesis. In: *BSAVA Manual of Canine and Feline Neurology* 3rd ed., BSAVA, 237-264.

Ramon S., Dominguez R., Paraira M., Olona M., Castello T., Garcia Fernandez L., 1997. Clinical and magnetic resonance imaging correlation in acute spinal cord injury. *Spinal Cord* 35, 664-673.

Rhodes, K.E. and Fawcett, J. W, 2004. Chondroitin sulphate proteoglycans: preventing plasticity or protecting the CNS? *Journal of Anatomy*, 204, 33-48.

de Risio, L., Adams, V., Dennis, R., McConnell, F.J., Platt, S.R., 2007. Magnetic resonance imaging findings and clinical associations in 52 dogs with suspected ischemic myelopathy. *Journal of Veterinary Internal Medicine*, 21, 1290-1298.

de Risio, L., Adams, V., Dennis, R., McConnell, F.J., Platt S.R., 2008. Association of clinical and magnetic resonance imaging findings with outcome in dogs suspected to have ischemic myelopathy: 50 cases (2000-2006). *Journal of the American Veterinary Medical Association*, 233, 129-135.

de Risio, L., Adams, V., Dennis, R., McConnell F.J., 2009. Association of clinical and magnetic resonance imaging findings with outcome in dogs with presumptive acute noncompressive nucleus pulposus extrusion: 42 cases (2000-2007). *Journal of the American Veterinary Medical Association*, 234, 495-504.

Ruddle, T.L., Allen, D.A., Schertel, E.R., Barnhart, M.D., Wilson, E.R., Lineberger, J.A., Klocke, N.W., Lehenbauer, T.W., 2006. Outcome and prognostic factors in nonambulatory Hansen Type I intervertebral disc extrusions: 308 cases. *Veterinary Comparative Oorthopaedics and Traumatology*, 19, 29-34.

Rusbridge, C., Wheeler, S.J., Lamb C.R., Page, R.L., Carmichael, S., Brearley, M.J., Bjornson, A.P., 1999. Vertebral plasma cell tumors in 8 dogs. *Journal of Veterinary Internal Medicine*, 13, 126-133.

Schroeder, R., Pelsue, D.H., Park, R.D., Gasso, D., Bruecker, K.A., 2011. Contrast-enhanced CT for localizing compressive thoracolumbar intervertebral disc extrusion. *Journal of the American Animal Hospital Association*, 47, 203-209.

Scivoletto, G., Morganti, B., Ditunno, P., Ditunno, J.F., Mollinari M., 2003. Effects on age on spinal cord lesion patients' rehabilitation. *Spinal Cord*, 41, 457-464.

Scivoletto, G. and Di Donna, V., 2009. Prediction of walking recovery after spinal cord injury. *Brain Research Bulletin*, 78, 43-51.

Scott, H.W., 1997. Hemilaminectomy for the treatment of thoracolumbar disc disease in the dog: a follow-up study of 40 cases. *Journal of Small Animal Practice*, 38, 488-494.

Scott, H.W. and McKee, W.M., 1999. Laminectomy for 34 dogs with thoracolumbar intervertebral disc disease and loss of deep pain perception. *Journal of Small Animal Practice*, 40, 417-422.

Seel, R.T., Huang, M.E., Cifu, D.X., Kolakowsky-Havner, S.A., McKinley W.O., 2001. Age-related differences in length of stays, hospitalization costs, and outcomes for an injury-matched sample of adults with paraplegia. *The Journal of Spinal Cord Medicine*, 24, 241-250.

Selden N.R., Quint D.J., Patel N., D'arcy H.S., Papadopoulos S.M., 1999. Emergency magnetic resonance imaging of cervical spinal cord injuries: clinical correlation and prognosis. *Neurosurgery* 44, 785-793.

Sharp, N. and Wheeler, S., 2005. Thoracolumbar disc disease. In: *Small Animal Spinal Disorders: Diagnosis and Surgery* 2nd ed., Mosby, 121-159.

Shepard, M.J. and Bracken, M. B., 1999. Magnetic resonance imaging and neurological recovery in acute spinal cord injury: observations from the National Acute Spinal Cord Injury Study 3. *Spinal Cord*, 37, 833-837.

Shores, A., Redding, R.W., Knecht, C.D., 1987. Spinal-evoked potentials in dogs with acute compressive thoracolumbar spinal cord disease. *American Journal of Veterinary Research*, 48, 1525-1530.

Srugo, I., Aroch, I., Christopher, M.M., Chai, O., Goralnik, L., Bdolah-Abram, T., Shamir, M.H., 2011. Signs and outcome in acute nonambulatory thoracolumbar disc disease in dogs. *Journal of Veterinary Internal Medicine*, 25, 846-855.

Sylvestre, A.M., Cockshutt, J.R., Parent J.M., Brooke, J.D., Holmberg, D.L., Partlow, G.D., 1993. Magnetic motor evoked potentials for assessing spinal cord integrity in dogs with intervertebral disc disease. *Veterinary Surgery*, 22, 5-10.

Tartarelli, C.L., Baroni, M., Borghi, M., 2005. Thoracolumbar disc extrusion associated with extensive epidural haemorrhage: a retrospective study of 23 dogs. *Journal of Small Animal Practice*, 46, 485-490.

Thomson, C.E., Kornegay, J.N., Stevens, J.B., 1989. Canine intervertebral disc disease: changes in the cerebrospinal fluid. *Journal of Small Animal Practice*, 30, 685-688.

Tipold, A. and Stein, V.M., 2010. Inflammatory diseases of the spine in small animals. *The Veterinary Clinics of North America. Small Animal Practice*, 40, 871-879.

Tokunaga, S., Yamanokuchi, K., Yabuki, A., Fujiki, M., Misumi, K., 2010. Cartilage oligomeric matrix protein in canine spinal cord appears in the cerebrospinal fluid associated with intervertebral disc herniation. *Spine*, 35, 4-9.

Weaver, C.E., Park-Chung, M., Gibbs, T.T., Far, D.H., 1997. 17 beta-Estradiol protects against NMDA-induced excitotoxicity by direct inhibition of NMDA receptors. *Brain Research*, 761, 338-341.

Weil, Z.M., Norman, G.J., Devries, A.C., Nelson. R.J., 2008. The injured nervous system: A Darwinian perspective. *Progress in neurobiology*, 86, 48-59.

Weisz G. M., Lamond T. S., Kitchener P. M., 1988. Spinal imaging: will MRI replace myelography. *Spine* 13, 65-68.

Widmer, W.R. and Blevins, W.E., 1991. Veterinary myelography: a review of contrast media, adverse effects, and technique. *Journal of the American Animal Hospital Association* 27, 163-177.

Windsor, R.C., Vernau, K.M., Sturges, B.K., Kass, P.H., Vernau, W., 2008. Lumbar cerebrospinal fluid in dogs with type I intervertebral disc herniation. *Journal of Veterinary Internal Medicine*, 22, 954-960.

Wright, J.A. and Clayton, J., 1981. Metrizamide myelography in sixty eight dogs. *Journal of Small Animal Practice* 22, 415-435.

Yarkony, G.M., Roth E.j., Heinemann, A.W., Lovell, L.L., 1988. Spinal cord injury rehabilitation outcome: the impact of age. *Journal of Clinical Epidemiology*, 41, 173-177.