

## Case Report

# <sup>99m</sup>Tc-RBC Scintigraphy for diagnosis of intestinal stromal tumor hemorrhage: a case report

Jiang Wang<sup>1</sup>, Rong Zhao<sup>2</sup>

<sup>1</sup>Department of General Surgery, Urumqi General Hospital of Lanzhou Military Region, Urumqi, Xinjiang, 830002, China; <sup>2</sup>Department of Nuclear Medicine, Urumqi General Hospital of Lanzhou Military Region, Urumqi, Xinjiang, 830002, China

Received March 3, 2012; accepted March 16, 2012; Epub March 25, 2012; Published March 30, 2012

**Abstract:** Background: Gastrointestinal stromal tumors (GISTs) are rare and our understanding of the natural history and optimal treatment of GISTs are continually evolving. They are characterized by a remarkable cellular variability and their malignant potential is sometimes difficult to predict. Case presentation: We report the case of intestinal stromal tumor in a 44 years old patient with a long history of anemia and recurrent hemafecia. By using <sup>99m</sup>Tc-labeled red blood cell (<sup>99m</sup>Tc-RBC) scintigraphy, extensive tracer accumulation in the jejunum was detected. Immunohistochemically, the tumor strongly expresses the KIT (CD117) protein. The intestinal tumor was successfully resected with a postoperative favorable outcome. Conclusion: <sup>99m</sup>Tc-RBC scintigraphy is an established technique for the identification and localization of gastrointestinal bleeding. Abdominal scintigraphy appears to be a valuable supplement to conventional diagnostic methods for the diagnosis of gastrointestinal stromal tumor hemorrhage.

**Keywords:** <sup>99m</sup>Tc-RBC, abdominal, scintigraphy, gastrointestinal stromal tumors

## Introduction

Gastrointestinal stromal tumors (GISTs) comprise a rare group of neoplasms with unpredictable malignant potential and an annual incidence of 4/1,000,000 persons [1]. These tumors arise from Cajal interstitial cells. This definition excludes the gastrointestinal smooth-muscle tumors (leiomyomas/leiomyoblastomas and leiomyosarcomas), as well as schwannomas and neurofibroma [2, 3]. CD117, the c-kit proto-oncogene product, is a specific marker for GISTs.

Diagnosis of this condition is sometimes difficult and treatment is often delayed because patients usually present with nonspecific abdominal symptoms, such as abdominal pain, bloating, upper gastro-intestinal hemorrhage or anemia. Gastroscopy, endoscopic ultrasound, abdominal and pelvic imaging are helpful. However, Technetium-99m-labeled red blood cell (<sup>99m</sup>Tc-RBC) scintigraphic imaging of the lower gastrointestinal (GI) tract has proven to be beneficial in identifying active bleeding. The final

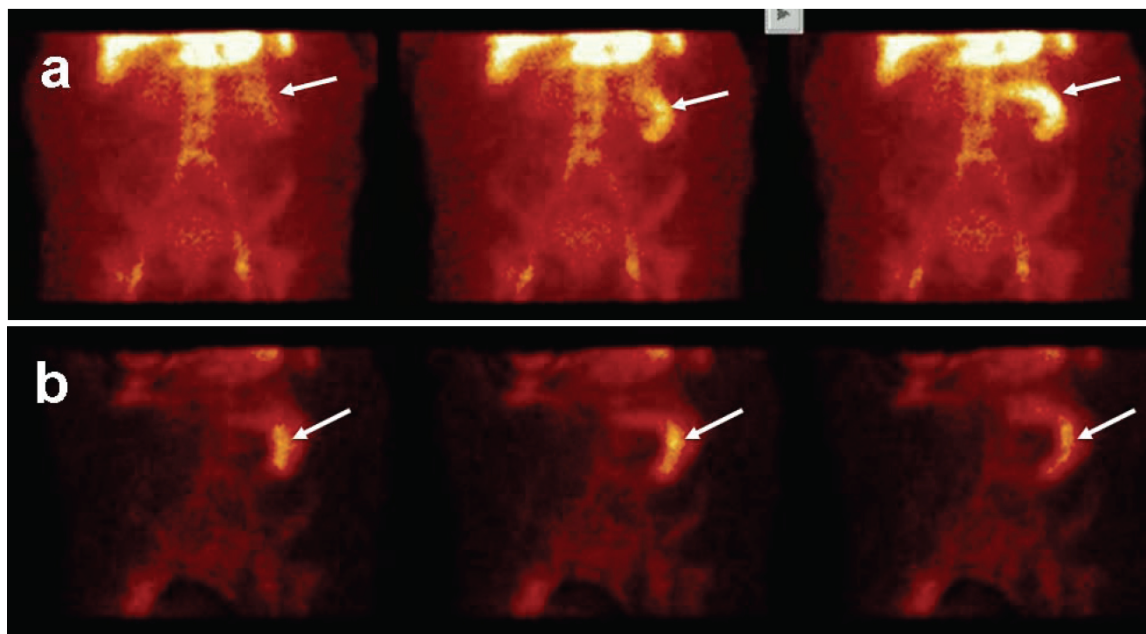
diagnosis is decided by pathological and immunohistochemical examination. The operative treatment is the first choice, and complete surgical resection is the most definitive treatment.

We report a case of intestinal stromal tumor hemorrhage that was successfully diagnosed by <sup>99m</sup>Tc-RBC scintigraphy and treated with surgery.

## Case presentation

### Clinical summary

A 44-yr-old female with a 3-yr history of slight abdominal pain, anemia and recurrent hemafecia was hospitalized. Because of a hemoglobin level of 4.1 g/dl, which was significantly lower than normal, and continual hemafecia, the patient was hospitalized and a diagnostic for gastrointestinal bleeding was undertaken. The physical examination found that she was pale, with mild left upper abdominal tenderness. Blood count test revealed anemia, hematocrit of 32.6%, white blood cell count of  $15.1 \times 10^9$ /liter, and platelets of  $178 \times 10^9$ /liter, while



**Figure 1.** In the dynamic imaging phase (a) a tracer accumulation throughout the left upper abdomen could already be seen (arrow heads). There was a distinct increase with time. In the blood-pool phase (b), the images obtained 20, 25 and 30min postinjection revealed tracer accumulation in the jejunum (arrows).

liver function tests and serum electrolytes were normal. Upper and lower digestive endoscopy was negative.

### Methods

To detect active bleeding, radionuclide imaging with <sup>99m</sup>Tc-RBCs (using a modified in vivo method) was performed using a large-field-of-view gamma camera with a low-energy, all-purpose parallel-hole collimator. Imaging began immediately after injection of <sup>99m</sup>Tc-RBCs (20 mCi, 740 MBq), dynamic imaging of 1-min duration was performed. Then static images of each 500 K counts were taken every 5 min up to 1h. There was an increased activity in the left upper abdomen followed by a tracer accumulation throughout the entire jejunum, which increased with time (**Figure 1**). Maximum intensity was reached at 25 min time point and then constantly persisted (arrow head). Meanwhile, there was no transport within the small bowel during the investigation. We finally suggested that the initial site of tracer accumulation in the jejunum was responsible for the extensive tracer accumulation.

Subsequently, an emergency abdominal ultrasound examination described a hypoechoic,

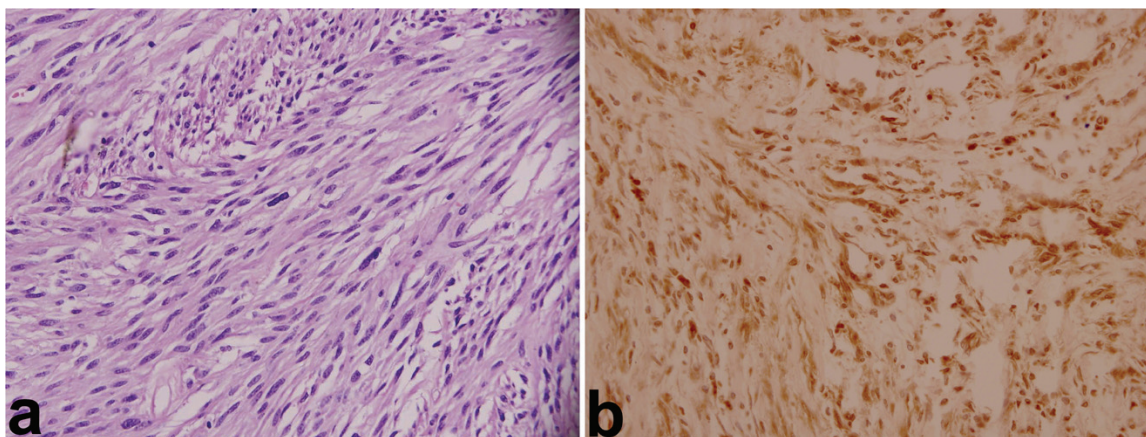
vascularized tumor of the left upper abdominal cavity with a size of 74 x 58 x 55 mm. Abdominal CT scan showed dense, homogeneous mass at the jejunum (62 x 46 x 60 mm, 56-67 HU). The patient underwent an emergency exploratory laparotomy due to the concern for continued hemorrhage.

### Pathological findings

The exploration revealed a 80 x 80 x 70 mm solid mass arising from the jejunum, located 60 cm proximal to the ligament of Treitz. Further intraoperative exploration did not reveal any other pathological findings. Histological examination described a jejunum stromal tumor (**Figure 2A**). Immunohistochemical staining confirmed the diagnosis of GIST (CD117 positive) (**Figure 2B**). The margins of surgical resection and all identified mesenteric lymph nodes were negative for malignancy. Resection margins as well as mesentery were disease free. The patient made a very satisfactory recovery and was discharged after 9 days.

### Discussion

GISTs are the most common mesenchymal tumors of the gastrointestinal tract. The common



**Figure 2.** a. histological features of the GIST. Note the spindle type cells including mitotic figures (H&E stain, 400x). b. Immunohistochemical analysis results demonstrated the tumor cells are strongly positive for CD117 (c kit protein, 400x).

sites of location are in the order of stomach (60~70%), small intestine (20~30%), rectum, esophagus and a small percent may be located elsewhere in the abdominal cavity. The most common clinical findings include abdominal pain, dysphagia, weight loss, gastrointestinal bleeding, bowel obstruction, or an abdominal mass [4]. These nonspecific symptoms rely mainly on the location and size of the tumors. Consequently, their diagnosis is often delayed or even overlooked and usually is made after laparotomy and formal pathologic examination [5]. GISTs tend to grow in an extraluminal fashion; however, they can also erode into the lumen of the gastrointestinal tract inducing significant hemorrhage [6]. Our patient presented with severe anemia and recurrent hemafecia, which could be explained from bleeding inside the intestinal tract.

The definite diagnosis of GIST is secured by immunohistochemical staining for the tyrosine kinase receptor KIT (CD117), which highlights the presence of interstitial cells of Cajal (ICC) [7]. KIT is regarded as a key confirmatory marker in the diagnosis of this tumor. Approximately two thirds of GISTs also express CD34. GISTs and ICCs are detected with antibodies to KIT, suggesting that GISTs originate from the ICCs. As seen in the jejunal GIST of our patient, KIT was positive.

In general, CT scans can be useful in diagnosing GIST by the presence of a large exophytic tumor with heterogeneous contrast enhancement, arising from the stomach or small bowel. How-

ever, the small intestinal GIST was difficult to diagnose initially because of nonspecific symptoms when tumors were small or the lack of symptoms. A lesion was not found until the tumor became larger and caused bleeding or mass effect. Lupescu et al. have reported that the most common symptom of GIST was abdominal pain (66.6%), a palpable abdominal mass (53.3%), weight loss (33.3%), and gastrointestinal bleeding (20%) [8]. The presence of active gastrointestinal bleeding can usually be diagnosed by a combination of history, physical examination, stool guaiac tests, and serial blood counts. However, it is difficult to find the actually site of active gastrointestinal bleeding. Endoscopy, barium examination, angiography, and exploratory laparotomy are the common methods of localizing GI hemorrhage. Endoscopy is especially useful in determining the site of bleeding in the upper gastrointestinal hemorrhage, but the procedure is difficult to perform in the poorly prepared colon. Moreover, it cannot find lesions in the distal duodenum, jejunum, and ileum. Angiography is widely used, but it is invasive, time-consuming, and carries significant complications. Also, the barium examination is often inconclusive during active bleeding and may reveal lesions that are not responsible for the acute bleeding. Because of these shortcomings, a noninvasive imaging technique that allows to detect the presence of continuing hemorrhage as well as to locate the site of bleeding would be helpful in the management of acute gastrointestinal hemorrhage. In addition, it is advantageous to use a gamma camera with a large field of view, making it possible to show

the entire abdominal cavity in one image.

The use of radionuclide tracers for the evaluation of bleeding began in the late 1970's when Alavi et al. first demonstrated active gastrointestinal bleeding lesions using <sup>99m</sup>Tc-sulfur colloid (<sup>99m</sup>Tc-SC). Later, the use of <sup>99m</sup>Tc-RBCs has largely replaced <sup>99m</sup>Tc-SC [9]. McKusick et al. reported that <sup>99m</sup>Tc-RBC scintigraphy is more sensitive than angiography for detecting bleeding sites and that angiography is likely to be negative if the scintigram fails to show the bleeding focus.

Because of the non-diagnostic physical findings of hemorrhage, the patient in our study had undergone many investigations with various imaging modalities within three years without a definitive diagnosis. In our study, <sup>99m</sup>Tc-RBC scintigraphy succeeded in demonstrating acute bleeding of jejunum. The data from this study suggest that <sup>99m</sup>Tc-RBC scintigraphy can provide an effective diagnostic tool in the management of patients with intermittent gastrointestinal hemorrhage, especially in patients with lower gastrointestinal bleeding. It can be particularly useful when the indications of continued active hemorrhage are obscure.

## Conclusion

This case presents an unusual jejunum gastrointestinal stromal tumor due to hemorrhage and emphasizes the importance of the <sup>99m</sup>Tc-RBC scintigraphy in the difficult diagnosis of unexplained gastrointestinal bleeding. Despite the concern of specificity, positive <sup>99m</sup>Tc-RBC scan will direct attention to the area of abnormality. Moreover, radionuclide scintigraphy provides a safe and simple procedure that is available in most medical centers. We believe that <sup>99m</sup>Tc-RBC scintigraphy should be more widely employed as a complementary, sensitive and non-invasive method for the localization of GIST bleeding. In addition, it may have a role to guide other invasive, diagnostic and/or therapeutic procedures.

**Address correspondence to:** Dr. Rong Zhao, Department of Nuclear Medicine, Urumqi General Hospital of Lanzhou Military Region, Urumqi, Xinjiang, 830002, China E-mail: zhaorongweiran@yahoo.com.cn

## References

- [1] Matthews BD, Joels CS, Kercher KW, Heniford BT. Gastro intestinal stromal tumors of the stomach. *Minerva Chir* 2004; 59: 219-231.
- [2] Miettinen M, Lasota J. Gastrointestinal stromal tumors: definition, clinical, histological, immunohistochemical, and molecular genetic features and differential diagnosis. *Virchows Archiv* 2001; 438: 1-12.
- [3] Strickland L, Letson GD, Muro-Cacho CA. Gastrointestinal stromal tumors. *Cancer Control* 2001; 8: 252-261.
- [4] Sharp RM, Ansel HJ, Keel SB: Best cases from the AFIP. gastrointestinal stromal tumor. Armed Forces Institute of Pathology. *Radiographics* 2001; 21: 1557-1560.
- [5] Crosby JA, Catton CN, Davis A, Couture J, O'Sullivan B, Kandel R, Swallow CJ. Malignant gastrointestinal stromal tumors of the small intestine: a review of 50 cases from a prospective database. *Ann Surg Oncol* 2001; 8: 50-99.
- [6] Hirasaki S, Fujita K, Matsubara M, Kanzaki H, Yamane H, Okuda M, Suzuki S, Shirakawa A, Saeki H. A ruptured large extraluminal ileal gastrointestinal stromal tumor causing hemoperitoneum. *World J Gastroenterol* 2008; 14: 2928-2931.
- [7] Chan JK. Mesenchymal tumors of the gastrointestinal tract: a paradise for acronyms (STUMP, GIST, GANT, and now GIPACT), implications of c-kit in genesis, and yet another of the many emerging roles of the interstitial cell of Cajal in the pathogenesis of gastrointestinal diseases? *Adv Anat Pathol* 1999; 6: 19-40.
- [8] Ioana G, Lupescu, Mugur Grasu, Mirela Boros, Cristian Gheorghe, Mihnea Ionescu, Irinel Popescu, Vlad Herlea, Serban A. Georgescu. Gastrointestinal Stromal Tumors: Retrospective Analysis of the Computer-Tomographic Aspects. *J Gastrointest Liver Dis* 2007; 16: 147-151.
- [9] Bunk SR, Lull RJ, Tanasescu DE, Redwine MD, Rigby J, Brown JM. Scintigraphy of gastrointestinal hemorrhage. Superiority of <sup>99m</sup>Tc red blood cells over <sup>99m</sup>Tc-sulfur colloid. *Am J Roentrol* 1984; 143: 543-548.