

Case Report

Glanzmann's thrombasthenia: report of a case and review of the literature

Christopher Sebastiano, Michael Bromberg, Karen Breen, Matthew T. Hurford

Department of Pathology and Laboratory Medicine, Temple University Hospital, Philadelphia, PA, USA

Received November 15, 2009, accepted March 25, 2010, available online: April 25, 2010

Abstract: Glanzmann's thrombasthenia is a rare congenital bleeding disorder. Patients usually present with mucocutaneous bleeding and excessive bleeding associated with trauma and/or surgery. Patients have an increased bleeding time and a normal platelet count with abnormal platelet function assays. Genetically, Glanzmann's thrombasthenia is associated with mutations in the genes which encode for glycoproteins, GPIIb or GPIIIa. Defects in these genes lead to a lack of or highly reduced expression of the glycoprotein complex (GPIIb/GPIIIa), resulting in platelet dysfunction. Bleeding is managed by platelet transfusions. Bone marrow transplants have been used successfully in rare cases. With proper supportive care Glanzmann's thrombasthenia has a very good prognosis.

Keywords: Glanzmann's thrombasthenia, glycoprotein complex, GPIIb/GPIIIa, platelet dysfunction, literature review

Introduction

Glanzmann's thrombasthenia was first documented in 1918 by Dr. Eduard Glanzmann, who described a novel platelet abnormality with defective clot retraction and abnormal appearance on stained film [1]. It has since been more specifically described as an autosomal recessive genetic disorder in which the platelet count is normal or subnormal, the bleeding time is prolonged, and platelet aggregation is deficient or absent [2-4]. Due to this deficiency of platelet function it manifests as a bleeding disorder characterized by mucocutaneous hemorrhage of varying severity. Globally, it is extremely rare but it has a relatively high incidence in consanguineous populations where intermarriage is common [5]. Despite its rarity, it has gained attention since the discovery of its pathophysiology, due to the consequent development of anti-platelet agents now commonly used during percutaneous coronary interventions [6]. In this report, we describe a case of Glanzmann's thrombasthenia and review the current literature.

Patient history

The patient was a Puerto Rican female who pre-

sented with fever, shortness of breath, fatigue, and chest pain. She had a long clinical history of easy and spontaneous bruising, excessive bleeding with tooth extractions, severe epistaxis as a child, and heavy menstrual bleeding. There was no family history of easy bruising or excessive bleeding. During hospitalization the patient became hypotensive but responded successfully to treatment. However, the fever was persistent and no origin was found. The patient subsequently developed hypoxia with no response to therapy and expired. At autopsy, the patient's anatomic cause of death was found to be acute hemorrhagic fibrinous pericarditis. The autopsy also revealed petechial hemorrhages on numerous skin sites as well as foci of hemorrhage in the lungs. Additionally, intramucosal petechial hemorrhages were present in the stomach and duodenum.

Clinical features

Patients with Glanzmann's thrombasthenia typically present in infancy or early childhood with purpura, epistaxis, gingival bleeding, and prolonged bleeding from trauma [5]. The bleeding which is universal to the disorder is typically not spontaneous, but rather an exaggeration of bleeding which occurs in normal patients [5].

Cutaneous purpura usually arise as a result of pressure or minor trauma, and truly spontaneous purpura are rare [5]. As in normal patients epistaxis is common in childhood and usually subsides by adulthood, but it is more severe and the most common cause for bleeding of clinical significance [5]. Gingival bleeding is also common, though it is more often found in those with poor dental hygiene [5]. Menorrhagia occurs in most female patients at the time of menarche and presents a considerable hemorrhagic concern, usually requiring transfusion [2, 5, 7]. Gastrointestinal hemorrhage, hematuria, and hemarthroses have been observed in a small number of patients but are potentially quite severe [5, 7]. Complications from Glanzmann's thrombasthenia may arise during child birth, tooth extraction, or any surgical procedure.

Pathology

Discoveries in the pathophysiology of Glanzmann's thrombasthenia have greatly increased our understanding of the mechanisms underlying platelet aggregation. The disorder is caused by deficiency or abnormality of the platelet glycoprotein IIb and/or IIIa [8-11]. A single platelet membrane is covered with approximately 50,000 copies of the GPIIb/IIIa integrin complex [1, 12]. Platelet activation confers a conformational change in the complex allowing it to bind to fibrinogen on both subunits [7, 13, 14]. Von Willebrand Factor, fibronectin, and vitronectin also bind the complex though with lower affinity than fibrinogen [1, 4]. The binding of fibrinogen to this complex allows it to bridge two platelets in the presence of calcium to initiate primary and secondary platelet aggregation. Platelet aggregation is deficient when any component of the complex is mutated or the complex is present in subnormal amounts. Thus, patients with thrombasthenia have a normal platelet count but these platelets cannot bind fibrinogen after stimulation and thus cannot aggregate properly.

Genetics

Glanzmann's thrombasthenia has an autosomal recessive pattern of inheritance. Heterozygotes appear asymptomatic and have essentially normal platelet function tests [5, 7]. Although it is extremely rare worldwide it is found with relatively high frequency within populations that have a prevalence of consanguineous mar-

riages, where its frequency may rival that of much more common disorders such as Von Willebrand's Disease [5]. The four populations (all of which have a high frequency of intermarriage) in which it is most commonly seen are French Gypsies, Iraqi Jews, Jordanian Arabs, and South Indians [7, 15-18]. The genes encoding for GPIIb and GPIIIa both localize to chromosome 17q 21-23 and several mutations found in these genes lead to lack of or highly reduced expression of the glycoprotein complex, resulting in the platelet dysfunction described above [1,9].

The disorder has been divided into three classifications, which were initially based on fibrinogen content and degree of clot retraction, before the GPIIb/IIIa complex was understood [5]. These classifications have since been adapted to the more recent molecular understanding of the disease. Type I and Type II result from mutations of GPIIb or GPIIIa that cause lack of (i.e., less than 5% of normal) or reduced expression (i.e., 10-20% of normal), respectively, of the IIb/IIIa complex on the platelet surface [5, 19]. By contrast, asymptomatic heterozygotes express 50-60% of the complex [5, 7]. Additionally, rare mutations may result in a dysfunctional complex that is expressed at a normal or subnormal amount resulting in the Type III, or variant form [5, 19]. These classifications allow for a better comparison of molecular abnormalities to clinical disease, but unfortunately for the most part the two do not correlate [5].

Laboratory diagnosis

Glanzmann's thrombasthenia is characterized by normal platelet morphology and normal platelet count, prolonged bleeding time, absent or decreased clot retraction, and normal platelet aggregation in the presence of ristocetin (**Figure 1**). Platelet aggregation is absent in the presence of epinephrine (**Figure 2**), collagen (**Figure 3**), Arachidonic Acid (**Figure 4**), ADP (**Figure 5**), due to the dependence of these factors on fibrinogen attachment to the platelet for aggregation [4, 20, 21]. Platelet aggregation occurs normally in response to ristocetin due to its independence from fibrinogen. Flow cytometry can also be used to detect the presence of the GPIIb-IIIa complex, GPIIb (CD41), GPIIIa, (CD61) and fibrinogen by using monoclonal antibodies [22]. This method can also be used to rapidly predict the carrier status of family

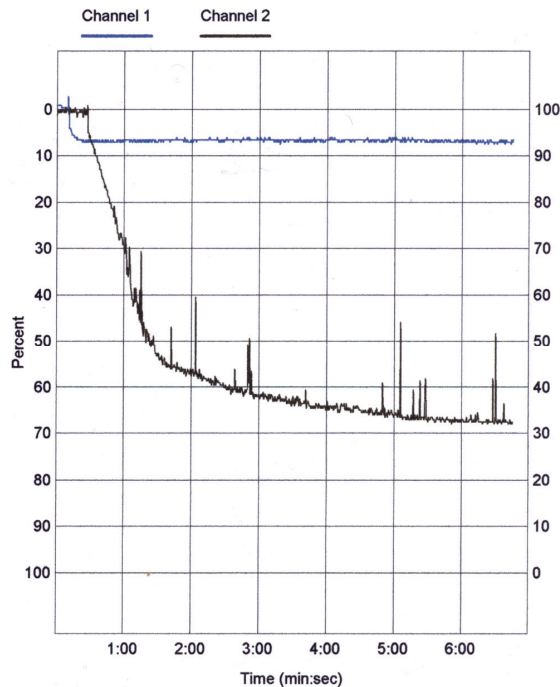


Figure 1. Platelet aggregation tracings for Ristocetin. Blue – No platelet aggregation (normal) with 0.50ug/ml Ristocetin. Black – Normal platelet aggregation with 1.2ug/ml Ristocetin.

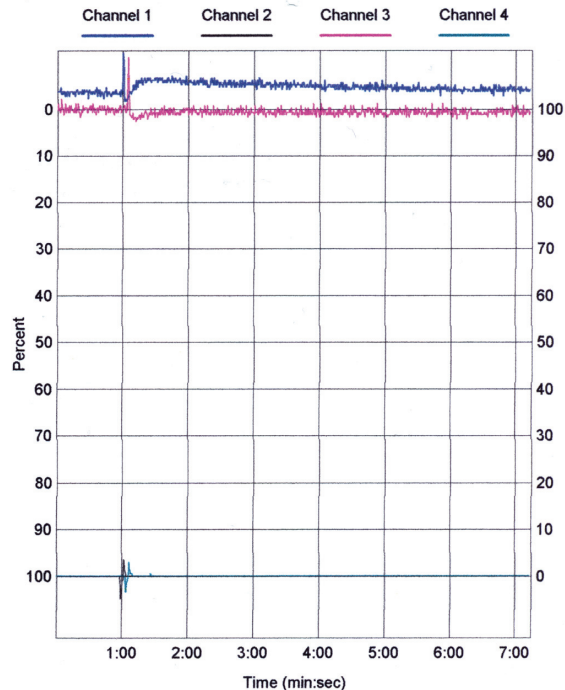


Figure 2. Platelet aggregation and secretion tracings for Epinephrine. Blue – No platelet aggregation with 7.5 μ M Epinephrine. Black – No ATP secretion with 7.5 μ M Epinephrine. Red – No platelet aggregation with 10.0 μ M Epinephrine. Green – No ATP secretion with 10.0 μ M Epinephrine.

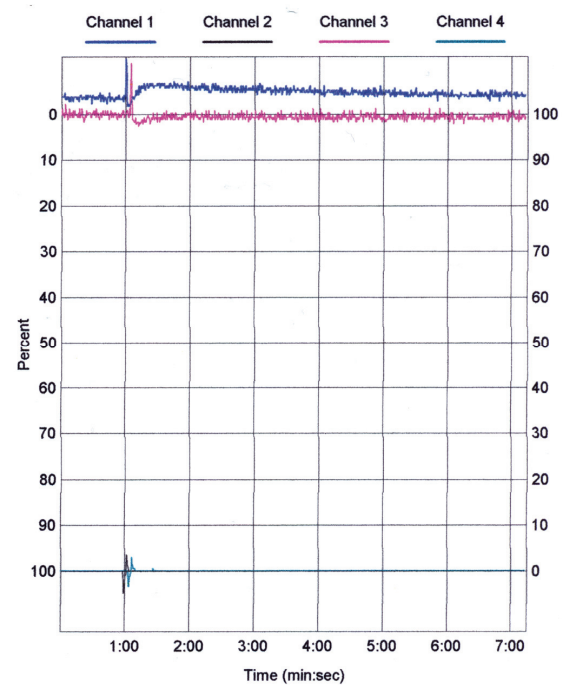


Figure 3. Platelet aggregation and secretion tracings for collagen. Blue – No platelet aggregation with 1.0 μ g/ml collagen. Black – No ATP secretion with 1.0 μ g/ml collagen. Red – No platelet aggregation with 5.0 μ g/ml collagen. Green – No ATP secretion with 5.0 μ g/ml collagen.

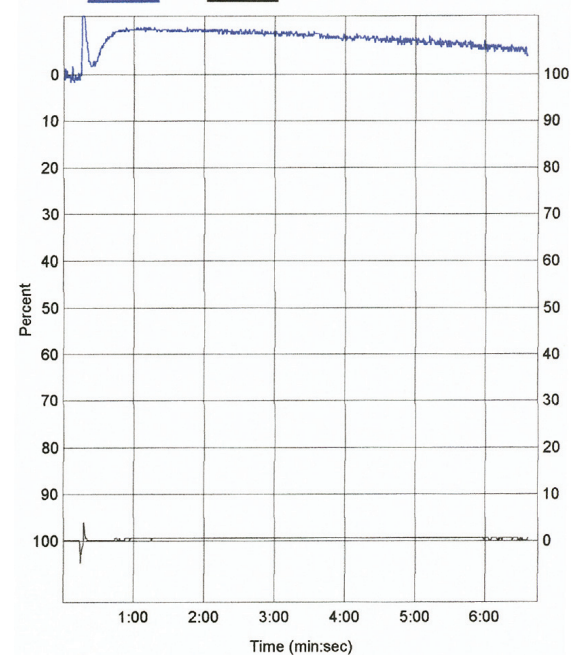


Figure 4. Platelet aggregation and secretion tracings for Arachidonic Acid. Blue – No platelet aggregation with 50 μ g/ml Arachidonic Acid. Black – No ATP secretion with 50 μ g/ml Arachidonic Acid.

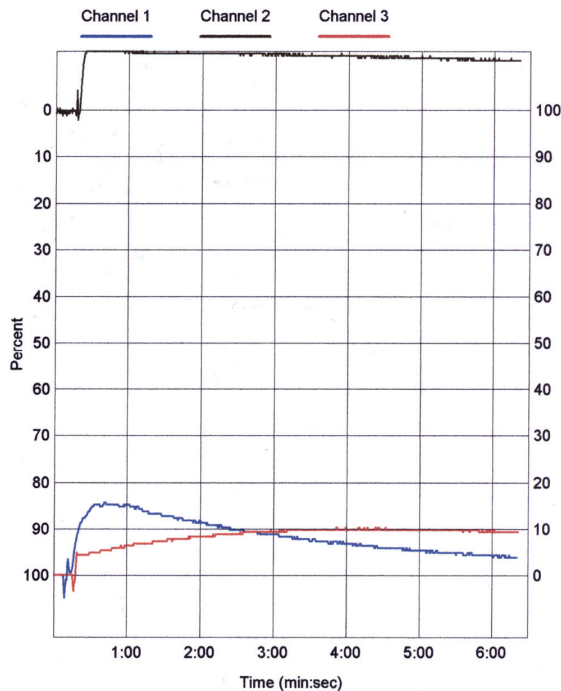


Figure 5. Platelet aggregation and secretion tracings for ADP and thrombin. Blue – markedly decreased secretion with 1 unit of thrombin. Black – No platelet aggregation with 2.5 μ M ADP. Red – No ATP secretion with 2.5 μ M ADP.

members of patients with the disorder [23]. DNA analysis is the most accurate in carrier detection but only when the defect is known, limiting its clinical utility. GPIIb-IIIa quantification by monoclonal antibodies and platelet antigen detection may be used for prenatal diagnosis of type I Glanzmann's thrombasthenia and heterozygous state [24, 25].

Therapy and prognosis

There is no known cure for Glanzmann's thrombasthenia. The overall morbidity and mortality have been difficult to estimate due to its rarity, but in most studies the prognosis has proven to be very good [5, 7]. Hemorrhage is naturally the main clinical concern and supportive care is critical. Platelet transfusion is necessary before any invasive procedure or heavy bleeding episode [5]. Platelet alloimmunization against HLA group and/or GPIIb/IIIa glycoproteins is a genuine concern, but the risk is no greater than for any transfused patient and it is not a contraindication to this therapy [5, 19]. Other than transfusion, management is primarily preventive

care. Drugs that affect platelet function, such as NSAIDs or aspirin, should be avoided. Immunizations for hepatitis B should be given due to the infectious risks of frequent transfusion. Oral contraceptives may be taken to treat menorrhagia [5]. Regular dental visits are encouraged to avoid gingivitis and gingival bleeding, and supplements are suggested during early childhood and adolescence to avoid iron deficiency anemia which is commonly caused by such bleeding [5]. Desmopressin (dDAVP) has been attempted as therapy but has not shown any proven clinical usefulness [26]. Bone marrow transplants have been used successfully in rare cases, though this remains a drastic treatment [27, 28].

In summary, Glanzmann's thrombasthenia is a rare inherited bleeding disorder. It is primarily found in a limited number of populations in which consanguineous marriage is common. Patients usually present with easy bruising and bleeding from epistaxis and dental extractions. Patients have a normal platelet count but increased bleeding time and abnormal platelet function assays. Genetically, Glanzmann's thrombasthenia has an autosomal recessive pattern and may arise from a number of mutations that affect GPIIb, GPIIIa, and/or the GPIIb/IIIa complex. The classification of type I and type II Glanzmann's thrombasthenia is based upon the amount of GPIIb/IIIa complex present on the platelet surface, whereas the variant form is classified by an abnormal GPIIb/IIIa complex present at normal or subnormal amounts. Supportive treatment is the best means for care, and bleeding is managed by platelet transfusions. Bone marrow transplants have been used successfully in rare cases. With proper supportive care Glanzmann's thrombasthenia has a very good prognosis.

Please address correspondence to: Mathew T. Hurford, M.D., Department of Pathology and Laboratory Medicine, Temple University Hospital, 3401 North Broad Street Philadelphia, PA 19140. Tel: 215-707-7740; Fax: 215-707-2053; Email: matthewh@temple.edu

References

- [1] Glanzmann E. Hereditaire Hamorrhagische thrombasthenie. Ein Beitrag Zur Pathologie der Blutplättchen. Jahrbuch Kinderheilkde. 1918; 88: 1– 42.
- [2] Hardisty RM, Dormandy KM, Hutton RA. Thrombasthenia: studies on three cases. Br J Haema-

- tol. 1964; 10: 371-87.
- [3] Pittman MA Jr., Graham JB. Glanzmann's thrombopathy: an autosomal recessive trait in one family. *Am J Med Sci.* 1964; 247: 293-303.
- [4] Larrieu MJ, Caen JP, Meyer DO, Vainer H, Sultan Y, Bernard J. Congenital bleeding disorders with long bleeding time and normal platelet count. II. Von Willebrand's disease (report of thirty-seven patients). *Am J Med.* 1968 Sep;45(3):354-72.
- [5] George JN, Caen JP, Nurden AT. Glanzmann's thrombasthenia: the spectrum of clinical disease. *Blood.* 1990; 75: 1383-95.
- [6] Seligsohn U. Glanzmann thrombasthenia: a model disease which paved the way to powerful therapeutic agents. *Pathophysiol Haemost Thromb.* 2002; 32: 216-17.
- [7] Caen JP. Glanzmann's thrombasthenia. *Baillieres Clin Haematol.* 1989; 2: 609-625.
- [8] Nurden AT, Caen JP. An abnormal platelet glycoprotein pattern in three cases of Glanzmann's thrombasthenia. *Br J Haematol.* 1974; 28: 253-60.
- [9] Phillips DR, Jenkins CSP, Luscher EF, Larrieu M-J. Molecular differences of exposed surface proteins on thrombasthenic platelet plasma membranes. *Nature.* 1975; 257: 599-600.
- [10] French DL. The molecular genetics of Glanzmann's thrombasthenia. *Platelets*[1].1998; 9: 5-20.
- [11] Nurden AT. Inherited abnormalities of platelets. *Thromb. Haemost.* 1999; 82: 468-480.
- [12] Collier BS, Cheresh DA, Asch E and Seligsohn U. Platelet vitronectin receptor expression differentiates Iraqi-Jewish from Arab patients with Glanzmann's thrombasthenia in Israel. *Blood.* 1991; 77: 75-83.
- [13] Van Willigen G, Hers I, Gorter G and Akkerman JW. Exposure of ligand-binding sites on platelet integrin alpha IIb/beta 3 by phosphorylation of the beta 3 subunit. *Biochem J.* 1996; 314: 769-779.
- [14] Kieffer N and Phillips DR. Platelet membrane glycoproteins: functions in cellular interactions. *Ann Rev Cell Biol.* 1990; 6: 329-357.
- [15] Caen JP. Glanzmann's thrombasthenia. *Clin Haematol.* 1972; 1: 383-92.
- [16] Khanduri U, Pulimood R, Sudarsanam A, Carman RH, Jadhav M, Pereira S, Pulimood BM. A review and report of 42 cases from South India. *Thromb Haemost.* 1981; 46: 717-21.
- [17] Seligsohn U, Rososhansky S. A Glanzmann's thrombasthenia cluster among Iraqi Jews in Israel. *Thromb Haemost.* 1984; 52: 230-1.
- [18] Awidi AS. Increased incidence of Glanzmann's thrombasthenia in Jordan compared with Scandinavia. *Scand J Haematol.* 1983; 30: 218-22.
- [19] Bellucci S, Caen JP. Molecular basis of Glanzmann's Thrombasthenia and current strategies in treatment. *Blood Reviews.* 2002; 16: 193-202.
- [20] Zucker MB, Pert JH, Hilgartner MW. Platelet function in a patient with thrombasthenia. *Blood.* 1966; 28: 524-34.
- [21] Weiss HJ, Kochwa S. Studies of platelet function and proteins in three patients with Glanzmann's thrombasthenia. *J Lab Clin Med.* 1968; 71: 153-65.
- [22] Warkentin TE, Powling MJ, Hardisty RM. Measurement of fibrinogen binding to platelets in whole blood by flow cytometry: a micromethod for the detection of platelet activation. *Br J Haematol.* 1990; 76: 387-94.
- [23] Sharp WJ, Khanduri UD, Christie BS. Rapid heterozygote detection in Glanzmann's thrombasthenia. *Br J Haematol.* 1998; 101: 66- 9.
- [24] Seligsohn U, Mibashan RS, Rodeck CH, Nicolaides KH, Millar DS, Collier BS. Prenatal diagnosis of Glanzmann's thrombasthenia. *Lancet* 1985; 2: 1419.
- [25] Kaplan C, Patereau C, Reznikoff-Etievant MN, Muller JY, Dumez Y, Kessler A. Antenatal PLA1 typing and detection of GP IIb-IIIa complex. *Br J Haematol.* 1985 Jul;60(3):586-8.
- [26] Lethagen S and Nilsson IM. DDAVP-induced enhancement of platelet retention: Its dependence on platelet-von Willebrand Factor and the platelet receptor GPIIb/IIIa. *Eur J Haematol.* 1992; 42: 7-13.
- [27] Bellucci S, Devergie A, Gluckman E, Tobelem G, Lethielleux P, Benbunan M, Schaison G, Boiron M. Complete correction of Glanzmann's thrombasthenia by allogeneic bone-marrow transplantation. *Br J Haematol.* 1985 Apr;59(4):635-41.
- [28] Bellucci S, Damaj G, Boval B, Rocha V, Devergie A, Yacoub-Agha I, Garderet L, Ribaud P, Traineau R, Socié G, Gluckman E. Bone marrow transplantation in severe Glanzmann's thrombasthenia with antiplatelet alloimmunization. *Bone Marrow Transplant.* 2000; 25: 327-330.