

## Case Report

# A rare pediatric case of a thymic cytotoxic and lymphoblastic T/NK cell lymphoma

Timo Gaiser<sup>1</sup>, Wolfgang Haedicke<sup>2</sup>, Maria R. Becker<sup>3</sup>

<sup>1</sup>Section of Cancer Genomics, National Cancer Institute, National Institutes of Health, Bethesda, MD, USA; <sup>2</sup>Institute of Pathology, IFP-Spandau, Berlin, Germany; <sup>3</sup>Department of Dermatology, University of Heidelberg, Germany. Current address: Center for Cancer Research, National Cancer Institute, National Institutes of Health, Bethesda, MD, USA.

Received February 17, 2010, accepted March 17, 2010, available online: March 20, 2010

**Abstract:** Attempts to establish a concise classification of lymphoblastic lymphomas (LBLs) have gained momentum in recent years, mainly due to the expanding possibilities of immunohistochemical and genetic characterization of different disease entities. Thus, cases of immature lymphoid malignancies with unusual immunopathological features have been reported during the last years, suggesting the need for new LBL classification concepts. To further characterize and demonstrate the extended spectrum of LBL, we present an unusual pediatric case of LBL that could not be categorized into one of the subgroups and exhibited a benign course after surgical treatment and subsequent chemotherapy. A mediastinal tumor of a 6-year-old Caucasian boy was examined by clinical staging, light microscopy, immunohistochemistry and PCR assays. The tumor cells reacted with TdT and had a positive cytoplasmic immunoreactivity for CD3. Further T- and NK-cell markers CD1a, CD4, CD8, CD10, and CD56 reacted positively, but CD57, CD16 and CD 30 (Ber H2) were all negative. CD34 as a marker for bipotential B/T-precursors was also positive. B cell markers (CD20, CD22, Cd79a and IgM) were all negative. No clonal B cell Ig or T cell gamma chain rearrangements were detectable. Epstein Barr virus and other Herpes Virus DNA were not detected using a sensitive PCR assay. The applied chemotherapy was tolerated well and a complete remission of the tumor was achieved (observation period three years after the initial diagnosis). Localization, morphology, and the expressions markers made the tumor a typical member of the LBL group. However, our case represents a rare pediatric lymphoma derived from a thymic precursor committed to T/NK-cell differentiation and a favourable outcome after chemotherapy.

**Keywords:** lymphoblastic lymphomas, T/NK cell lymphoma, pediatric lymphoma

## Introduction

Lymphoblastic lymphoma (LBL) is a distinct category of non-Hodgkin lymphoma derived from a lymphocytic precursor. It was first discovered by Sternberg [1] and clinically characterized by Cooke [2]. Only 4% of the non-Hodgkin lymphomas are considered to be LBLs and the majority of them has a thymic T-cell origin [3]. Sheibani et al [4] classified the LBLs into five subgroups based on their immunophenotype: 1. T-LBL (expression of only T cell-associated antigens); 2. T-LBL with expression of common acute lymphoblastic leukemia antigen (expression of T-associated antigens with CD10); 3. Natural killer (NK)-LBL (expression of CD16 with or without T-associated antigens); 4. Pre-B-LBL (expression of CD24 without T-associated antigen); 5. B-LBL (expression of

monoclonal surface membrane immunoglobulin, IgM, without terminal deoxynucleotidyltransferase (TdT)).

Recently, following the discovery of further phenotypic markers and new antibodies, a more detailed immunophenotypic analysis has become possible and new entities have been proposed [5]: 1. CD7+ blastic stem cell leukemia (a pluripotent stem cell malignancy) [6]; 2. Blastic NK cell lymphoma (own entity in the new WHO classification of lymphomas) [7]; 3. Myeloid NK cell precursor cell leukemia (derived from a myeloid antigen-positive precursor preceding a NK cell precursor) [8]; 4. CD4+ CD56+ hematodermic lymphoma (derived from precursor cells related to plasmacytoid monocytes) [9]. All of these subtypes share an aggressive clinical course with rapid systemic involvement and a

poor prognosis. The close relationship between T-cells and NK-cells in the fetal thymus has been vigorously studied and there is common agreement that within human fetal thymocytes there is a population of T-cell/NK-cell (T/NK) bipotential progenitors with the ability to differentiate into T cells and NK cells through further separate precursors [10-12]. These bipotential progenitors can be characterized by the phenotype of CD3+, CD7+, CD13+, CD33+, CD34+, CD38+, HLA-DR+/-, CD2+/-, CD5+/-, CD28+/-, CD1-, no T cell receptor (TCR) gene rearrangement or CD56/CD16 expression [13]. Here, we describe a rare pediatric case of LBL with similar pheno/genotype of committed T/NK cell precursors and a surprisingly favorable prognosis after surgical treatment and subsequent chemotherapy.

## Case history

A 6-year-old previously healthy boy presented with oligoarthritic joint pain, fever of 38°C and weight loss. Chest x-ray showed significantly enlarged mediastinal lymph nodes. Computed tomography and magnetic resonance imaging (MRI) revealed a 6x5x3cm mass in the anterior mediastinum compressing the Vena cava superior. Further physical examination, bone marrow biopsy, and scintigraphy revealed no evidence of bone marrow involvement.

Lymph node extraction near the M.sternocleidomastoideus and subsequently pathological examination showed an unspecific lymphadenitis. The thereafter performed thoracotomy disclosed a solid tumor mass caudal of the thymus extending to the jugulum and infiltrating the vena cava superior through the right atrium. The tumor and parts of the vena cava were resected, yielding a macroscopic R0 resection. Without suffering from postoperative complications the patient received a polychemotherapy according to the NHL-BFM 95 protocol [14]. The chemotherapy was tolerated well and a complete remission of the tumor was achieved. Regular follow-ups during an observation period of three years showed no recurrence of the tumor until now.

## Materials and methods

Immunohistochemical analysis was performed on Formalin-fixed, paraffin-embedded tissue sections. Immunostaining was done with the

following monoclonal antibodies: CD1a, CD8, CD20, CD22, CD79a, CD56, CD30, MIB1(Dako, Glostrup; Denmark), c-Kit, TdT, CD2, CD4, CD3, CD5, CD16, CD34, CD43, Granzyme B (Novocastra, Newcastle; UK), TIA-1 (Coulter, Hialeah; USA), CD57 (Becton-Dickinson, San Jose; USA). Antibody binding was visualized using the Envision System (Dako, Glostrup; Denmark) system as described by the manufacturer. Herpes Virus, TCR gene rearrangement and B cell clonality PCR assays were performed as published previously [15-17].

## Pathologic and immunohistochemical findings

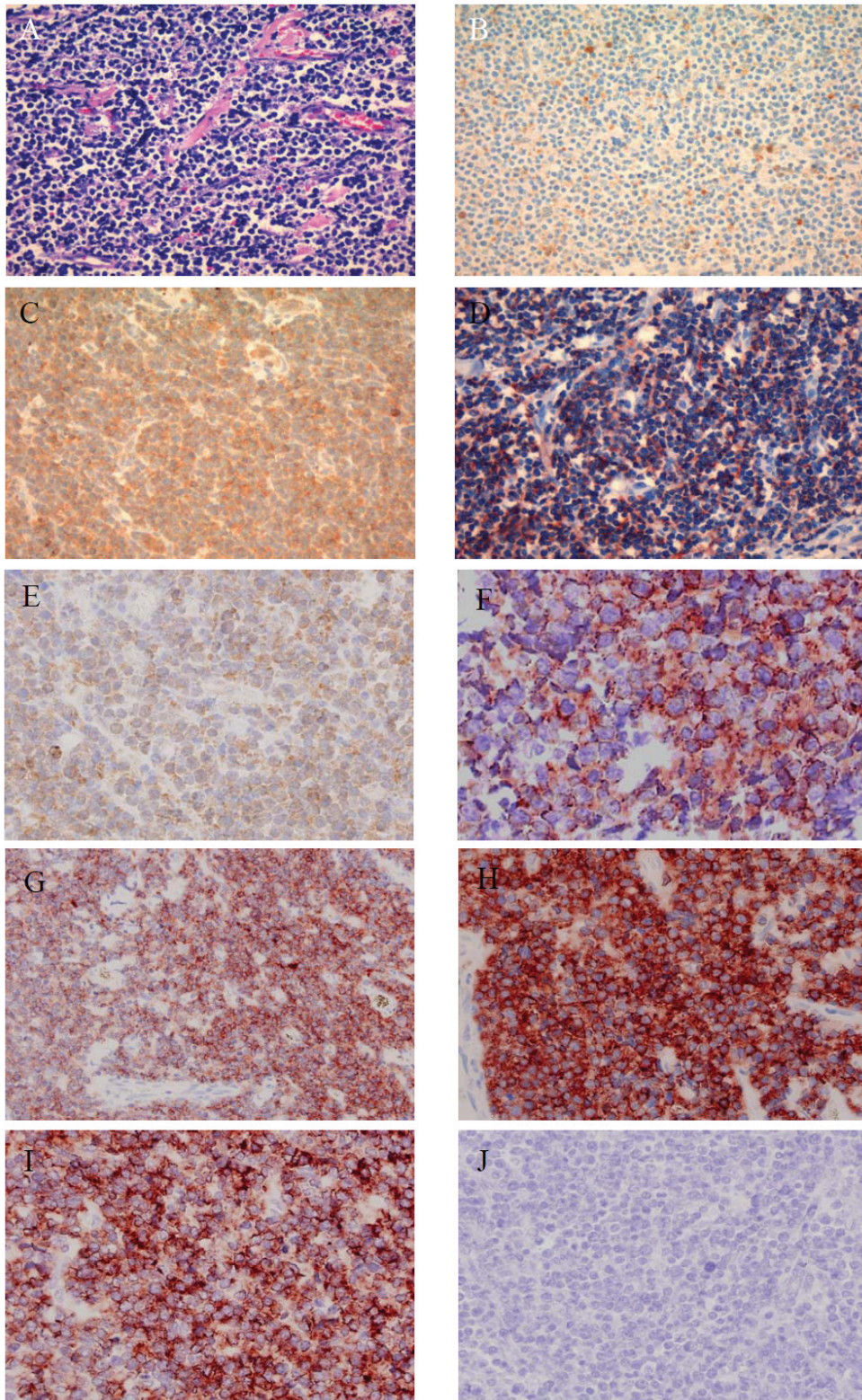
Macroscopically, the specimen removed from the anterior mediastinum was a 7x6x4cm tumor with pseudo capsule. On the cut surface, the tumor was heterogeneous with yellow and white areas. Histologically, the tumor consisted of diffuse and monotonous proliferation of round or polyhedral - shaped lymphoid cells surrounded by a pseudo capsule and abundant necrosis. The chromatin was finely dispersed within the nucleus. Marginally, normal thymus tissue was resected, infiltrated by single tumor cells.

The tumor cells were positive for TdT, cytoplasmic immunoreactivity for CD3 and the cytotoxic effector molecule TIA-1. Granzyme B was negative. Membranous CD3 reactivity was not detectable. Of the typical T cell differentiation markers CD1a, CD4, CD8 and CD10 reacted positively. CD34 as a marker for bipotential B/T-precursors was also positive.

The NK cell markers CD56 and CD2 were positive within the tumor cells, but CD57 and CD16 were all negative, suggesting an immature NK cell phenotype [18]. CD 30 (Ber H2) was negative. The proliferation fraction (MIB-1 index) was about 80%. B cell markers (CD20, CD22, CD79a and IgM) were all negative. No clonal B cell or T cell gamma chain rearrangements were detectable. Epstein Barr virus and other Herpes Virus DNA were not detected using a sensitive PCR assay [15]. Results of the immunohistochemical and PCR assays are summarized in **Table 1** and **Figure 1**.

## Discussion

The anatomical site of the tumor in the anterior mediastinum, the lack of any other tumor foci



**Figure 1:** A) HE (1:200) showing a diffuse and monotonous proliferation of round or polyhedral shaped lymphoid cells. B) TdT (1:200). C) CD3 (1:200) showing a cytoplasmic staining pattern. D) CD8 (1:200). E) TIA-1 (1:400). F) CD-34 (1:200). G) CD-4 (1:200). H) CD-10 (1:400). I) CD-56 (1:400). J) Pan-Cytokeratin (1:400).



## Lymphoblastic T/NK cell lymphoma

**Table 1.** Immunophenotypic results and PCR analysis of lymphoma cells. cCD3: cytoplasmic cCD3, mCD3: membranous CD3

Class of markers	Marker	+/-
Immaturity markers	C-Kit	-
	TdT	+
	cCD3	+
Markers of bipotential precursors	CD34	+
NK cell marker	CD2	+
	CD16	-
	CD56	+
	CD57	-
T cell marker	CD1a	+
	mCD3	-
	CD4	+
	CD5	-
	CD8	+
	CD10	+
	CD30	-
	TCR rearrangement	polyclonal
B cell markers	CD20	-
	CD22	-
	CD30	-
	CD79a	-
	IgM	-
	Ig clonality (CDR 3)	polyclonal
Cytotoxic markers	TIA-1	+
	Granzyme B	-
Epithelial marker	Pan-CK	-
Proliferation index	MIB-1	≥80%
Herpesvirus-PCR		-

and the expression of TdT suggested that it originated from the thymus. Based on this and the histological appearance of the tumor cells resembling lymphoblasts (monomorphic, medium sized cells with high N/C ratio and finely dispersed chromatin) we classified the tumor as LBL. Furthermore, the tumor combined immunophenotypical characteristics of a blastic/immature with a mature lymphoma. The lymphoblasts exhibited a unique set of markers, combining features of the T cell lineage with features of NK cell precursors. The coexpression of CD1a, CD4 and CD8 suggested a T cell precursor similar to the so called early double positive cells (EDP) by the model of Res and

Spits [12], but without demonstrating the rearrangement of the TCR gamma, which is normally present at this stage [19]. TdT, CD3 and CD34 are antigens commonly expressed by cells at an early developmental stage, the antigen CD34 disappears when cells differentiate from bipotential T/NK progenitors to precursors of T or NK cells [13, 20]. Interestingly, the tumor cells in our case still expressed CD34. This suggests that, phenotypically, the lymphoma cells did not fully progress out of the stage of the bipotential T/NK progenitors.

Besides, the neoplastic cells coexpressed NK cell lineage features (CD2, CD56)[21, 22].

Based on these findings, it appears that the lymphoma cells of this case have differentiated towards NK cells, although they were negative for CD16 or CD57. But CD16 and CD57 are not clearly associated with NK-cell precursors according to the model of NK cell development [23]. However, the expression of CD56 is not common in malignant lymphomas and usually identifies a group of lymphomas with distinctive clinicopathologic features. These lymphoma commonly affects middle-aged adults presenting with fever, skin rash, hepatosplenomegaly and an association with EBV infection [24].

Our case did not fit into this group of NK lymphomas due to the following features: (1) the histologic and cytologic appearance was that of a LBL, confirmed by expression of TdT with lymphoblastic morphology, (2) EBV DNA was not (3) azurophilic cytoplasmic granules were not found (4) the phenotype is that of T precursor cells, and (5) the age of the patient.

A possible relationship with a T-cell lymphoma seemed unlikely since a TCR rearrangement, cutaneous lesions or hepatosplenomegaly were not detected. Although cases of LBL with combined T and NK cell features have already been published [25, 26], this case of a thymic lymphoma is unique by combining the features of different developmental stages and lineages as well as the pediatric age of the patient.

We conclude that our case represents a novel pediatric lymphoma derived from a thymic precursor committed to T/NK-cell differentiation with a favourable outcome after postoperative adjuvant chemotherapy.

## Acknowledgements

We thank Irina Berger, M.D. for her contribution. T.G. was supported by a fellowship within the postdoctorate program of the German Cancer Aid. M.R.B. received a NIH grant.

**Please address all correspondences to:** Timo Gaiser, MD, Section of Cancer Genomics, National Cancer Institute, National Institutes of Health, Bethesda, MD, USA, Tel: 001-301-496-6501; Fax: 001-310-435-4428; Email: [timo\\_gaiser@web.de](mailto:timo_gaiser@web.de)

## References

- [1] Sternberg C. Leukosarkomatose und Myeloblastenleukämie. Beitr z Path Anat uz allg

- Path 1916; 61: 75-100.
- [2] Cooke JV. Mediastinal tumor in acute leucemia: a clinical and roentgenologic study. Am J Dis Child 1932; 44: 1153-1177.
- [3] A clinical evaluation of the International Lymphoma Study Group classification of non-Hodgkin's lymphoma. The Non-Hodgkin's Lymphoma Classification Project. Blood 1997; 89: 3909-3918.
- [4] Sheibani K, Nathwani BN, Winberg CD, Burke JS, Swartz WG, Blayney D, van de Velde S, Hill LR and Rappaport H. Antigenically defined subgroups of lymphoblastic lymphoma. Relationship to clinical presentation and biologic behavior. Cancer 1987; 60: 183-190.
- [5] Karube K, Ohshima K, Tsuchiya T, Yamaguchi T, Suefuji H, Suzumiya J, Harada M and Kikuchi M. Non-B, non-T neoplasms with lymphoblast morphology: further clarification and classification. Am J Surg Pathol 2003; 27: 1366-1374.
- [6] Kurtzberg J, Waldmann TA, Davey MP, Bigner SH, Moore JO, Hershfield MS and Haynes BF. CD7+, CD4-, CD8- acute leukemia: a syndrome of malignant pluripotent lymphohematopoietic cells. Blood 1989; 73: 381-390.
- [7] Swerdlow SH, International Agency for Research on Cancer. and World Health Organization. WHO classification of tumours of haematopoietic and lymphoid tissues. Lyon, France: International Agency for Research on Cancer, 2008.
- [8] Suzuki R, Yamamoto K, Seto M, Kagami Y, Ogura M, Yatabe Y, Suchi T, Kodera Y, Morishima Y, Takahashi T, Saito H, Ueda R and Nakamura S. CD7+ and CD56+ myeloid/natural killer cell precursor acute leukemia: a distinct hematolymphoid disease entity. Blood 1997; 90: 2417-2428.
- [9] Petrella T, Comeau MR, Maynadie M, Couillault G, De Muret A, Maliszewski CR, Dalac S, Durlach A and Galibert L. 'Agranular CD4+ CD56+ hematodermic neoplasm' (blastic NK-cell lymphoma) originates from a population of CD56+ precursor cells related to plasmacytoid monocytes. Am J Surg Pathol 2002; 26: 852-862.
- [10] Benlagha K, Wei DG, Veiga J, Teyton L and Bendelac A. Characterization of the early stages of thymic NKT cell development. J Exp Med 2005; 202: 485-492.
- [11] Pear WS, Tu L and Stein PL. Lineage choices in the developing thymus: choosing the T and NKT pathways. Curr Opin Immunol 2004; 16: 167-173.
- [12] Res P and Spits H. Developmental stages in the human thymus. Semin Immunol 1999; 11: 39-46.
- [13] Sanchez MJ, Muench MO, Roncarolo MG, Lanier LL and Phillips JH. Identification of a common T/ natural killer cell progenitor in human fetal thymus. J Exp Med 1994; 180: 569-576.
- [14] Woessmann W, Seidemann K, Mann G, Zimmermann M, Burkhardt B, Oschlies I, Ludwig WD, Klingebiel T, Graf N, Gruhn B, Juergens H,

- Niggli F, Parwaresch R, Gadner H, Riehm H, Schrappe M and Reiter A. The impact of the methotrexate administration schedule and dose in the treatment of children and adolescents with B-cell neoplasms: a report of the BFM Group Study NHL-BFM95. *Blood* 2005; 105: 948-958.
- [15] Tenorio A, Echevarria JE, Casas I, Echevarria JM and Tabares E. Detection and typing of human herpesviruses by multiplex polymerase chain reaction. *J Virol Methods* 1993; 44: 261-269.
- [16] Trainor KJ, Brisco MJ, Wan JH, Neoh S, Grist S and Morley AA. Gene rearrangement in B- and T-lymphoproliferative disease detected by the polymerase chain reaction. *Blood* 1991; 78: 192-196.
- [17] Wang RF, Cao WW and Johnson MG. A simplified, single tube, single buffer system for RNA-PCR. *Biotechniques* 1992; 12: 702, 704.
- [18] Liang X and Graham DK. Natural killer cell neoplasms. *Cancer* 2008; 112: 1425-1436.
- [19] Dik WA, Pike-Overzet K, Weerkamp F, de Ridder D, de Haas EF, Baert MR, van der Spek P, Koster EE, Reinders MJ, van Dongen JJ, Langerak AW and Staal FJ. New insights on human T cell development by quantitative T cell receptor gene rearrangement studies and gene expression profiling. *J Exp Med* 2005; 201: 1715-1723.
- [20] Murphy S and Jaffe ES. Terminal transferase activity and lymphoblastic neoplasms. *N Engl J Med* 1984; 311: 1373-1375.
- [21] Jaffe ES, Krenacs L and Raffeld M. Classification of cytotoxic T-cell and natural killer cell lymphomas. *Semin Hematol* 2003; 40: 175-184.
- [22] Siu LL, Chan JK and Kwong YL. Natural killer cell malignancies: clinicopathologic and molecular features. *Histol Histopathol* 2002; 17: 539-554.
- [23] Lanier LL, Spits H and Phillips JH. The developmental relationship between NK cells and T cells. *Immunol Today* 1992; 13: 392-395.
- [24] Jaffe ES, Krenacs L, Kumar S, Kingma DW and Raffeld M. Extranodal peripheral T-cell and NK-cell neoplasms. *Am J Clin Pathol* 1999; 111: S46-55.
- [25] Ichinohasama R, Endoh K, Ishizawa K, Okuda M, Kameoka J, Meguro K, Myers J, Kadin ME, Mori S and Sawai T. Thymic lymphoblastic lymphoma of committed natural killer cell precursor origin: a case report. *Cancer* 1996; 77: 2592-2603.
- [26] Gloeckner-Hofmann K, Ottesen K, Schmidt S, Nizze H, Feller AC and Merz H. T-cell/natural killer cell lymphoblastic lymphoma with an unusual coexpression of B-cell antigens. *Ann Hematol* 2000; 79: 635-639.