

Original Article

Magnetic resonance imaging investigations of position of conus medullaris in adolescent idiopathic scoliosis as a peripheral neuropathy

Hamid Hesarikia¹, Kamran Azma², Aliasghar Kousari¹, Farshad Nikouei³

¹Department of Orthopedics, Baqiyatallah Hospital, Baqiyatallah University of Medical Sciences, Tehran, Iran;

²Department of Physical Medicine and Rehabilitation, AJA University of Medical Sciences, Tehran, Iran; ³Bone and Joint Reconstruction Research Center, Shafa Orthopedic Hospital, Iran University of Medical Sciences, Tehran, Iran

Received January 31, 2015; Accepted March 31, 2015; Epub April 15, 2015; Published April 30, 2015

Abstract: Adolescent idiopathic scoliosis (AIS) is a structural 3-dimensional deformity the spine, which is occurring between 10 years of age and skeletal maturity and it mostly affects prepubertal girls. The etiology of AIS remains unknown and seems should be multifactorial. According to the theories, there could be a shorter spinal cord or a higher location of the conus medullaris and disproportionate growth in neuro-osseous system. This study wants to investigate the position of the conus medullaris in AIS patients with a large curve magnitude in comparison with healthy adolescents. 94 AIS patients consisting of 25 males and 69 females between 11 and 25 years old, based on physical examination and standing posteroanterior roentgenography of the total spine with a Cobb angle more than 40 degrees was chosen. The main curve magnitude of every AIS patient was measured by the Cobb method. Apex of deformity was determined based on SRS definition. Patients' deformity were calcified based on Lenke classification. Magnetic resonance imaging examinations of the total spine were performed in the AIS group, by means of a 1.5-T magnetic resonance imaging system. The position of conus medullaris was defined according to the method by saffiudin et al and was assessed based on the age, sex, type of deformity, severity of deformity, kyphosis, lordosis, flexibility, apical vertebra, stable vertebra. The mean age of patients were 16.34 with 6.77 of conus medullaris position in mean, which was lower one-third of L1. Our study showed no significant correlation between the position of conus medullaris with age, weight, preoperative curve, flexibility, types of deformity based on Lenke classification and degree of kyphosis and lordosis. In conclusion, there is the same mean and the distribution of the conus medullaris locations for AIS patients and normal populations.

Keywords: Adolescent idiopathic scoliosis, conus medullaris, magnetic resonance imaging, cobb angle, lenke classification, vertebra, spine

Introduction

Scoliosis is defined as a lateral deviation of the spine greater than 10 degrees on a radiograph. Idiopathic scoliosis is defined as structural 3-dimensional deformity of the spine, occurring in an otherwise healthy child, for which no recognizable cause exists. The Scoliosis Research Society recommends that idiopathic scoliosis be classified according to the age of the patient when the diagnosis is made. Adolescent idiopathic scoliosis (AIS), occurs between 10 years of age and skeletal maturity. AIS mostly affects peripubertal girls [1]. The etiology of AIS remains largely unknown [2-5] despite extensive research for decades. Based on the cur-

rent understanding, it is generally acknowledged that the cause of AIS should be multifactorial [6-9], these multiple elements, uncoupled neuro-osseous growth between the spine and the spinal cord was thought to be a potential factor impacting on the development of the AIS [10-13]. According to this theory, there could be a shorter spinal cord or a higher location of the conus medullaris. As a hypothesis in some scholastic patients, there is disproportionate growth in neuro-osseous system. And spine buckling occur into a scoliosis deformity because the longitudinal growth of the spinal cord fails to keep pace with the growth of the vertebral column [10-14].

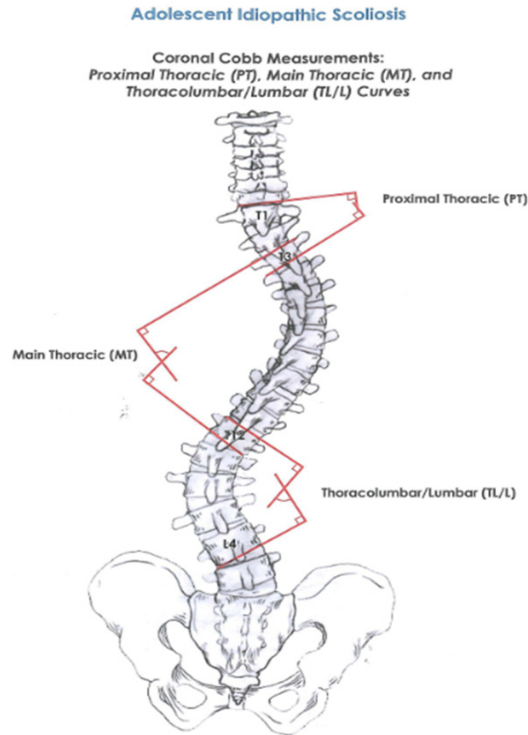


Figure 1. Measurement of scoliosis angle with Cobb method.

Table 1. Main curve location

Location of Apex (SRS Definition)	
Curve	Apex
Thoracic	T2 through the T11-T12 disc
Thoracolumbar	T12 to L1
Lumbar	L1-L2 disc through L4

In the current study, we attempted to investigate the positions of the conus medullaris in AIS patients with a large curve magnitude in comparison with healthy adolescents as published in the literature [15] to explore the relationship of those with patients' age, sex, curve magnitude, and curve pattern.

Previously, there were several studies concerning the conus medullaris locations in healthy populations, And a few Studies in scoliotic patients. Thomson [16] first reported the conus locations in adult cadavers. It was Reimann and Anson [17] who introduced the concept of the vertebra/disk unit to identify the conus position. With the advent of MR imaging, investigation on the conus position in the living population became available.

Methods

Patients

A retrospective radiographic study was performed on 94 AIS patients with a Cobb angle more than 40 degrees who had magnetic resonance (MR) imaging examinations of the spine before receiving surgical interventions at our hospital during the period from October 2012 to January 2013. Diagnosis of AIS was based on physical examination and standing postero-anterior roentgenography of the total spine. There were 94 patients consisting of 25 males and 69 females. All patients were aged between 11 and 25 years (mean 16.34 ± 3 years).

Ethical approval and informed consent from the patients have been obtained.

All patients were neurologically normal on detail clinical examination. Exclusion criteria included history of back injury, weakness or numbness in one or more limbs, urinary incontinence, or nocturnal and any suspected congenital spinal anomaly.

On the following MRI examinations, anyone with positive finding suggesting a cerebral, cerebellar, or spinal disorder or presence of any thickening of the filumterminal or a conus location lower than L3 was also excluded. Therefore, all the subjects included in this study were considered not to have disorders that would affect the position of the conus medullaris.

The main curve magnitude of every AIS patient was measured by the Cobb method (**Figure 1**). For patients with more than one curve in the spine, the magnitude of the largest curve was used as the Cobb angle for the following analyses. Apex of deformity was determined based on SRS definition (**Table 1**). Based on changing in angle at the bending relative to PA radiographs, flexibility of curve was determined. Subsequently, Patients deformity were calcified based on Lenke classification (**Table 2**) [18].

Measurements on MRI images

Magnetic resonance imaging examinations of the total spine were performed in the AIS group, by means of a 1.5-T magnetic resonance imaging system (Sagittal images were taken from the segments of T11-L5 using Turbo spin-echo T1-weighted sequence (recovery time, 400 mil-

Table 2. Curve types and criteria for structural curves and location of apex(18)

Type	Proximal thoracic	Main thoracic	Thoracolumbar/ Lumbar	Curve type
1	Nonstructural	Structural (major)	Nonstructural	Main thoracic (MT)
2	Structural	Structural (major)	Nonstructural	Double thoracic (DT)
3	Nonstructural	Structural (major)	Structural	Double major (MD)
4	Structural	Structural (major)	Structural	Triple major (TM)
5	Nonstructural	Nonstructural	Structural (major)	Thoracolumbar/Lumbar (TL/L)
6	Nonstructural	Structural	Structural (major)	Thoracolumbar/Lumbar structural MT (Lumbar curve > thoracic by > 10)

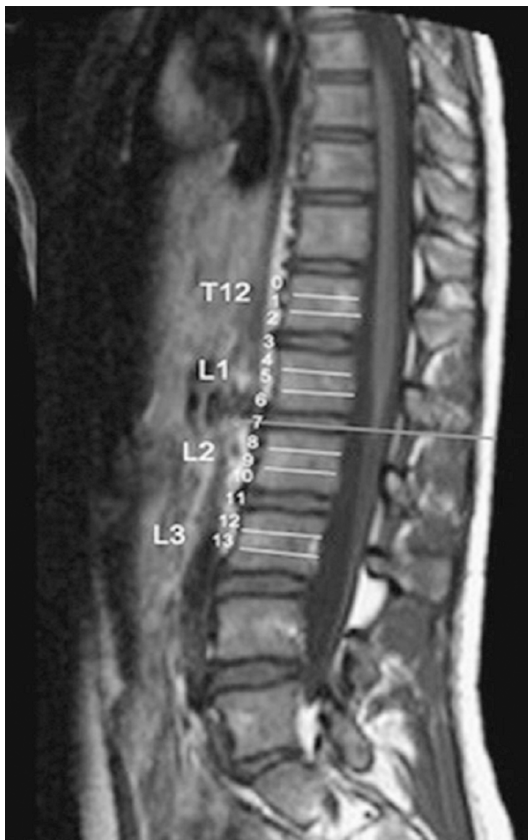


Figure 2. The vertebral body is divided into 3 parts. The disk space is viewed as an independent section. The spinal unit is divided into 4 segments. A straight line perpendicular to the axis of the spinal cord in the median sagittal sequence was subtended to the adjacent vertebra or disk space, and the position was defined in relation to the vertebra or disk space.

liseconds; echo time, 20 nanoseconds) with 3-mm-thick sections and 2.5-mm-thick inter-sectional gaps, which were determined in each subject as part of a routine imaging protocol.

Three images, including the midsagittal and the two adjacent images, were selected for the analyses of the conus positions. Of these three images, the one with the most evident configuration of the conus was selected for further

measurements, and the tip of the conus was defined as the most distal point of the cord that could be visualized. A line perpendicular to the long axis of the cord was then drawn to the adjacent vertebra, and the position was defined in relation to the vertebra. According to the method described by Saifuddin et al [19], each vertebral/disc unit was divided into four segments. The vertebralbody was divided into three equal portions (upper, middle, and lower thirds), and the distal intervertebral disc was defined as a separate region. For the purpose of statistical evaluation, each conus level was assigned a value (C value) such that the middle third of T12 = 1 and the L2-L3 disc space = 11, and a range of 4 was assigned from the top of each vertebral body to the next; thus, the conus position was represented with a C value (**Figure 2**).

Position of conus medullaris was assessed based on the age, sex, type of deformity (Lenke classification), severity of deformity (Cobb angle), kyphosis, lordosis, flexibility, apical vertebra, stable vertebra. Then we assess relationship between position of conus medullaris and other parameters.

Results

Demographic analysis

The primary data are shown on **Tables 3** and **4**. The mean age of the patients was 16.34 years (range, 11 to 25 years) and the mean position of conus medullaris was 6.77 which was lower one-third of L1. Minimum and maximum values was 3 And 12 respectively. In Girls is slightly lower than boys- upper limit of the L1-L2. Of course it is not significant (6.238 ± 1.86 versus $6.93 \pm 2.125/p\text{-value} = 0.362$).

Relation between position of conus medullaris and age

Age of our samples is between 11 and 25. Position of conus medullaris had not relation

Table 3. demographic analysis of patient

	Male	Female	All
Number	21 (22.34%)	73 (77.65%)	94
Age (year)	16.96 ± 3.142	16.12 ± 3.756	16.34 ± 3.606
Weight (Kg)	48.96 ± 10.888	46.14 ± 7.839	
Conus Position	6.93 ± 2.125	6.23 ± 1.868	6.77 ± 0.208

Table 4. Frequency Distribution for conus position (n = 94). Mean conus position = 6.77 (lower third of L1) and SD = (equivalent to half a vertebra)

Conus position	Spinal unit	Frequency
1	Middle third of T12	0
2	Lower third of T12	0
3	T12/L1 disc space	3
4	Upper third of L1	10
5	Middle third of L1	11
6	Lower third of L1	19
7	L1/L2 disc space	11
8	Upper third of L2	31
9	Middle third of L2	3
10	Lower third of L2	2
11	L2/L3 disc space	1
12	Upper third of L3	3

Table 5. Conus (Mean ± SD) relation to Lenke classification

Lenke	Mean ± SD
1	6.83 ± 2.079
2	4.67 ± 2.887
3	7.46 ± 2.064
4	7.20 ± 0.837
5	6.78 ± 1.394
6	6.09 ± 1.375

a: P ≤ 0.05.

with age of this range. There are no differences between age under and above 20.

According to the main curve magnitude, AIS patients were divided into 3 subgroups: 36 patients in group A with a Cobb angle greater than 40 degrees but less than 59 degrees, 42 patients in group B with a Cobb angle greater than 60 degrees but less than 89 degrees, and 15 patients in group C with a Cobb angle greater than 90 degrees. Subsequently, curves were further classified according to the Lenke classification.

Also there is no significant correlation between conus position and type of deformity based of Lenke classification (**Table 5**).

At last, we founded no significant correlation between position of conus medullaris and age, weight, preopera-

tive curve and flexibility of curve in bending films and amount of kyphosis (based on Lenke criteria classified to “-” < 10, “N” = 10-40, “+” > 40). Position of conus had not significant correlation with degree of kyphosis and lordosis.

Discussion

Despite extensive research for decades, the etiology of AIS remains largely unknown [1-5]. Currently, it is generally accepted that the cause of AIS should best be regarded as multifactorial [3-9], including factors such as genetics, growth pattern, neuromuscular abnormalities, and others. Some authors put forward that the factor with the origin of neurological dysfunction or disorder should play an important role in the development of AIS [10, 11, 13]. Porter [10-12] reported that the length of the spinal cord was shorter than that of the vertebral column in scoliotic cadavers and presented the uncoupled neuro-osseous growth theory. Based on this theory, AIS patients could have a shorter spinal cord, or a conus medullaris of a higher location.

In our study mean position of conus medullaris was in lower third of L1. Range from T12-L1 disc space to upper third of L3.

The position of the conus medullaris in a large adult population only previously has been described with the use of cadaveric studies [16, 17, 20, 21]. These studies have shown the level of the conus medullaris to be between T12 and L3. In other studies, the embryologic migration and final position of the conus in children have been described; it has been reported that the conus reaches the adult level by 2 years of age and lies at an average position of L1 to L2 [19].

In an adult population, Saifuddin et al [19] reported the conus positions in 273 females and 231 males by introducing the concept of the vertebra/disk unit to measure the conus position on sagittal MR images. They found that

the range of the conus positions was located from the middle third of T12 to the upper third of L3 and that the mean was located in the lower third of L1. No significant difference in conus position was seen between male and female patients or with increasing age.

Similar findings were reported by Kim et al [22] in 690 healthy adults older than 20 years. A study by Wang et al [23] reported the conus positions in 1199 healthy Chinese subjects in which there were 20 children and adolescents aged younger than 18 years. They showed that the mean conus position was located at the lower third of L1.

Deniz Demiryürek et al [24] in retrospective evaluation of the location of conus medullaris according to age and sex with a 0.5-T MRI in 639 subjects found no significant difference in the conus level with increasing age. The level of conus medullaris was most commonly located at the T12-L1 intervertebral disc level in the whole population. Their results do not correlate with the other studies.

Winnie C. W. et al [25] at 2006 with MRI evaluation of the spine in 28 AIS patients (14 mild curve; 14 severe curve) and 14 age-matched controls. Concluded that there was significantly reduced spinal cord to vertebral column ratios in the AIS patients with severe curve, suggesting a disproportional growth between the skeletal and the neural systems. The relative shortening and functional tethering of spinal cord may play an important role in the etiopathogenesis of AIS.

Li-Feng Lao et al [26] in 2011 published the result of MRI three-dimensional reconstruction of the whole spine in 90 adolescents (49 AIS with thoracic/thoracolumbar curve, and 41 age-matched healthy controls) and evaluation of the ratio of anteroposterior (AP) and transverse (TS) diameter of the cord, the concave and convex lateral cord space (LCS) were obtained at the apical level in AIS patients. Cord length and vertebral column length were not significantly different between AIS and control group. However, cord/vertebral column length ratio was significantly smaller in AIS group ($P < 0.01$). Cord length, vertebral column length and cord/vertebral column length ratio were not related with age or Cobb angle ($P > 0.05$). These data suggest the presence of uncoupled neuro-osseous growth along the longitudinal

axis of spinal cord with associated morphologic changes of cross-sectional configuration and relative position of the cord. Some changes are significantly relevant with Cobb angle, which may indicate pathogenesis of AIS.

Jae-Young Hong, et al [27] with prospective study of 31 patient with AIS demonstrated the conus medullaris level changed postoperatively in the patients with severe scoliosis. Overall, the postoperative degree of correction of the coronal curve was higher in the change group than that in the non-change group. The degrees of correction of the coronal curve and lumbar lordosis were related to the spinal cord level change after scoliosis correction.

Xu Sun, et al [15] in 2008 investigated the positions of the conus medullaris of 240 AIS patients with a Cobb angle greater than 40 degrees, as compared with age-matched controls, through measurements on sagittal MR images. In AIS patients, the positions and the position distributions of the conus were not found to be significantly different from those of age-matched controls. In both AIS and control adolescents, no significant associations of the conus positions either with age or with sex were found. Furthermore, neither the curve magnitude nor the curve patterns in AIS patients were found to be significantly associated with the conus positions as well as the position distributions. The results of their study demonstrated that AIS patients do not have a conus with a higher location when compared with age-matched controls. Taken together, these findings provide lots of evidence regarding the conus positions in AIS patients, which suggests that the conus positions might not be involved in the development and progression of AIS.

Wang et al [23] and Xu Sun [15], reported that the mean conus position was located at the lower third of L1 not only in AIS patients but also in the age-matched adolescents. Furthermore, no significant association was found between the age and the conus position. Grounded on the natural growth and development of the spinal cord and based on the above previous findings in adult populations, it is inferred that the relative position of the conus might be invariable through adolescence to adulthood. In study of Wang et al [23] the age of the control group was not matched with the AIS group.

The effect of sex on the conus position remains controversial, although lots of attentions have been paid.

In cadaveric studies, Thomson [16] and Needles [21] found that the conus location was significantly lower in females than in males. Similar findings were reported by Kim et al [22] and Wang et al [23] in studies with measurements on MR images. However, Saifuddin et al [19] reported that there was no significant difference regarding the conus positions in both sexes. The Xu Sun study [15] could not detect significant difference between girls and boys in both groups. It is thus implied that the conus locations were not significantly associated with sex in both scoliosis and nonscoliosis adolescents.

In our study conus locations is lower in Girls rather than boys slightly. Of course it is not significant (6.238 ± 1.86 versus 6.93 ± 2.125).

Soleiman, Joseph et al. concluded mean conus-medullaris termination was at the level of the middle third of L1. The range span extended from the lower third of Th11 to the upper third of L3 [28]. In their study the conus medullaris termination displayed a small but significant positive correlation with age and with gender.

DA Wilson and Prince JR [29] The range for was T12 to L2-L3 with an average of L1-L2. The range and average of conus levels for the 0-2-year-old group and 19-20-year-old group are the same (L1-L2). They concludes that the conus medullaris does not ascend throughout childhood as stated by previous authors but attains the adult level sometime during the first few months of life. A conus level at L2-L3 or above should be considered normal at any age. A conus level at L3 is indeterminate, since it is possible for normal or tethered conus to be located at this level.

In our study conus position was lower in females than males, although this difference was not statistically significant and no difference between ages from 11 to 25 was detected.

In conclusion, our study demonstrated that the distribution of the conus locations in AIS patients was similar to normal populations that were published in literature. No significant associations were found between the conus position and age, sex, kyphosis, lordosis and

severity of curve (Cobb angle) Xu Sun, et al [15] demonstrated no significant associations between the conus position and age between conus position and sex, in both scoliosis and non-scoliosis adolescents. But our study demonstrated slightly lower position of conus medullaris in female sex. That is not significant.

In our study according to Xu Sun [15] study, neither curve severity nor curve patterns were found to be significantly associated with the conus position. These findings indicate that the conus location might not be involved in the pathogenesis and curve progression of AIS.

Our study demonstrated significant correlation between conus position and stable vertebra, apical vertebra.

In conclusion, the mean and the distribution of the conus locations were similar for AIS patients (based on our study) and normal population (based on other studies in literatures). No significant associations of the conus position with curve severity and with curve patterns were found, indicating that the conus location might not be involved in the pathogenesis and curve progression of AIS.

Acknowledgements

This study was supported in part by the Bone and Joint Reconstruction Research Center Iran University of Medical Sciences, Tehran, IR Iran (grant no. 13-04-01718a).

Disclosure of conflict of interest

None.

Address correspondence to: Farshad Nikouei, Bone and Joint Reconstruction Research Center, Shafa Orthopedic Hospital, Iran University of Medical Sciences, Tehran, IR Iran. Tel: +98-2133542000; Fax: +98-2133542020; E-mail: farshadnikouei@yahoo.com

References

- [1] Beaty JH, Canale ST, Campbell WC. Campbell's Operative Orthopaedics. 11th edition. Philadelphia, PA: Mosby/Elsevier; pp. 1928.
- [2] Justice CM, Miller NH, Marosy B, Zhang J, Wilson AF. Familial idiopathic scoliosis: evidence of an X-linked susceptibility locus. Spine 2003; 28: 589-94.

- [3] Qiu Y, Sun X, Qiu X, Li W, Zhu Z, Zhu F, Wang B, Yu Y, Qian B. Decreased circulating leptin level and its association with body and bone mass in girls with adolescent idiopathic scoliosis. *Spine* 2007; 32: 2703-10.
- [4] Qiu Y, Zhu L, Song Z. Clinical etiological classification of scoliosis. *Chinese Journal of Orthopedics* 2000; 20: 265-8.
- [5] Weinstein SL, Dolan LA, Cheng JC, Danielsson A, Morcuende JA. Adolescent idiopathic scoliosis. *Lancet* 2008; 371: 1527-37.
- [6] Ahn UM, Ahn NU, Nallamshetty L, Buchowski JM, Rose PS, Miller NH, Kostuik JP, Sponseller PD. The etiology of adolescent idiopathic scoliosis. *Am J Orthop (Belle Mead NJ)* 2002; 31: 387-95.
- [7] Burwell RG. Aetiology of idiopathic scoliosis: current concepts. *Pediatr Rehabil* 2003; 6: 137-70.
- [8] Dickson R. The etiology and pathogenesis of idiopathic scoliosis. *Acta Orthopaedica Belgica* 1991; 58: 21-5.
- [9] Zhu F, Qiu Y, Yeung HY, Lee KM, Cheng JC. Histomorphometric study of the spinal growth plates in idiopathic scoliosis and congenital scoliosis. *Pediatr Int* 2006; 48: 591-8.
- [10] Porter RW. Idiopathic scoliosis: the relation between the vertebral canal and the vertebral bodies. *Spine* 2000; 25: 1360-6.
- [11] Porter RW. The pathogenesis of idiopathic scoliosis: uncoupled neuro-osseous growth? *Eur Spine J* 2001; 10: 473-81.
- [12] Porter RW. Can a short spinal cord produce scoliosis? *Eur Spine J* 2001; 10: 2-9.
- [13] Roth M. Idiopathic scoliosis caused by a short spinal cord. *Acta Radiol Diagn (Stockh)* 1968; 7: 257.
- [14] Porter R, Hall-Craggs M, Walker A, Ursu T, Edgar M. The position of the cerebellar tonsils and the conus in patients with scoliosis. *J Bone Joint Surg Br* 2000; 82Suppl iii: 286.
- [15] Sun X, Chu WC, Cheng JC, Zhu F, Zhu Z, Yu Y, Wang B, Qiu Y. Do adolescents with a severe idiopathic scoliosis have higher locations of the conus medullaris than healthy adolescents? *J Pediatr Orthop* 2008; 28: 669-73.
- [16] Thomson A. Fifth annual report of the committee of collective investigation of the Anatomical Society of Great Britain and Ireland for the year 1893-94. *J Anat physiol* 1894; 29: 35.
- [17] Reimann AF, Anson BJ. Vertebral level of termination of the spinal cord with report of a case of sacral cord. *The Anatomical Record* 1944; 88: 127-38.
- [18] Lenke LG, Betz RR, Harms J, Bridwell KH, Clements DH, Lowe TG, Blanke K. Adolescent idiopathic scoliosis a new classification to determine extent of spinal arthrodesis. *J Bone Joint SurgAm* 2001; 83: 1169-81.
- [19] Saifuddin A, Burnett SJ, White J. The variation of position of the conus medullaris in an adult population: a magnetic resonance imaging study. *Spine* 1998; 23: 1452-6.
- [20] McCotter RE. Regarding the length and extent of the human medulla spinalis. *The Anatomical Record* 1916; 10: 559-64.
- [21] Needles JH. The caudal level of termination of the spinal cord in American whites and American negroes. *The Anatomical Record* 1935; 63: 417-24.
- [22] Kim JT, Bahk JH, Sung J. Influence of age and sex on the position of the conus medullaris and Tuffier's line in adults. *Anesthesiology* 2003; 99: 1359-63.
- [23] Wang G, Wang K, Jiang L. MR imaging of the variation in position of the tip of the conus medullaris in the Chinese population. *Chin J Med Imaging Technol* 2003; 19: 1193-4.
- [24] Demiryürek D, Aydingöz Ü, Akşit MD, Yener N, Geyik PÖ. MR imaging determination of the normal level of conus medullaris. *Clin Imaging* 2002; 26: 375-7.
- [25] Chu WC, Lam WW, Chan YL, Ng BK, Lam TP, Lee KM, Guo X, Cheng JC. Relative shortening and functional tethering of spinal cord in adolescent idiopathic scoliosis?: study with multiplanar reformat magnetic resonance imaging and somatosensory evoked potential. *Spine* 2006; 31: E19-E25.
- [26] Lao LF, Shen JX, Chen ZG, Wang YP, Wen XS, Qiu GX. Uncoupled neuro-osseous growth in adolescent idiopathic scoliosis? A preliminary study of 90 adolescents with whole-spine three-dimensional magnetic resonance imaging. *Eur Spine J* 2011; 20: 1081-6.
- [27] Hong JY, Suh SW, Park JH, Hur CY, Hong SJ, Modi HN. Changes in level of the conus after corrective surgery for scoliosis: MRI-based preliminary study in 31 patients. *Clin Orthop Surg* 2011; 3: 24-33.
- [28] Soleiman J, Demaerel P, Rocher S, Maes F, Marchal G. Magnetic resonance imaging study of the level of termination of the conus medullaris and the thecal sac: influence of age and gender. *Spine* 2005; 30: 1875-80.
- [29] Wilson DA, Prince JR. MR imaging determination of the location of the normal conus medullaris throughout childhood. *AJR Am J Neuroradiol* 1989; 10: 259-6.