

Case Report

Osteochondroma of bilateral mandibular condyle: a case report

Qin Zhou, Chi Yang, Min-Jie Chen

Department of Oral and Maxillofacial Surgery, Ninth People's Hospital, Shanghai Jiao Tong University School of Medicine, Shanghai Key Laboratory of Stomatology, Shanghai 200011

Received December 2, 2014; Accepted January 29, 2015; Epub February 15, 2015; Published February 28, 2015

Abstract: Osteochondroma represents the largest group of benign tumors of bone, which usually develops in long bones and relatively uncommon in the craniofacial region. The condyle and coronoid tip are the most common sites of occurrence in the mandible, but both sides of condyle involved has never been reported. Here, we describe a case of osteochondroma arising from the bilateral mandibular condyle.

Keywords: Osteochondroma, multiple osteochondroma, bilateral condyle

Introduction

Osteochondroma (OC) is the most common bone tumor, which constitutes 20%-50% of all benign bone tumors and 10%-15% of all bone tumors [1]. It usually appears near the growth plate at the ends of long bones, only about 1% of these occur within the head and neck region [2]. They can occur as solitary or multiple lesions, the latter is seen in multiple osteochondromas syndrome (MO), previously known as hereditary multiple exostoses (HME) [3, 4]. In the majority of MO patients, a positive family history and/or mutation in one of the EXT genes can be detected [3, 5]. As MO presented, they are usually seen in long bones. Here, we report a unique case of osteochondroma concurrent with bilateral condyle. To our knowledge, this is the first one to be reported in the temporomandibular joint (TMJ).

Case report

A 61-year-old woman was referred with pain in the right preauricular region and restricted mouth opening about 1 years' duration. On examination of the facial region, a painful bony hard swelling was found on the right preauricular region with slight right lateral deviation of the chin and deep overbite in anterior teeth. The maximum mouth opening was 25 mm with clicking of the right TMJ. CT scan showed the bony dense protuberance with a stalk of antero-lateral part of right condyle. Meanwhile, we

were surprised to note that the similar hyperintense occurred in anteromedial aspect of left condyle (**Figure 1**). MRI displayed normal disc-condyle relationship of both side. Detailed case history revealed no other family members to have similar bony outgrowths. The rest of the body examination was unremarkable. Based on the clinical and radiographic findings, the initial diagnosis of bilateral mandibular condylar OC was made.

Simultaneous excision of both tumors was done via a preauricular incision to the joint under general anesthesia. The inferior compartment was opened and the stalk of the mass was cut with a motor saw (**Figure 2**). The tumors measured 1 cm × 1.5 cm (right) and 1.2 cm × 1 cm (left) respectively. Histopathologic examination of the resected specimen revealed a thickened cartilaginous cap with irregular arrangement of collagen fibers over the mass and islands of subchondral ossification (**Figure 3**), thereby confirming the diagnosis of osteochondroma. The patient demonstrated pain relief and maximum mouth opening was 35 mm 1.5 years after operation. CT revealed no recurrence (**Figure 4**).

Discussion

WHO 2002 defined OC as a cartilage capped bony projection arising from the external surface of bone containing a marrow cavity that is

Osteochondroma of bilateral mandibular condyle

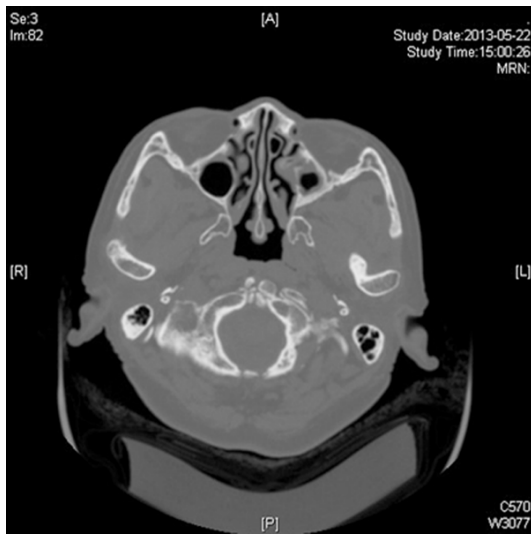


Figure 1. Preoperative CT scans. Axial CT scan showing the bony masses arising from the both sides of condylar surface (arrow).

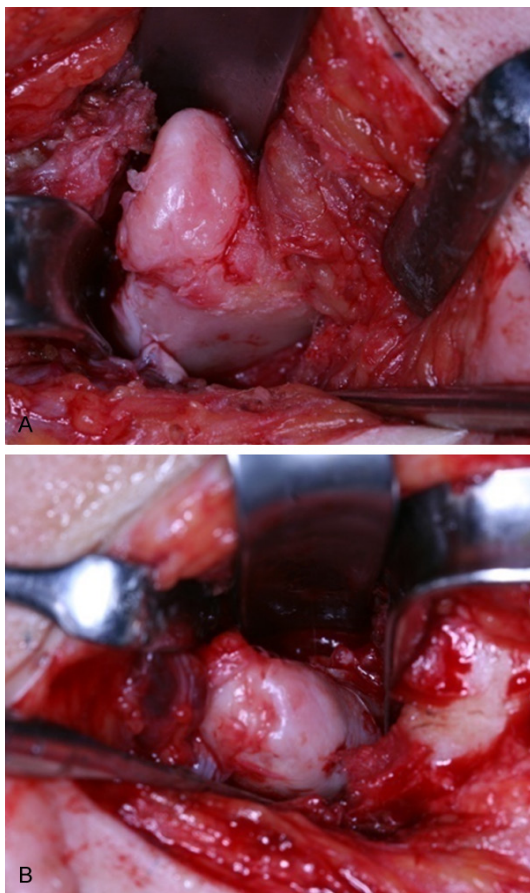


Figure 2. Intraoperative view of the tumors. A: Right side. B: Left side.

continuous with that of the underlying bone [6]. More often the patient is a young adult (10-30

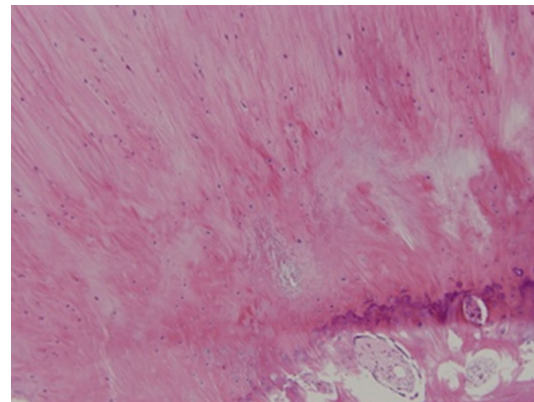


Figure 3. Microscopic view showing trabecular bone covered with a cartilaginous cap of irregular collagen fibers (He ×200).

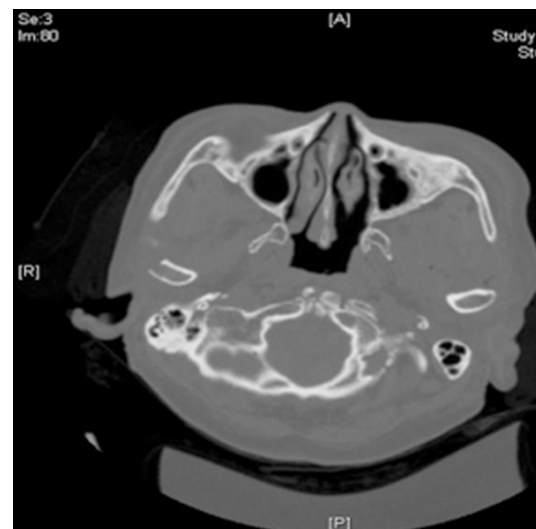


Figure 4. Postoperative CT examination showing no recurrence.

years old) and no sex predilection [6]. Approximately 15% of patients with osteochondromas have multiple lesions [7]. The metaphyseal region of the long bones is the most common site of the involvement, also seen at flat bones, such as ileum and scapula, too. This rare incidence of the jaws usually occurs at the unilateral condyle or coronoid process. Roychoudhury et al [8] reported that at least 108 cases of mandibular condylar osteochondroma had been reported until 2011 in the English literatures. Through reviewing literature, we found that about 215 cases of mandibular condylar osteochondroma have been reported. HME complicated with OC of craniofacial region has been reported. For example, Ruiz et al [9] reported a HME case of coronoid osteochondroma associated with occipital exostosis;

Navaneetham et al [10] reported a patient of the mandibular symphysis OC conjunction with the distal femur. While MO only occurred in maxillofacial region has not been reported.

According to the growing pattern, OC usually manifests as 2 types: lesions with a stalk or those with sessile base. Several surgical approaches have been suggested for the treatment of condylar OC, including complete resection of the tumor using condylectomy with or without reconstruction or selected tumor removal without condylectomy [11]. The good results of local resection for exostosis OC have been verified [12-18]. The tumor margin could be marked more accurate and the lesion could be resected more completely through computer assisted design (CAD) technique [19]. In the present case, the authors removed only masses. The resolution of the facial asymmetry and dental malocclusion was obtained. The follow-up examination at 18 months revealed no clinical or radiological sign of recurrence.

This is the first case of multiple osteochondroma of the bilateral condyle reported in the literature. The outcomes of treatment and prognosis are good after local resection.

Disclosure of conflict of interest

None.

Address correspondence to: Chi Yang or Min-Jie Chen, Department of Oral and Maxillofacial Surgery, Ninth People's Hospital, Shanghai Jiao Tong University School of Medicine, Shanghai Key Laboratory of Stomatology, NO. 639 Zhi zao ju Road, Shanghai 200011. Tel: +86-21-23271699-5218; +86-21-23271699-5705; Fax: +86-21-63135412; E-mail: yangchi63@hotmail.com (CY); chenminjie00@126.com (MJC)

References

- [1] Karras SC, Wolford LM, Cottrell DA. Concurrent osteochondroma of the mandible condyle and ipsilateral cranial base resulting in TMJ ankylosis. Report of a case and review of the literature. *J Oral Maxillofac Surg* 1996; 54: 640-646.
- [2] Samir K, El-Mofty. *Diagnostic Surgical Pathology of the Head and Neck*. 2nd edition. Philadelphia, Pa, USA: Saunders; 2009.
- [3] Bovée JV, Hogendoorn PC. Multiple osteochondromas. In: Fletcher CD, Unni KK and Mertens F, editors. *World Health Organization Classification of Tumours. Pathology and Genetics of Tumours of Soft Tissue and Bone*. Lyon; 2002. pp. 360-362.
- [4] Bovée JV. Multiple osteochondromas. *Orphanet J Rare Dis* 2008; 13: 3-3.
- [5] Legeai-Mallet L, Munnich A, Maroteaux P, Le Merrer M. Incomplete penetrance and expressivity skewing in hereditary multiple exostoses. *Clin Genet* 1997; 52: 12-16.
- [6] Khurana J, Abdul-Karim F, Bovée JV. Osteochondroma. In: Fletcher CDM, Unni KK, Mertens F, editors. *World Health Organization Classification of Tumours. Pathology and Genetics of Tumours of Soft Tissue and Bone*. Lyon: IARC Press; 2002. pp. 234-236.
- [7] Hameetman L, Bovée JV, Taminiau AH, Kroon HM, Hogendoorn PC. Multiple osteochondromas: clinicopathological and genetic spectrum and suggestions for clinical management. *Hered Cancer in Clin Pract* 2004; 2: 161-173.
- [8] Roychoudhury A, Bhatt K, Yadav R, Bhutia O, Roychoudhury S. Review of osteochondroma of mandibular condyle and report of a case series. *J Oral Maxillofac Surg* 2011; 69: 2815-2823.
- [9] Ruiz LP, Lara JC. Craniomaxillofacial features in hereditary multiple exostosis. *J Craniofac Surg* 2012; 23: 336-338.
- [10] Navaneetham A, Rao KA, Kumaran S, Baweja HH. A unique case of multiple osteochondroma: Mandibular symphysis and femur. *Ann Maxillofac Surg* 2012; 2: 182-184.
- [11] Karras SC, Wolford LM, Cottrell DA. Concurrent osteochondroma of the mandibular condyle and ipsilateral cranial base resulting in temporomandibular joint ankylosis: report of a case and review of the literature. *Oral Maxillofac Surg* 1996; 54: 640-646.
- [12] Chen MJ, Yang C, Qiu YT, He DM, Zhou Q, Huang D, Shi HM. Local resection of the mass to treat the osteochondroma of the mandibular condyle: Indications and different methods with 38-case series. *Head Neck* 2014; 36: 273-279.
- [13] Wolford LM, Mehra P, Franco P. Discussion: use of conservative condylectomy for treatment of osteochondroma of the mandible condyle. *J Oral Maxillofac Surg* 2002; 60: 262-268.
- [14] Lizuka T, Schroth G, Laeng RH, Lädach K. Osteochondroma of the mandibular condyle: report of a case. *J Oral Maxillofac Surg* 1996; 54: 495-501.
- [15] Koole R, Steenks MH, Witkamp TD, Slootweg PJ, Shaefer J. Osteochondroma of the mandibular condyle. A case report. *Int J Oral Maxillofac Surg* 1996; 25: 203-205.

Osteochondroma of bilateral mandibular condyle

- [16] Rivera H, Bastidas R, Acevedo AM. A conservative surgical approach of osteochondroma affecting the mandibular condyle. *Invest Clin* 1998; 39: 117-124.
- [17] Kurita K, Ogi N, Echiverre NV. Osteochondroma of the mandibular condyle: a case report. *Int J Oral Maxillofac Surg* 1999; 28: 380-382.
- [18] Aydın MA, Küçükçelebi A, Sayilkan S, Celebioğlu S. Osteochondroma of the mandibular condyle: report of 2 cases treated with conservative surgery. *J Oral Maxillofac Surg* 2001; 59: 1082-1089.
- [19] Huang D, He DM, Yang C, Chen MJ, Zhou Q, Dong MJ. Computer-assisted local resection for exostosis osteochondroma of the mandibular condyle. *J Craniofac Surg* 2013; 24: 446-449.