

Original Article

Embolization of cavernous sinus dural arteriovenous fistula via inferior petrosal sinus: anatomical basis and management practicability

Yunyan Wang¹, Bin Du², Jian Zhang³, Xueen Li¹, Qinglin Liu¹, Gang Li¹

¹Department of Neurosurgery, Qi Lu Hospital, Shandong University, Jinan 250012, P.R. China; ²Department of Neurosurgery, Jinan Central Hospital Affiliated to Shandong University, Jinan 250013, P.R. China; ³Department of Neurosurgery, Dezhou People's Hospital, Dezhou 253014, P.R. China

Received July 30, 2014; Accepted August 16, 2014; Epub September 15, 2014; Published September 30, 2014

Abstract: The aim of this study is to explore anatomical basis and reevaluate the practicability of embolization of cavernous sinus dural arteriovenous fistulas (CSdAVFs) via the inferior petrosal sinus (IPS) with detachable coils and Onyx-18. In this study, retrospective studies were performed on 15 consecutive patients with CSdAVFs via the IPS treated by Onyx-18 and detachable coils in Qilu hospital between March 2009 and January 2013. One patient was treated with Onyx-18 only and others were treated by Onyx-18 combined with coils. The median follow-up time was 30 months, ranged from 16 to 54 months. The results indicated that all patients experienced clinical relief. The patient treated with Onyx-18 only acquired incomplete embolization and then carotid compression was continued for 1 week. The other 14 patients treated by Onyx-18 combined with coils got the complete embolization. Complications were encountered in 8 patients, including reflex bradycardia (40%, n=6), cranial nerve III palsy aggravation (6.6%, n=1) and postoperative headache (6.6%, n=1). No patients had recurrent symptoms during the follow-up period. In conclusion, combined with coils, Onyx-18 can enter the "culprit chambers" of the CS and occlude the fistula. Embolization via the opacified or nonopacified IPS was practicable and safe enough. The approach also can improve cure rates and reduce medical expenses.

Keywords: Cavernous sinus, dural arteriovenous fistula, inferior petrosal sinus, therapeutic embolization

Introduction

Intracranial dural arteriovenous fistulas comprise 10%-15% of all intracranial arteriovenous malformations [1]. Symptoms of CSdAVFs associated with hemorrhage, neurologic deficits embody severe headache, proptosis, chemosis, bruits, diplopia and even loss of visual acuity. CSdAVFs can be managed by carotid compression, endovascular intervention, surgery, radiosurgery or a combination of multidisciplinary approaches [2, 3].

Our series report our institutional experience of 15 consecutive patients with CSdAVFs treated by Onyx-18 (MRI-EV3, Irvine, CA, USA) and detachable coils. Their characteristics will be discussed in the context of a literature review regarding anatomical considerations, endovascular treatment and complication avoidance.

Materials and methods

Subjects

Retrospectively, we reviewed 15 consecutive patients with CSdAVFs treated by embolization via the IPS in Qilu Hospital of Shandong University (Jinan, China) from March 2009 to January 2013. In all patients (8 females and 7 males), aged from 30 to 73 years (mean, 52 years), CSdAVFs were confirmed by digital subtraction angiography and classified according to the categorization proposed by Borden et al [4]. The median follow-up time was 30 months ranging from 16 to 54 month. The patients' characteristics were shown on **Table 1**.

Operation procedure (Figure 1)

During the operation after general anesthesia, one 5F guiding catheter (125 cm) was navigat-

CSdAVFs via IPS for reevaluation of management practicability

Table 1. Characteristics of the 15 patients with CSdAVFs

Patient No.	Age (yr)/ Sex	Type/Side	Feeders	Sypt.	Types of Coils	Volume of Onyx (ml)	Follow-up time (m)	Opa. of the IPS
1	38/M	II/Rt.	Rt-ICA	Chemosis Bruits Rt. CNIII VI palsy	Microplex Hydrocoil Helix	0.3	54	+
2	43/M	I/Rt.	Rt-ICA	Chemosis Bruits Blurred vision	Microplex Morpheux Helix	1.5	50	+
3	30/M	I/Rt.	Rt-ICA	Chemosis Bruits CNVI palsy	Helix	4.5	44	+
4	44/F	II/Rt.	Rt-ICA	Bilat. Chemosis Bruits Rt. CNVI palsy Lt. CNIII palsy Blured vision	Helix	4.5	42	+
5	47/F	I/Rt.	Rt-ICA	Chemosis Bruits	Hydrocoil Axiom	1.5	37	
6	36/M	I/Rt.	Bilat-ICA	Chemosis Rt. CNVI palsy Blured vision	-	1.5	36	
7	72/F	I/Lt.	Bilat-ICA	Lt. CNIII palsy Headache Vomitting	Complex	3.0	27	+
8	54/F	I/Rt.	Bilat-ICA	Chemosis	Complex	1.6	27	
9	72/F	I/Rt.	Rt-ICA Bilat-ECA	Chemosis Bruits	Helix	2.7	24	
10	65/M	I/Rt.	Bilat-ECA	Chemosis Bruits Rt. CNVI palsy	Axiom	2.4	23	+
11	73/M	I/Rt.	Rt-ICA Rt-ECA	Chemosis Bruits	Helix	1.7	21	
12	56/F	I/Rt.	Bilat-ICA Bilat-ECA	Chemosis Bruits	Axiom	3.6	19	+
13	52/M	I/Lt.	Lt-ICA	Chemosis Bruits Rt. CNVI palsy	Axiom	1.4	18	+
14	31/F	I/Lt.	Bilat-ICA Bilat-ECA	Lt. CNIII palsy Chemosis Bruits Blurred vision	Axiom	3.5	18	+
15	62/F	I/Rt.	Bilat-ICA Bilat-ECA	Chemosis Lt. CNIII palsy	Axiom	2.1	16	+

Yr: years, Sypt.: symptoms, ml: milliliter, m: month, Embli.: embolization, F: female, M: male, Rt.: right, Lt.: left, Bilat.: bilateral, -: lost, CNIII: the oculomotor nerve, CNVI: the abducent nerve, CCA: the common carotid artery, ECA: the external carotid artery, Opa.: opacification; +: existence.

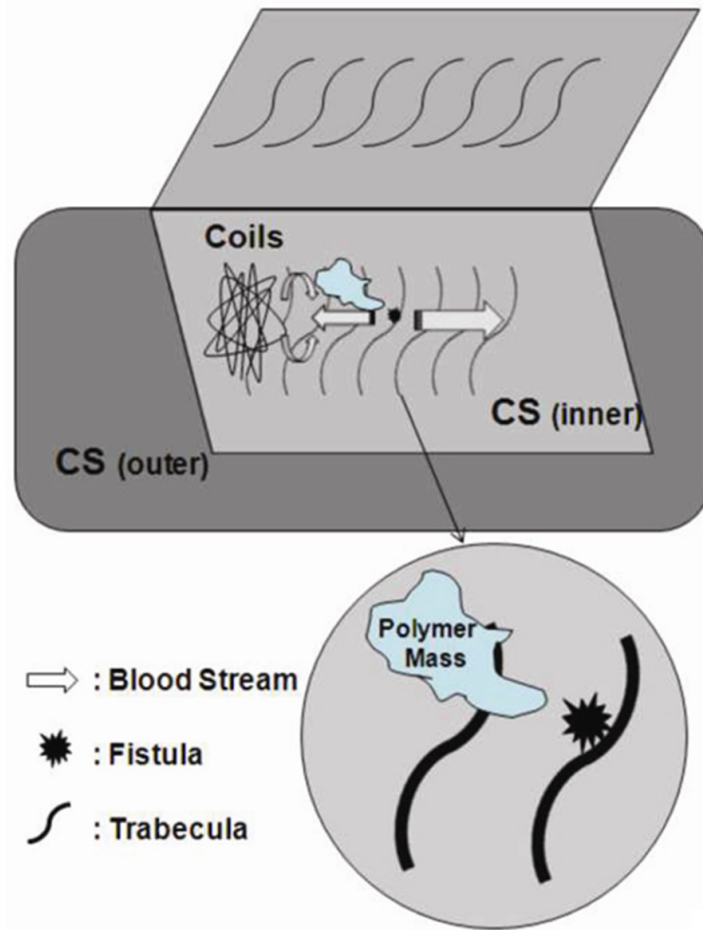


Figure 1. Drawing shows the procedure of embolization of CSdAVFs with coils and Onyx-18.

ed to the internal jugular vein via femoral vein and another 5F guiding catheter was positioned in carotid artery. Then the microcatheter (Echelon 10/14, Micro Therapeutics) with the microwire (PT2, Boston, MA, US) was navigated coaxially to the CS via the IPS. One patient was treated with Onyx-18 only and others were treated by Onyx-18 combined with coils. As the fistulas were almost completely disappeared, angiography was performed immediately after every 0.1 ml Onyx-18, aimed at decreasing the dosage of Onyx-18 and complication rates. As slowly withdrawing the microcatheter in the middle and posterior part of cavernous sinus, it was essential to confirm that the coils and polymer mass were not moved on angiography. If the fistula reoccurred, Onyx-18 would be injected slowly until complete occlusion of the fistula. At the same time, the position of the guiding catheter should be under surveillance to avoid

its head sliding upward to puncture the IPS or internal jugular vein due to the tension of microcatheter adhesive to the polymer mass.

Illustrative cases

Patient 6 (Figure 2): A 36-year-old male, with no history of head trauma or surgical operation, presented with slowly progressing left eye swelling and chemosis during a forty-day period. The patient was admitted to our department for one week of visual deterioration. On admission, the left partial abducent nerve palsy was identified and computed tomographic (CT) scan revealed enlargement of the left superior ophthalmic vein (SOV). Left internal carotid artery (ICA) angiography showed abnormal early drainage into the cavernous sinus. An Echelon 14 microcatheter was positioned in the anterior part of the cavernous sinus. The patient treated with Onyx-18 of 1.5 ml only acquired incomplete embolization and then carotid compression was continued for 1 week. Postprocedural neurologic examination two months later showed marked improvement in visual acuity and ocular

movement. No recurrence occurred by following-up of 36 months.

Patient 8 (Figure 3): A 54-year-old female developed progressively the right eye swelling and chemosis during a 6-month period. The patient also appeared visual deterioration and orbital tenderness ten days later. Physical examination showed proptosis and conjunctive chemosis on the right eye and extraocular movements were intact. CT scan revealed the enlargement of the right SOV. Angiography showed a dural carotid cavernous fistula (CCF) fed by bilateral branches of the CS ICA. An Echelon 10 microcatheter was positioned in proximal aspect of SOV. Complex (Micro Vention, Calif.) coils of an 8 mm × 20 cm, a 7 mm × 18 cm, two 5 mm × 12 cm were deployed into the proximal right SOV and the anterior part of the cavernous sinus. The tip of the

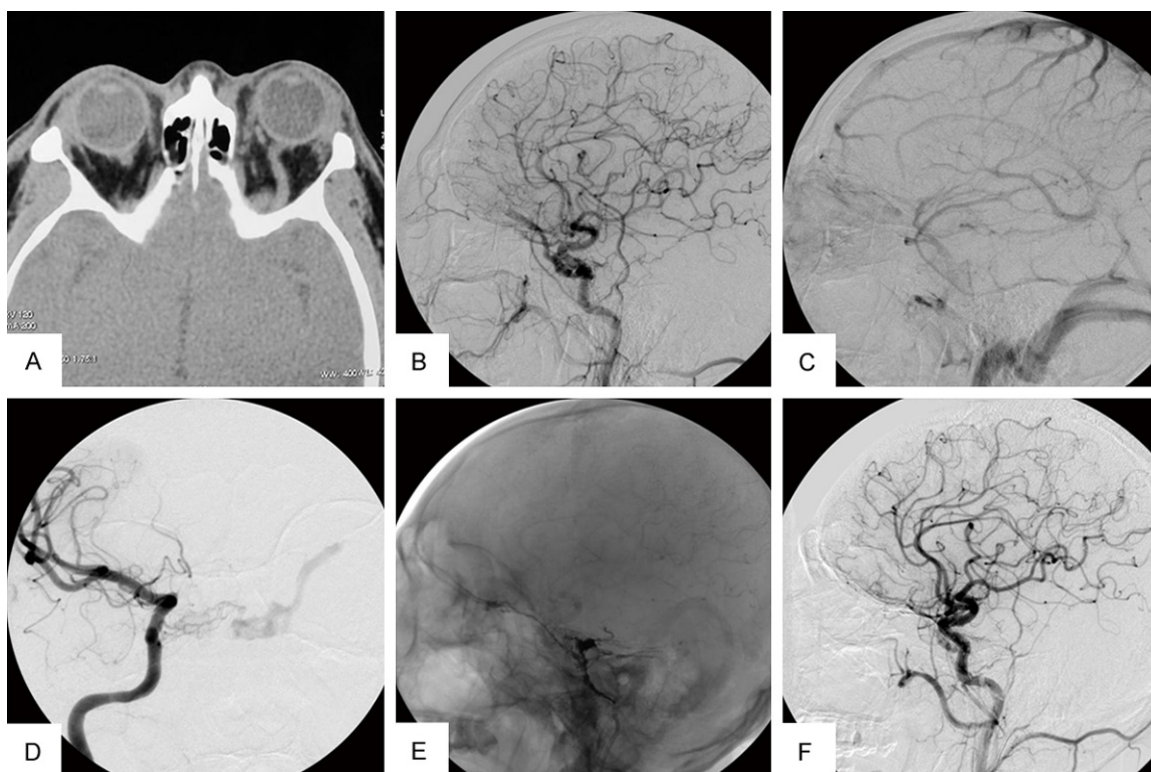


Figure 2. A. Computed tomographic scan of patient 6 shows the enlargement of the left SOV (arrowhead); B and C. Pre-embolization: Lateral projection of left CCA angiography arterial phase shows retrograde filling of abnormally dilated the left SOV and the venous phase shows the IPS is not opacified; D. Pre-embolization: Frontal angiography of right ICA arterial phase also shows retrograde filling of the left SOV in abnormal dilation (arrowhead); E and F. Angiogram obtained after the injection of Onyx demonstrates the existence of dilated the left SOV (arrowhead).

microcatheter was then inserted into the deployed coils. A total volume of 1.6 ml Onyx-18 was injected slowly. The postembolization angiography confirmed complete occlusion of the fistula. The eye symptoms improved significantly one month later. The patient was in good condition in the follow-up of 27 months.

Patient 10 (Figure 4): A 65-year-old male experienced progressing right eye swelling, bruits, chemosis and diplopia for two weeks. On examination, the right abducent nerve palsy was ascertained. A cerebral angiogram confirmed the right CSdAVF with feeders from bilateral external carotid artery (ECA). An Echelon 10 microcatheter was positioned in the CS/SOV junction region. A total of three coils of Axium (EV3, CA, US) (a 6 mm × 30 cm, a 5 mm × 20 cm, a 4 mm × 12 cm) were deployed and 2.4 ml of Onyx-18 was injected. After 3 months of rehabilitation, neurologic examinations showed notable improvement in ocular movement. No recurrence occurred in 23 months follow-up.

Results

All patients experienced clinical relief. One patient was treated with Onyx-18 only and others were treated by Onyx-18 combined with coils. The patient treated with Onyx-18 only acquired incomplete embolization and then carotid compression was continued for 1 week. Complications were encountered in 8 patients, including reflex bradycardia (40%, n=6), cranial nerve III palsy aggravation (6.6%, n=1) and postoperative headache (6.6%, n=1). No patients had recurrent symptoms during 16 to 54 months follow-up.

Discussion

Anatomical considerations

The clinical manifestation, management and prognosis of CSdAVFs depend mostly on the venous drainage pattern and the fistula blood flow. On angiography, it is necessary to assess the feeding artery, the venous drainage pattern

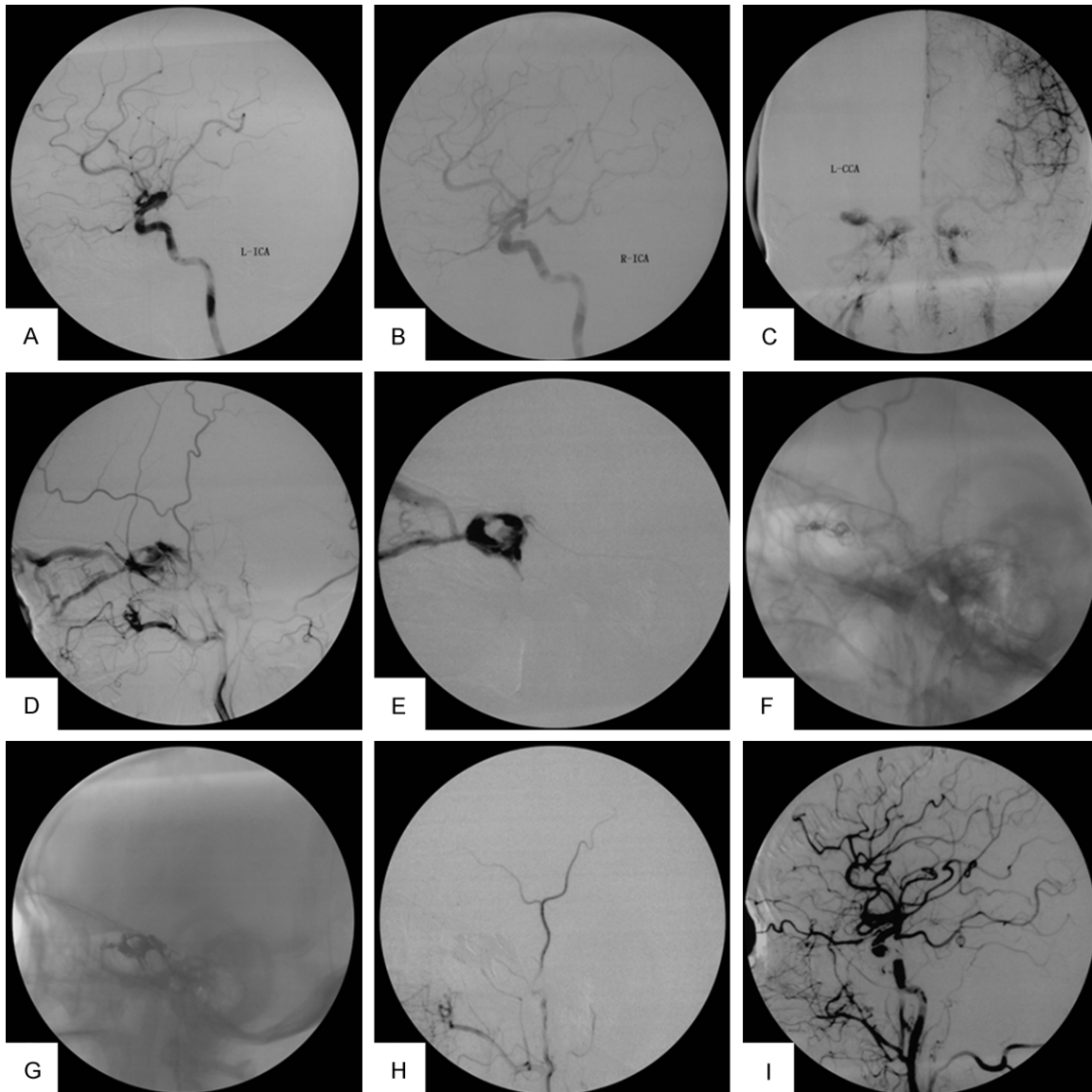


Figure 3. Preoperation, lateral projection: Bilateral ICA angiography arterial phase shows there are no dural arteriovenous shunts (A and B). Preoperation, frontal projection of left CCA angiography arterial phase shows dural arteriovenous shunts in the right cavernous sinus (C). Preoperation, lateral projection of right ECA angiography arterial phase shows retrograde filling of the right OV and drainage to the IPS (arrowhead) (D). Superselective angiography shows the cavernous sinus involved and drainage to the right OV (E). Unsubtracted lateral view after deployment of detachable coils (F). Unsubtracted angiography shows the coils and Onyx mass in the right cavernous sinus (arrowhead) (G). Post-embolization, lateral projection: Right ECA and CCA angiography show no apparent arteriovenous shunts in cavernous sinus (H and I).

and the size and location of the fistula in all patients. Based on anatomy and treatment of spinal and cranial dural AVFs, Borden et al. proposed the categorization: Type I, Drainage into sinus or meningeal veins; Type II, Drainage into sinus or meningeal veins with cortical venous reflux (CVR); Type III, CVR only [4]. Despite of extensive research, the anatomy of cavernous sinus remains controversial. We agree the notion that the sinus is an unbroken, trabecu-

lated and venous channel [5]. CS is divided into numerous chambers by trabecula, which being involved in a fistula is named as “culprit chambers”. Only after the microcatheter being positioned in the nearest place of “culprit chambers”, an ideal embolization outcome can be achieved. During the process of the microcatheter inserting into or near the “culprit chambers”, we tried adjusting the position of the tip of the microcatheter and sometimes even pen-

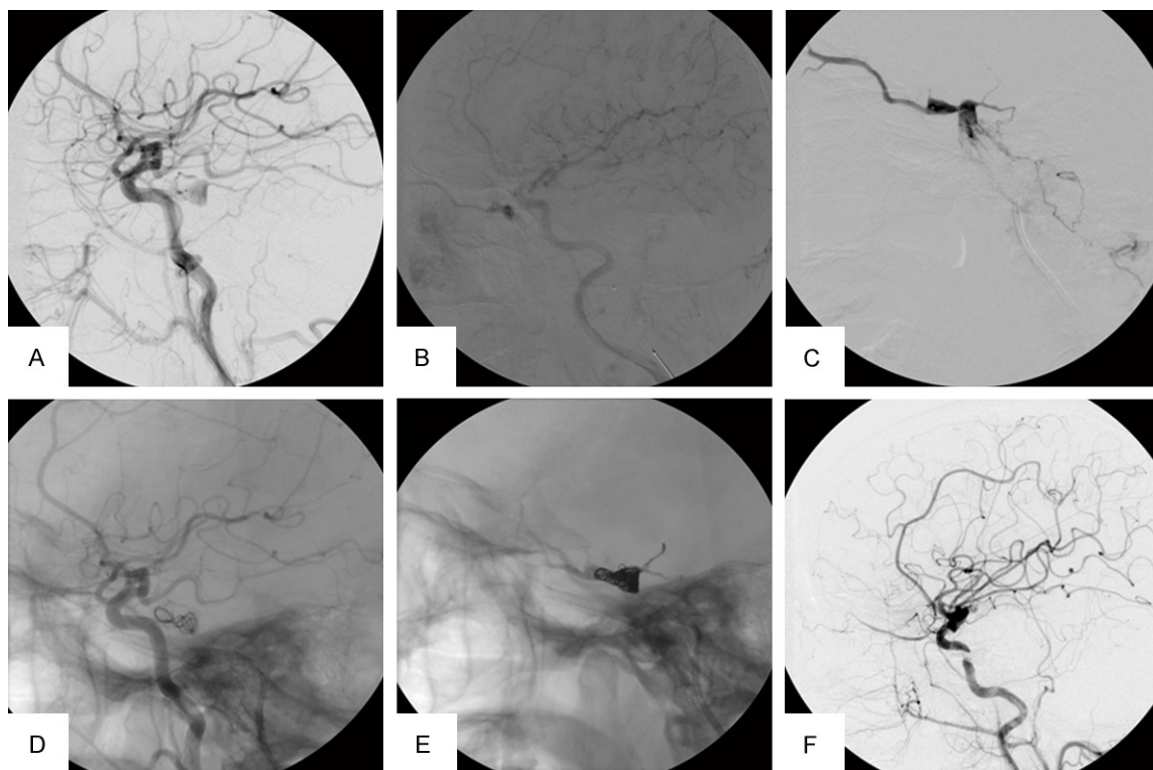


Figure 4. A and B. Pre-embolization, lateral projection: Left CCA injection arterial phase shows arteriovenous shunts in the right cavernous sinus (arrowhead) and right CCA angiography late arterial phase shows retrograde filling of the right SOV. C. Superselective angiography shows the cavernous sinus involved and drainage to the right SOV. D. Unsubtracted lateral view after deployment of detachable coils. E. Lateral skull radiograph shows the coils and Onyx mass in the right cavernous sinus. F. Post-embolization, Lateral projection: Right common carotid angiography shows no apparent arteriovenous shunts in cavernous sinus.

etrating the chambers' wall by hard PT2 micro-ware, and then the superselective angiography compared with the original simultaneously.

The main constant branches of the CS ICA are the meningohypophyseal trunk and artery of the inferior cavernous. The latter is the major blood supply for the cranial nerves in the CS. In our group, the number of patients with abducent nerve palsy is six (40%) while five (33.3%) with oculomotor nerve palsy. It is difficult to evaluate trochlear dysfunction when the oculomotor nerve palsy is present. Also, postoperative aggravation of cranial nerves palsy suggests a secondary injury from embolization. Postoperative aggravation symptoms always disappear in several days though initial symptoms may relieve in several months. Thus, the postoperative follow-up also supports the hypothesis that the initial damage is more important than secondary injury on cranial nerves [6].

The IPS is not always patent, because it does not always drain into the internal jugular vein.

Shiu et al. [7] described four types of anatomical variations of the IPS. Type I (45%), the IPS drains into the internal jugular vein; Type II (24%), the IPS drains into a communication between the internal jugular vein and the deep cervical plexus; Type III (24%), the IPS exists as a plexus of multiple small venous channels; Type IV (7%), the IPS has no communication with the internal jugular vein. Thus, the IPS approach seems to be unpractical when the type III or type IV is encountered. However, Zhang P et al. [8] reported that the successful rate of catheterization via unopacified IPS sinus and the cure rate were 99% (91/92). In our group the number of patients with nonopacification of the IPS on angiography is 5. Neither patients of Zhang's group nor ours hold relative complication. We suppose that, just as the CS, the IPS is also an unbroken, trabeculated and venous channel. Actually, the nonopacification of the IPS is not equal to type III and IV mentioned above. High density of the petrous bone and the skull base and low blood flow of the IPS also lead to the nonopacification of the

IPS. Wan YB described the IPS adjoined the glossopharyngeal, vagus and accessory nerve and the sagittal portion communicated with basilar plexus [9]. Because mechanical recanalization has the risk of the iatrogenic dissecting aneurysm and hemorrhage, it is essential to avoid inappropriate procedure. At present, no standard have been set on the 'exploring wire' passing through the 'unopacified' IPS. Zhang P used the guidewire (Terumo, Japan) of 0.889 mm in diameter and we selected PT2, a microwire of hard texture. Anyway, the wonderful outcomes of these patients suggest that it is safe and practicable to recanalize the 'unopacified' IPS mostly.

If the fistula was occluded, the normal blood flow of the cavernous sinus could be reverted. In patients with retrograde flow of the CS, it is practicable to occlude the ipsilateral cavernous sinus when ipsilateral draining veins are redirected and the contralateral cavernous sinus is not involved. When the fistula is large and blood stream is rapid, embolization with Onyx and coils has its own advantages.

Endovascular treatment

Due to recent technical development, interventional procedures have become the primary treatment for dural arteriovenous fistula. Transarterial embolization can relieve symptoms but hardly cure the fistula for the developed arteriovenous anastomoses in the dura. With application of NBCA or Onyx, transvenous embolization has evolved as the preferred method for the treatment of the CSdAVFs. Embolization via the IPS was considered more effective and safer [10].

Onyx, consisting of ethylenevinyl alcohol copolymer (EVOH), dimethyl sulfoxide (DMSO), and tantalum, is a liquid embolus dissolved in DMSO that poly-merizes on contact with the bloodstream. The polymer is expected to be a permanent therapeutic agent which has a decreased risk of catheter retention compared with n-BCA [11]. Its nonadhesive property allows a slowly long period single injection of embolus with simultaneous angiography. Onyx-18 (6% EVOH) with lower viscosity permeates better than Onyx-34 (8% EVOH). When Onyx contacts with bloodstream, Onyx-34 can easily form poly-merize in lump, which is difficult to enter the 'culprit chambers' for blockage of tra-

becula. Thus, Onyx-18 has its advantage on entering the 'culprit chambers' and occluding the fistula combined with coils (**Figure 3**). The microcatheter was positioned in the proximal SOV and the anterior compartment of the CS. Then coils were deployed irregularly in turn while the tip of the microcatheter was positioned behind coils. Hydrodynamically, irregular coils obstacle lowers the velocity of blood stream for vortex flow materializing. On one hand, it helps Onyx-18 permeate to the fistula. On the other hand, it prohibits Onyx-18 permeating to the SOV and reduces the dosage of Onyx-18. For lower viscosity of Onyx-18, we can adjust the contrast of the video-unit and reduce luminance of the operative room in order to control its injection speed. A combination of Onyx-18 and coils improve the immediate cure rate and compensate coils' lack of diffusion capacity. Coils, instead of entering the chamber directly, have advantage of thromboses to occlude the fistula postoperatively. Compared with Onyx, hardness of coils makes it easier to damage the cranial nerves but harder to reduce postoperative space-occupying effect. So, Combined with Onyx and coils, introducing several coils can reduce the blood velocity in CS without severe space-occupying effect, and avoid unexpected dissemination of Onyx.

Complications and avoidance

Complications related to the procedure include postoperative headache, cranial nerve palsy, venous perforations and reflex bradycardia. Postoperative headache may result from Onyx drainage into cortical veins or toxic effects of Onyx on the trigeminal nerve. Simple trapping and partial embolization can lead to diversion of shunt flowing into the dangerous vessels and dangerous anastomoses that result in conversion of dural arteriovenous fistula into a more dangerous and aggressive stage [12]. The coils are selected according to the volume of cavernous sinus. However, incomplete or inadequate embolization of venous outlets with coils may increase the pressure in the drainage veins, then results in hemorrhage. On the contrary, the dense packing of the cavernous sinus may result in cranial nerve deficits because of the space-occupying effect and ischemic cranial nerve damage caused by the substantial vessel wall injury [7, 15]. Injection of Onyx may provide the potential neurotoxicity of DMSO and mass effect on the trigeminal ganglion which leads to reflex bradycardia. Slow and persistent

injection can decrease the toxic effects because there are enough time to dissipate DMSO in the blood stream [13]. Li L. et al. [14] reported reflex bradycardia occurrence rate was 33.3% (2/6) when Onyx was injected. Similarly, 40% (6/15) patients in our group occurred but were reversed by dexamethasone without recurrence.

In conclusion, combined with coils, Onyx-18 can enter the "culprit chambers" of the CS and occlude the fistula. Embolization via the IPS of opacification or not was practicable and safe. The approach also can improve cure rates and reduce medical expenses.

Acknowledgements

This work was supported by The National Natural Scientific Foundation of China (No. 81141088), by The Promotive Research Fund for Excellent Young and Middle-aged Scientists of Shandong Province (No. 2004BS02010).

Disclosure of conflict of interest

None.

Address correspondence to: Dr. Gang Li, Department of Neurosurgery, Qi Lu Hospital, Shandong University, Jinan 250012, P.R. China. Tel: +86-531-82166615; Fax: +86-531-82166615; E-mail: ligangjinan@yeah.net

References

- [1] Newton TH and Cronqvist S. Involvement of dural arteries in intracranial arteriovenous malformations. *Radiology* 1969; 93: 1071-1078.
- [2] Cabral De Andrade G, Alves HP, Parente R, Salvarani CP, Clímaco VM and Pereira ER. Spontaneous isolated dural arteriovenous fistula of the cavernous sinus: endovascular approach via the foramen ovale. A technical note. *Interv Neuroradiol* 2012; 18: 458-462.
- [3] Jiang C, Lv X, Li Y, Wu Z and Shi J. Surgical access on the superior ophthalmic vein to the cavernous sinus dural fistula for embolization. *J Neurointerv Surg* 2013; 5: 13.
- [4] Borden JA, Wu JK and Shucart WA. A proposed classification for spinal and cranial dural arteriovenous fistulous malformations and implications for treatment. *J Neurosurg* 1995; 82: 166-179.
- [5] Tsuha M, Aoki H and Okamura T. Roentgenological investigation of cavernous sinus structure with special reference to paracavernous cranial nerves. *Neuroradiology* 1987; 29: 462-467.
- [6] Bink A, Goller K, Luchtenberg M, Neumann-Haefelin T, Dützmänn S, Zanella F, Berkefeld J and du Mesnil de Rochemont R. Long-term outcome after coil embolization of cavernous sinus arteriovenous fistulas. *AJNR Am J Neuroradiol* 2010; 31: 1216-1221.
- [7] Shiu PC, Hanafée W, Wilson GH and Rand RW. Cavernous sinus venography. *Am J Roentgenol Radium Ther Nucl Med* 1968; 104: 57-62.
- [8] Zhang P, Zhi XL, Li M, Song QB and Ling F. Embolization of dural arteriovenous fistula via unopacified venous sinus. *Chin J Cerebrovasc D* 2007; 4: 529-532.
- [9] Wan YB, Xu M and Guo GJ. Clinical anatomy of inferior petrosal sinus in phlebography of the intercavernous sinuses. *Chin J Neurosurg* 1987; 3: 35-38.
- [10] Théaudin M, Saint-Maurice JP, Chapot R, Vahedi K, Mazighi M, Vignal C, Saliou G, Stapf C, Bousser MG and Houdart E. Diagnosis and treatment of dural carotid-cavernous fistulas: a consecutive series of 27 patients. *J Neurol Neurosurg Psychiatry* 2007; 78: 174-179.
- [11] Carlson AP, Taylor CL and Yonas H. Treatment of dural arteriovenous fistula using ethylene vinyl alcohol (onyx) arterial embolization as the primary modality: short-term results. *J Neurosurg* 2007; 107: 1120-1125.
- [12] Yoshida K, Melake M, Oishi H, Yamamoto M and Arai H. Transvenous embolization of dural carotid cavernous fistulas: a series of 44 consecutive patients. *AJNR Am J Neuroradiol* 2010; 31: 651-655.
- [13] Suzuki S, Lee DW, Jahan R, Duckwiler GR and Viñuela F. Transvenous treatment of spontaneous dural carotid-cavernous fistulas using a combination of detachable coils and Onyx. *AJNR Am J Neuroradiol* 2006; 27: 1346-1349.
- [14] Li L, Cui JG, Liang ZH, Xu SB, Li J, Tian HQ, Fan YH. Transvenous treatment of complex cavernous dural arteriovenous fistulae with Onyx and coils. *Neurol India* 2011; 59: 92-96.