

Original Article

A point mutation in ϵ -sarcoglycan induces inherited myoclonus dystonia syndrome in a Chinese family

Hailiang Yan¹, Xiaoting Guan², Luning Wang³, Jiping Tan³, Guihong Wang², Yuan An², Yan Zhang¹

¹State Key Laboratory of Biomembrane and Membrane Biotechnology, College of Life Sciences, Peking University, Beijing, 100871, China; ²Department of Neurology, Beijing Tiantan Hospital, Capital Medical University, Beijing, 100050, China; ³Department of Geriatric Neurology, Chinese PLA General Hospital, Beijing 100853, China

Received January 21, 2013; Accepted March 12, 2013; Epub April 12, 2013; Published April 30, 2013

Abstract: Myoclonus dystonia syndrome is a rare movement disorder featured by myoclonic jerks and dystonia. We identified here a point mutation in ϵ -sarcoglycan gene exon 6 associating with inherited myoclonus dystonia syndrome in a Chinese Han family. The mutation identified induces a stop codon and terminates the transcription of ϵ -sarcoglycan mRNA. This in turn results in a large truncation of ϵ -sarcoglycan protein. The further investigation is required to understand physiological and pathological functions of ϵ -sarcoglycan.

Keywords: ϵ -sarcoglycan gene, myoclonus dystonia syndrome, mutation, Chinese, movement disorder

Introduction

Myoclonus dystonia syndrome (MDS) is a rare movement disorder featured by myoclonic jerks and dystonia [1, 2]. The patients often show typical clinical symptoms in their 10s or 20s [2]. These symptoms include myoclonic jerks at rest, which can be aggravated by action and stress; mild to moderate dystonia predominate in the upper body and axial muscles [2-4]. The symptoms of MDS are often relieved by alcohol [1]. The inherited MDS is an autosomal dominant disorder. Most reported mutations are located in the ϵ -sarcoglycan (SGCE) gene in chromosome 7 [5]. Human SGCE contains 13 exons resulting in 3 isoforms with 437, 451 and 462 amino acid long fragments depending on alternative splicing [1]. SGCE protein belongs to a family including α -, β -, γ -, and ζ -sarcoglycan. SGCE protein is a transmembrane protein with the extracellular domain containing conserved sites for asparagines-linked N-glycosylation and cysteine residues. The cytoplasmic domain consists with multiple phosphorylation sites [1]. Various mutations in SGCE are reported associating with MDS in different families [1]. Here, we reported a C>T point mutation in SGCE exon 6 causing MDS in a Chinese Han family in two generations.

Materials and methods

Subjects

We identified a family of 6 individuals from Anhui province affected with MDS. The diagnosis of MDS was made based on published criteria [6]. The close kindred and the detailed family history were investigated and a three-generation pedigree was constructed according to limited information. This study was approved by the Ethics Committee of Peking University. All the participants were given informed consent by themselves or via their legal guardians.

Human genomic DNA isolation

All the participants go to doctors and 20 ml peripheral blood was obtained from each individual. Genomic DNA was extracted from 10 ml of human whole blood following the traditional standard protocol, with proteinase K digestion of lysed peripheral leukocytes followed by phenol/chloroform extraction and ethanol purification [7]. The concentration of sample DNA was determined by a Nanodrop® ND1000 spectrophotometer (NanoDrop Technologies, Wilmington, DE).

Table 1. Primer Sequences and PCR Conditions for Exon Amplification of the SGCE Gene (NG_008893.1)

Primer Name	Exon	Sequence	Expected Size of the PCR Product (bp)	Annealing Temperature	No. of PCR Cycles
Exon 1 F	1	5'-CCGATAAGCACGGGAATGA-3'	761	55	39
Exon 1 R	1	5'-AGAGGCTGGTGCCCAAAGG-3'			
Exon 2 F	2	5'-AGTGAGACCCCTCTTTAT-3'	426	55	39
Exon 2 R	2	5'-ATGCTTTCCTTAACATTG-3'			
Exon 3 F	3	5'-CCAGATGGGTTTTGTATGT-3'	325	55	39
Exon 3 R	3	5'-TTTTGCTCTTTCTAGGTGT-3'			
Exon 4 F	4	5'-GAAAATGGAAGAATGAC-3'	400	55	39
Exon 4 R	4	5'-AGGACTATCTGTTGGCTT-3'			
Exon 5 F	5	5'-CAGAACTCAACAAATCGCA-3'	498	55	39
Exon 5 R	5	5'-TTCACAGACCAGGAACCTG-3'			
Exon 6 F	6	5'-CTCAATTCAAAAGGCTAAA-3'	394	55	39
Exon 6 R	6	5'-TAATCTCAAGGGAAGTCAAC-3'			
Exon 7 F	7	5'-CATTTGTTACATTCCCTAC-3'	442	55	39
Exon 7 R	7	5'-TGTTGTTATCTTAGCAGGA-3'			
Exon 8 F	8	5'-TCCAAGCAATGTCATAAAC-3'	214	55	39
Exon 8 R	8	5'-GAAAATAACAGGAAAGAAGA-3'			
Exon 9 F	9	5'-AGTATGTGAGATGTATGCCTT-3'	507	55	39
Exon 9 R	9	5'-AGAGTAGGGGTGAGATTTA-3'			
Exon 10 F	10	5'-ATAAGGGAATGGTGGGTAAC-3'	197	55	39
Exon 10 R	10	5'-AGGTGCGTATAATCCGAGCT-3'			
Exon 11 F	11	5'-TTGTGCTGGATTACATGACTG-3'	280	55	39
Exon 11 R	11	5'-GTGTTTTGCCTTATTTGGTG-3'			
Exon 12 F	12	5'-CTCTATTACTGCTTTCGTG-3'	299	55	39
Exon 12 R	12	5'-GTGGTAGTAGGGATTCATT-3'			
Exon 13 F	13	5'-TGCCCTGACTAACTCCTGC-3'	410	55	39
Exon 13 R	13	5'-AACCTGTTTCTAGCGATT-3'			

PCR: polymerase chain reaction; F: forward; R: reverse.

Oligonucleotide primers

All 13 exons and flanking intron regions of the SGCE gene were amplified through polymerase chain reaction (PCR), followed by sequencing of the PCR products (Sangon, Shanghai, China). Primers and PCR conditions were listed in **Table 1**.

Results

Clinical findings

In July 2011, the patient III-4 (Male, 25 yr old) came to the Department of Neurology, Beijing Tiantan Hospital, with involuntary myoclonus jerks in the neck, trunk, upper limbs, and with the writer's cramp since the age of 18. Myoclonus of the upper limbs often is accompanied by rapid, brief muscle contraction that was difficult to control. He appeared neurosis and anxiety frequently. The myoclonus symptoms were aggravated under mental stress and

significantly alleviated after alcohol intake, resting and sleeping. The patient III-4 was a full-term birth, normal growth and mental development. The cranial nerve, the sensory nervous system, the muscle strength, muscle tone and the coordination were all within normal range. The knee reflex and the Achilles tendon reflex were slightly active. Bilateral pathological reflex was negative. The Kayser-Fleischer ring examination was negative. During the examination, his head was rotating to the right side in association with the intensive jerking in the neck and upper limbs. Blood biochemistry, renal function, thyroid hormone T3 and T4, serum folic acid, vitamin B12, ceruloplasmin, four of the cerebral metabolic tests (arylsulfatase A, the galactocerebrosidase lipase, B-galactosidase, hexosaminidase A) were normal. Electroencephalography (EEG), somatosensory evoked potential (SSEP), brainstem auditory evoked potential (BAEP), electromyography (EMG), tremograms, motor evoked poten-

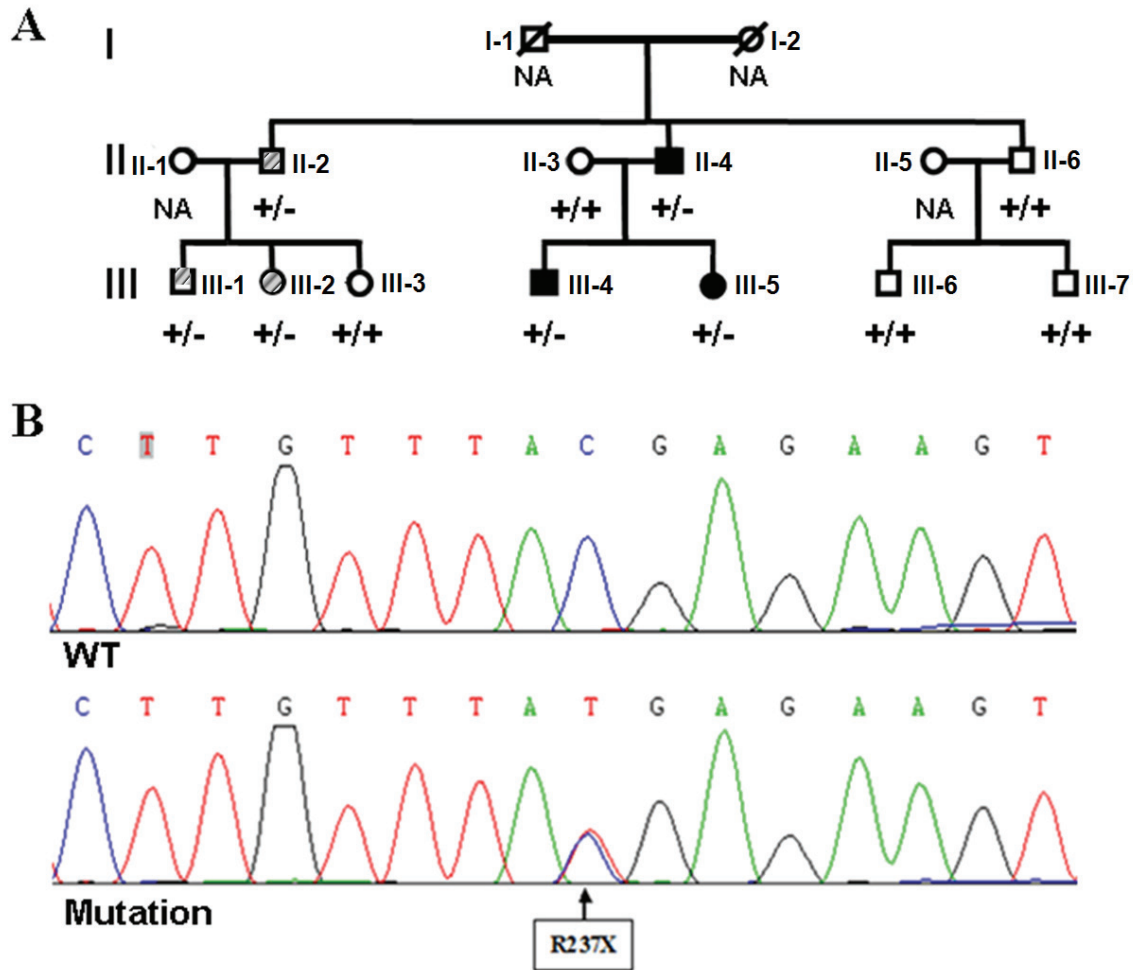


Figure 1. A point mutation in SGCE exon 6 was identified associated with inherited MDS in a Chinese family. A. Pedigree of the family with inherited MDS. B. SGCE mutation was identified by sequencing in the MDS-affected family. NA: genetic background was not determined; +/+, +/-: the genotype of the SGCE alleles confirmed by sequencing. WT: wild type of SGCE; Mutation: mutant type of SGCE allele. R237X: C>T mutation-induced truncation of SGCE protein at Arg²³⁷.

tials (MEP) were all normal. Mini-mental state examination (MMSE) scored 30. Hamilton depression scale (HAMD, 24 items) scored 25. Hamilton anxiety scale (HAMA, 14 items) scored 21. These results showed normal intelligence, moderate anxiety and depression. Brain magnetic resonance imaging (MRI) was normal. Arotinolol and madopar were invalid in respect to treating the disease on the patient III-4, while clonazepam slightly alleviated the symptoms.

His sister III-5 (Female, 27 yr old) had similar situation since 18 years old. Their father II-4 (Male, 58 yr old) (Figure 1A) showed more dramatic myoclonic jerks than the patient III-4 and III-5. His intelligence is normal currently and he

is able to do a variety of household work. He started the symptoms at the age of 19 and was alcoholic as reported by his family that alcohol consuming could reduce the symptom significantly. The diagnose of MDS for these 3 individuals were made in Department of Neurology at Beijing Tiantan Hospital.

Genetic analysis

We first investigated the genetic background of 3 patients (II-4, III-4 and III-5) with confirmed clinical diagnosis of MDS, and found a common C>T mutation in exon 6 of SGCE transcript of all 3 patients (Figure 1B). This single base pair transversion of C to T at codon 237 of arginine would terminate the mRNA translation because

of the formation of stop codon of TGA. The mutation was heterozygous because the genomic DNA retains a normal copy of "C" and a mutant copy of "T". No sequence alterations were found in any of the other 13 exons previously suggested to be associated with MDS [1]. The mutation segregated with the disease and paternal origin was apparent (**Figure 1A**). The kindred members were then subsequently investigated for the genomic DNA information at this site. Among 8 at-risk family members, five had two wild type (WT) alleles of SGCE, while the other 3 of them (II-2, III-1 and III-2) were heterozygous carriers of the identified C>T mutation (**Figure 1A**).

Discussion

The association of MDS to the point mutation of 237 C>T in exon 6 of SGCE was reported in Hungarian population [8-10]. This is the first time, to our knowledge, the identification of this mutation in a Chinese Han family with inherited MDS. In Chinese populations, deletions in SGCE exon 5 and 7 as well as reduced dosage of exon 2-11 in one allele were reported in 3 Taiwan families [11]. Another genetic study identified duplication in the exon 5 of SGCE in a Chinese family [12]. In our study, the family member II-2, III-1 and III-2 are heterozygous carriers of identified C>T mutation in exon 6. All 3 family members self-reported symptoms similar to MDS with myoclonic jerks which can be alleviated by alcohol. However, since their clinic phenotypes were not evaluated by doctors and therefore not diagnosed confirmatively as MDS (**Figure 1A**).

The point mutation of 237 C>T in exon 6 results in a large truncated fragment of SGCE protein. Mutations in mouse SGCE protein are linked to late secretory pathway trafficking and processing [13, 14] and brain development [15]. The size of deletion at SGCE determines the clinical phenotype of the disease [16]. Despite of the existing evidence, the function of SGCE in the brain is largely unknown [15]. The investigation on SGCE function and metabolism is needed to understand its physiological implications and how its mutations cause diseases.

Abbreviations

BAEP, brainstem auditory evoked potential; EEG, electroencephalography; EMG, electromy-

ography; HAMA, Hamilton anxiety scale; HAMD, Hamilton depression scale; MDS, myoclonus dystonia syndrome; MEP, motor evoked potentials; MMSE, mini-mental state examination; MRI, magnetic resonance imaging; PCR, polymerase chain reaction; SGCE, ϵ -sarcoglycan; SSEP, somatosensory evoked potential; WT, wild type.

Acknowledgements

This work was supported by the National Program of Basic Research sponsored by the Ministry of Science and Technology of China (2009CB941301), National Science Foundation of China (NSFC) Major Research Grant (91132718), and Beijing Municipal Science & Technology Commission (Z101107052210-002).

Disclosure statement

All authors declare no actual or potential conflicts of interest including any financial, personal or other relationships with other people or organizations within three years of beginning the work submitted that could inappropriately influence (bias) their work.

Address correspondence to: Dr. Xiaoting Guan, Department of Neurology, Beijing Tiantan Hospital, Capital Medical University, Beijing, 100050, China. Phone: 86-10-67096641; Fax: 86-10-67098046; E-mail: gxt-137@medmail.com.cn; Dr. Yan Zhang, College of Life Sciences, Room 219, Peking University, Beijing, 100871, China. Tel: 86-10-62754880; Fax: 86-10-62751526; E-mail: yan-zhang@pku.edu.cn; Dr. Luning Wang, Department of Geriatric Neurology, Chinese PLA General Hospital, Beijing 100853, China. Phone: 86-10-66876268; E-mail: ln_wang301@sohu.com

References

- [1] Kinugawa K, Vidailhet M, Clot F, Apartis E, Grabi D, Roze E. Myoclonus-dystonia: an update. *Mov Disord* 2009; 24: 479-489.
- [2] Phukan J, Albanese A, Gasser T, Warner T. Primary dystonia and dystonia-plus syndromes: clinical characteristics, diagnosis, and pathogenesis. *Lancet Neurol* 2011; 10: 1074-1085.
- [3] Roze E, Apartis E, Clot F, Dorison N, Thobois S, Guyant-Marechal L, Tranchant C, Damier P, Doummar D, Bahi-Buisson N, Andre-Obadia N, Maltete D, Echaniz-Laguna A, Pereon Y, Beaugendre Y, Dupont S, De Greslan T, Jedynak CP,

- Ponsot G, Dussaule JC, Brice A, Durr A, Vidailhet M. Myoclonus-dystonia: clinical and electrophysiologic pattern related to SGCE mutations. *Neurology* 2008; 70: 1010-1016.
- [4] Asmus F, Gasser T. Inherited myoclonus-dystonia. *Adv Neurol* 2004; 94: 113-119.
- [5] Zimprich A, Grabowski M, Asmus F, Naumann M, Berg D, Bertram M, Scheidtmann K, Kern P, Winkelmann J, Muller-Myhsok B, Riedel L, Bauer M, Muller T, Castro M, Meitinger T, Strom TM, Gasser T. Mutations in the gene encoding epsilon-sarcoglycan cause myoclonus-dystonia syndrome. *Nat Genet* 2001; 29: 66-69.
- [6] Gasser T. Inherited myoclonus-dystonia syndrome. *Adv Neurol* 1998; 78: 325-334.
- [7] Vandenplas S, Wiid I, Grobler-Rabie A, Brebner K, Ricketts M, Wallis G, Bester A, Boyd C, Mathew C. Blot hybridisation analysis of genomic DNA. *J Med Genet* 1984; 21: 164-172.
- [8] Grunewald A, Djarmati A, Lohmann-Hedrich K, Farrell K, Zeller JA, Allert N, Papengut F, Petersen B, Fung V, Sue CM, O'Sullivan D, Mahant N, Kupsch A, Chuang RS, Wiegers K, Pawlack H, Hagenah J, Ozelius LJ, Stephani U, Schuit R, Lang AE, Volkmann J, Munchau A, Klein C. Myoclonus-dystonia: significance of large SGCE deletions. *Hum Mutat* 2008; 29: 331-332.
- [9] Doheny DO, Brin MF, Morrison CE, Smith CJ, Walker RH, Abbasi S, Muller B, Garrels J, Liu L, De Carvalho Aguiar P, Schilling K, Kramer P, De Leon D, Raymond D, Saunders-Pullman R, Klein C, Bressman SB, Schmand B, Tijssen MA, Ozelius LJ, Silverman JM. Phenotypic features of myoclonus-dystonia in three kindreds. *Neurology* 2002; 59: 1187-1196.
- [10] Koukouni V, Valente EM, Cordvari C, Bhatia KP, Quinn NP. Unusual familial presentation of epsilon-sarcoglycan gene mutation with falls and writer's cramp. *Mov Disord* 2008; 23: 1913-1915.
- [11] Huang CL, Lan MY, Chang YY, Hsu CY, Lai SC, Chen RS, Chang HC, Lu CS, Wu-Chou YH. Large SGCE deletion contributes to Taiwanese myoclonus-dystonia syndrome. *Parkinsonism Relat Disord* 2010; 16: 585-589.
- [12] Chen XP, Zhang YW, Zhang SS, Chen Q, Burgunder JM, Wu SH, Yang Y, Luo ZM, Shang HF. A novel mutation of the epsilon-sarcoglycan gene in a Chinese family with myoclonus-dystonia syndrome. *Mov Disord* 2008; 23: 1472-1475.
- [13] Waite A, De Rosa MC, Brancaccio A, Blake DJ. A gain-of-glycosylation mutation associated with myoclonus-dystonia syndrome affects trafficking and processing of mouse epsilon-sarcoglycan in the late secretory pathway. *Hum Mutat* 2011; 32: 1246-1258.
- [14] Peall KJ, Waite AJ, Blake DJ, Owen MJ, Morris HR. Psychiatric disorders, myoclonus dystonia, and the epsilon-sarcoglycan gene: a systematic review. *Mov Disord* 2011; 26: 1939-1942.
- [15] Waite A, Brown SC, Blake DJ. The dystrophin-glycoprotein complex in brain development and disease. *Trends Neurosci* 2012; 35: 487-496.
- [16] Asmus F, Hjermand LE, Dupont E, Wagenstaller J, Haberlandt E, Munz M, Strom TM, Gasser T. Genomic deletion size at the epsilon-sarcoglycan locus determines the clinical phenotype. *Brain* 2007; 130: 2736-2745.