

Case Report

Acute myeloid leukemia with t(10;17)(p13;q12) chromosome translocation: a case report and literature review

Lu Li¹, Fan Zhou¹, Jian Hou^{1,2}

¹Shanghai Zhabei District Central Hospital (L.L., Z.F.), Shanghai, China; ²Changzheng Hospital, Second Military Medical University (J.H.), Shanghai, China

Received October 26, 2012; Accepted November 12, 2012; Epub November 25, 2012; Published November 30, 2012

Abstract: More than 50% of adult patients with acute myeloid leukemia (AML) carry chromosome abnormalities, like t(8;21)(q22;q22), t(15;17), t(8;21)inv(16) or t(16;16). t(10;17) translocation was very rare in AML. There are only 10 such cases reported in the literature. Here, we describe a case of acute myeloid leukemia with t(10;17)(p13;q12) chromosome translocation, who had complete remission after one course of chemotherapy.

Keywords: Acute myeloid leukemia, t(10;17)(p13;q12), chromosome translocation

More than 50% of adult patients with acute myeloid leukemia (AML) carry chromosome abnormalities, like t(8;21)(q22;q22), t(15;17), t(8;21)inv(16) or t(16;16) [1]. t(10;17) translocation was first reported in 1989 by Lai et al [2]. There are only 10 such cases reported (Table 1), and all outside China. Here, we describe a case of acute myeloid leukemia with t(10;17)(p13;q12) chromosome translocation, who got complete remission after one course of chemotherapy.

Case report

A 30-year-old man presented with high fever (39.4°C) for 7 Days. He started experiencing pain in the right hip since Jan. 2010, and the pain spread to the entire body within a year. The patient disclosed persistent low fever (37.4°C~37.8°C) since Jan. 2010. In Jun 2011, the patient was fully conscious and had steady breathing. The palpebral conjunctiva was normal. There was no pressing pain in the sternum, and no skin bleeding. There was no chest rale. The abdomen was soft upon palpation. The liver and spleen are not palpable. Muscle tone in the limbs was apparently normal. A MRI examination revealed bone loss in the iliac,

acetabular bone, hucklebone, marrow space, and lumbar vertebra centrum. A bone ECT revealed high uptake of 99Tcm-MDP in the skull, bilateral iliac, right pubis and hucklebone. Blood routine was unremarkable. A bone marrow smear revealed 36% blasts. Most of the blasts were negative for peroxidase (POX) and naphthol AS-D chloroacetate esterase (CE) indicating myeloid lineage. A flow cytometric analysis (FCM) revealed 10% blast cells. Immunophenotyping revealed positive HLADR+, CD117+, CD34+, CD33+, CD38+, cMPO+ in abnormal cells, confirming myeloid phenotype. A bone marrow biopsy indicated hyperplasia and fibrosis, expansion of minute vessel, focal lymphocyte infiltration, and no malignant cells. A karyotype analysis revealed 46,XY, t(10;17)(p13;q12) [19]/46,XY [1] (Figure 1). Allele-specific PCR and gel electrophoresis analyses did not reveal mutation in the C-kit/D816V, NPM1, and FLT3/ITD. A diagnosis of acute monocytic leukemia was established, and the patient started to receive a MA chemotherapeutic regimen (mitoxantrone 12 mg intravenously [IV] d1 and 2, 10 mg d3; cytarabine 200mg/d intravenously [IV] for 7days) scheme. After one treatment cycle of 1 month, a bone marrow smear revealed complete remission

Acute myeloid leukemia with t(10;17)(p13;q12) translocation

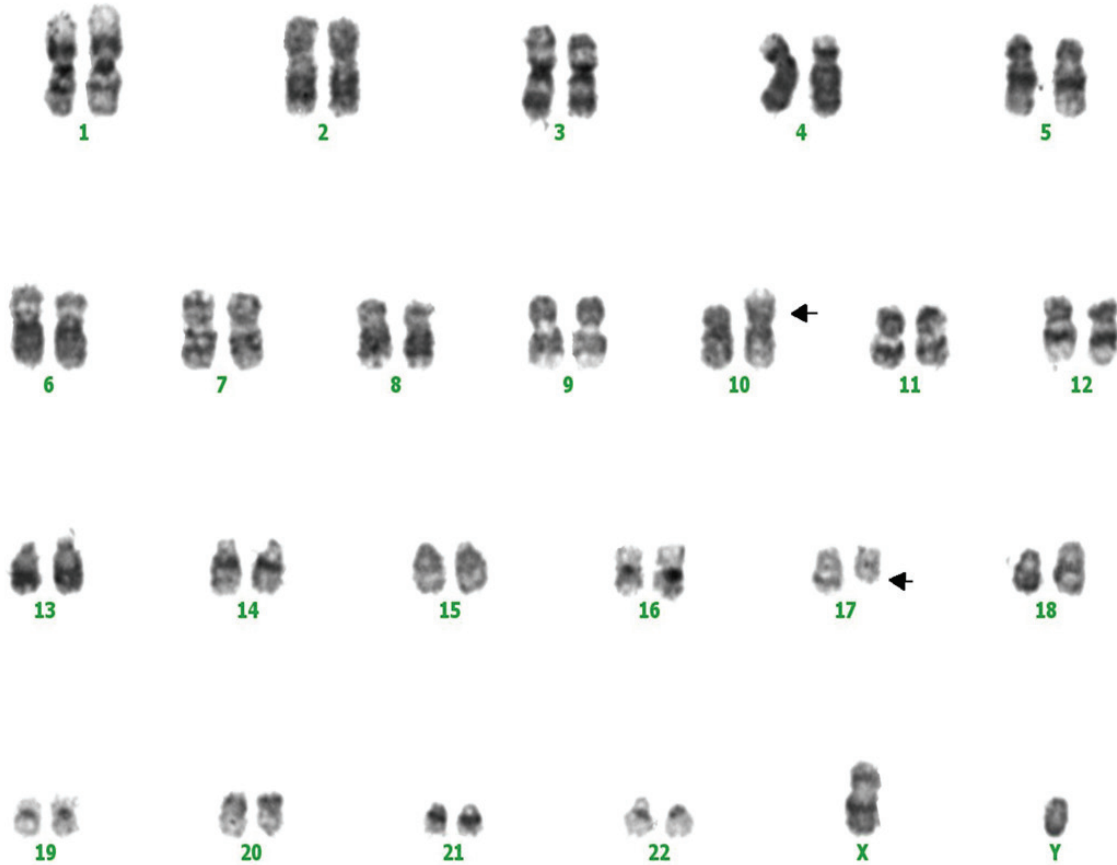


Figure 1. Karyotype: 46,XY, t(10;17)(p13;q12). Horizontal arrows indicate the derivative chromosomes involved in this translocation.

(CR). At the time of submission of this manuscript, bone puncture still revealed CR.

Discussion and review of the literature

Chromosome abnormality is an important basis in diagnosing malignant hematological diseases. We here report a young man with AML with t(10;17)(p13;q12) chromosomal translocation.

17q12~21 section is fragile and prone to chromosome translocation and gene recombination. This chromosomal region contains the BRCA 1 proto-oncogene, and as such, is implicated in breast, ovarian and non-small cell lung cancer [3]. The 10p13 locus carried the Bmi-1 gene; chromosome translocation involving this site is implicated in malignant T cell lymphoma and many other types of malignant tumors [4-6]. However, Bmi-1 has also been reported to block the key enzymes in cell cycle [7].

Six of the 10 previously reported AML patients with t(10;17)(p13;q12) chromosome translocation

also harbor other translocations. Eight of the 10 reported cases are partial differentiating and undifferentiating leukemia. In three of the 10 cases, blast cells have phagocytic activity. In general, these patients (complex chromosomal translocation involving t(10;17)(p13;q12)) have very short survival. In contrast, patients with simple t(10;17)(p13;q12) translocation have better prognosis [8, 9]. The longest survival is 15 months among the 4 reported patients with simple t(10;17)(p13;q12) translocation. The poor prognosis in patients with complex translocations seems to be related to poor degree of differentiation of leukemia cells. In the 4 cases of single chromosome t(10;17) translocation, one is M1, and 2 are M0. The remaining one case is M1, but developed new chromosome change (del(11)(p11.2)) upon relapse after ten months [10]. This patient did not respond to the treatment and died of sepsis. Noticeably, all 3 cases with blast phagocytic activity have simple chromosome translocation.

Acute myeloid leukemia with t(10;17)(p13;q12) translocation

Table 1. Summary of patients with t(10;17)(p13~15;q12~21) from the literatures

Author	Gender / Age	Typing	WBC 10 ³ /uL	Chromosome study	Survival period
Pollak C [21]	Male /16			46,XY,t(10;17)(p15;q21)/46,idem,del(6)(q15q23),del(9)(p21p22),del(14)(q21q24)	4 Month
Laï JL [1]	Female/25	M0	6.1	46,XX,t(10;17)(p13;q12)	Survival
Laï JL [1]	Female/81	M0	1.6	46,XX,t(10;17)/(p13;q12~21)	Survival
Shah D [20]	Male /11	M1		46,XY,t(10;17)(p15;q21)[5]/46,idem,i(7)(q10) [10]	42 Month
Silva ML [18]	Female / 6	ALL/L1		46,XX,t(10;17)(p15;q21)[24]/46,XX [3]	Lost
Dicker F [19]	Female	M0		46,XX,t(10;17)(p15;q21)[2]/47,idem,t7 [7]/46,XX [16]	Lost
Seung Hwan Oh [10]	Male /48	M1	11.2	46,XY,t(10;17)(p13~15;q12~21)[8]/46,XY [2]	15 Month
Wang E [16]	Male /53	M7	4.8	46,XY,t(10;17)(p15;q22)	6 Month
Tempescul A [17]	Male /13	M1	2.2	46,XY,t(10;17)(p15;q21)[5]/47,XY,t(10;17)(p15;q21),+13[9]/46,XY [9]	Lost
Tempescul A [17]	Female /40	M1	7.4	46,XY,t(10;17)(p15;q21)[3]/46,idem,add(11)(q11),add(13)(q3~2) [6]/46,XY [16]	Lost

The patient in the current case achieved CR after a course of chemotherapy. The CR status remained for 17 month at least. The relatively benign prognosis may be related to the ethnicity, as reported earlier. Clinical studies conducted by Mari-Lyn L [11], British Medical Research Committee (MRC) [12] and French AML Working Group [13] confirmed the AML in Chinese population tend to have better prognosis than in other populations [14, 15]. Blast cells in this patient did not display phagocytic activity. Previous reports showed that phagocytic activity is associated with unfavorable prognosis and recurrence.

The significance of chromosome t(10;17)(p13-15;q12-21) translocation in acute leukemia need more studies.

Abbreviations

CR, complete remission; AML, acute myeloid leukemia; POX, peroxidase; CE, naphthol AS-D chloroacetate esterase; FCM, a flow cytometric analysis.

Address correspondence to: Dr. Jian Hou, Department of Hematology, Changzheng Hospital,

Second Military Medical University, 415 Fengyang Road, 200003, Shanghai, China. Tel: 86-21-81885421; E-mail: houjian167@sohu.com

Reference

- [1] Laï JL, Estienne MH, Fenaux P, Lepelley P, Huard JJ, Bauters F, Deminatti M. Translocation t(10;17)(p13;q12) in two cases of acute non-lymphocytic leukemia with phagocytic activity of Blasts. *Cancer Genet Cytogenet* 1989; 39: 45-53.
- [2] Mrózek K, Heerema NA, Bloomfield CD. Cytogenetics in acute leukemia. *Blood Rev* 2004; 18: 115-136.
- [3] Gachechiladze M, Skarda J. The role of BRCA1 in non-small cell lung cancer. *Biomed Pap Med Fac Univ Palacky Olomouc Czech Repub* 2012; 156: 200-3.
- [4] Jacobs JJ, Kieboom K, Marino S, DePinho RA, van Lohuizen M. The oncogene and Polycomb-group gene *bmi-1* regulates cell proliferation and senescence through the *ink4a* locus. *Nature* 1999; 397: 164-8.
- [5] Leung C, Lingbeek M, Shakhova O, Liu J, Tanger E, Saremaslani P, Van Lohuizen M, Marino S. *Bmi1* is essential for cerebellar development and is overexpressed in human medulloblastomas. *Nature* 2004; 428: 337-41.

- [6] Dimri GP, Martinez JL, Jacobs JJ, Keblusek P, Itahana K, Van Lohuizen M, Campisi J, Wazer DE, Band V. The Bmi-1 oncogene induces telomerase activity and immortalizes human mammary epithelial cells. *Cancer Res* 2002; 62: 4736-45.
- [7] Van-Lohuizen M, Frasch M, Wientjens E, Berns A. Sequence similarity between the mammalian bmi-1 proto-oncogene and the Drosophila regulatory genes Psc and Su(z)2. *Nature* 1991; 353: 353-5.
- [8] Grimwade D, Walker H, Harrison G, Oliver F, Chatters S, Harrison CJ, Wheatley K, Burnett AK, Goldstone AH. Medical Research Council Adult Leukemia Working Party. The predictive value of hierarchical cytogenetic classification in older adults with acute myeloid leukemia (AML): analysis of 1065 patients entered into the United Kingdom Medical Research Council AML11 trial. *Blood* 2001; 98: 1312-20.
- [9] Byrd JC, Mrózek K, Dodge RK, Carroll AJ, Edwards CG, Arthur DC, Pettenati MJ, Patil SR, Rao KW, Watson MS, Koduru PR, Moore JO, Stone RM, Mayer RJ, Feldman EJ, Davey FR, Schiffer CA, Larson RA, Bloomfield CD. Cancer and Leukemia Group B (CALGB 8461). Pre-treatment cytogenetic abnormalities are predictive of induction success, cumulative incidence of relapse, and overall survival in adult patients with de novo acute myeloid leukemia: results from Cancer and Leukemia Group B (CALGB 8461). *Blood* 2002; 100: 4325-36.
- [10] Oh SH, Park TS, Cho SY, Kim MJ, Huh J, Kim B, Song SA, Lee JY, Jun KR, Shin JH, Kim HR, Lee JN. Acute myeloid leukemia associated with t(10;17) (p13-15;q12-21) and phagocytic activity by leukemic blasts: a clinical study and review of the literature. *Cancer Genetics and Cytogenetics* 2010; 202: 43-46.
- [11] Slovak ML, Kopecky KJ, Cassileth PA, Harrington DH, Theil KS, Mohamed A, Paietta E, Willman CL, Head DR, Rowe JM, Forman SJ, Appelbaum FR. Karyotypic analysis predicts outcome of preremission and postremission therapy in adult acute myeloid leukemia: a Southwest Oncology Group/Eastern Cooperative Oncology Group study[J]. *Blood* 2000; 96: 4075-4083.
- [12] Grimwade D, Walker H, Harrison G, Oliver F, Chatters S, Harrison CJ, Wheatley K, Burnett AK, Goldstone AH. Medical Research Council Adult Leukemia Working Party. The predictive value of hierarchical cytogenetic classification in older adults with acute myeloid leukemia (AML): analysis of 1065 patients entered into the United Kingdom Medical Research Council AML11 trial. *Blood* 2001; 98: 1312-1320.
- [13] Nguyen S, Leblanc T, Fenaux P, Witz F, Blaise D, Pigneux A, Thomas X, Rigal-Huguet F, Lioure B, Auvrignon A, Fièvre D, Reiffers J, Castaigne S, Leverger G, Harousseau JL, Socié G, Dombret H. A white blood cell index as the main prognostic factor in t(8; 21) acute myeloid leukemia (AML): a survey of 161 cases from the French AML intergroup. *Blood* 2002; 99: 3517-3523.
- [14] Shi HX, Jiang B, Qiu JY, Lu XJ, Fu JF, Wang DB, Lu DP. Studies of treatment strategy and prognosis on acute myeloid leukemia with chromosome 8 and 21 translocation [J]. *Chinese Journal Of Hematology* 2005; 26: 481-484.
- [15] Lai YY, Qiu JY, Jiang B, Lu XJ, Huang XJ, Liu YR, Shi Y, Dang H, He Q, Lu DP. Analysis of characteristics of 72 cases of t(8 ;21) acute myeloid leukemia. *Journal Of Peking University(Health Sciences)* 2005; 37: 245-248.
- [16] Wang E, Stoecker M. "Cannibalistic" phagocytosis in acute megakaryoblastic leukemia (AML M7) with t(10;17)(p15;q22). *Leukemia & Lymphoma* 2010; 51: 1944-1947.
- [17] Tempescul A, Guillerme G, Douet-Guilbert N, Morel F, Le Bris MJ, De Braekeleer M. Translocation (10;17)(p15;q21) is a recurrent anomaly in acute myeloblastic leukemia. *Cancer Genet Cytogenet* 2007; 172: 74-6.
- [18] Silva ML, Ornellas de Souza MH, Ribeiro RC, Morel F, Le Bris MJ, De Braekeleer M. Cytogenetic analysis of 100 consecutive newly diagnosed cases of acute lymphoblastic leukemia in Rio de Janeiro. *Cancer Genet Cytogenet* 2002; 137: 85-90.
- [19] Dicker F, Haferlach C, Kern W, Haferlach T, Schnittger S. Trisomy 13 is strongly associated with AML1/RUNX1 mutations and increased FLT3 expression in acute myeloid leukemia. *Blood* 2007; 110: 1308-16.
- [20] Shah D, Bond M, Kilby AM, Patterson KG. Widespread bone disease in acute myeloid leukaemia. *Leuk Lymphoma* 2001; 42: 1309-14.
- [21] Pollak C, Hagemeijer A. Abnormalities of the short arm of chromosome 9 with partial loss of material in hematological disorders. *Leukemia* 1987; 1: 541-8.