

## Case Report

# Takotsubo cardiomyopathy: reversible stress-induced cardiac insult - a stress protective mechanism

Sachin Kumar Amruthlal Jain, Timothy R Larsen, Anas Souqiyeh, Shukri W David

*Providence Heart Institute, Providence Hospital and Medical Centers, MI, USA*

Received October 16, 2012; Accepted December 11, 2012; Epub February 17, 2013; Published February 27, 2013

**Abstract:** Takotsubo cardiomyopathy (TCM) is characterized by a typical pattern of wall motion abnormalities (basal hyperkinesis with mid-ventricular and apical hypokinesis) in the absence of obstructive coronary artery disease. The clinical presentation often mimics acute coronary syndrome with anginal and anginal-equivalent symptoms, dynamic ECG changes, and elevated cardiac biomarkers. Patients are predominantly postmenopausal women. In the vast majority of cases an extremely stressful inciting event can be identified. The catecholamine surge occurring in response to stress has been implicated as the trigger for this peculiar myocardial response. It appears the specific type of beta-adrenergic receptor activation, relative epinephrine to norepinephrine activity, and a genetic predisposition all play a role. This apparently paradoxical response to stress may, in fact, be an important evolutionary safety net preventing catecholamine induced myocardial collapse.

**Keywords:** Takotsubo cardiomyopathy, stress cardiomyopathy, adrenergic receptor polymorphism

## Introduction

Takotsubo cardiomyopathy (TCM), also known as stress induced cardiomyopathy, apical ballooning syndrome and the “Broken heart syndrome” is a well described disease entity resulting in an acute left ventricular (LV) functional abnormality in response to severe emotional or physiologic stress. It typically involves dyskinesia of the mid-ventricular and/or apical segments of the left ventricle, with new EKG abnormalities and/or elevation of cardiac biomarkers (e.g. troponin) in the absence of obstructive coronary artery disease, myocarditis, or pheochromocytoma. Takotsubo cardiomyopathy was first described by Sato et al in 1990 [1]. The name is derived from the characteristic appearance of the heart on left ventriculogram and echocardiogram with apical ballooning resembling a Japanese octopus trap or “takotsubo”.

While initial presentation is quite variable, common symptoms include chest pain and dyspnea. Often symptoms are preceded by a severe emotional or physical stressor. Occasionally TCM may be identified as an unex-

plained cardiomyopathy in an asymptomatic individual, making it difficult to establish the diagnosis [2].

In the United States, TCM is estimated to account for up to 0.02% of all in-patient admissions and 89.0% of cases occur in women, typically post-menopause. Common co-morbid conditions include cerebrovascular disease, psychiatric disorders (including anxiety, depression, and other mood disorders), chronic liver disease, sepsis, and malignancy [3, 4]. New and dynamic electrocardiographic (ECG) changes are often identified in TCM. ST-segment elevation is present in approximately 1/3 of cases. T-wave inversion is common and may be diffuse. Occasionally new Q-waves and changes in QRS voltages are observed. The most common change appears to be QT-prolongation which can predispose to ventricular tachycardia, specifically torsades de pointes. Serum levels of cardiac biomarkers (troponin, creatinine kinase, and brain natriuretic peptide) are oftentimes elevated [2, 5, 6]. Echocardiography typically reveals the “Japanese octopus trap configuration” with mid-ventricular and apical dyskinesia along with basilar hyperkinesis [7].

Objective criteria for diagnosing TCM have been developed by the Mayo Clinic [8]. In order to establish the diagnosis all four of these criteria must be met: 1) transient dyskinesia of the mid-ventricular segment with or without apical involvement 2) Absence of obstructive coronary artery disease, 3) New EKG abnormalities (ST-segment elevation or T-Wave inversion) or mild troponin elevation, and 4) Absence of pheochromocytoma and myocarditis.

The exact mechanism responsible for the peculiar myocardial response seen in TCM is not entirely understood. It appears that excess catecholamine (particularly epinephrine) released in response to extreme stress induces a change in the beta2 adrenergic receptor. Under these circumstances activation paradoxically inhibits myocardial contraction in certain regions of the heart. Certain genetic polymorphisms of the beta 2 receptor may predispose some patients to TCM.

Herein we report three cases of women presenting with chest pain and/or dyspnea that were subsequently diagnosed with TCM.

### Case 1

A 67 year old African American female presented to the emergency room complaining of acute onset retrosternal chest pain described as a pressure sensation. This pain started several hours earlier while she was doing yard work that included mowing the lawn and raking leaves. The pain was non radiating and only slightly relieved with rest. This was associated with shortness of breath and heart palpitations. She was otherwise healthy and did not take any chronic medications. There was no family history of premature cardiovascular disease. She did not use tobacco, alcohol or illicit drugs.

Initial vital signs were blood pressure of 98/60 mmHg, heart rate of 110 beats/minute, respiratory rate of 12 breaths/minute, and temperature of 97.9 degrees Fahrenheit. She was in mild distress. Cardiac exam revealed normal S1 and S2, no murmurs or gallops present, point of maximal impulse was not displaced. Pulmonary auscultation revealed normal breath sounds, with no wheezes, rales, or rhonchi. The remainder of the physical exam was unremark-

able. Serum troponin T level was elevated at 0.55 ng/ml. ECG showed ST-segment elevation in V2 and V3 and T-wave inversion in the inferior, anteroseptal, and anterolateral leads. Chest X-ray revealed a normal cardiac silhouette, no evidence of vascular congestion, and no active pulmonary disease.

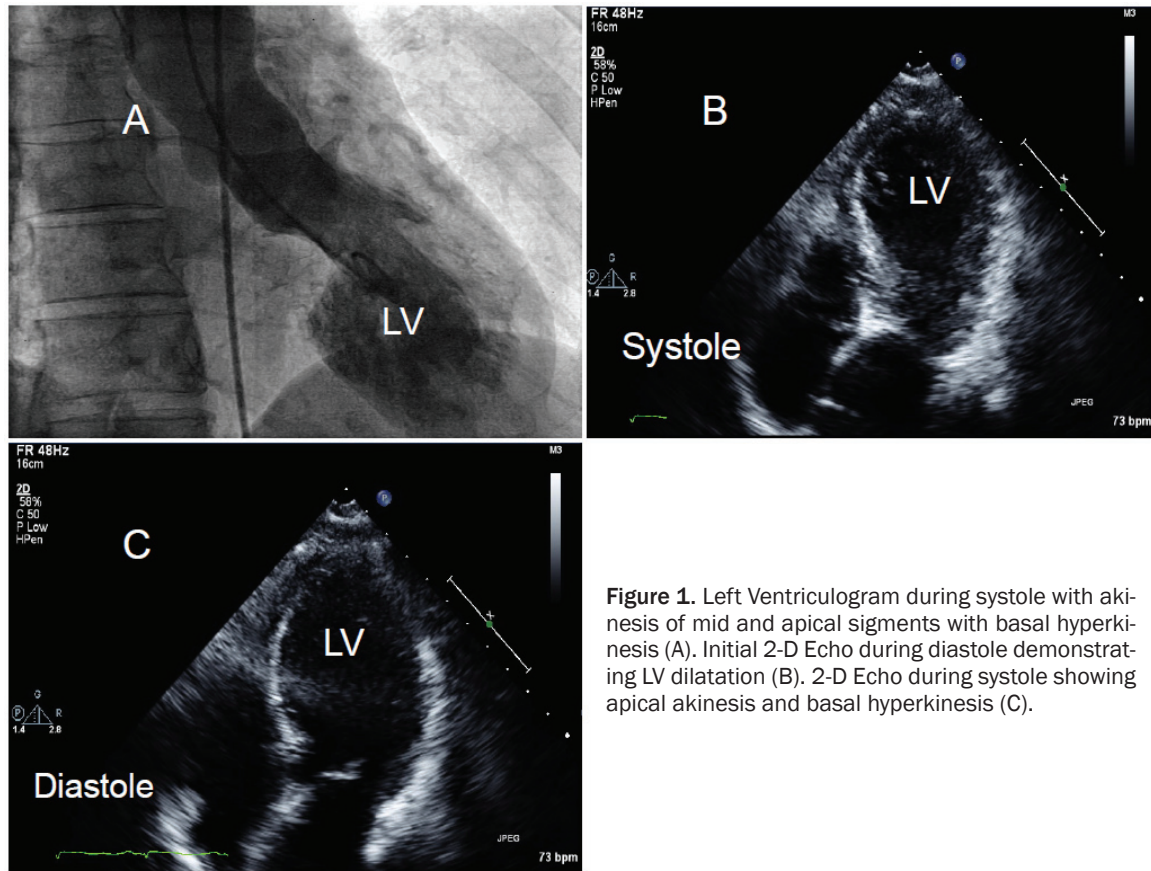
She was emergently transferred to the cardiac catheterization laboratory for possible percutaneous coronary intervention. Coronary angiogram revealed normal arteries without obstructive disease. Left ventriculogram showed an estimated LV ejection fraction of 20% with akinesis of the mid and apical segments (**Figure 1A**). These findings were confirmed by transthoracic echocardiogram (**Figure 1B**) and (**Figure 1C**).

Having demonstrated characteristic LV wall motion dysfunction and new ECG changes without obstructive coronary artery disease, pheochromocytoma, or myocarditis the diagnosis of TCM was made. Pharmacotherapy with beta-blockade and angiotensin system inhibition was initiated. A follow up transthoracic echocardiogram performed one week after discharge showed improvement in LV systolic function from an ejection fraction of 20% to 30%.

### Case 2

A 70-year-old Caucasian female was emergently transferred from an outside hospital to our catheterization laboratory with the diagnosis of ST-segment elevation myocardial infarction. She initially complained of sudden onset shortness of breath, diaphoresis, abdominal pain, and headache.

Her past medical history is significant for coronary artery disease with multiple myocardial infarctions, a stroke, hypertension, hypothyroidism, and obstructive apnea. She denied smoking, alcohol, and illicit drug use. She had prior coronary angioplasty with stenting. Her initial vital signs were blood pressure of 168/94 mmHg, heart rate of 113 beats/minute, respiratory rate of 14 breaths/minute, and a temperature of 98.7 degrees Fahrenheit. Pulmonary auscultation demonstrated bibasilar crackles with decreased air entry. Cardiac exam revealed grade 2/6 crescendo-decrescendo systolic



**Figure 1.** Left Ventriculogram during systole with akinesis of mid and apical segments with basal hyperkinesis (A). Initial 2-D Echo during diastole demonstrating LV dilatation (B). 2-D Echo during systole showing apical akinesis and basal hyperkinesis (C).

murmur loudest at the base, the point of maximal impulse was displaced laterally. The remainder of the physical exam was unremarkable.

Chest X-ray showed cardiomegaly and bilateral pleural effusions. ECG showed normal sinus rhythm with 2 mm ST-segment elevation in leads V2 to V6. Initial troponin T level was 0.48 ng/ml. Angiogram revealed patent coronary arteries with no significant in-stent restenosis. Left ventriculogram demonstrated an estimated ejection fraction of 20% (Figure 2A). Transthoracic echocardiogram (Figure 2B) and (Figure 2C) confirmed LV dysfunction with hypokinesis of the mid and apical ventricular segments with contractility of basal segment.

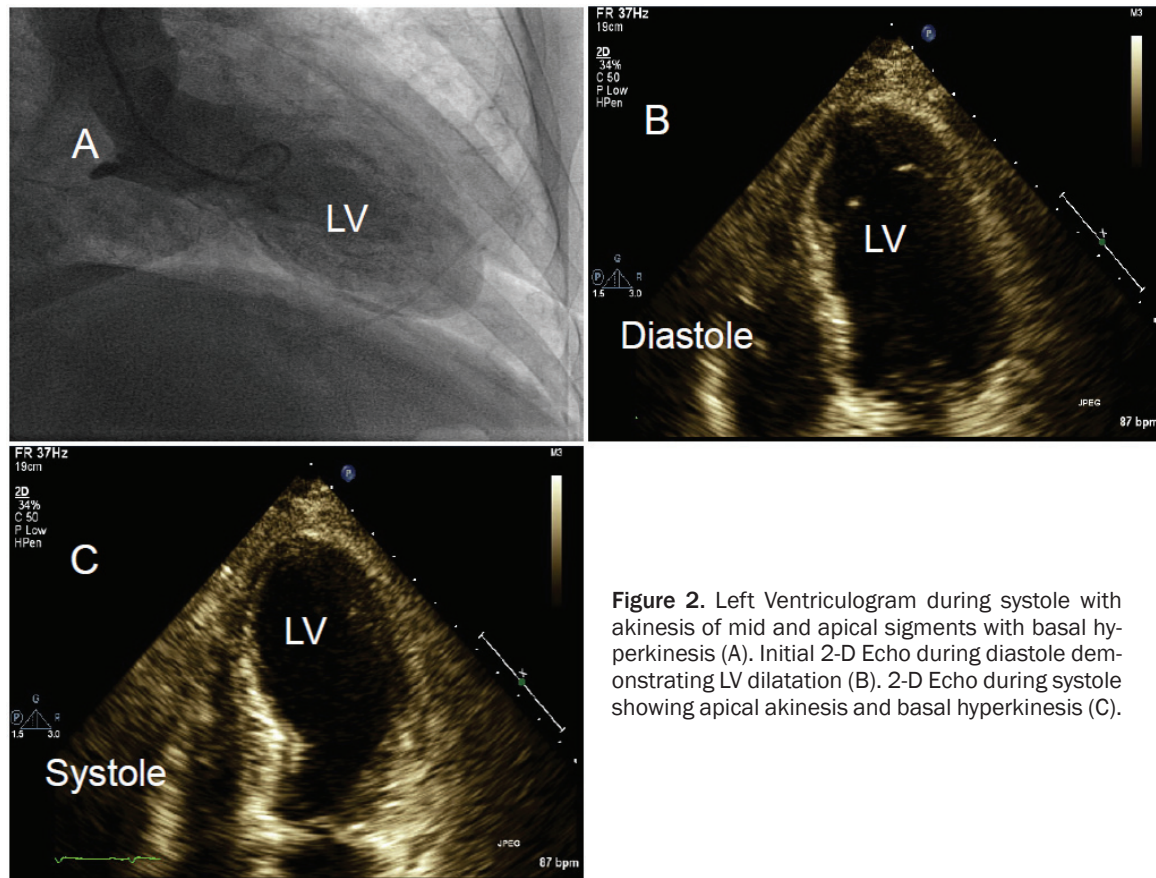
Having fulfilled the Mayo Clinic criteria the diagnosis of TCM was made. Appropriate beta-blockade and ace-inhibition were initiated along with general supportive therapy. A follow-up 2D echocardiogram performed five days after admission showed improvement in LV ejection fraction from 20% to 35%.

## Case 3

An 81-year-old female presented to the emergency room complaining of shortness of breath at rest that was present upon waking that morning. She had undergone successful electrical cardioversion for atrial fibrillation one day prior to symptom onset. Her past medical history was significant for chronic obstructive pulmonary disease, chronic renal insufficiency, type II diabetes mellitus, and hypertension. She did not use tobacco, alcohol or illicit drugs.

Vital signs on presentation were blood pressure of 111/35 mmHg, heart rate of 72 beats/minute, respiratory rate of 22 breaths/minute, and temperature of 98.1 degrees Fahrenheit. Pulmonary exam demonstrated decreased breath sounds at the bases and scattered rhonchi. Cardiac auscultation revealed an irregular rate with no murmurs or gallops. The remainder of the physical exam was unremarkable.

Chest x-ray revealed pulmonary edema with diffuse vascular congestion. Initial ECG demon-



**Figure 2.** Left Ventriculogram during systole with akinesis of mid and apical segments with basal hyperkinesis (A). Initial 2-D Echo during diastole demonstrating LV dilatation (B). 2-D Echo during systole showing apical akinesis and basal hyperkinesis (C).

strated a sinus rhythm and ST-segment depression with inverted T waves in the anterolateral and inferior leads. Initial troponin-T was 1.14 ng/ml and pro-BNP of 2,173 pg/ml. Echocardiogram showed a left ventricular ejection fraction of 20%, decreased from 55% on echocardiogram performed prior the cardioversion one day before (**Figure 3A**). She was referred for emergent left heart catheterization and possible percutaneous coronary intervention. Angiography, however, revealed patent coronary arteries. Left ventriculogram demonstrated ballooning of the mid-ventricular and apical segments with hyperkinesis of the basal segment, consistent with TCM (**Figure 3B**).

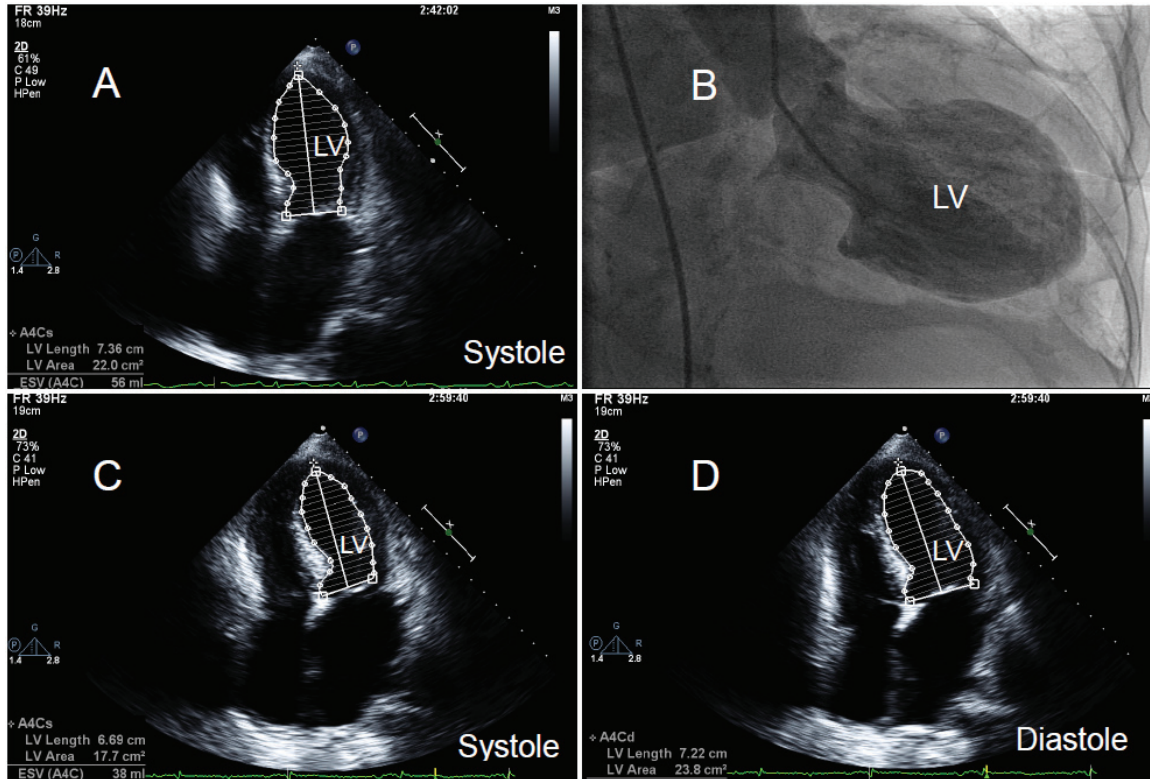
Standard therapy for LV systolic dysfunction was initiated based on American Heart Association guidelines. Fluid overload was treated with loop diuretics until the patient was euvolemic and no longer short of breath. An Echocardiogram performed two weeks after discharge revealed normalization of LV function with an ejection fraction of 30% (**Figure 3C**) and (**Figure 3D**).

## Discussion

Our three cases demonstrate the typical presentation of TCM with chest pain and dyspnea that mimics acute coronary syndromes. All three patients had dynamic EKG changes, elevated cardiac biomarkers, wall motion abnormalities on echocardiogram, yet angiographically normal coronary arteries. Additionally, all patients demonstrated improvement in LV function over days to weeks. Takotsubo cardiomyopathy was triggered by very different situations in each case, which emphasizes the principle that any event stressful enough to raise circulating epinephrine to supraphysiologic levels could potentially cause TCM in susceptible patients.

The exact mechanism responsible for the myocardial injury and temporary dysfunction characteristic of TCM is not yet completely understood. It does appear, however, that surges in catecholamines, particularly epinephrine, following severe and acute stress play a central role. Animal studies examining the effect of





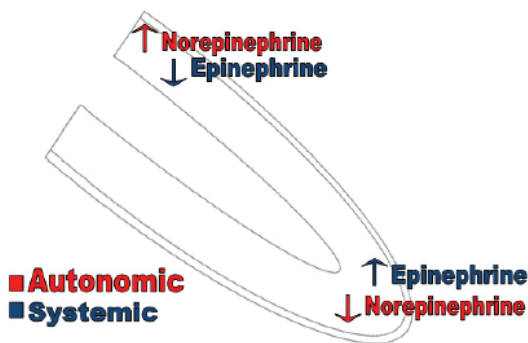
**Figure 3.** 2-D Echo during systole upon admission showing apical akinesis and basal hyperkinesis (A). Left Ventriculogram during systole with akinesis of mid and apical segments and basal hyperkinesis (B). 2-D Echo during systole performed two weeks after diagnosis showing improvement in LV function, particularly the apical segment (C). 2-D Echo during diastole performed two weeks after diagnosis with improvement in ventricular dilatation (D).

various concentrations of epinephrine on the rodent heart support this hypothesis [9]. A transient cardiomyopathy, similar to TCM, has been observed in rats after the administration of beta adrenergic receptor agonists. Additionally, like TCM, the cardiomyopathy improved with discontinuation of the offending agent [10]. In humans a pattern of myocardial injury identical to TCM has been observed in patients with pheochromocytoma, an epinephrine producing tumor. Removal of the pheochromocytoma resulted in recovery of LV function [11].

Epinephrine has a higher relative affinity for the beta2 subtype of adrenergic receptors. Norepinephrine, on the other hand, exerts its physiologic action through activation of the beta1 receptor subtype. Norepinephrine is produced in the axons of post-synaptic sympathetic neurons, thus Norepinephrine will be present in higher concentrations in regions of the heart with greater densities of sympathetic neurons. In the human heart the density of sympathetic neurons is highest in the basal region, with

approximately 40% more neurons than the apex [12]. Epinephrine is produced in the adrenal medulla and reaches the heart through the systemic circulation, thus the entire myocardium will be exposed to the same dose of epinephrine. The relative influence on myocardial function of norepinephrine and epinephrine is depicted in **Figure 4**.

Both the beta1 and beta 2 adrenergic receptor subtypes are G-protein coupled receptors. Under normal circumstances both receptors couple to the Gs G-protein subunit. The Gs subunit exerts a stimulatory effect within cells through activation of adenylyl cyclase, which catalyses the formation of cyclic adenosine monophosphate (cAMP), which then activates protein kinase A which stimulates energy uptake and facilitates myocyte contraction [13]. The beta1 receptor only couples with the Gs subunit. The beta2 receptor, when exposed to supraphysiologic doses of epinephrine, has been shown to couple with the Gi G-protein [14-16]. This phenomenon is known as signal traf-



**Figure 4.** Schematic distribution of the autonomic innervations through norepinephrine predominantly in the basal areas and systemic effects of epinephrines in the apical area of the ventricle.

ficking and carries important physiologic consequences. When activated the Gi subunit exerts an inhibitory effect within the myocyte by inhibiting adenyl cyclase activity and decreasing intracellular levels of cAMP.

Signal trafficking may carry additional physiologic benefits. The Gi G-protein subunit has been shown to inhibit myocyte apoptosis through activation of the mitogen-activated protein kinase/extracellular signal-regulated protein kinase (MAPK/ERK), phosphatidylinositol-3', and Akt/protein kinase B pathway [17].

Severe stress increases both sympathetic nervous system activity and epinephrine production in the adrenal medulla. Under these conditions, norepinephrine mediated activation of beta1 receptors is the predominate effect on basilar myocardium. This results in continuous activation of the Gs subunit, increased production of intracellular cAMP, with an overall inotropic effect. While circulating epinephrine activation of beta2 receptors is the predominate effect in the mid-ventricular and apical segments. Initially this promotes myocardial contraction though Gs subunit activation. Once a critical concentration of epinephrine is reached signal trafficking occurs and further stimulation of the beta2 receptor results will have a negative inotropic effect. This pattern of beta adrenergic activation explains the wall motion abnormalities characteristic of TCM (basal hyperkinesis with mid-ventricular and apical dyskinesia).

Certain genetic polymorphisms of the beta adrenergic receptors appear to predispose

affected patients to the development of TCM. Vríz et al demonstrated that substitution of Arginine for Glycine at amino acid 389 (Gly389Arg) of the beta1 adrenergic receptor was more common in patients with TCM than normal controls [18]. This mutation results in a gain of function that alters Gs-protein coupling with the beta1 adrenergic receptor. Excess stimulation of the beta1 receptor may, in part, explain the cardiotoxicity seen in patients with TCM.

The switch from Gs coupling to Gi coupling may play an important myocardial protective role. The heart cannot maintain maximal contraction indefinitely. Eventually energy sources are exhausted, toxic metabolites accumulate, and contractile proteins begin to breakdown resulting in myocyte necrosis (clinically evident as elevated serum troponin) [19]. The ability to “turn off” or hibernate a portion of the myocardium in the face of extreme physiologic stress may be a survival mechanism that insures, if the organism survives the stressful situation, there will still be a functioning myocardium [9, 20].

## Conclusion

Takotsubo cardiomyopathy is a heterogeneous disease with a variable clinical presentation. Common symptoms include chest pain and dyspnea mimicking acute coronary syndrome following a severely stressful event. Given the heterogeneity of presentation, objective criteria have been developed to aid in diagnosing TCM. With the development and widespread use of invasive coronary angiography many more patients with presumed acute coronary syndromes are discovered to have TCM. It has been purposed that TCM may in fact be a myocardial protective response elicited via a change in G-protein coupling (Gs to Gi subunit) by the beta2 adrenergic receptor. This phenomenon is known as “signal trafficking”. Additionally, adrenergic receptor polymorphisms may predispose certain patients to the development of TCM.

**Address correspondence to:** Dr. Sachin Kumar Amruthlal Jain, Providence Heart Institute, Providence Hospital and Medical Centers, 16001 West Nine Mile Road, Southfield, MI 48075. Phone: 248-849-2842; Fax: 248-849-2790; E-mail: doctor-sachin@gmail.com

## References

- [1] Sato H TH, Uchida T, Dote K, Ishihara M. Stunned myocardium with specific (tsubo-type) left ventriculographic configuration due to multivessel spasm. In: Kodama K, Haze K, Hori M, Eds. Clinical aspects of myocardial injury: From ischemia to heart failure. Japanese: Kagakuhyouronsya Co 1990; pp: 56-64.
- [2] Kawai S, Kitabatake A and Tomoike H. Guidelines for diagnosis of takotsubo (ampulla) cardiomyopathy. *Circ J* 2007; 71: 990-992.
- [3] Deshmukh A, Kumar G, Pant S, Rihal C, Murugiah K and Mehta JL. Prevalence of Takotsubo cardiomyopathy in the United States. *Am Heart J* 2012 Jul; 164: 66-71.e1.
- [4] El-Sayed AM, Brinjikji W and Salka S. Demographic and co-morbid predictors of stress (takotsubo) cardiomyopathy. *Am J Cardiol* 2012; 110: 1368-1372.
- [5] Bybee KA, Kara T, Prasad A, Lerman A, Barsness GW, Wright RS and Rihal CS. Systematic review: transient left ventricular apical ballooning: a syndrome that mimics ST-segment elevation myocardial infarction. *Ann Intern Med* 2004; 141: 858-865.
- [6] Golabchi A and Sarrafzadegan N. Takotsubo cardiomyopathy or broken heart syndrome: A review article. *J Res Med Sci* 2011; 16: 340-345.
- [7] Naser N, Buksa M, Kusljagic Z, Terzic I, Sokolovic S and Hodzic E. The role of echocardiography in diagnosis and follow up of patients with takotsubo cardiomyopathy or acute ballooning syndrome. *Med Arh* 2011; 65: 287-290.
- [8] Madhavan M, Rihal CS, Lerman A and Prasad A. Acute heart failure in apical ballooning syndrome (TakoTsubo/stress cardiomyopathy): clinical correlates and Mayo Clinic risk score. *J Am Coll Cardiol* 2011; 57: 1400-1401.
- [9] Lyon AR, Rees PS, Prasad S, Poole-Wilson PA and Harding SE. Stress (Takotsubo) cardiomyopathy—a novel pathophysiological hypothesis to explain catecholamine-induced acute myocardial stunning. *Nat Clin Pract Cardiovasc Med* 2008; 5: 22-29.
- [10] Ueyama T. Emotional stress-induced Tako-tsubo cardiomyopathy: animal model and molecular mechanism. *Ann N Y Acad Sci* 2004; 1018: 437-444.
- [11] Iga K, Gen H, Tomonaga G, Matsumura T and Hori K. Reversible left ventricular wall motion impairment caused by pheochromocytoma—a case report. *Jpn Circ J* 1989; 53: 813-818.
- [12] Kawano H, Okada R and Yano K. Histological study on the distribution of autonomic nerves in the human heart. *Heart Vessels* 2003; 18: 32-39.
- [13] Xiang YK. Compartmentalization of beta-adrenergic signals in cardiomyocytes. *Circ Res* 2011; 109: 231-244.
- [14] Daaka Y, Luttrell LM and Lefkowitz RJ. Switching of the coupling of the beta2-adrenergic receptor to different G proteins by protein kinase A. *Nature* 1997; 390: 88-91.
- [15] Heubach JF, Ravens U and Kaumann AJ. Epinephrine activates both Gs and Gi pathways, but norepinephrine activates only the Gs pathway through human beta2-adrenoceptors overexpressed in mouse heart. *Mol Pharmacol* 2004; 65: 1313-1322.
- [16] Zamah AM, Delahunty M, Luttrell LM and Lefkowitz RJ. Protein kinase A-mediated phosphorylation of the beta 2-adrenergic receptor regulates its coupling to Gs and Gi. Demonstration in a reconstituted system. *J Biol Chem* 2002; 277: 31249-31256.
- [17] Chesley A, Lundberg MS, Asai T, Xiao RP, Ohtani S, Lakatta EG and Crow MT. The beta(2)-adrenergic receptor delivers an antiapoptotic signal to cardiac myocytes through G(i)-dependent coupling to phosphatidylinositol 3'-kinase. *Circ Res* 2000; 87: 1172-1179.
- [18] Vriz O, Minisini R, Citro R, Guerra V, Zito C, De Luca G, Pavan D, Pirisi M, Limongelli G and Bossone E. Analysis of beta1 and beta2-adrenergic receptors polymorphism in patients with apical ballooning cardiomyopathy. *Acta Cardiol* 2011; 66: 787-790.
- [19] Rona G. Catecholamine cardiotoxicity. *J Mol Cell Cardiol* 1985; 17: 291-306.
- [20] Nef HM, Mollmann H, Troidl C, Kostin S, Voss S, Hilpert P, Behrens CB, Rolf A, Rixe J, Weber M, Hamm CW and Elsasser A. Abnormalities in intracellular Ca<sup>2+</sup> regulation contribute to the pathomechanism of Tako-Tsubo cardiomyopathy. *Eur Heart J* 2009; 30: 2155-2164.